

43^{ème} CONGRÈS ANNUEL de la



SFNR
SOCIÉTÉ FRANÇAISE
DE NEURORADIOLOGIE



Du **30 mars** au
1^{er} avril 2016
Novotel Paris Tour Eiffel



IRM de perfusion par marquage de spin artériels : intérêt dans les malformations artério-veineuses cérébrales de l'enfant

O. Naggara, MD, PhD - T. Blauwblomme , MD, PhD - G. Boulouis, MD, MSc –
F. Brunelle, MD, PhD – M. Bourgeois, MD- C. Oppenheim, MD, PhD –
S. Puget, MD, PhD - M. Zerah, MD, PhD - C. Sainte-Rose , MD, PhD –
N. Boddaert, MD, PhD



43^{ème} congrès de la SFNR – Paris

FACULTÉ
DE MÉDECINE
PARIS DESCARTES



Conflits d'intérêt

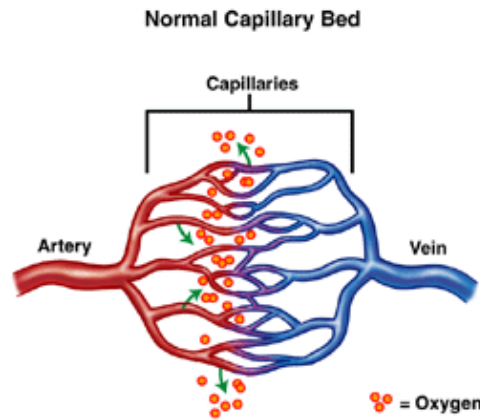
- Aucun

Shunts artério-veineux

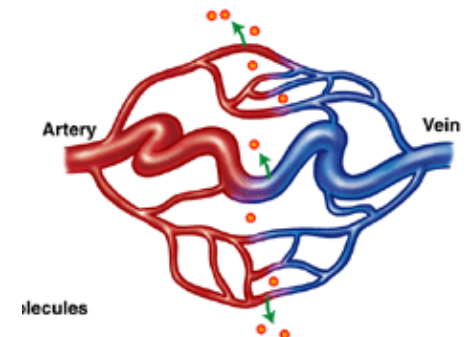
- Communication anormale entre un segment artériel et un segment veineux

- Unique ou multiple

- Simple ou **complexe**



Arteriovenous Malformation



Shunts artério-veineux

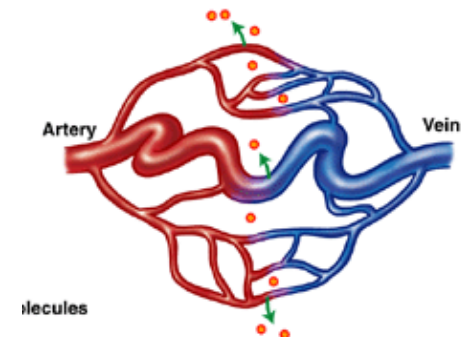
- Conséquences

→ locale : Hyperdébit vasculaire (insuffisance cardiaque)

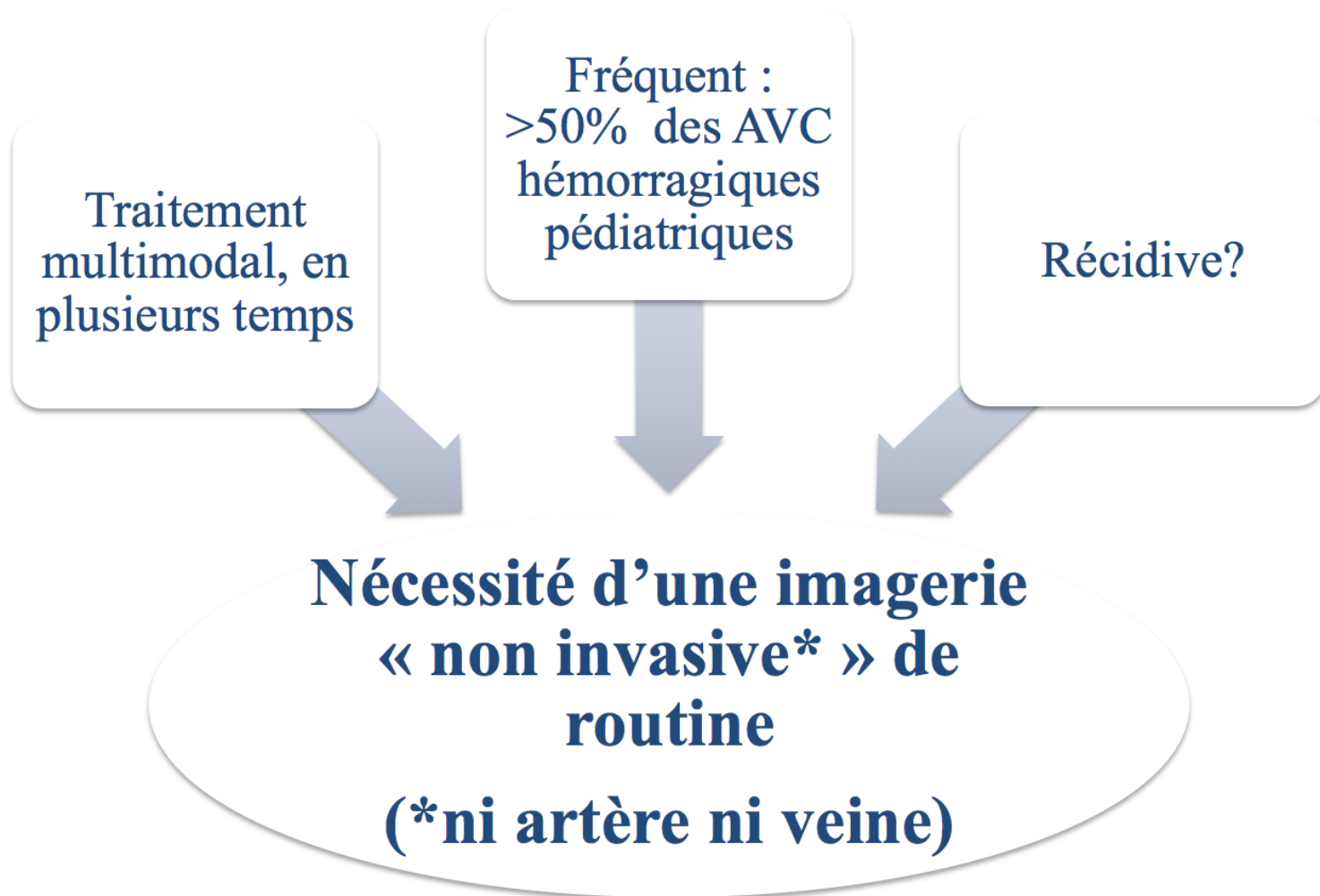
→ régionale: vol vasculaire et ischémie

→ globale : élévation chronique de la pression veineuse

Arteriovenous Malformation



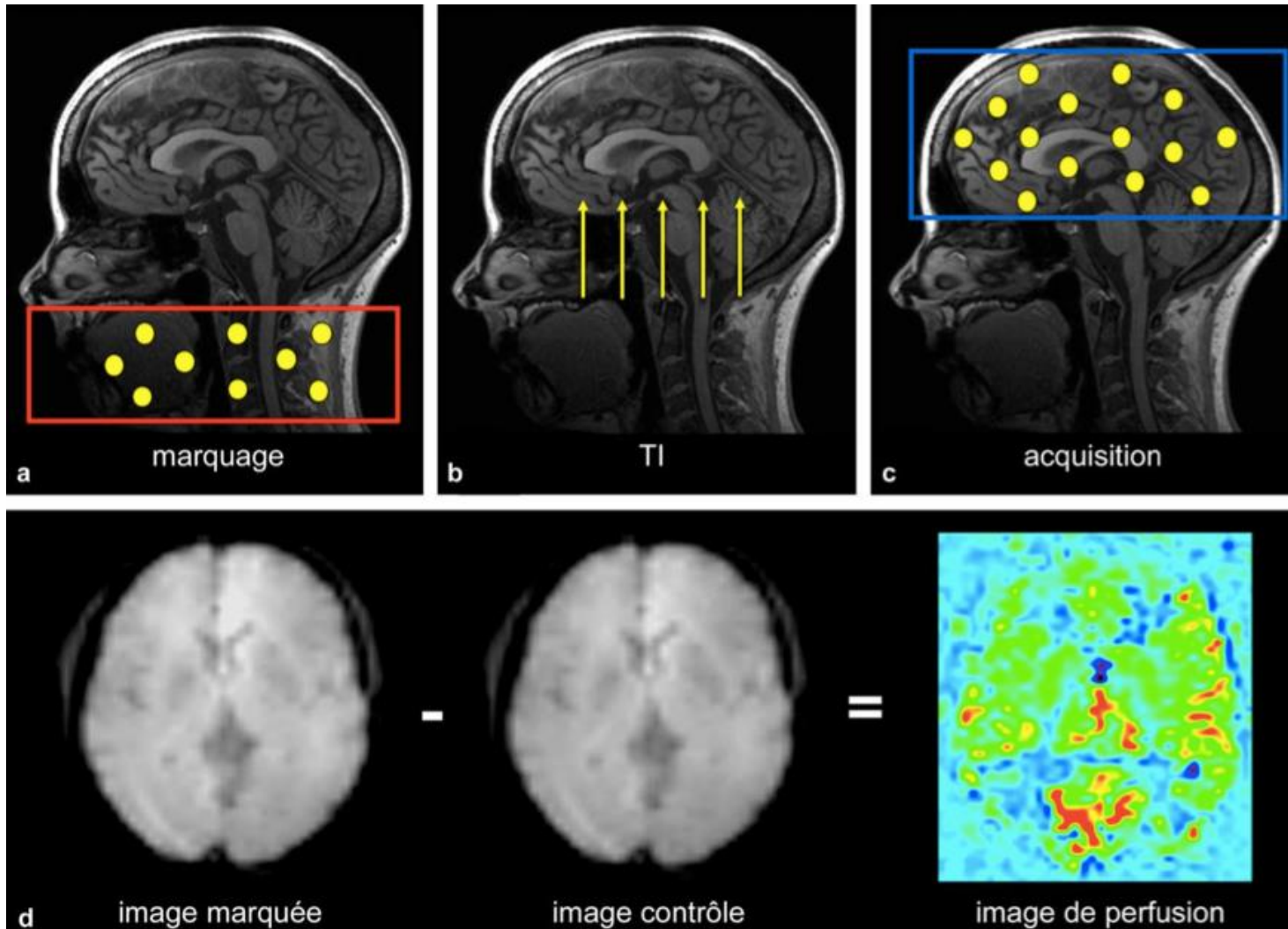
Shunts artério-veineux



Shunts artério-veineux

- Questions habituelles vis-à-vis d'une (nouvelle) technique d'imagerie :
 - Peut elle affirmer la présence d'un shunt ?
 - Peut elle éliminer la présence d'un shunt ?

ASL-MRI: Principes



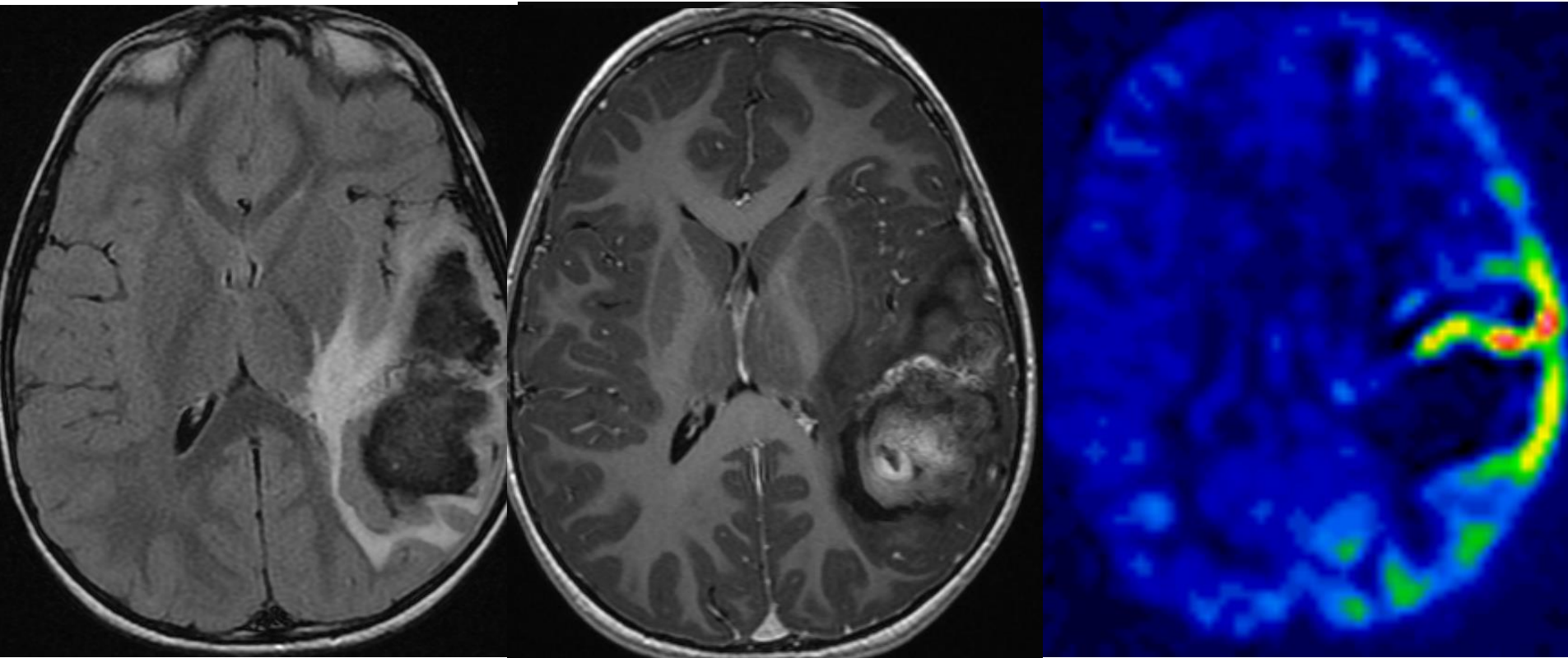
Protocole ASL Necker

- 1,5T
- ASL pseudo continu
 - TE=10,5ms
 - PLD=1025ms
 - Flip angle=155°
- Analyse Image
 - Segmentation ROI
 - Quantification DSC

Détection du shunt par ASL

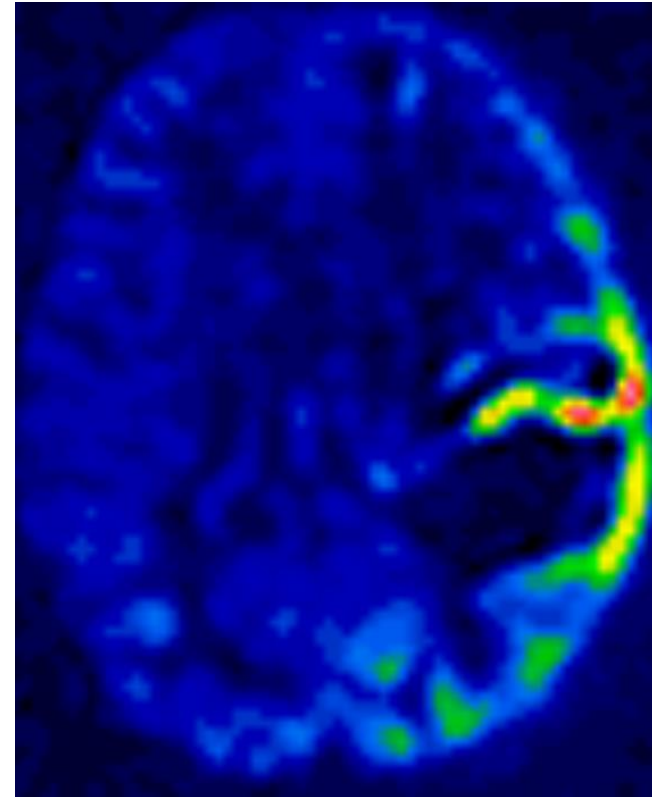
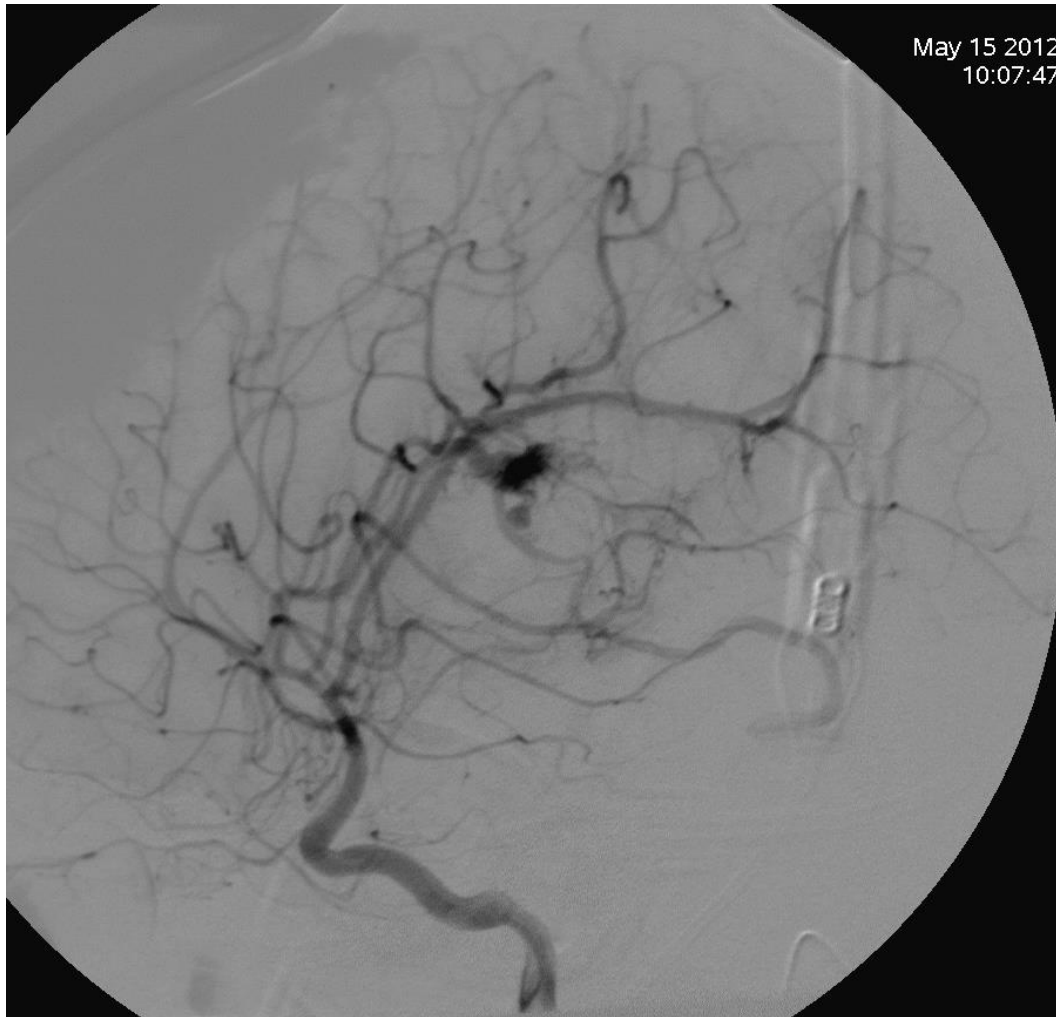May 10 2012
08:52:15 PM

Aide au diagnostic (+) de shunt artério-veineux

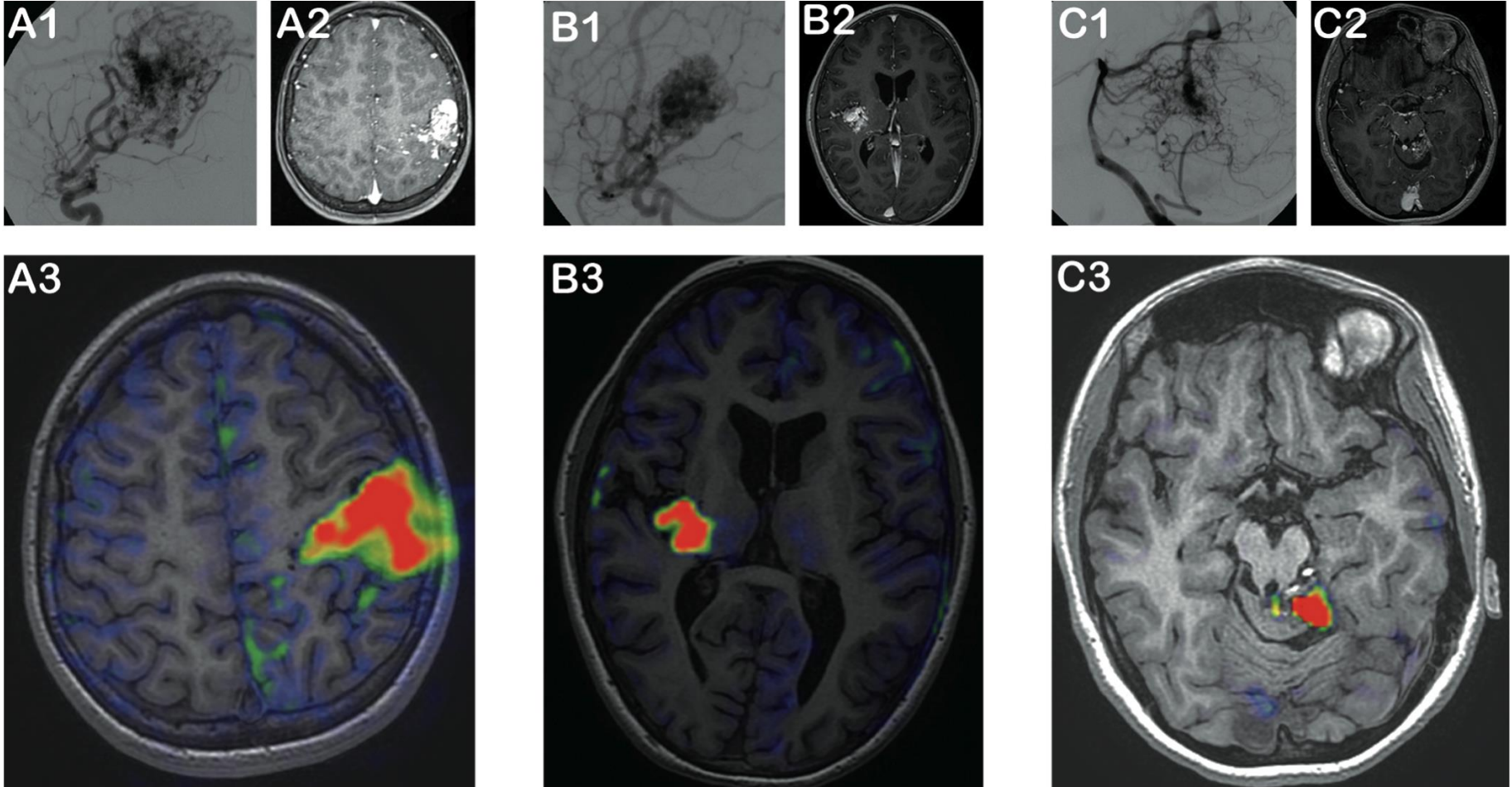


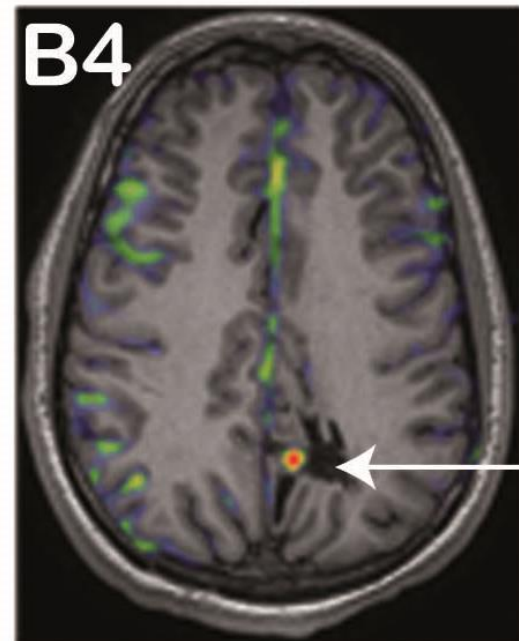
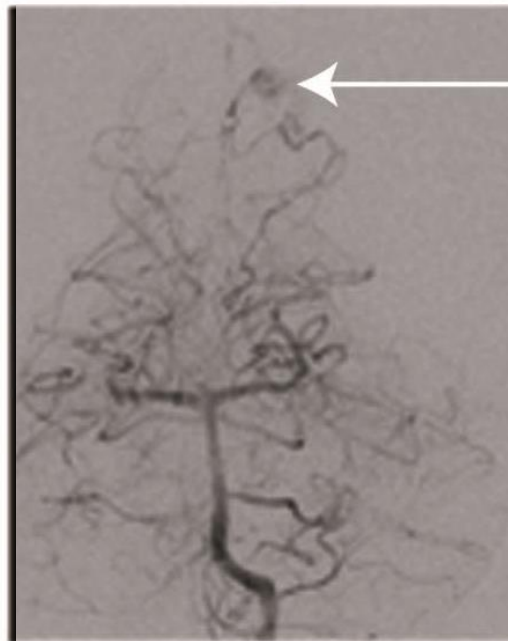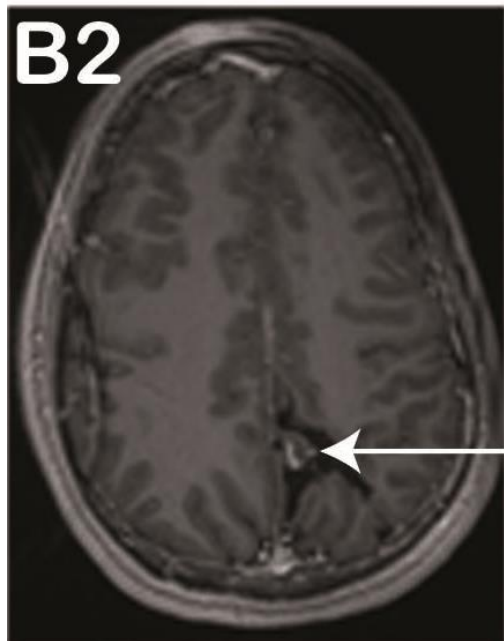
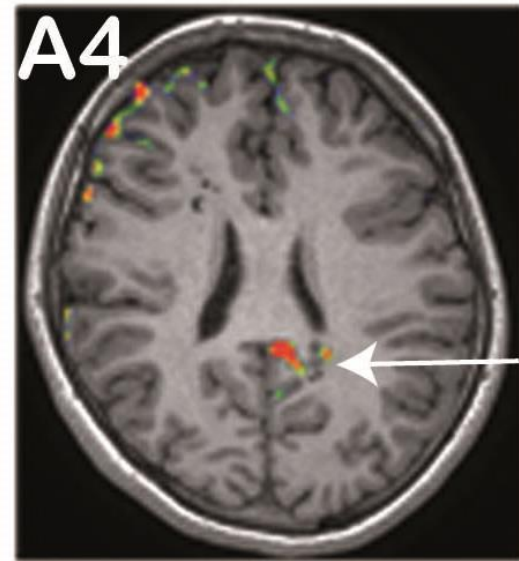
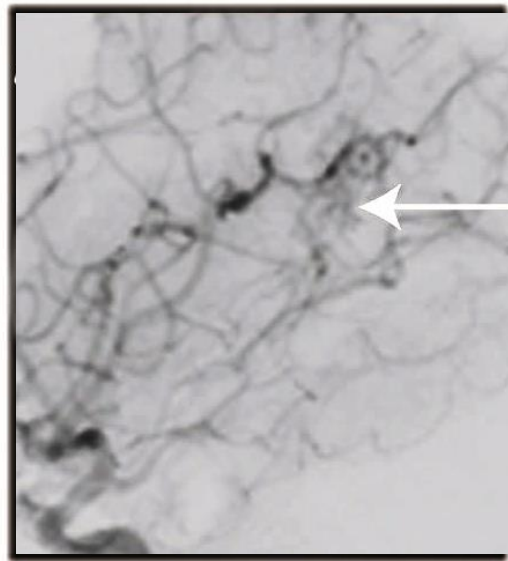
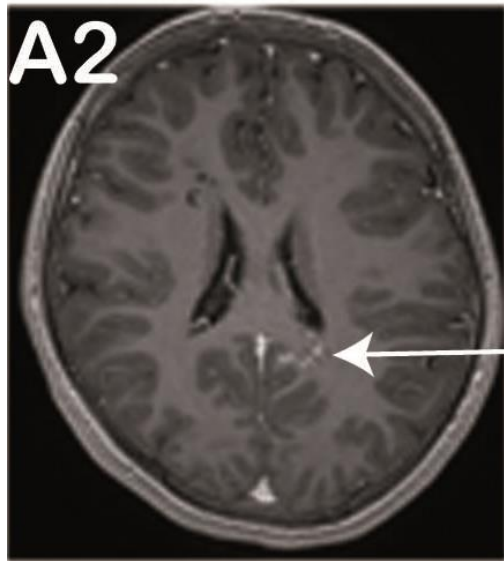
Chloé, 4 ans

Aide au diagnostic (+) de shunt artériovoineux





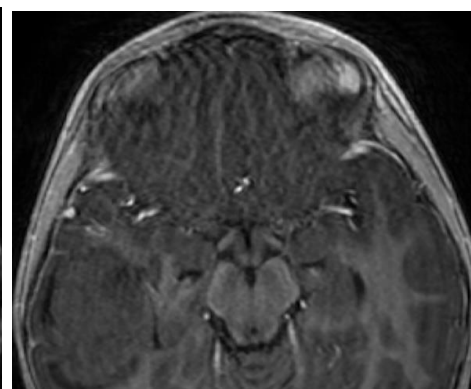
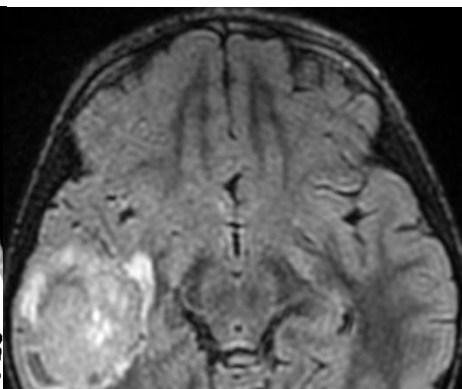
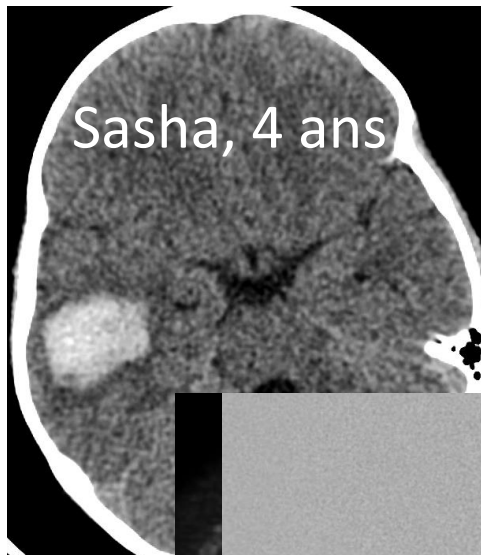
Aide au diagnostic (+) de shunt artério-veineux





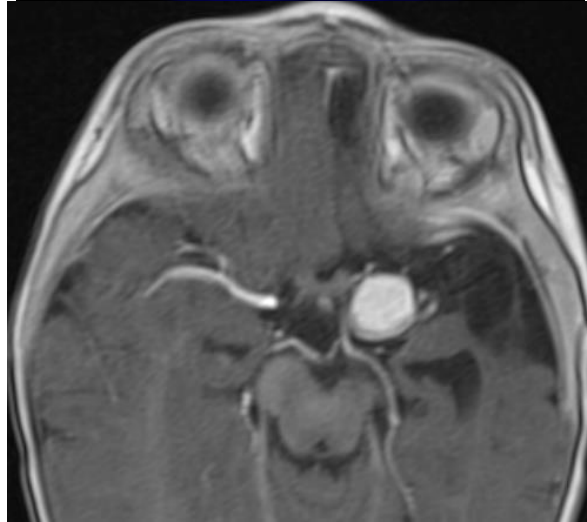
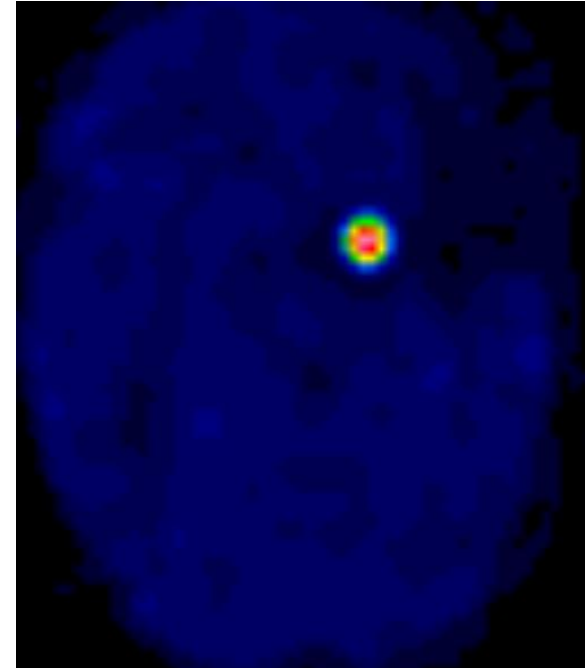
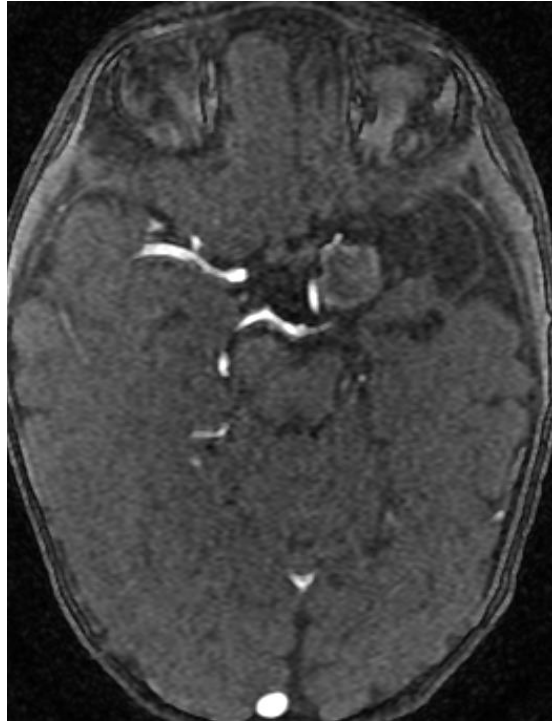
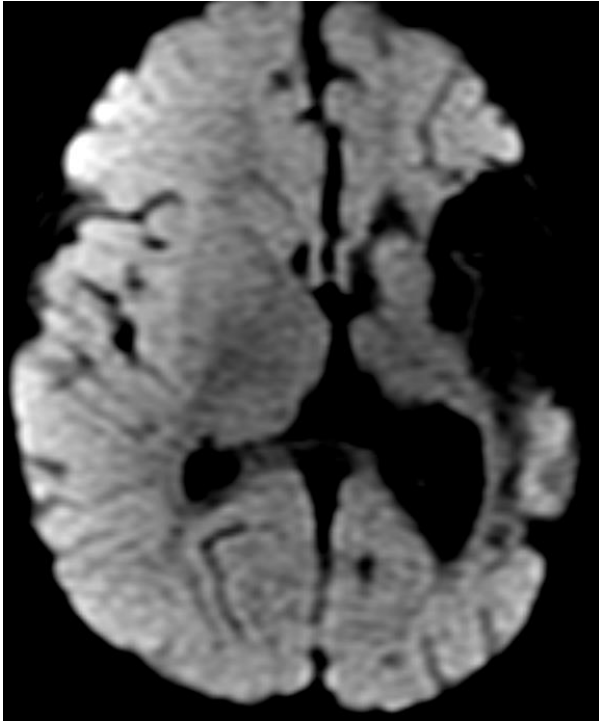
Rater un shunt est possible

L'imagerie dynamique reste indispensable dans certains cas



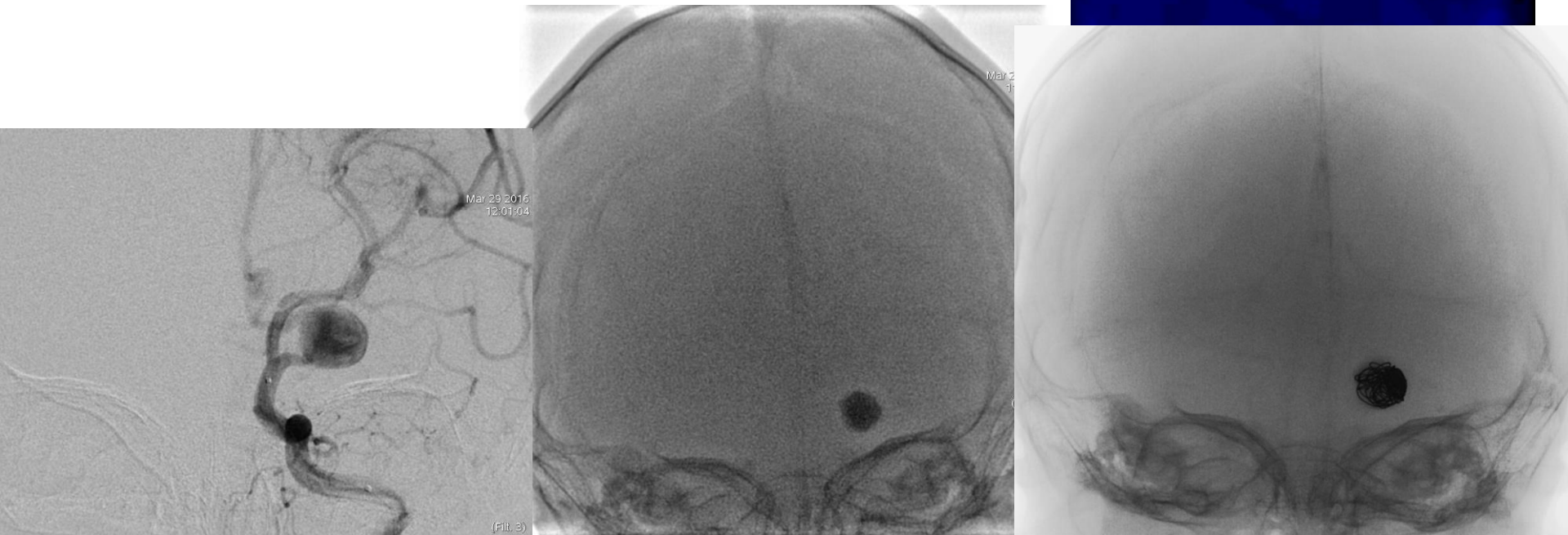
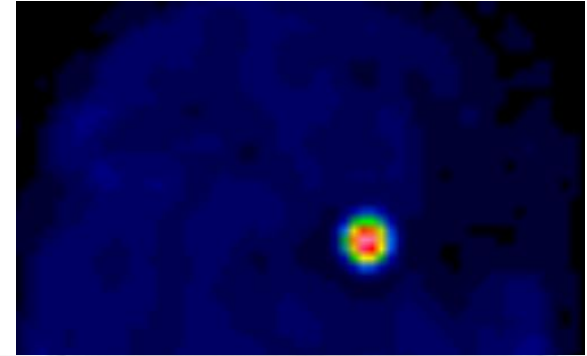
Très sensible mais attention aux nombreux faux (+)

Enzo, 7 mois, AVC à 2 mois de vie



Attention aux faux positifs

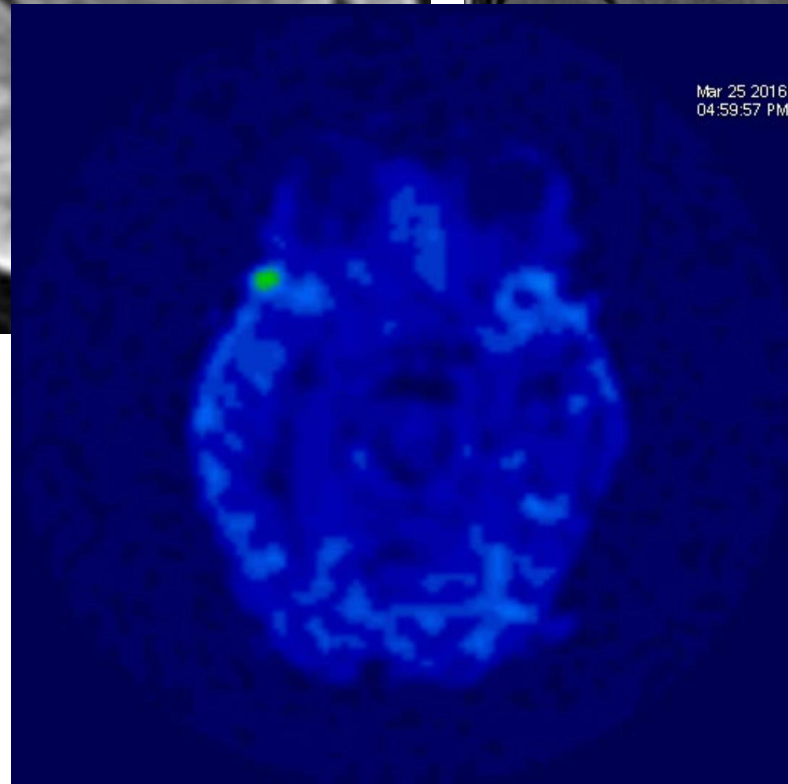
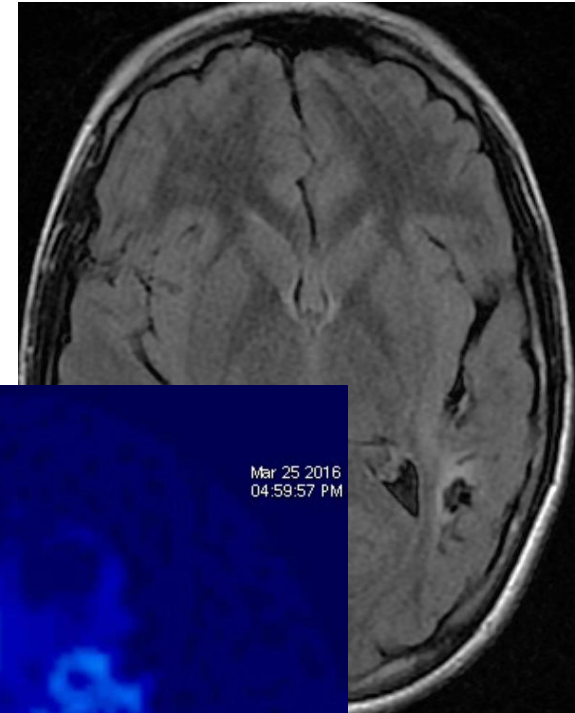
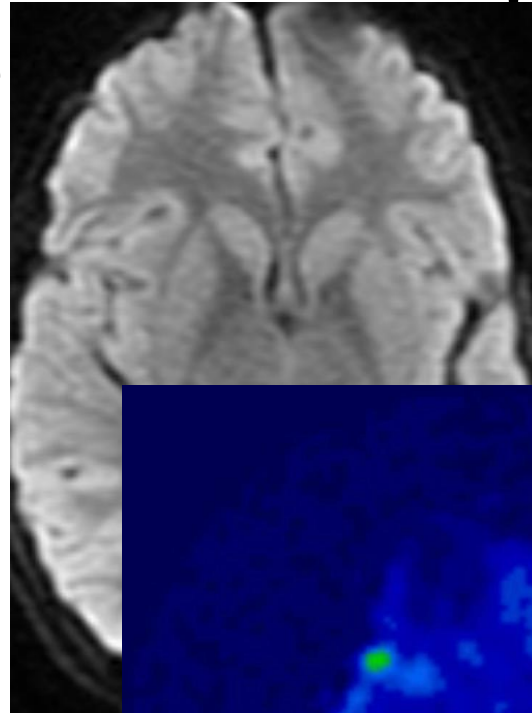
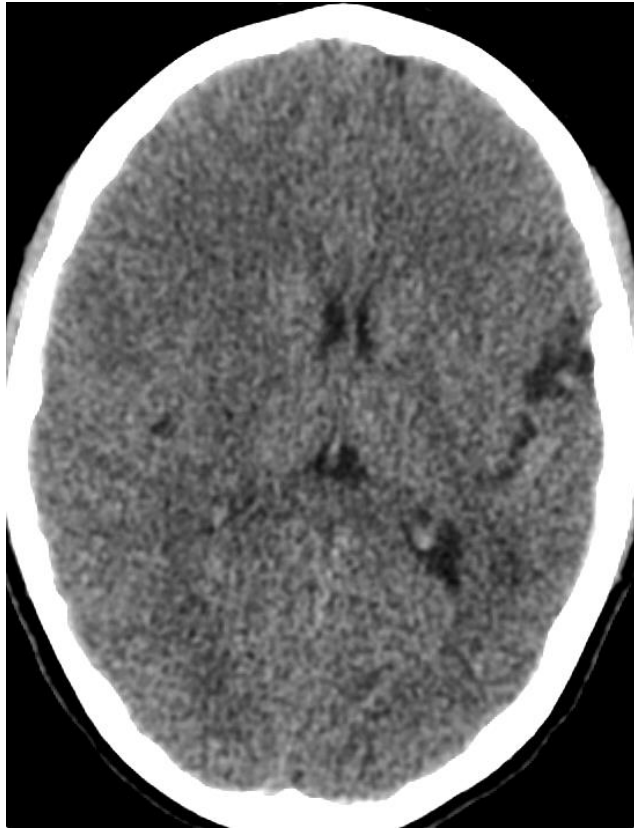
Enzo, 7 mois, AVC à 2 mois de vie



stagnation artérielle

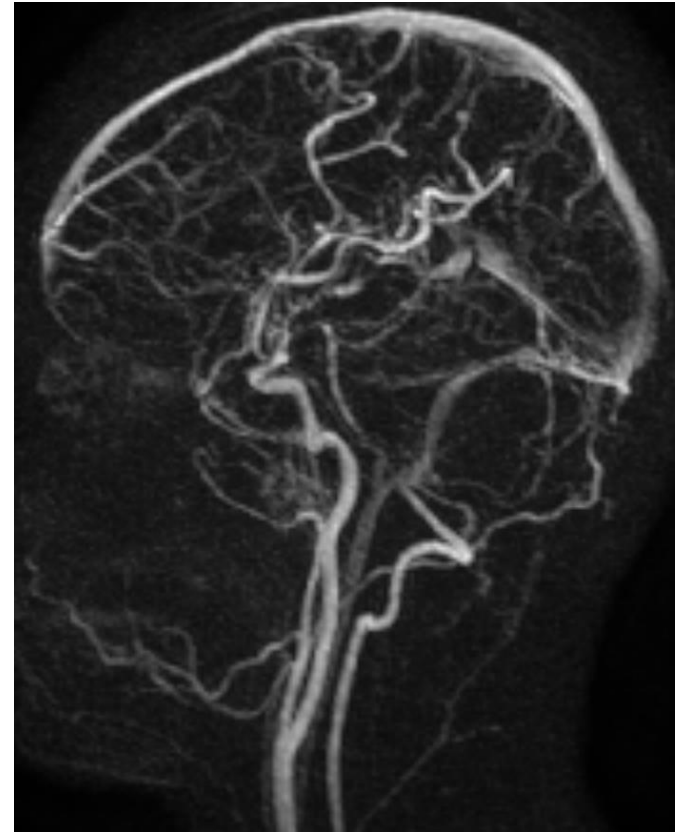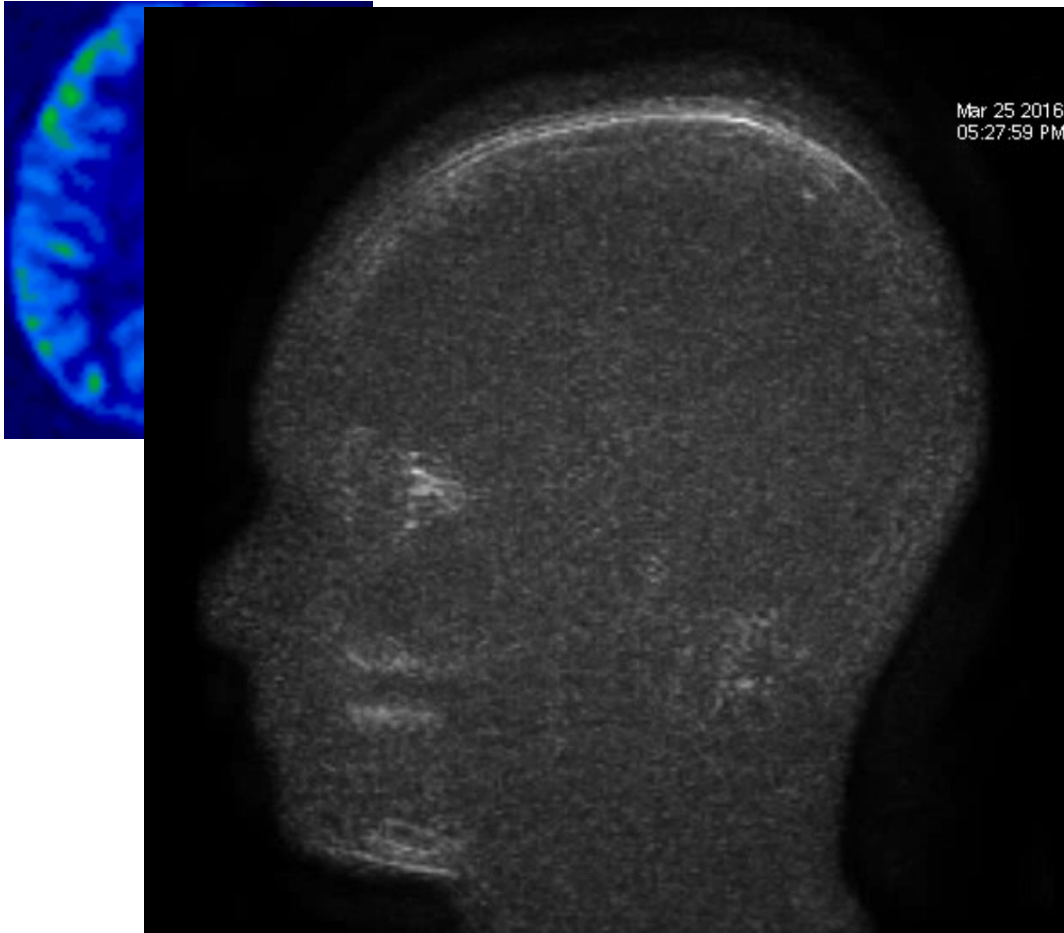
Attention aux faux positifs

Vincent, 14 ans, AIT sylvien gauche

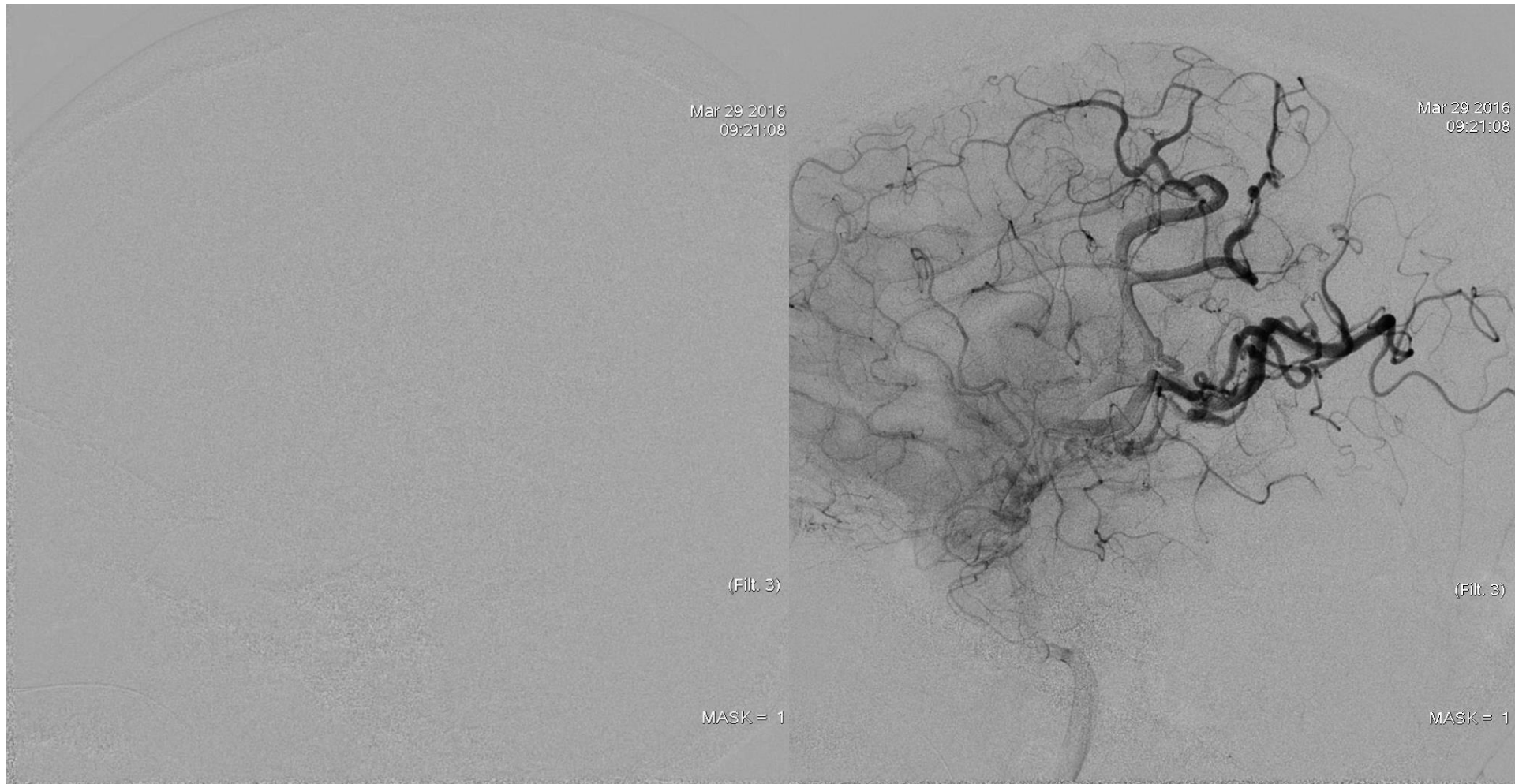


Attention aux faux positifs

Vincent, 14 ans, AIT sylvien gauche

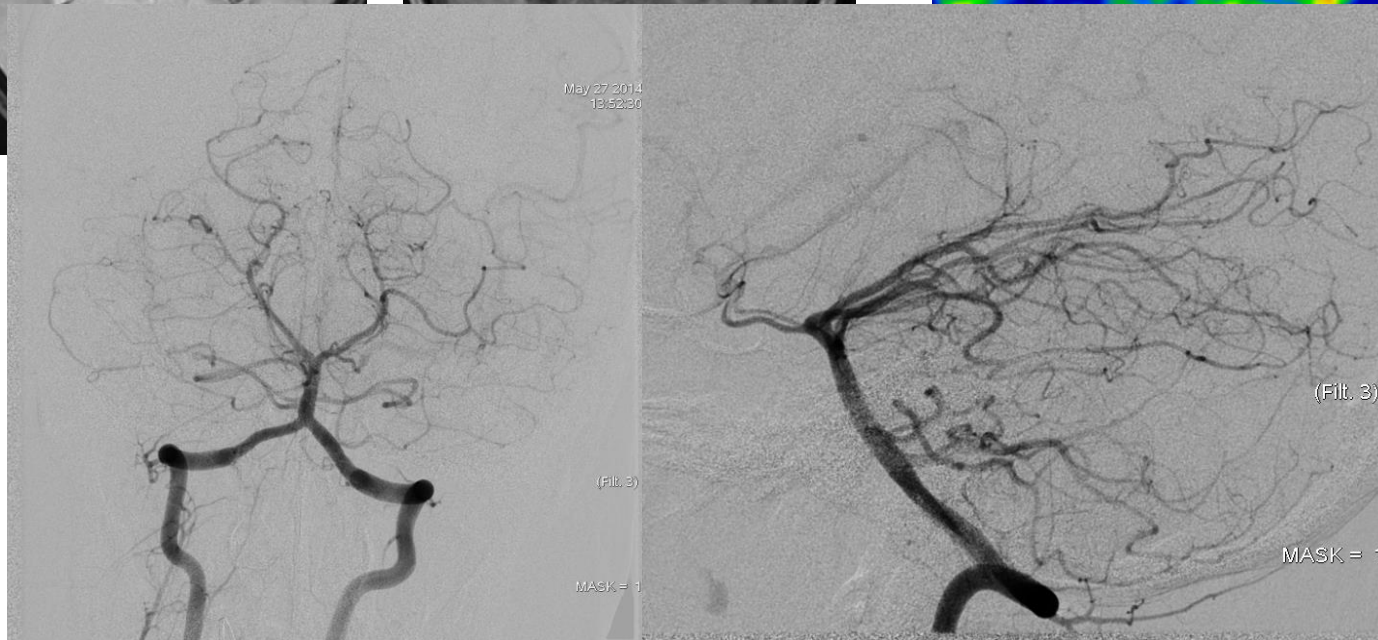
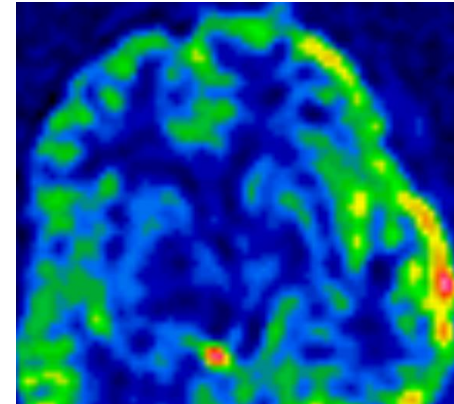
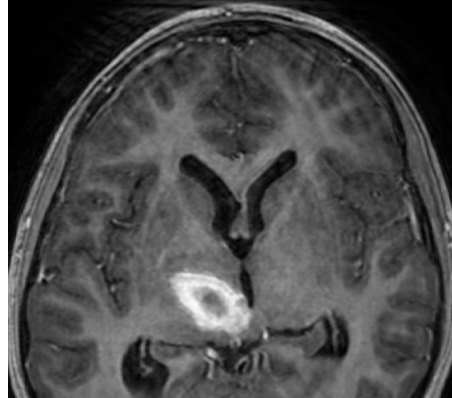
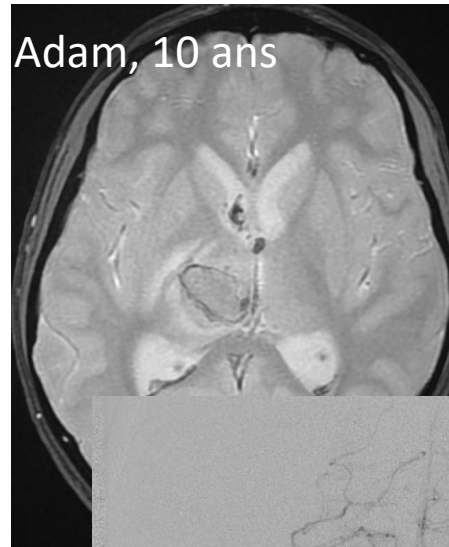


Attention aux faux positifs

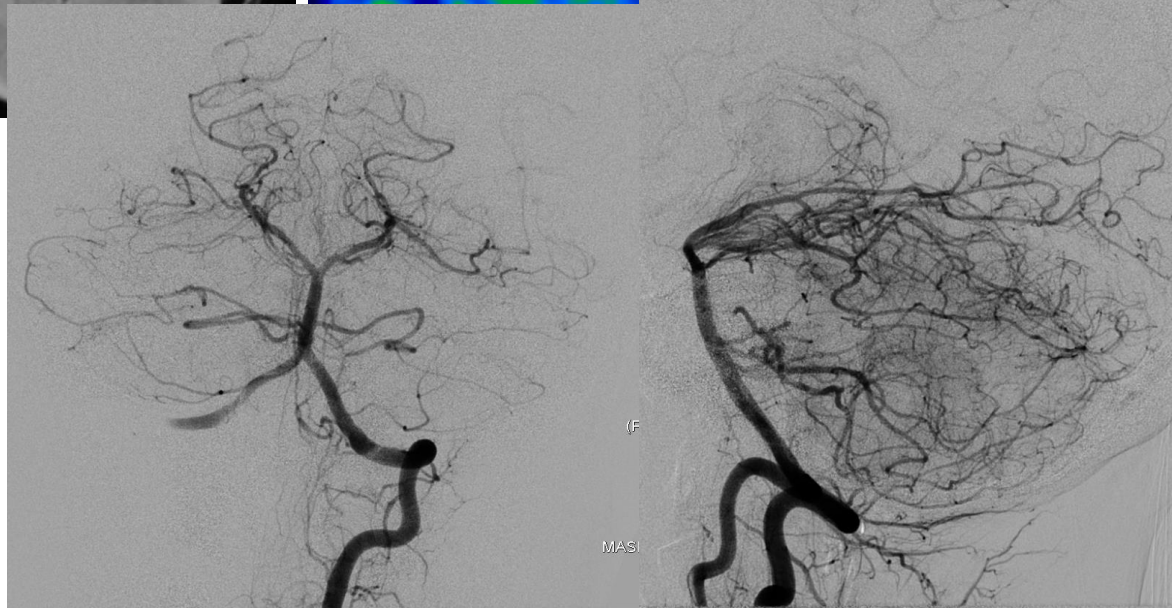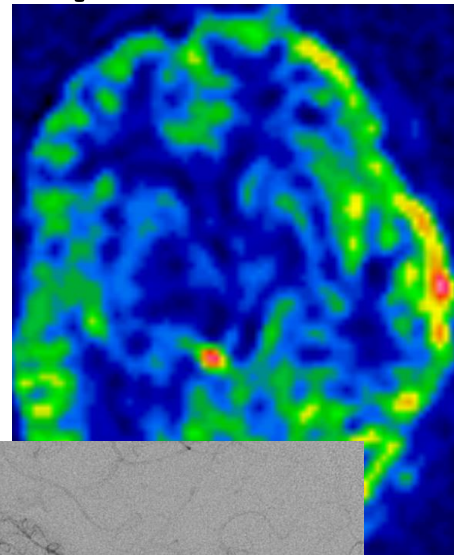
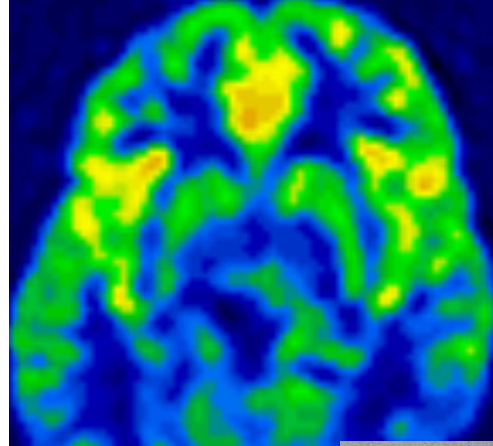
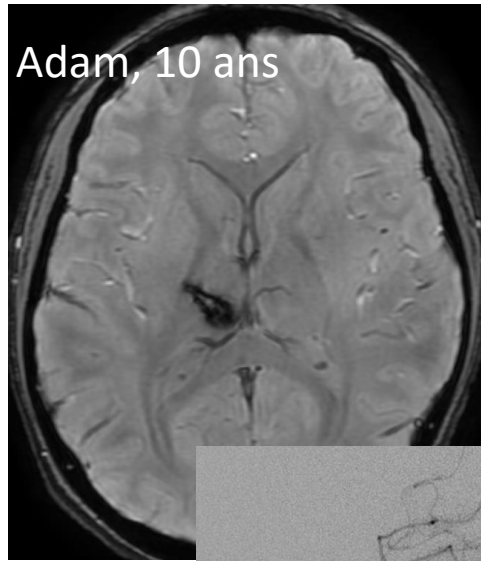


Ralentissement artériel

Attention aux faux positifs



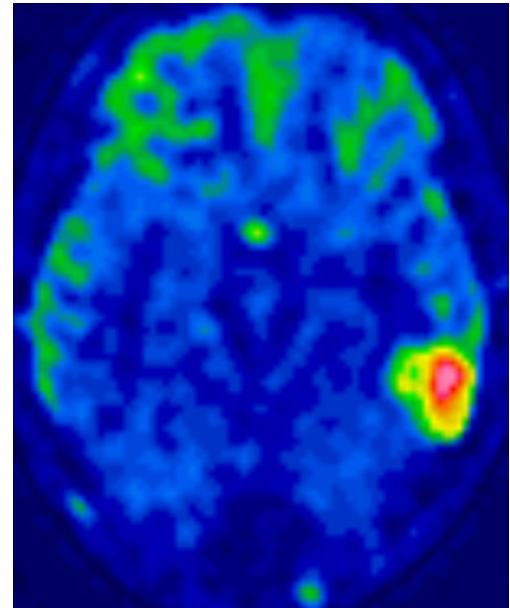
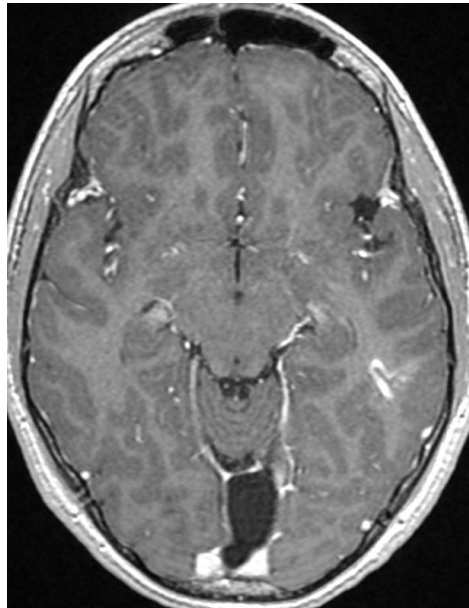
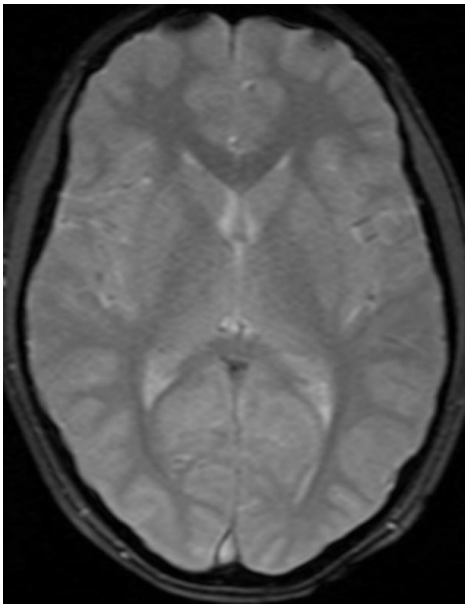
Attention aux faux positifs



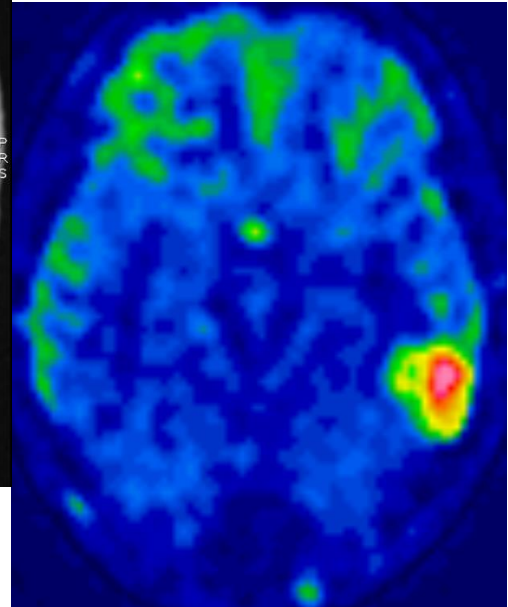
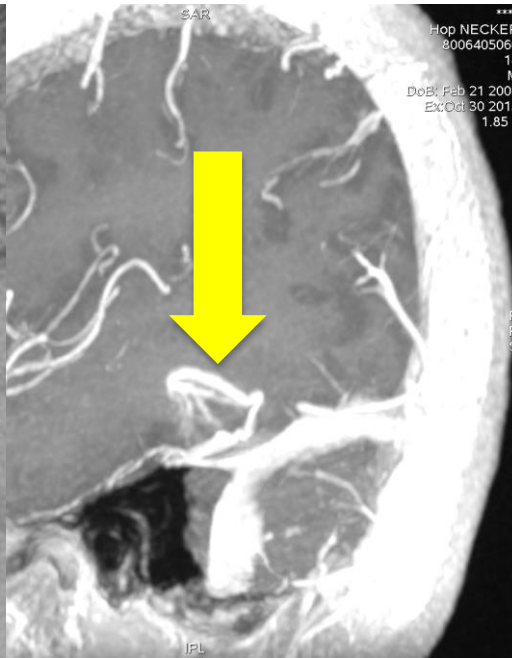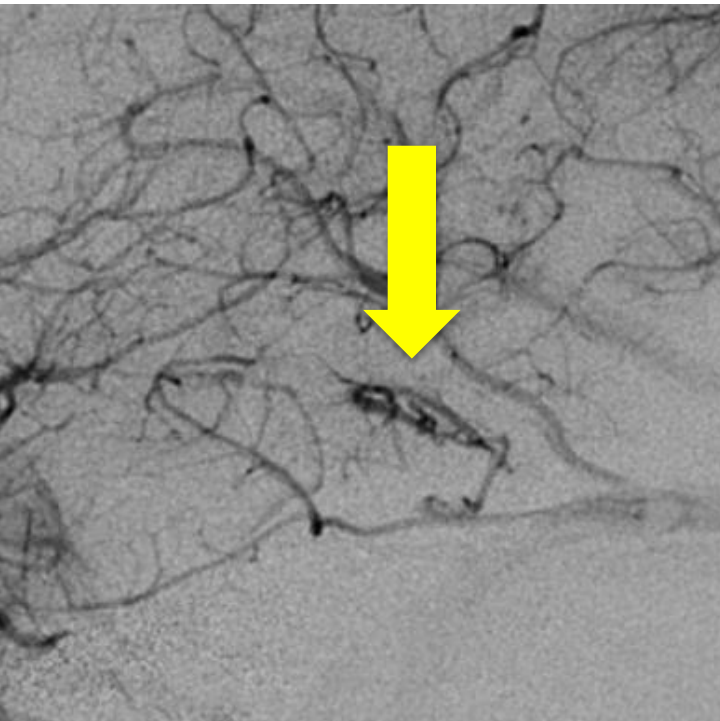
Péri-hématome

Attention aux faux positifs

Naim, 14 ans

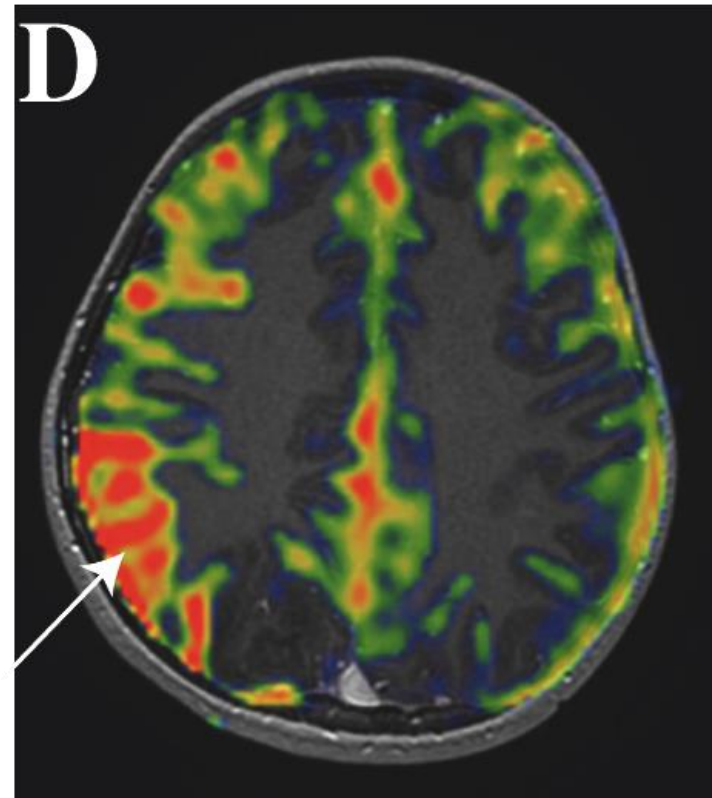
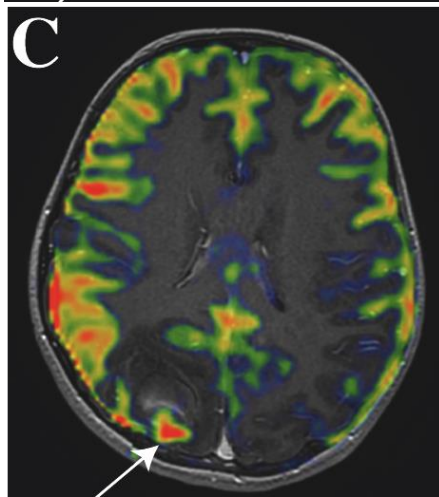
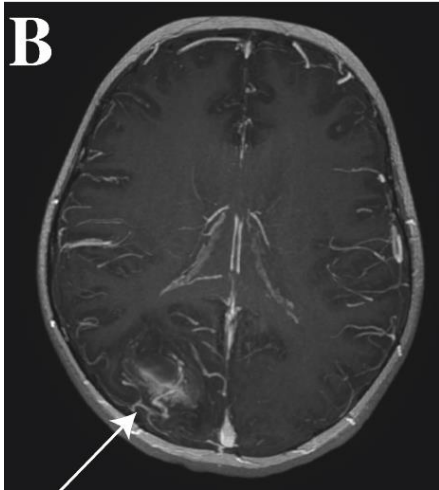


Attention aux faux positifs



Stagnation veineuse dans une AVD

Attention aux faux positifs



Anomalies per-critiques

ASL et malformation artérioveineuse cérébrale de l'enfant

- Questions habituelles vis-à-vis du shunt :

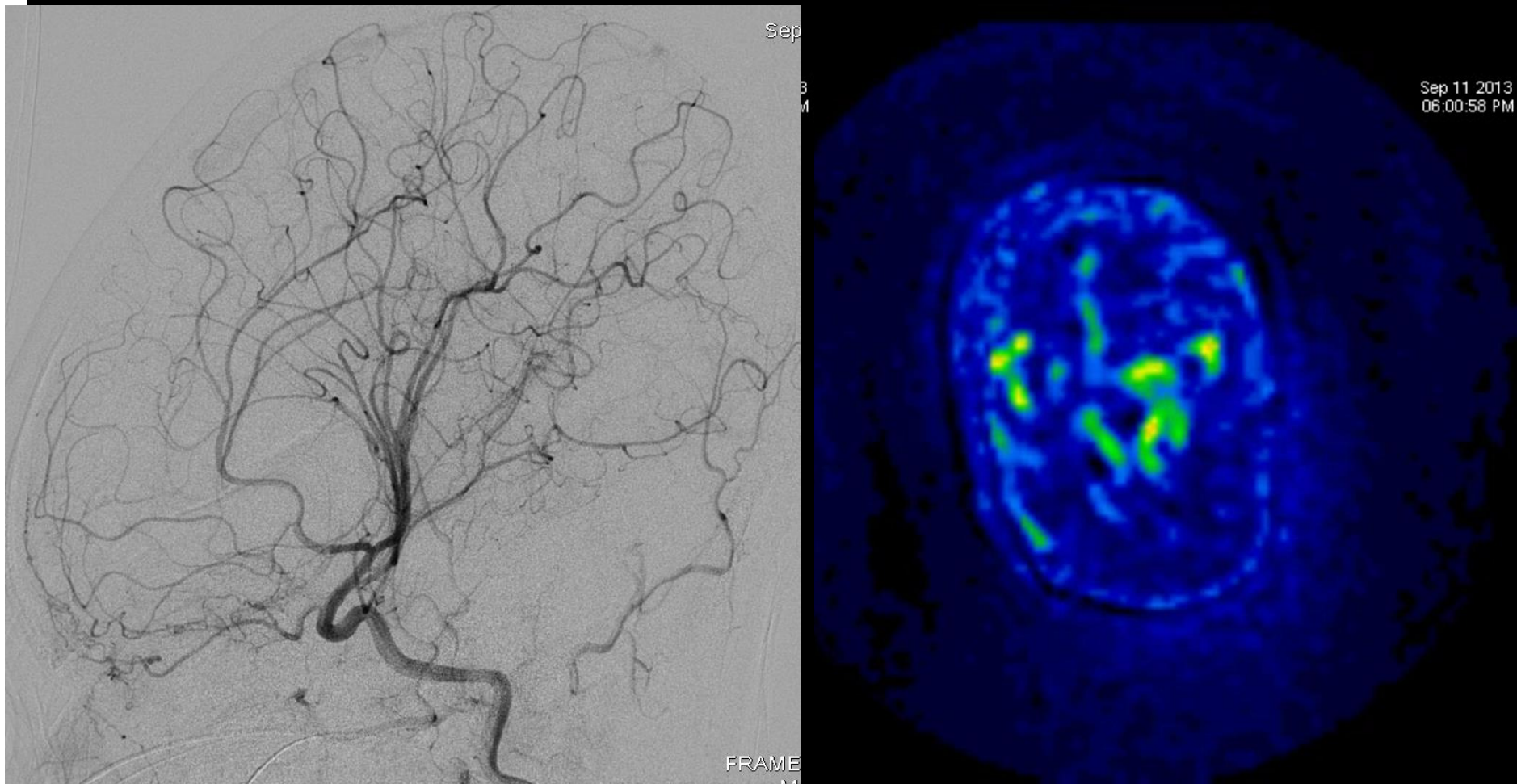
→ Affirmer sa présence

Très (trop) sensible

Rares faux négatifs (imagerie dynamique)

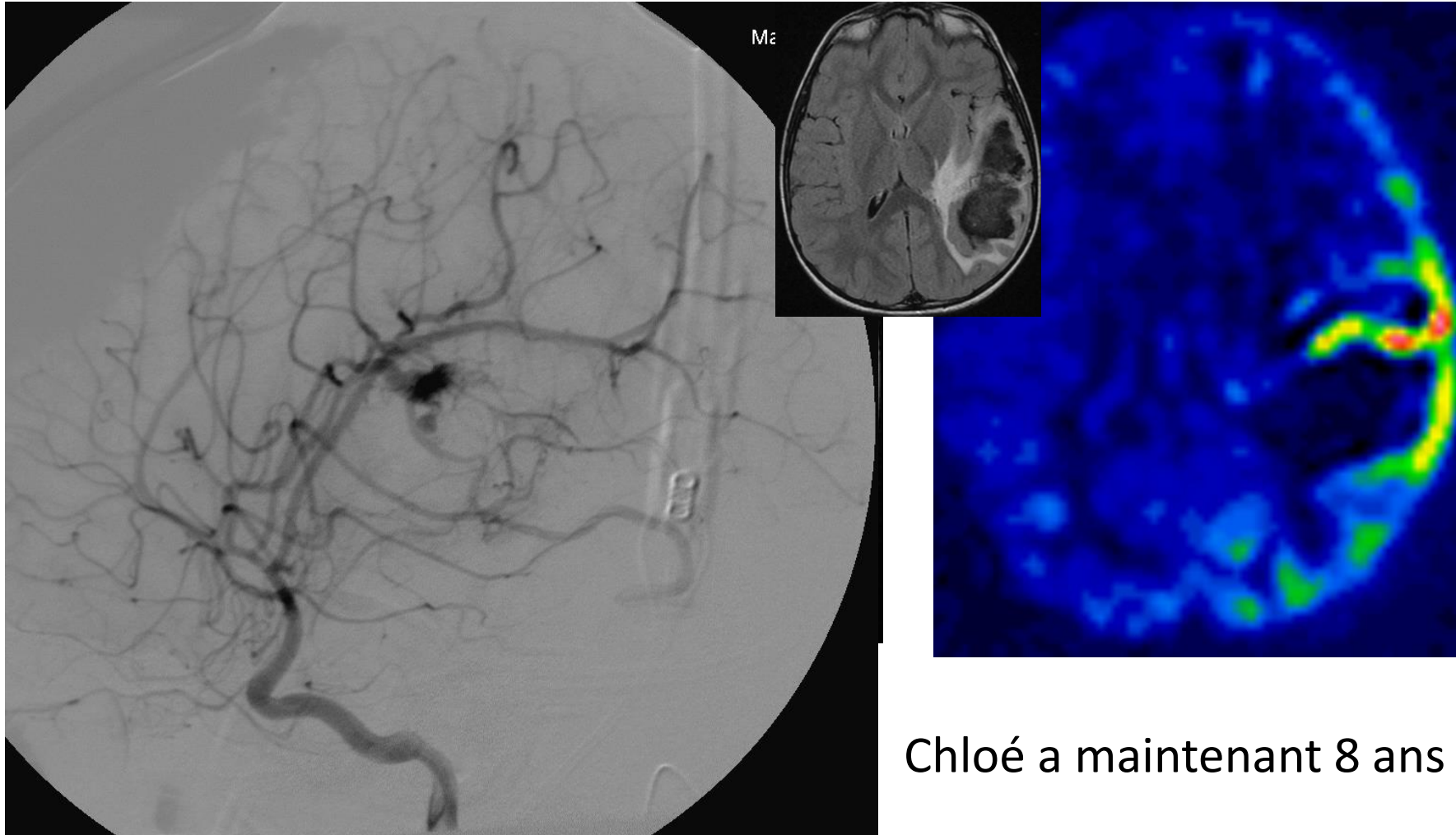
→ Affirmer son absence

Aaron, 3 jours



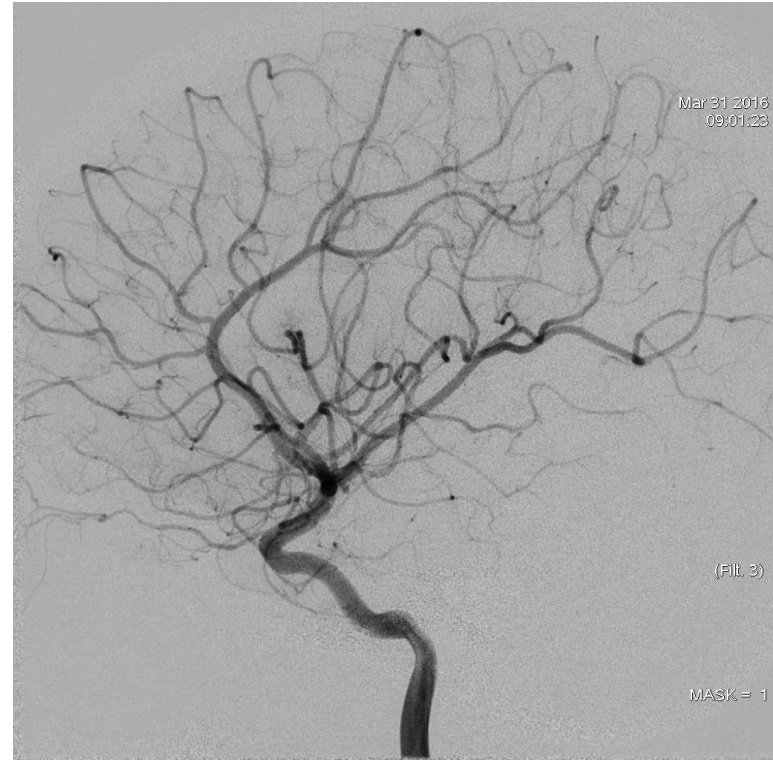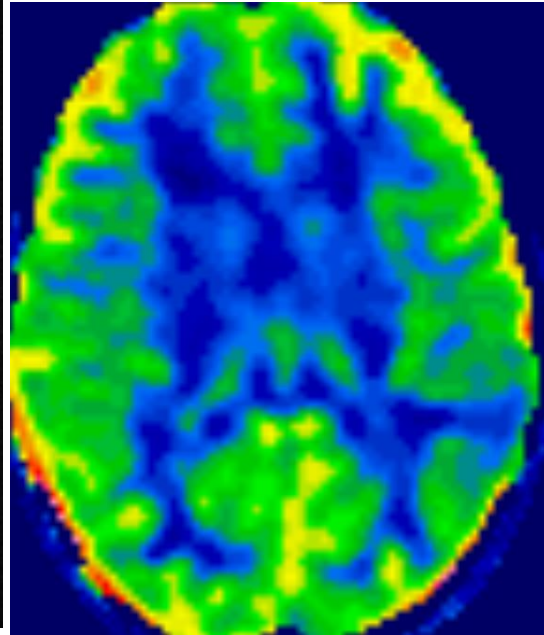
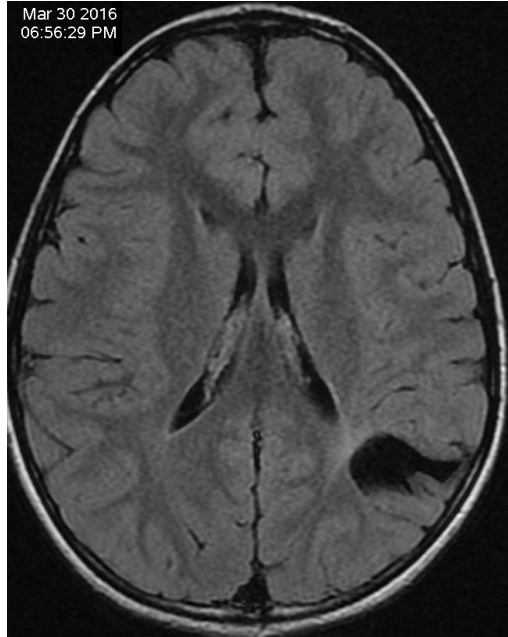
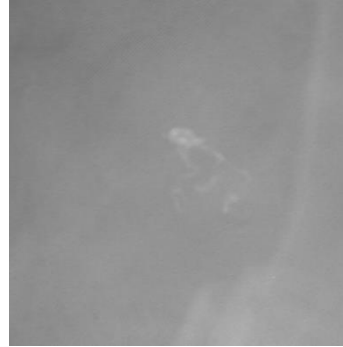
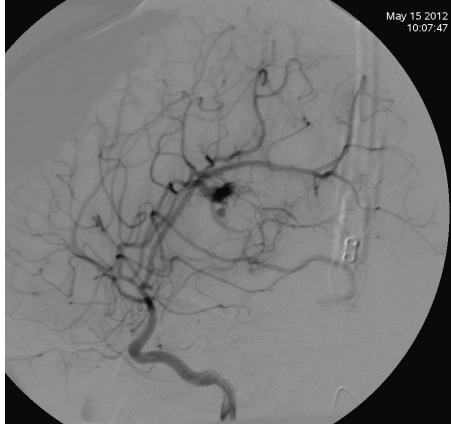
Pas de shunt A-V

Éliminer la présence d'un shunt artériovoineux



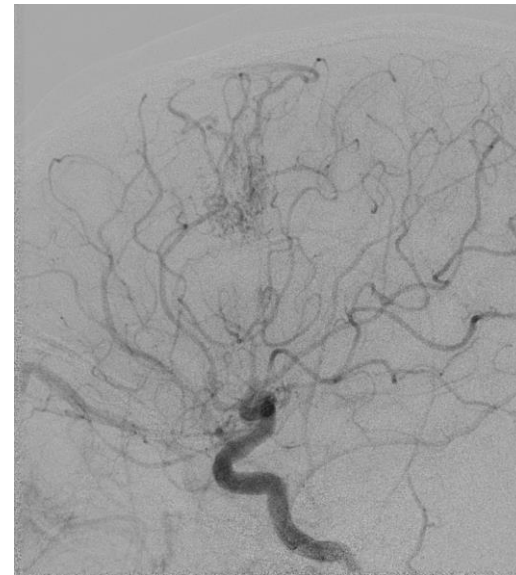
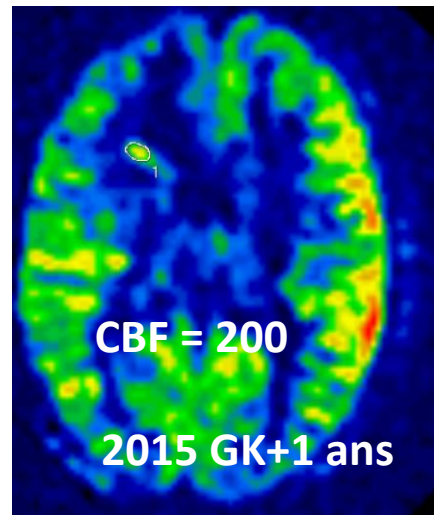
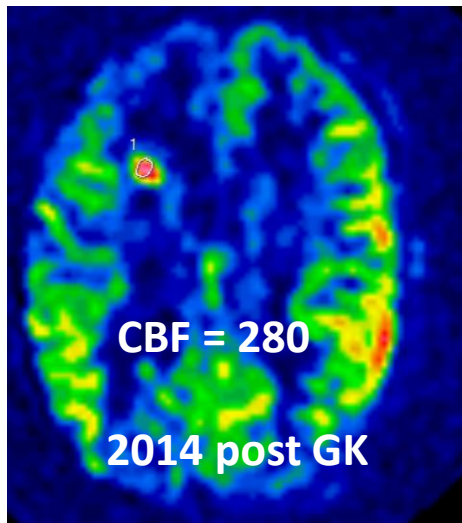
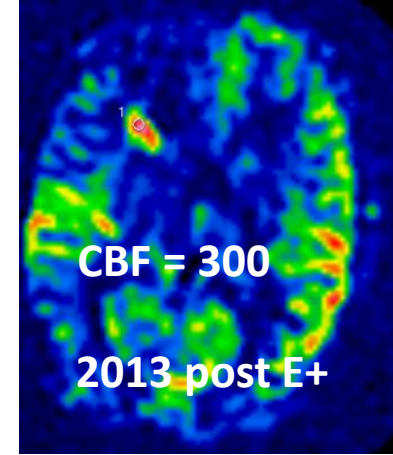
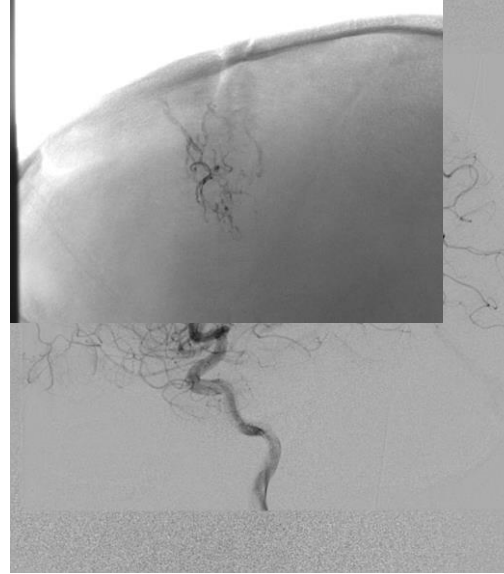
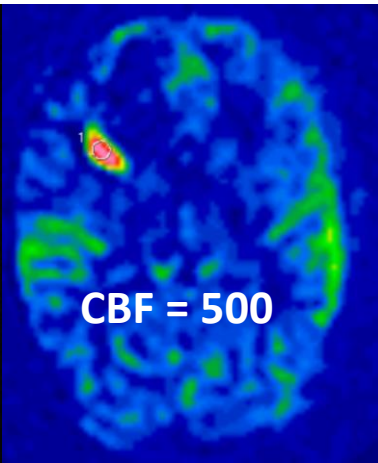
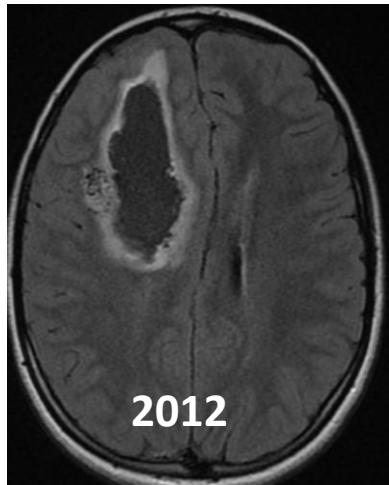
Chloé a maintenant 8 ans

Éliminer un shunt A-V

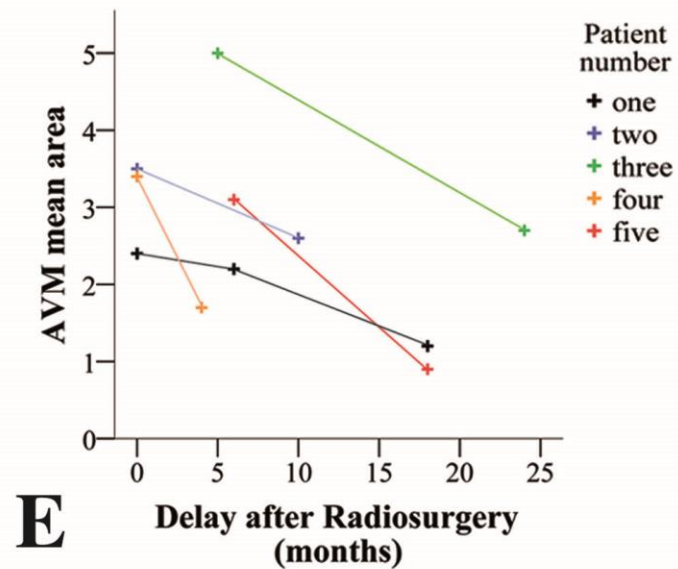
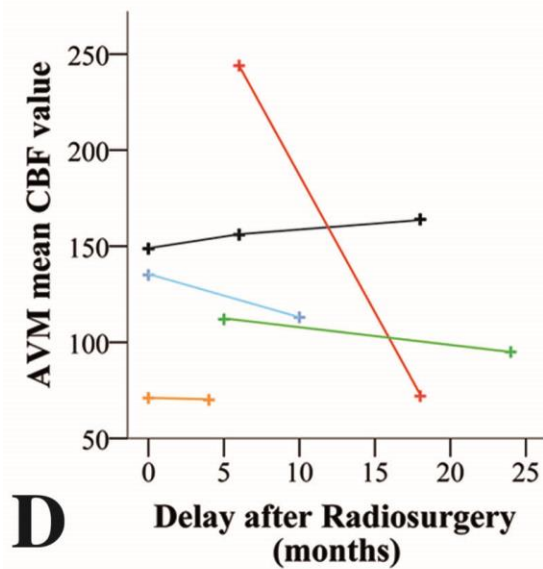
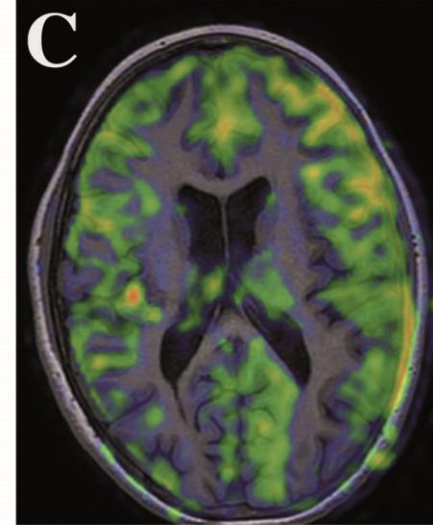
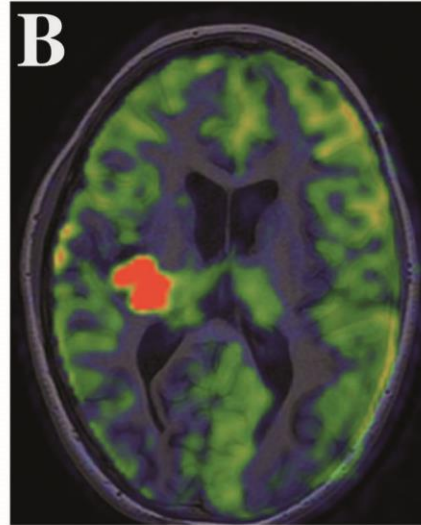
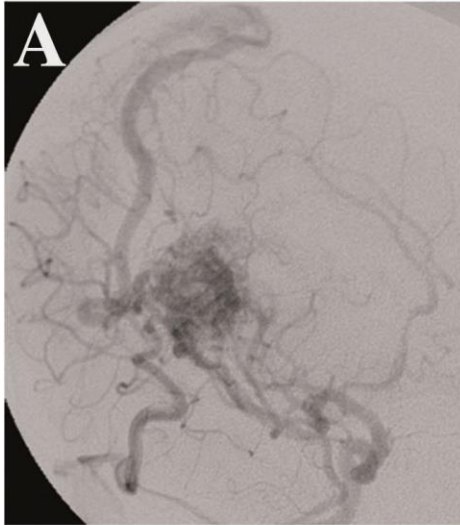


Suivre la disparition progressive
d'un shunt artério-veineux
après irradiation

Suivre la disparition progressive d'un shunt artériovoineux



Suivre la disparition progressive d'un shunt artério-veineux



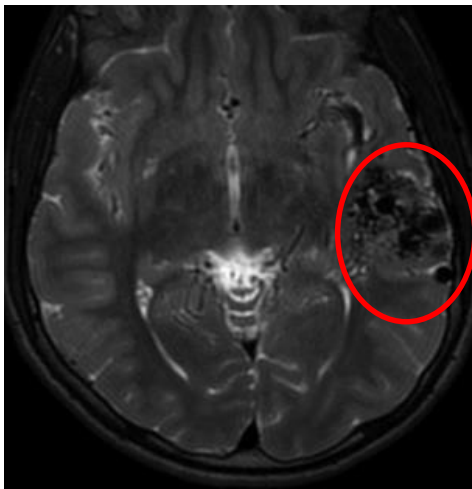
CONCLUSION

ASL pour le **diagnostic positif de shunt A-V**

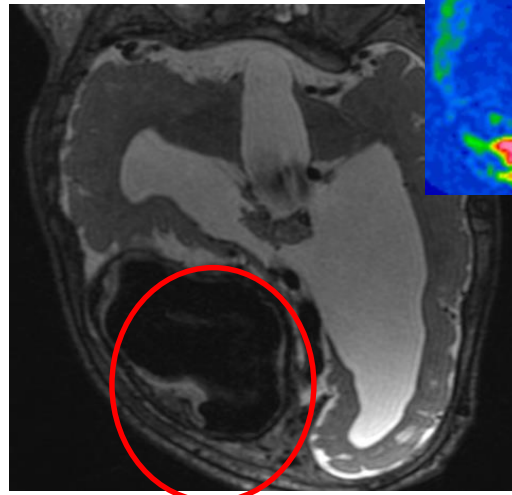
- Non invasif
- Sensible +++
- Spécificité si analyse conjointe des autres séquences

ASL pour le **suiti des MAV**

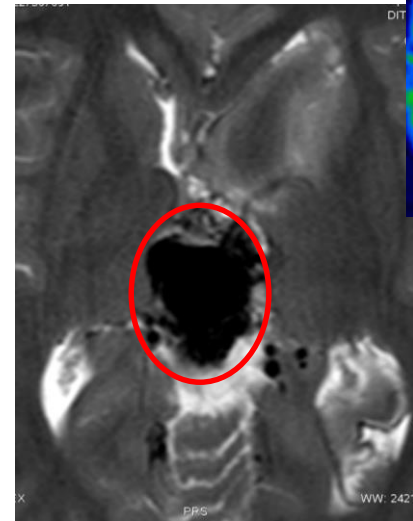
- (semi) Quantification de la perfusion du nidus
- Suivi après Radiochirurgie +++



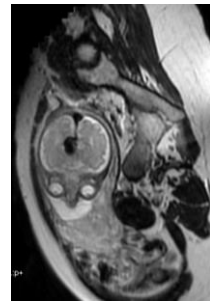
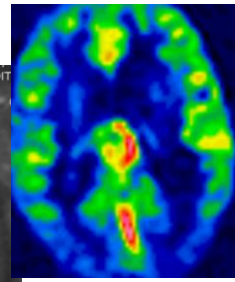
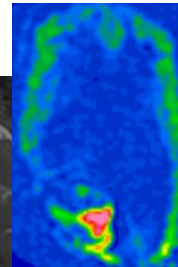
Shunt pial



Shunt dural



Galien



43^{ème} CONGRÈS ANNUEL de la



SFNR
SOCIÉTÉ FRANÇAISE
DE NEURORADIOLOGIE



Du **30 mars** au
1^{er} avril 2016
Novotel Paris Tour Eiffel



IRM de perfusion par marquage de spin artériels : intérêt dans les malformations artério-veineuses cérébrales de l'enfant

O. Naggara, MD, PhD - T. Blauwblomme , MD, PhD - G. Boulouis, MD, MSc –
F. Brunelle, MD, PhD – M. Bourgeois, MD- C. Oppenheim, MD, PhD –
S. Puget, MD, PhD - M. Zerah, MD, PhD - C. Sainte-Rose , MD, PhD –
N. Boddaert, MD, PhD



43^{ème} congrès de la SFNR – Paris

FACULTÉ
DE MÉDECINE
PARIS DESCARTES

