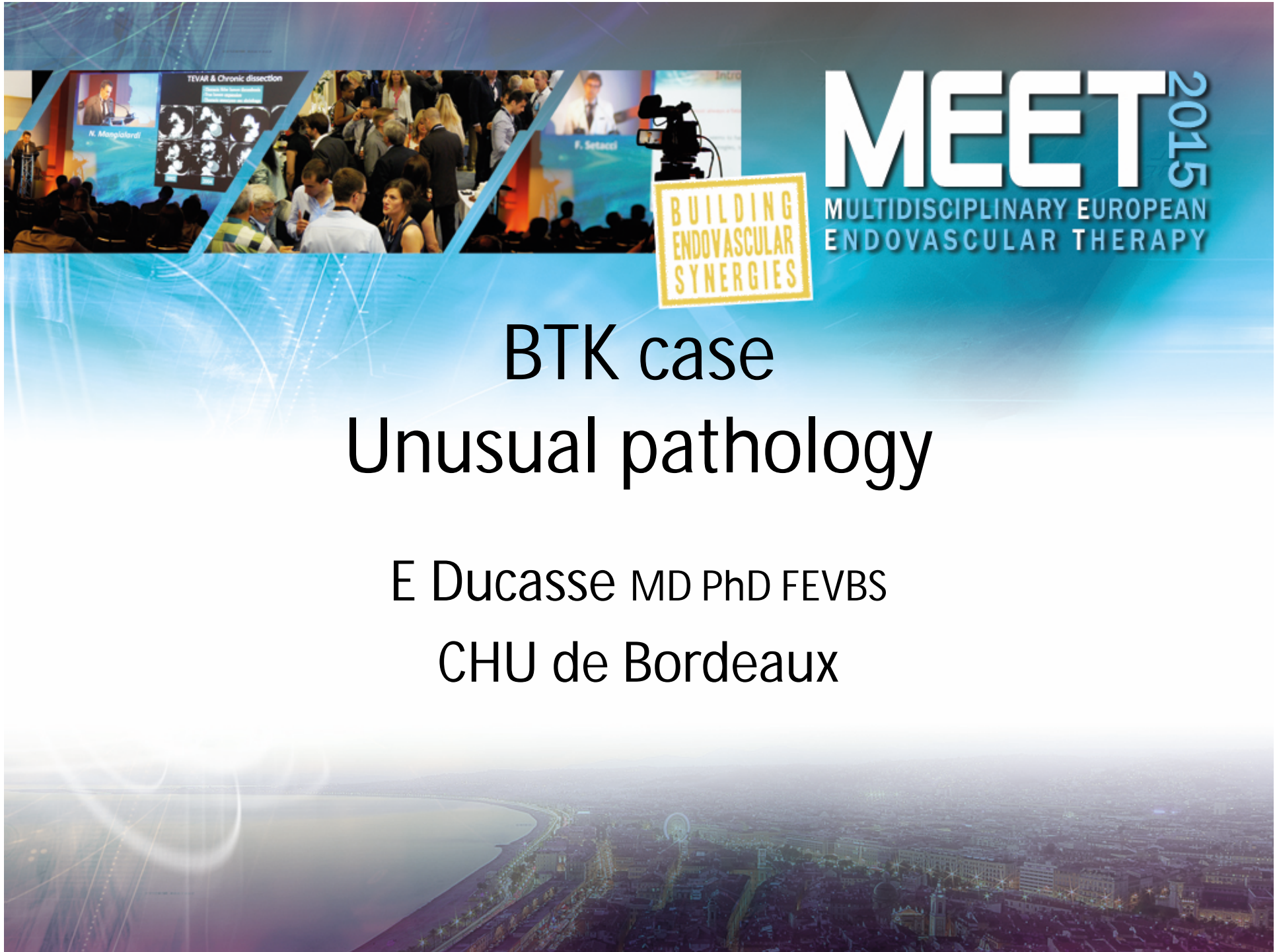



MEET 2015
MULTIDISCIPLINARY EUROPEAN
ENDOVASCULAR THERAPY

BUILDING
ENDOVASCULAR
SYNERGIES

BTK case

Unusual pathology

E Ducasse MD PhD FEVBS
CHU de Bordeaux

Disclosure

Speaker name:

.....

I have the following potential conflicts of interest to report:

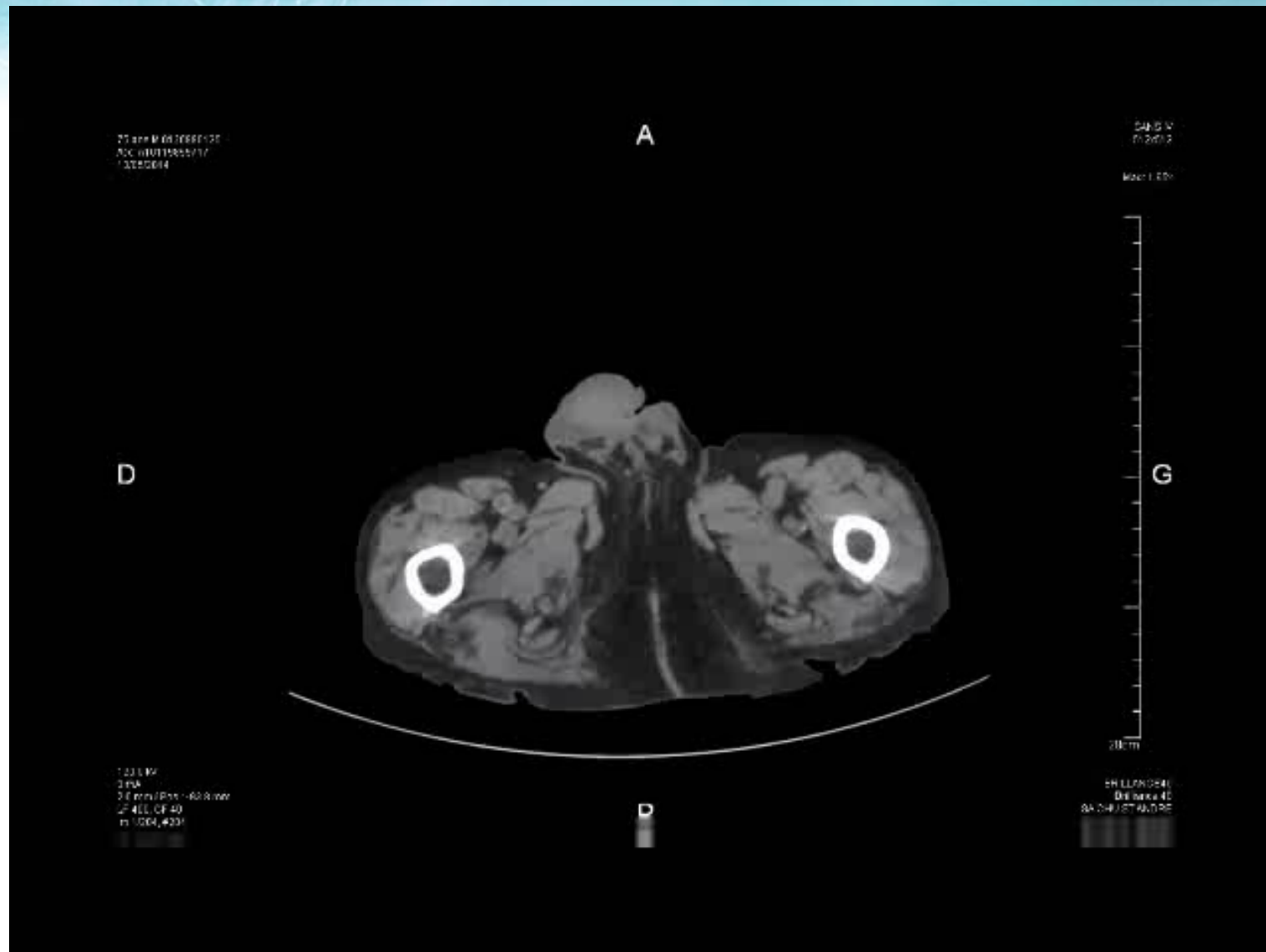- Consulting
- Employment in industry
- Shareholder in a healthcare company
- Owner of a healthcare company
- Other(s)

- I do not have any potential conflict of interest

Clinical case

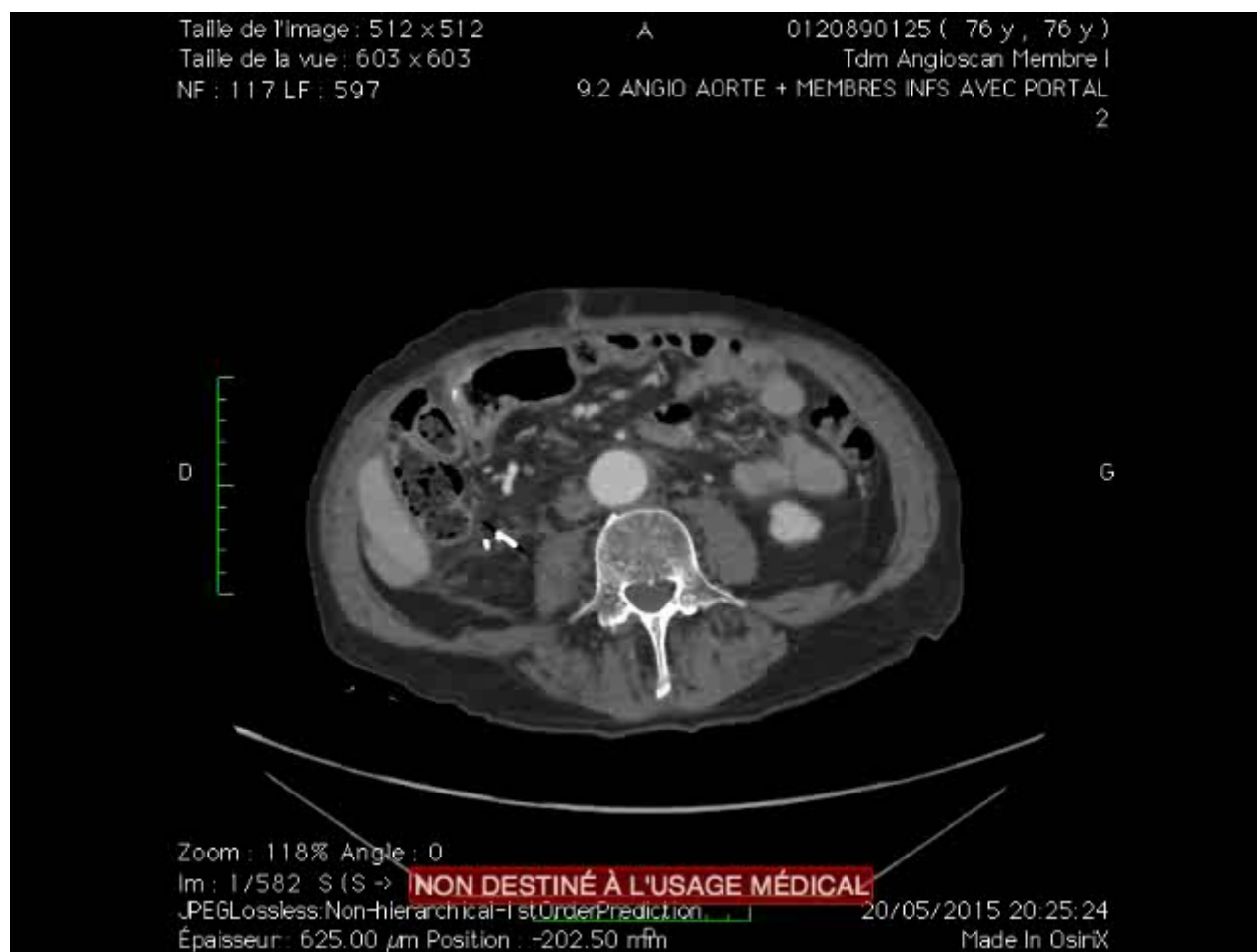- Male 75 Y.
- Sudden abdominal pain
- +/- collapse
- angioCT scan

Clinical case

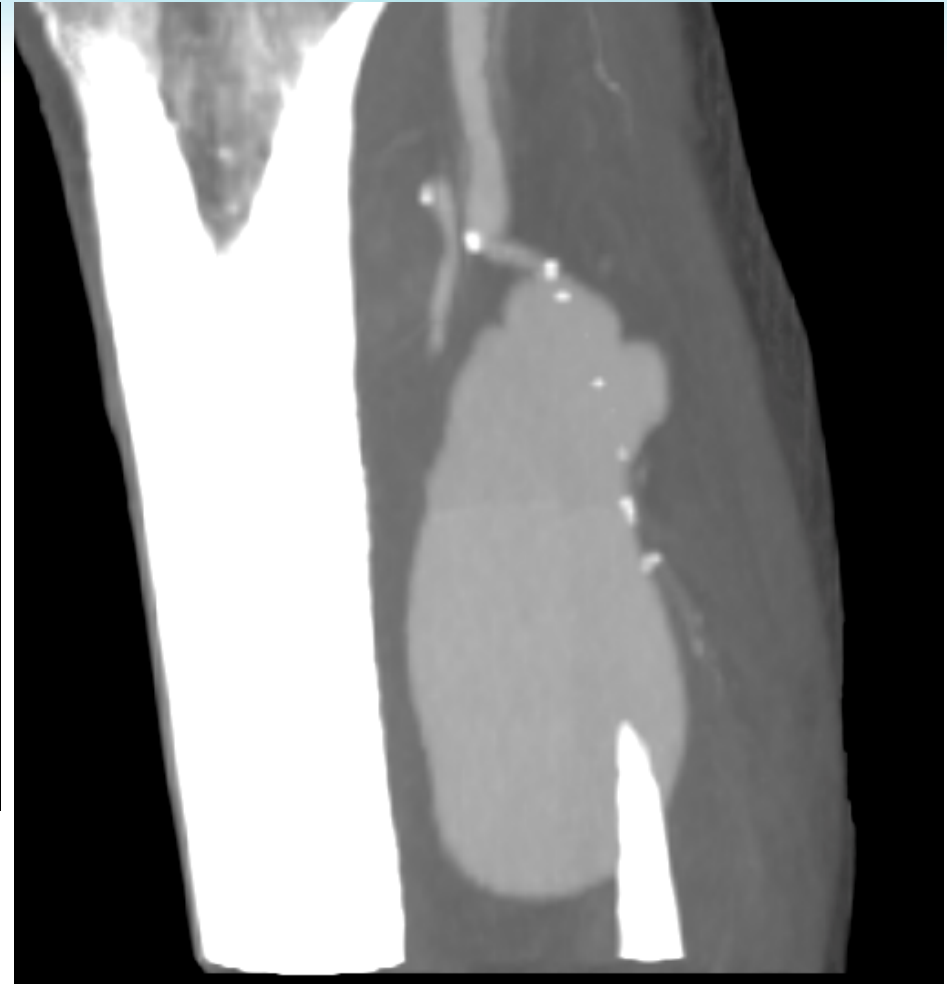
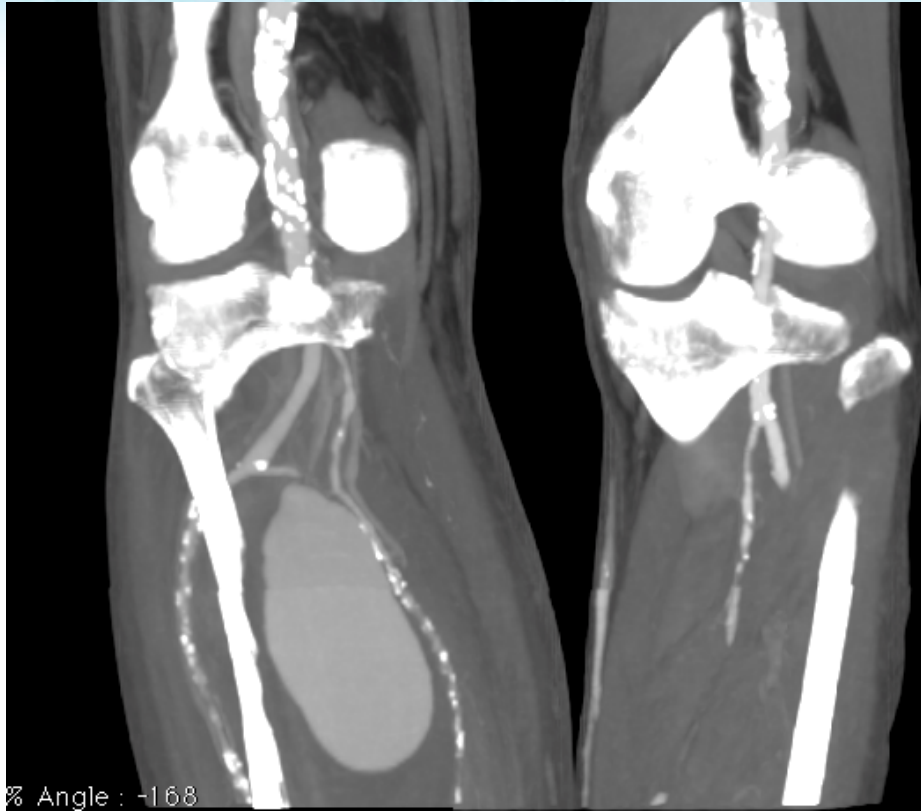
Clinical case

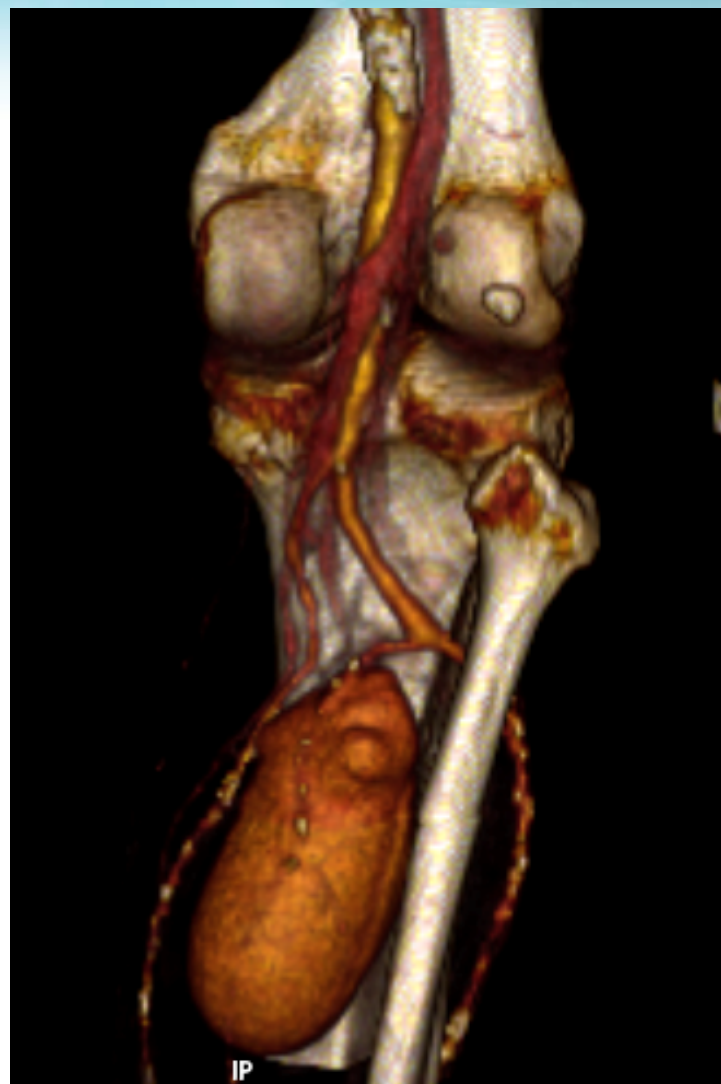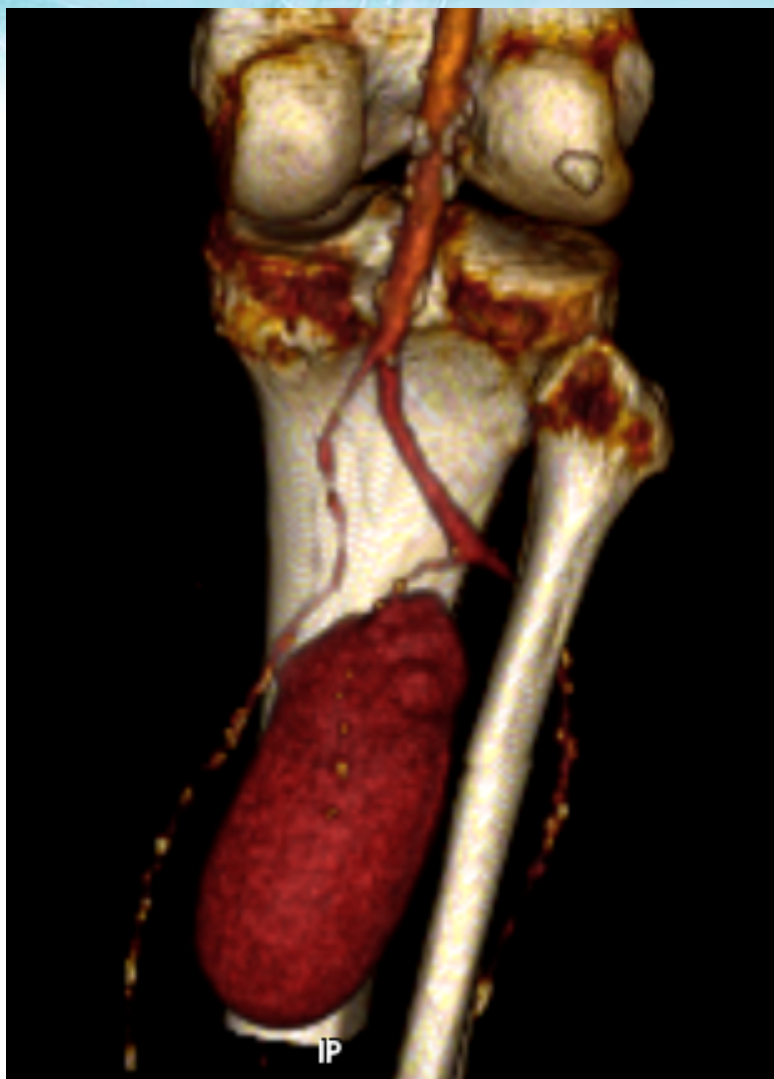- 3 months later...right limb pain




Clinical case




Clinical case




Clinical case




Clinical case




Clinical case




Clinical case




Clinical case




Clinical case




Clinical case




Clinical case




Clinical case




Clinical case




Clinical case




Clinical case



Clinical case



Clinical case



Clinical case

