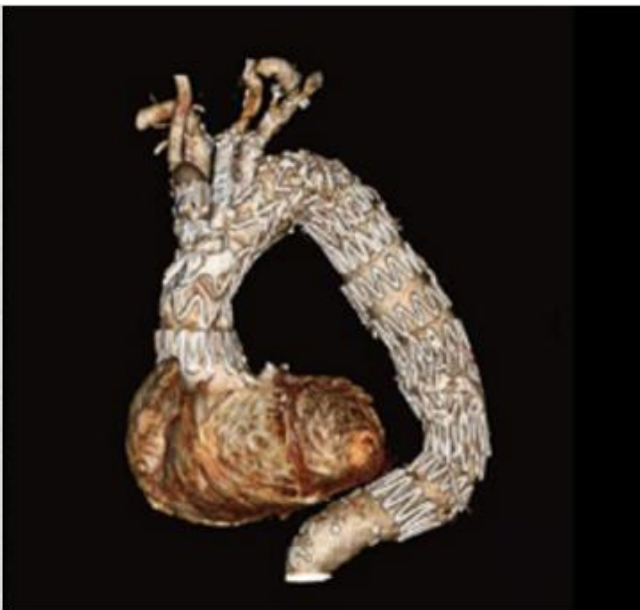



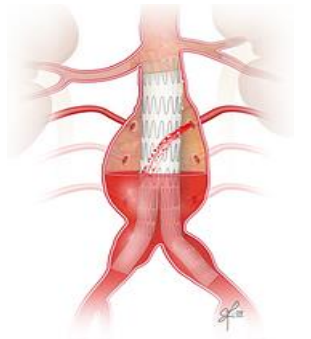
20TH INTERNATIONAL EXPERTS SYMPOSIUM
CRITICAL ISSUES
in aortic endografting **2016**
May **20 & 21** - LILLE - FRANCE



When a stab in the back works: translumbal type 2 endoleak embolization

A. Hertault, T. Martin-Gonzalez, R. Spear, R. Clough, R. Azzaoui, J. Sobocinski, S. Haulon

Type II Endoleak



Incidence 10-50% (1y)

Parent, J Vasc Surg, 2002

Growth > 5 mm

Indication for treatment

Gelfand, Ann Vasc Surg, 2006

Growing aneurysm with type II

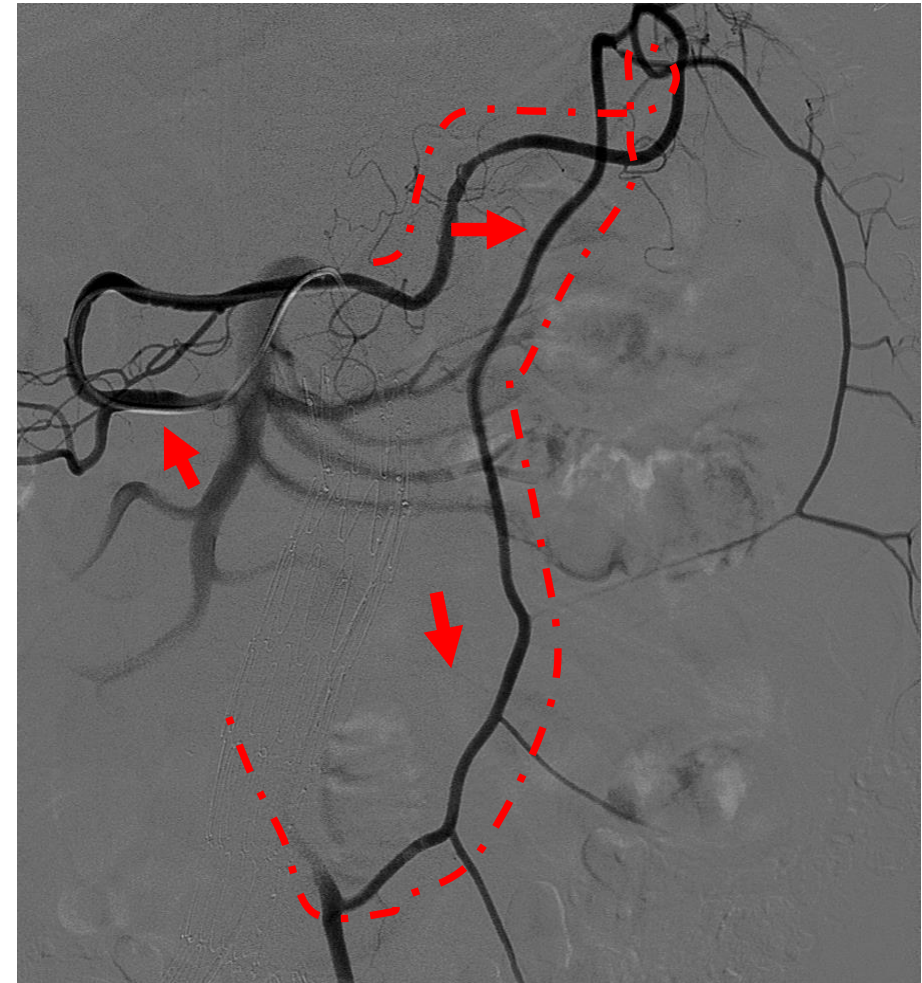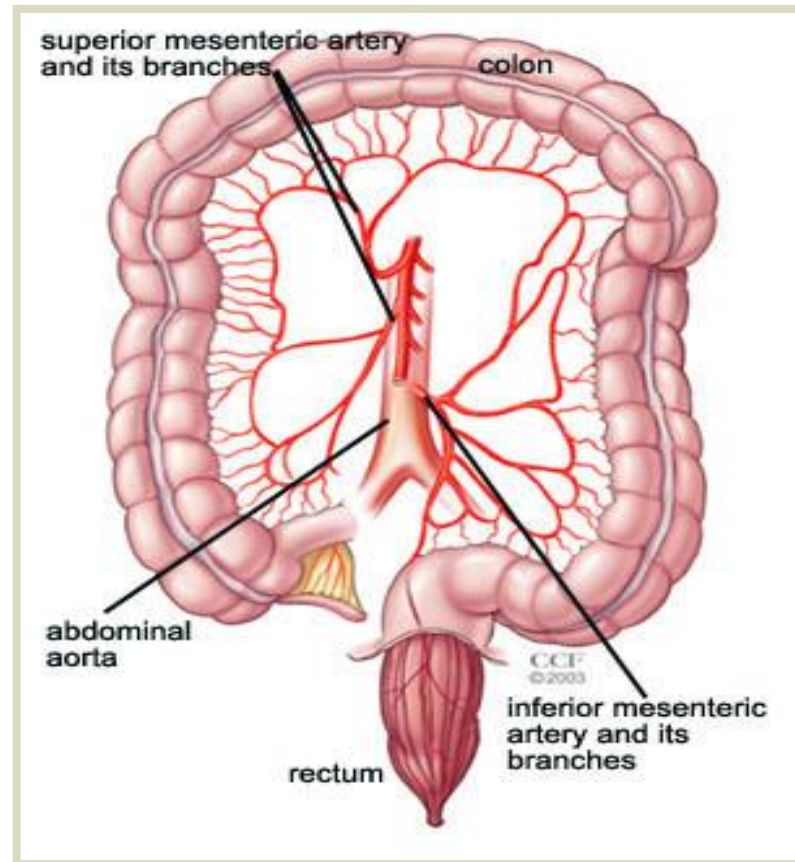
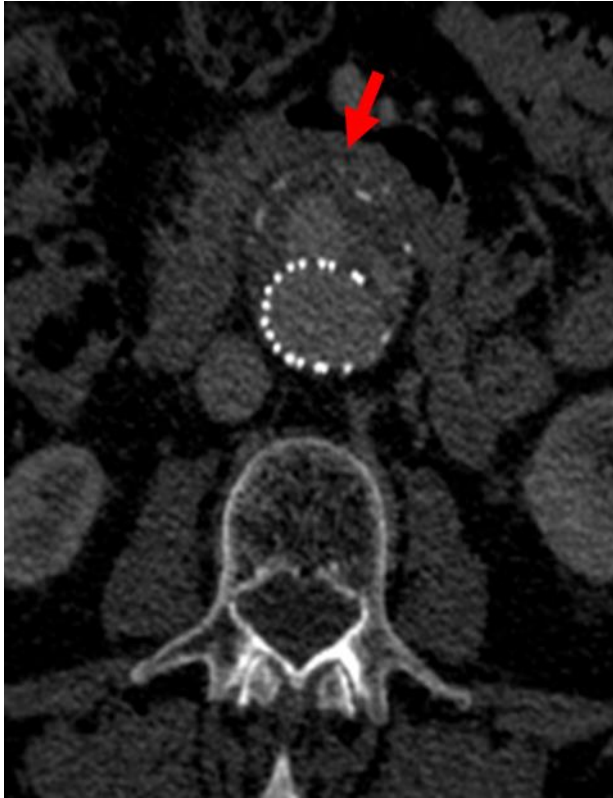Rule out Type I or III

Transarterial

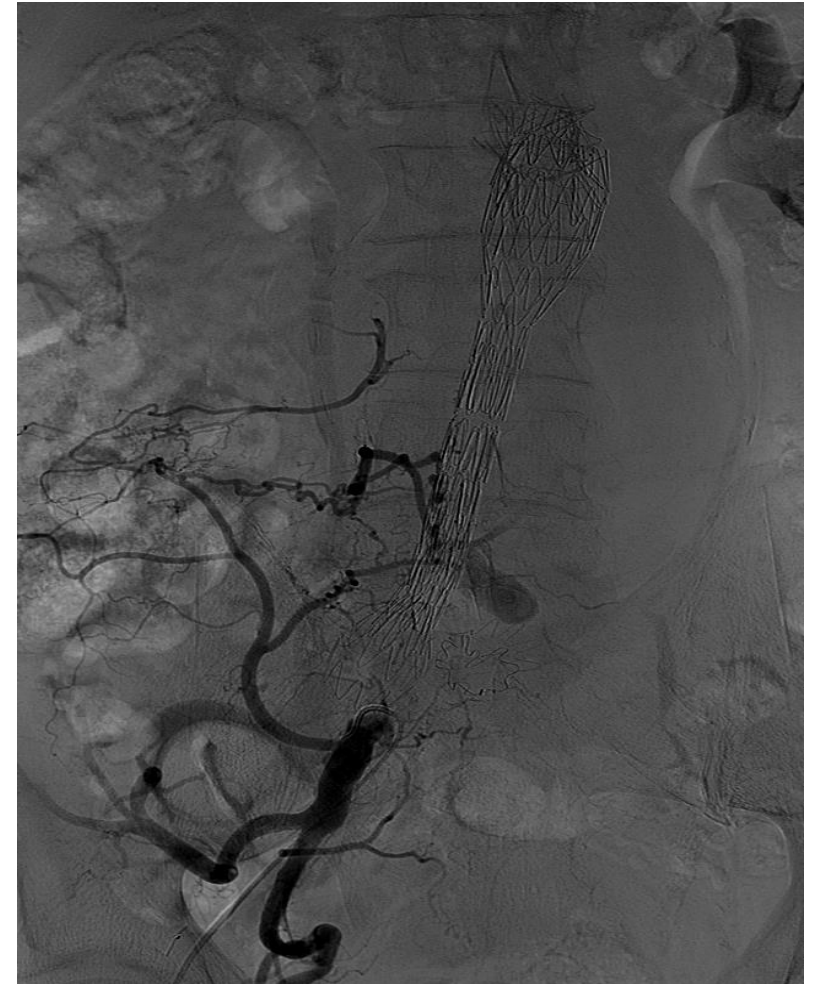
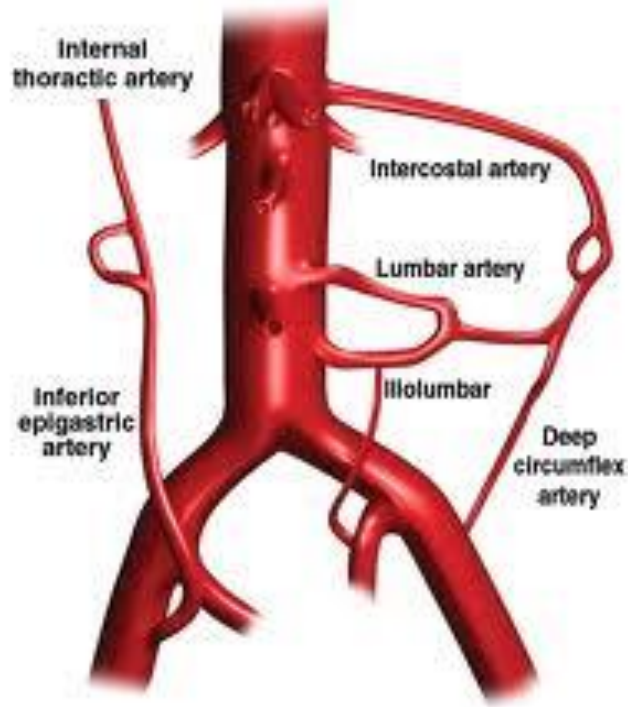
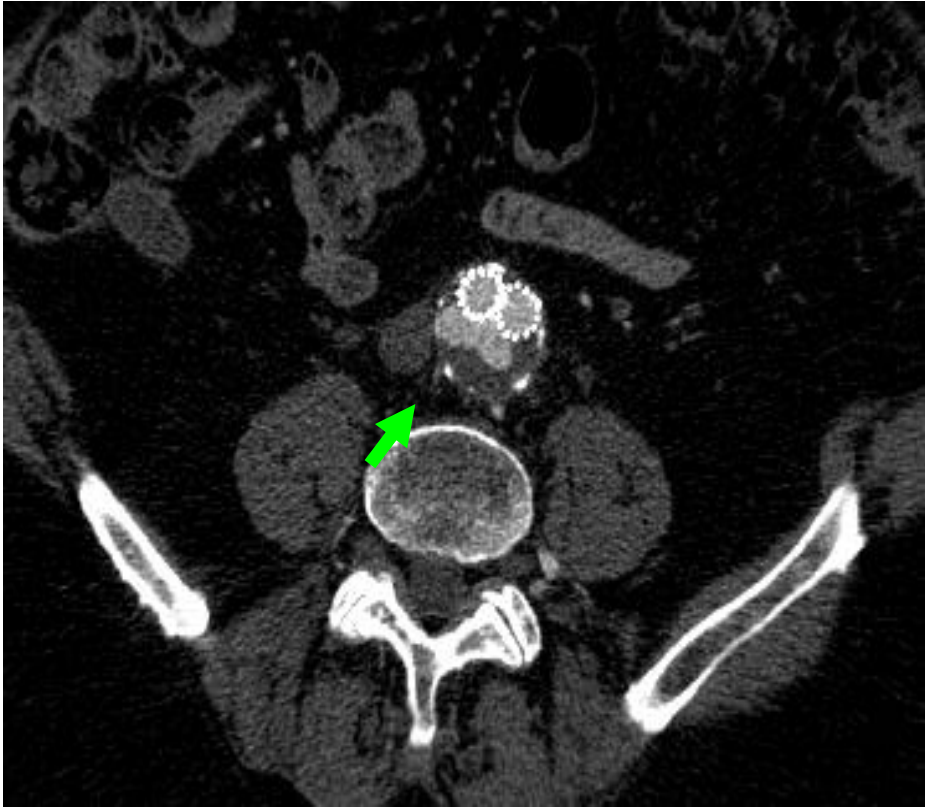Translumbar

Open

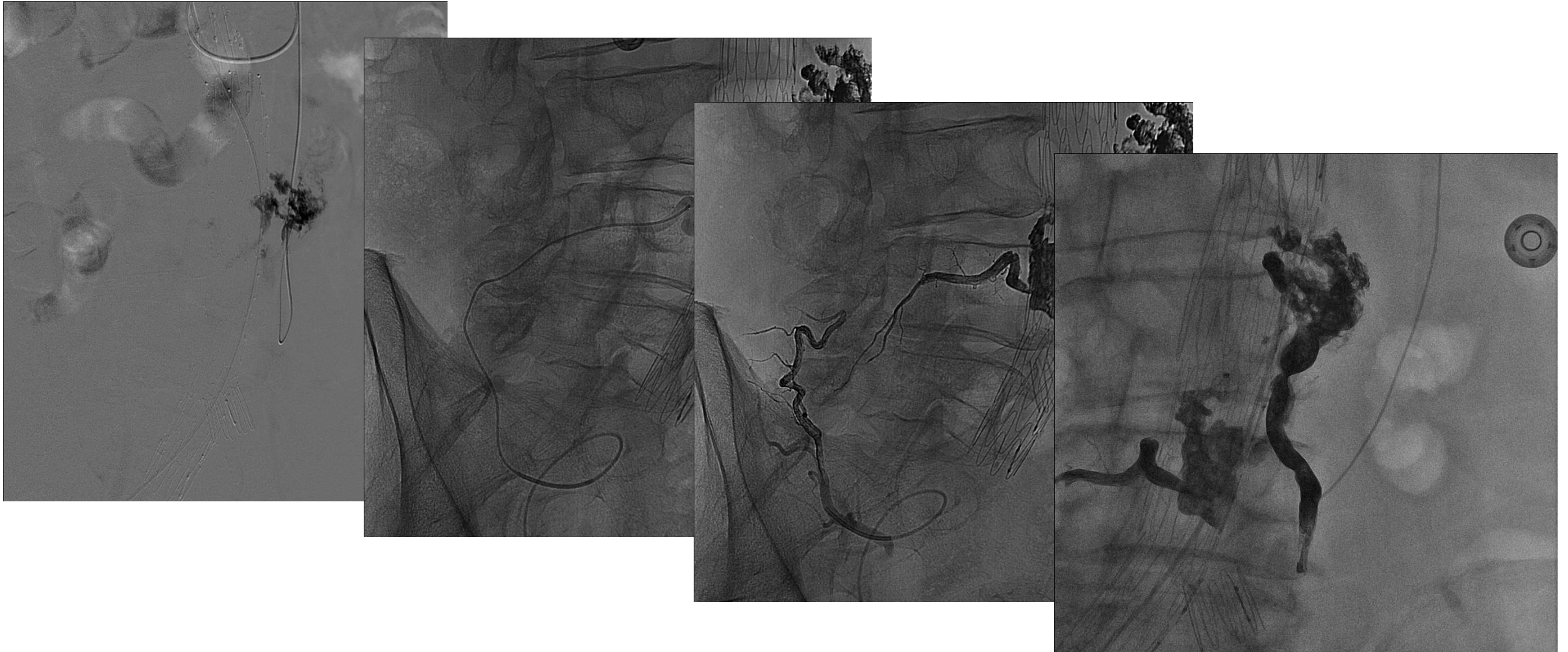
Type II Endoleak (IMA)



Type II Endoleak (Lumbar)



Transarterial Embolization



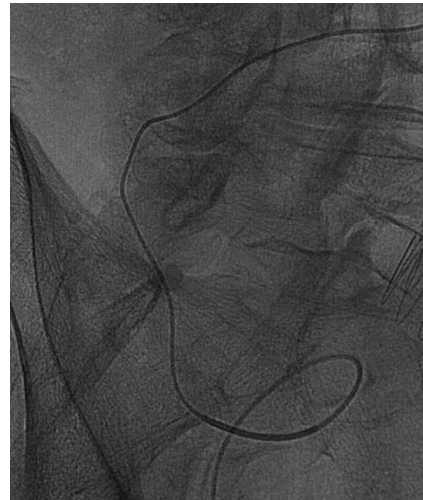
Transarterial Embolization

Challenging Procedures

**Difficulties to identify
In & Out Flow**

**Complex IIA
Catheterization**

Time/Dose-consuming



Alternatives

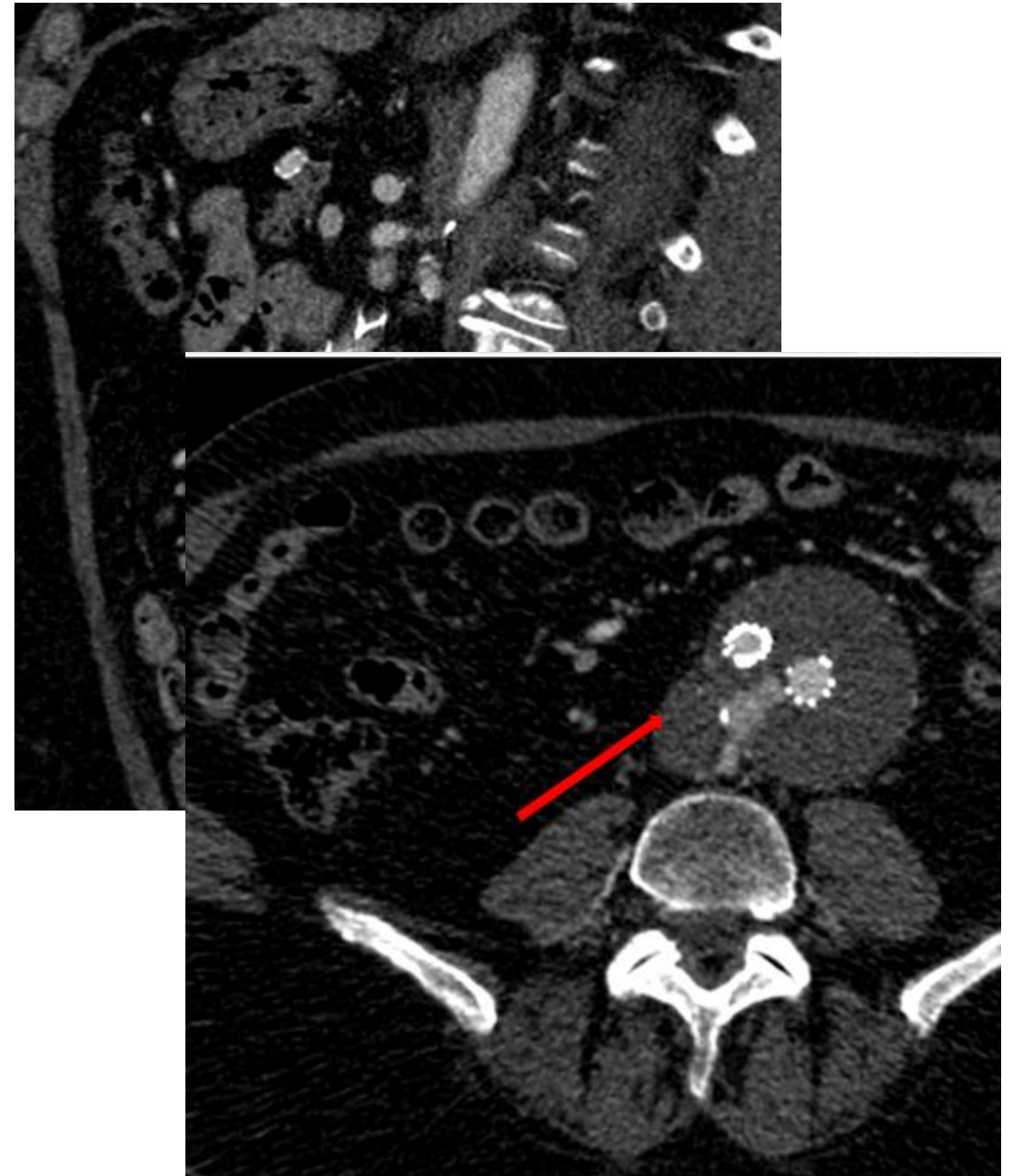
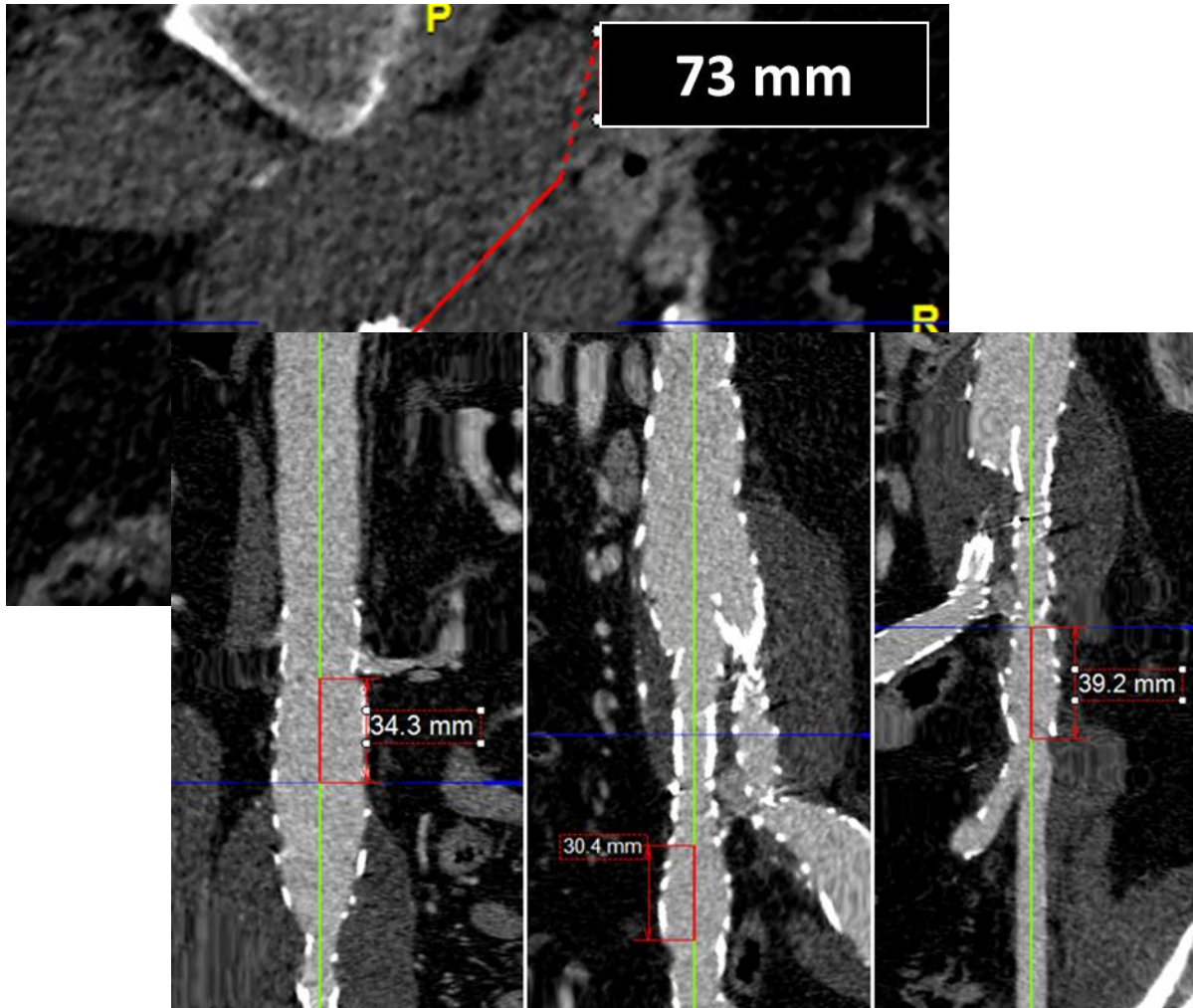
Transcaval embolization

Transsealing embolization

Translumbar embolization

New Workflow with CBCT

About a Case (#1)



Installation & CBCT

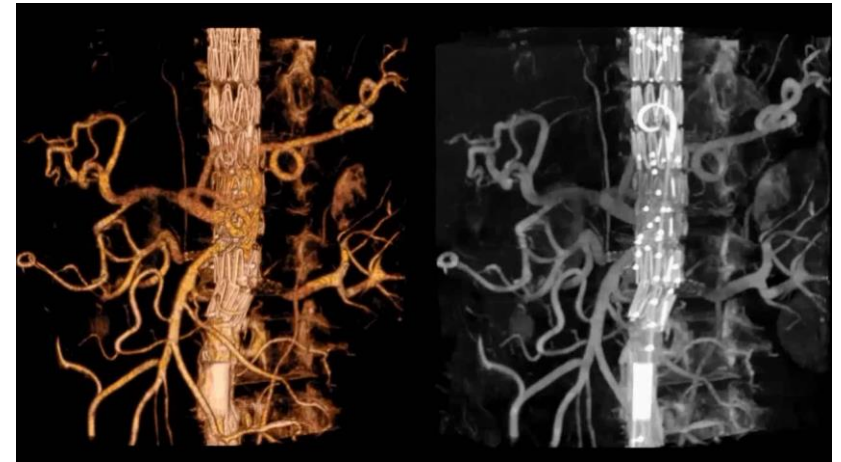
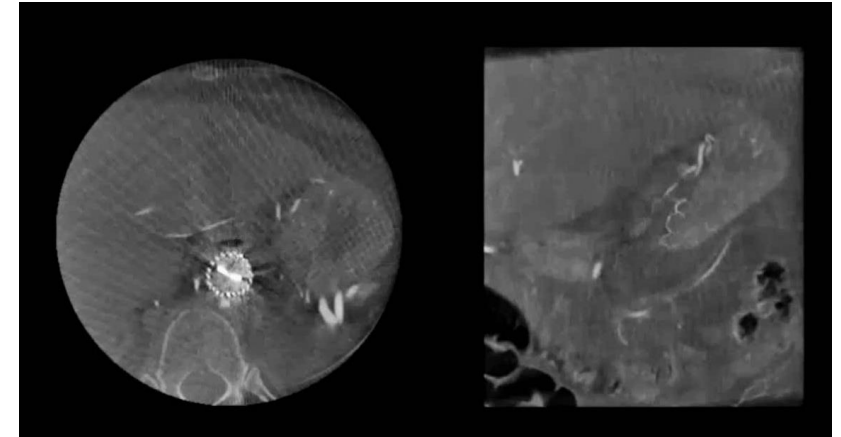
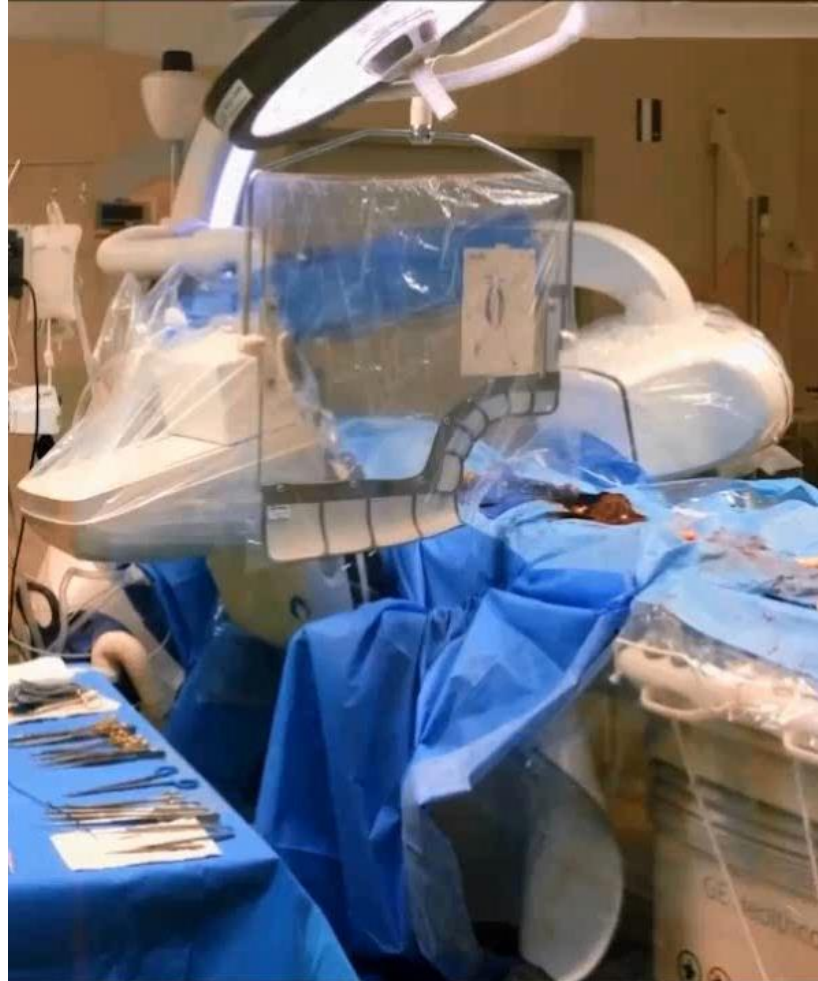Under GA



200° spin

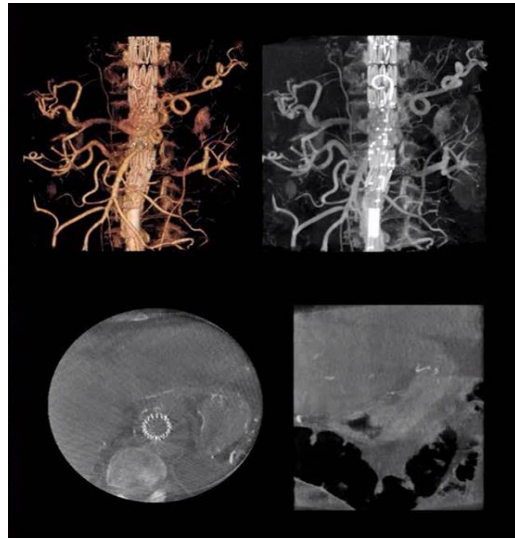40°/sec

150 images

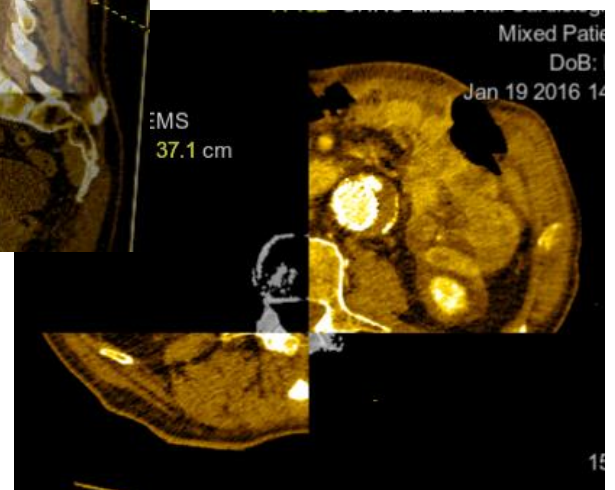
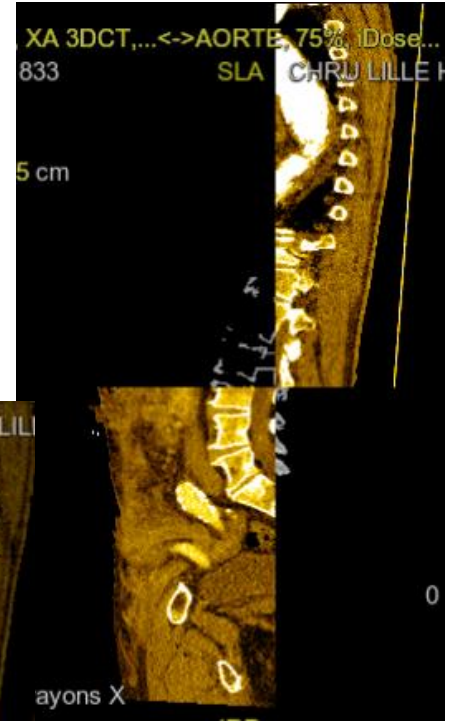
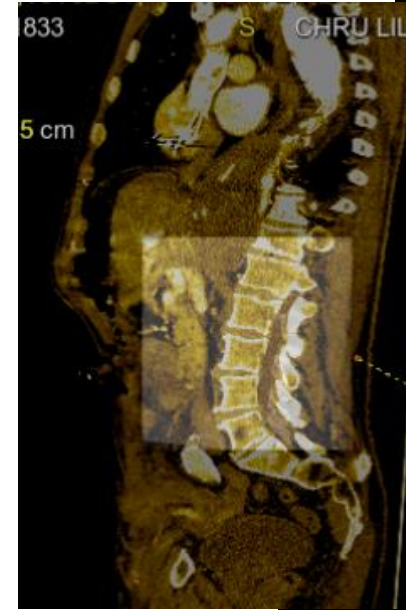
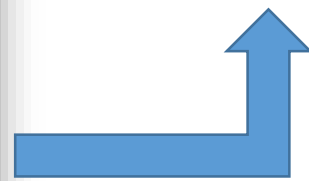
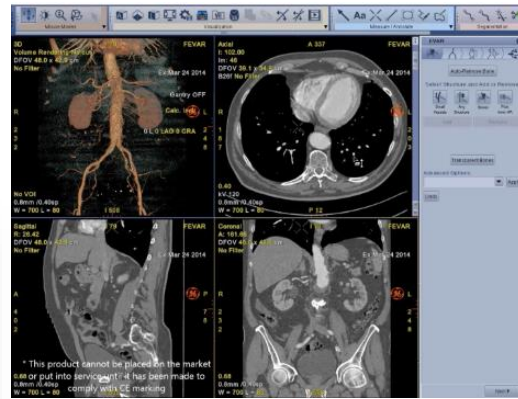
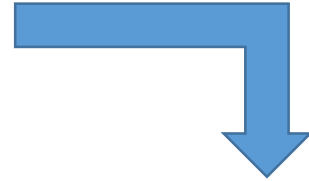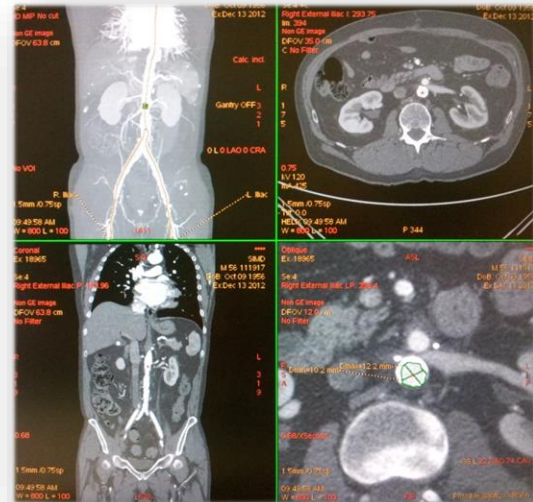


CBCT/CTA Registration

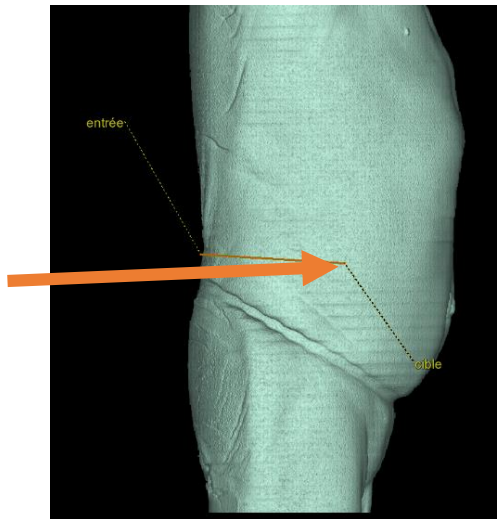
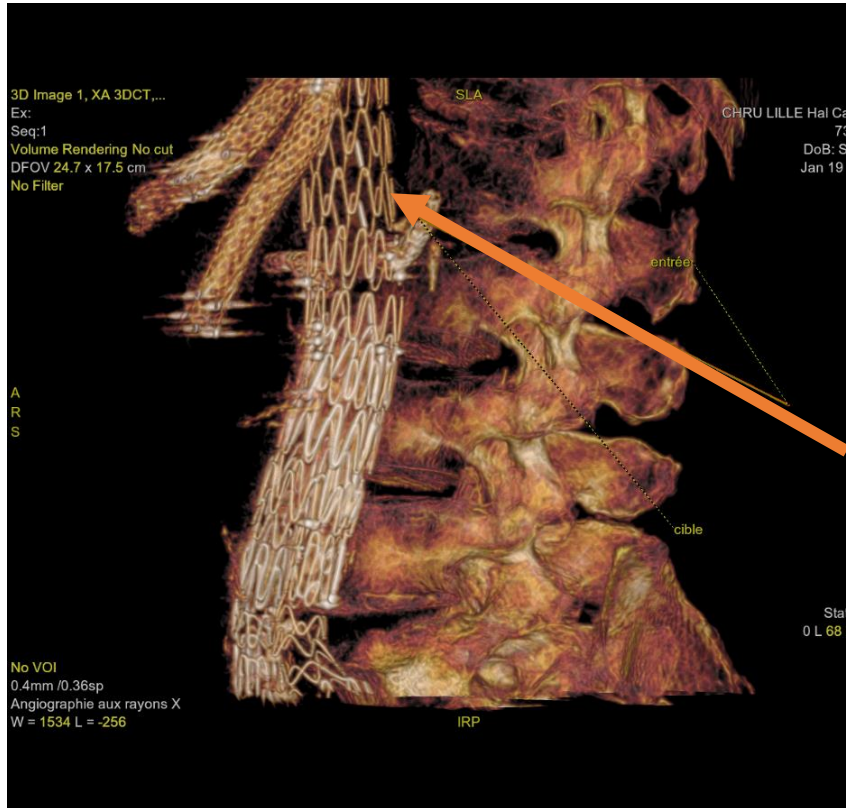
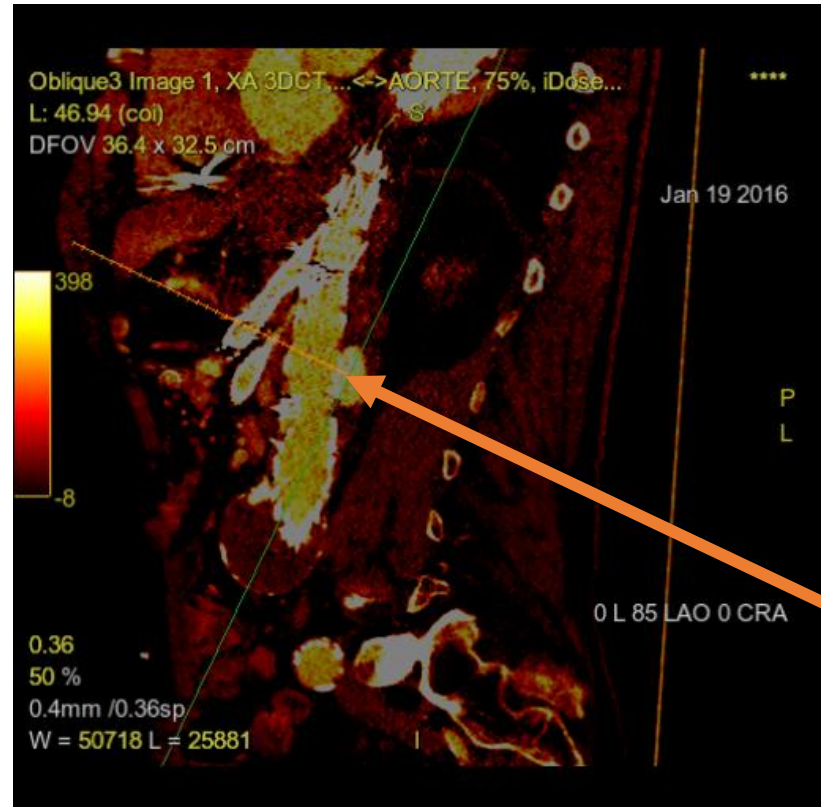
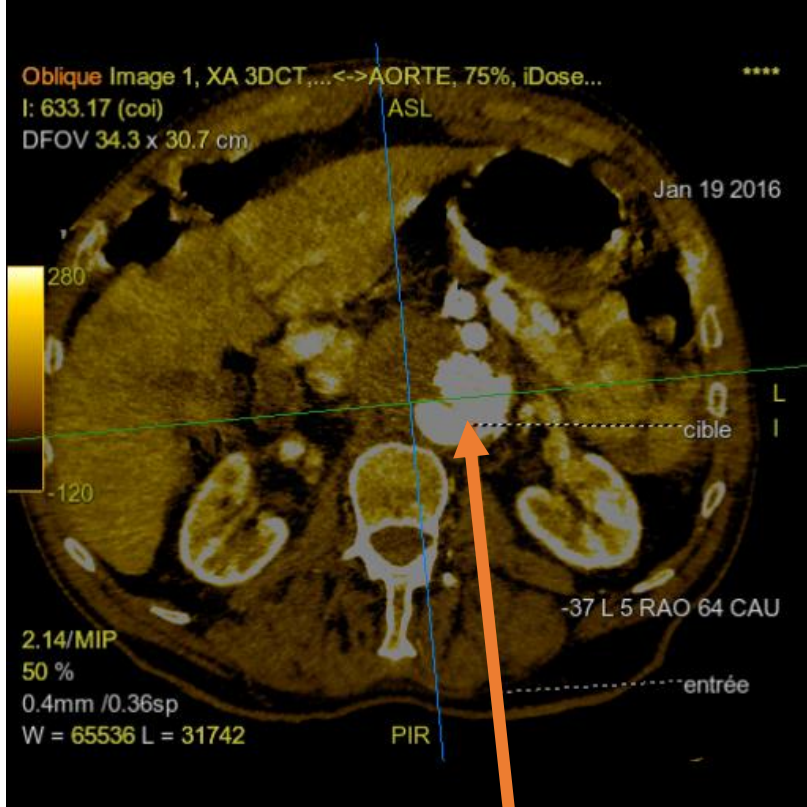PEROP CBCT



PREOP CTA

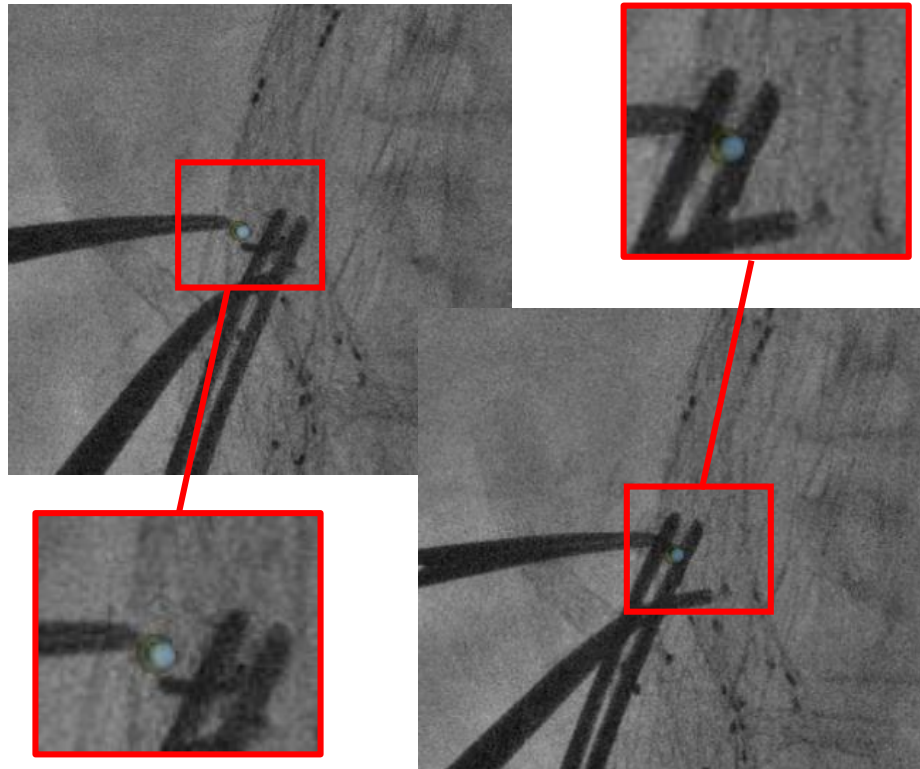


Needle Trajectory Planning

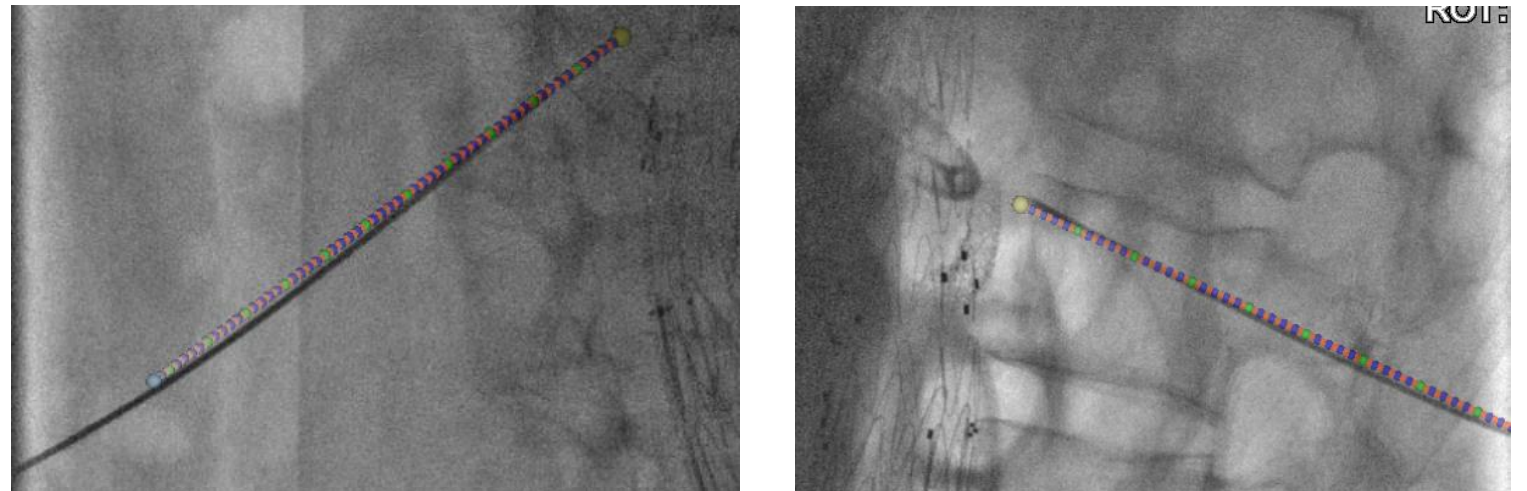


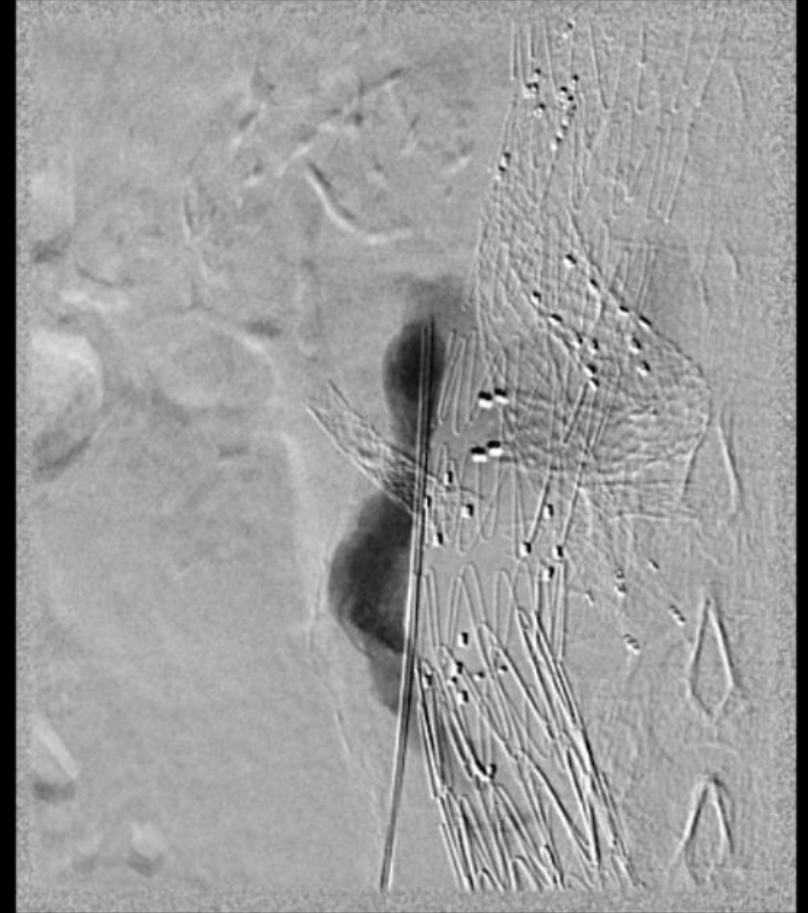
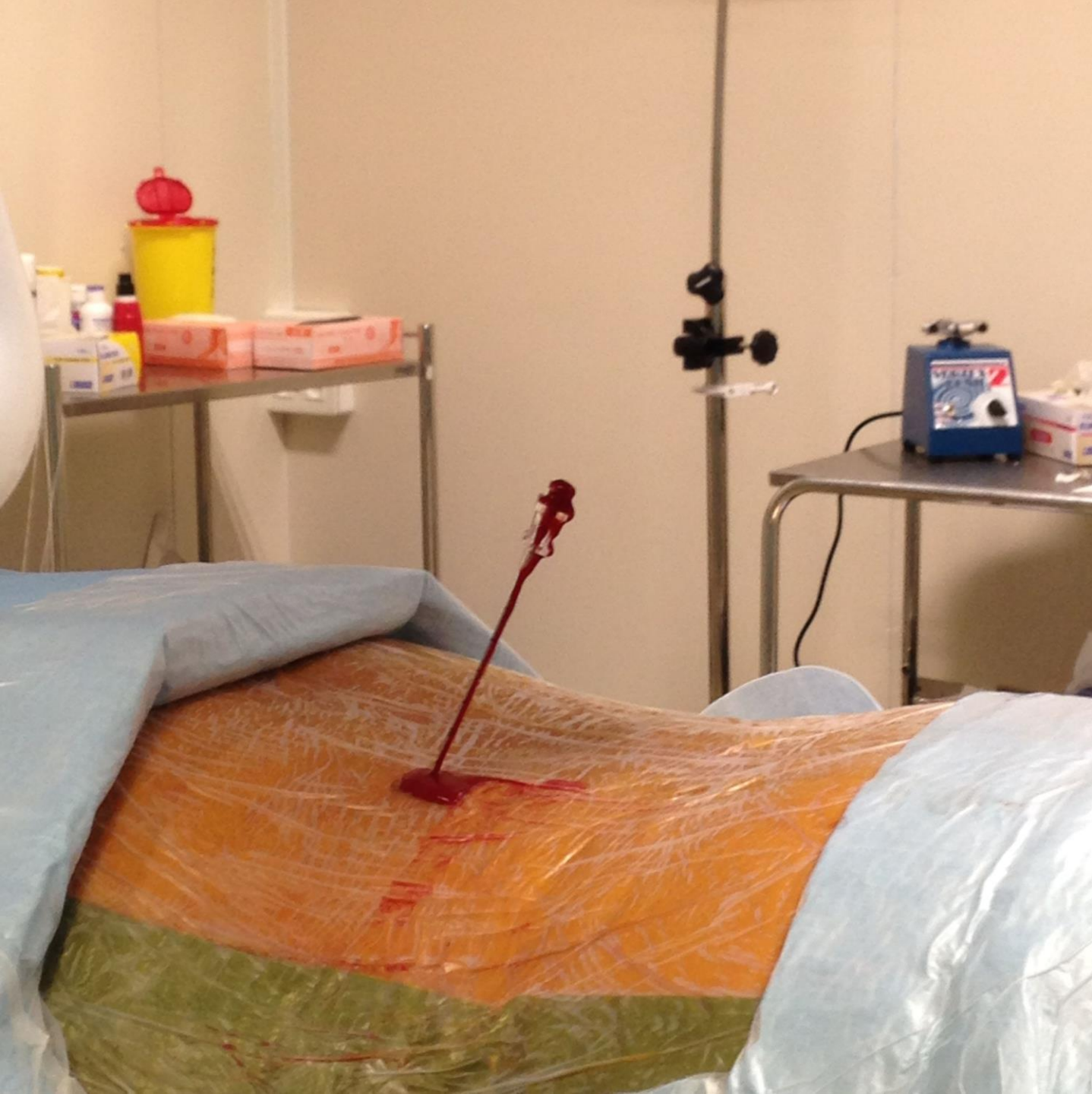
Fusion-guided Puncture & Progression

Bull-eye View



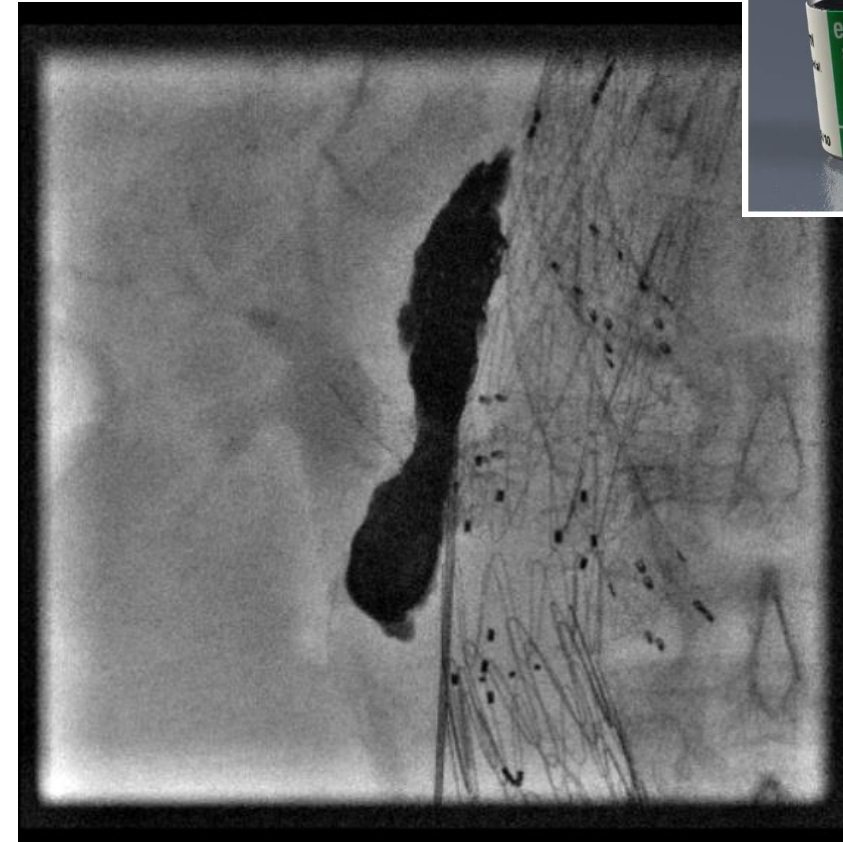
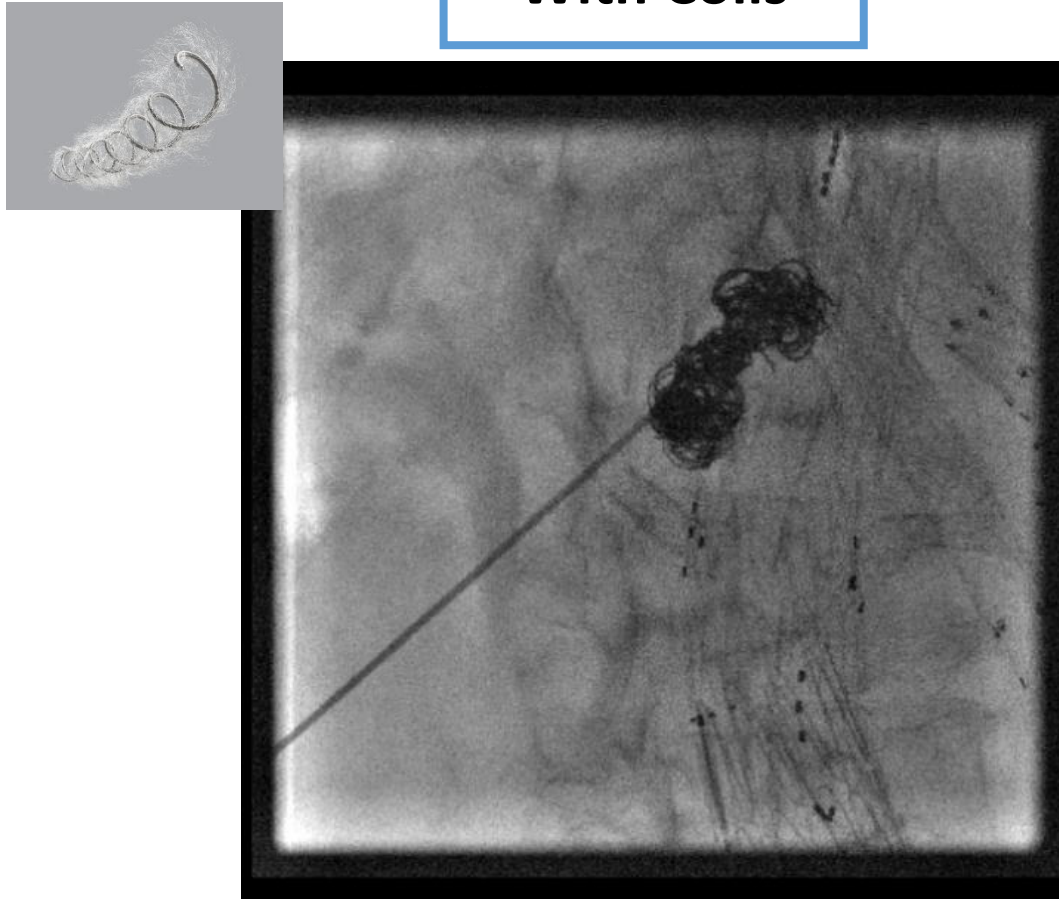
Progression View



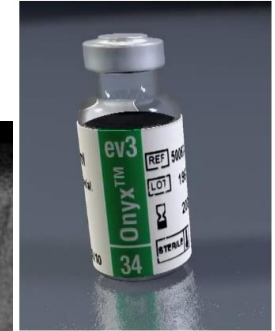

Embolization

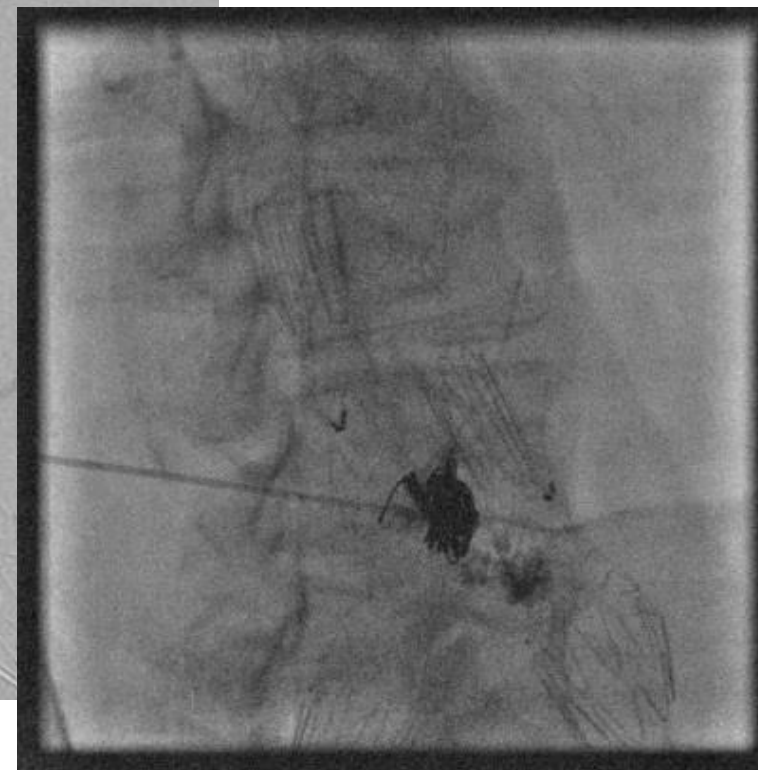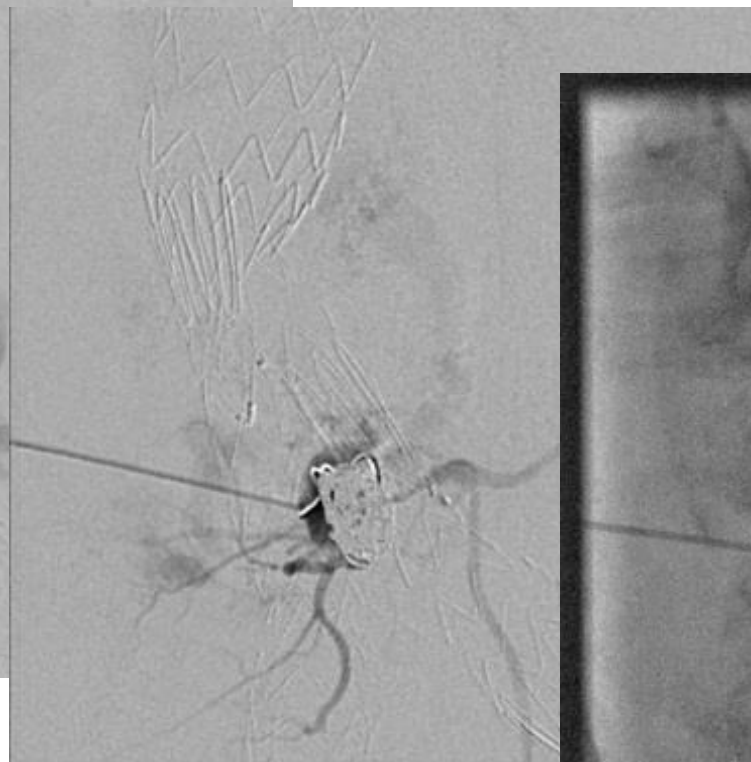
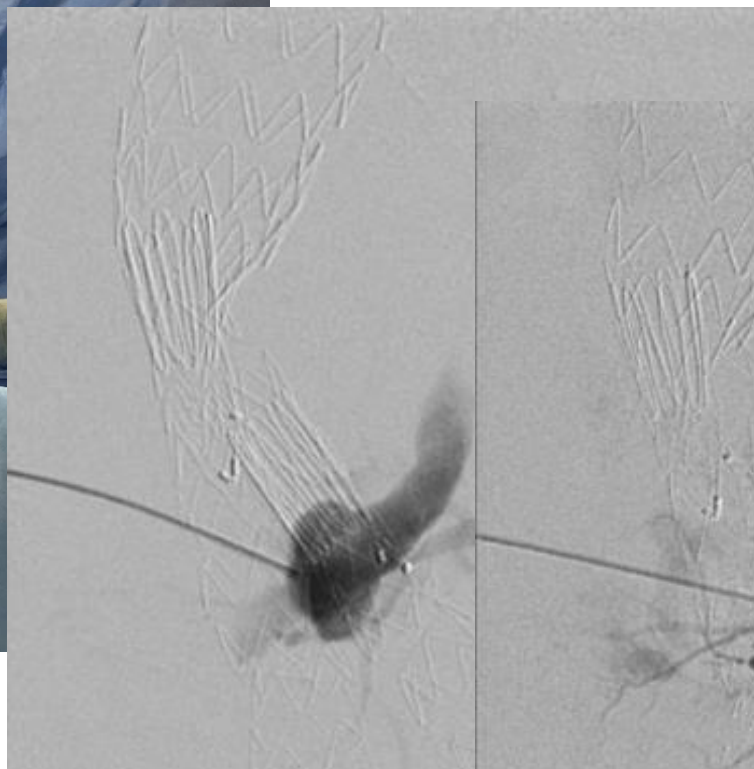
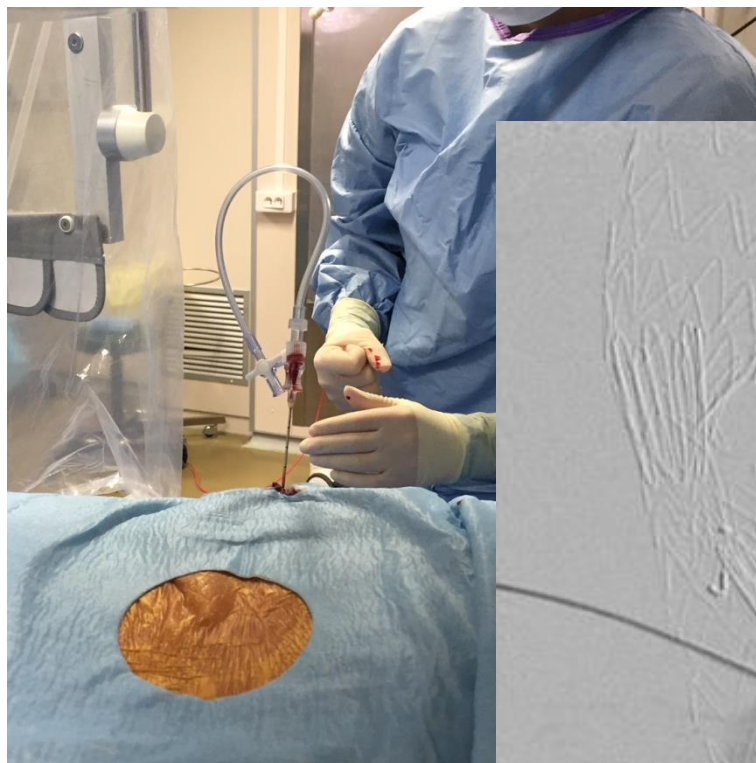
With Coils



**With ethylene–vinyl alcohol
copolymer**



Case #2



Literature

8 patients

Success rate

8/8

Proc. Time

45 min

Contrast

<20mL

Lille

3 patients

Similar results

Cardiovasc Intervent Radiol (2016) 39:447–452
DOI 10.1007/s00270-015-1217-x



TECHNICAL NOTE

Unenhanced Cone Beam Computed Tomography and Fusion Imaging in Direct Percutaneous Sac Injection for Treatment of Type II Endoleak: Technical Note

Gianpaolo Carrafiello¹ · Anna Maria Ierardi¹ · Alessandro Radaelli² ·
Giuseppe De Marchi¹ · Chiara Floridi¹ · Gabriele Piffaretti³ · Fontana Federico¹

FU

36 months

Clinical
Success

7/8

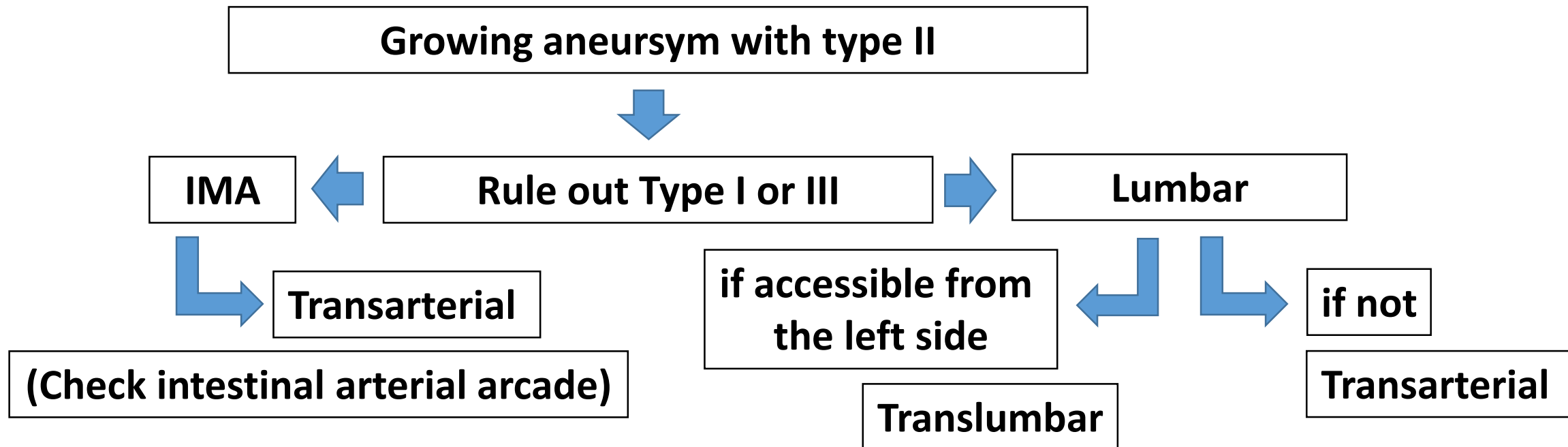
Carrafiello, Cardiovasc Intervent Radiol, 2016

Take Home Message

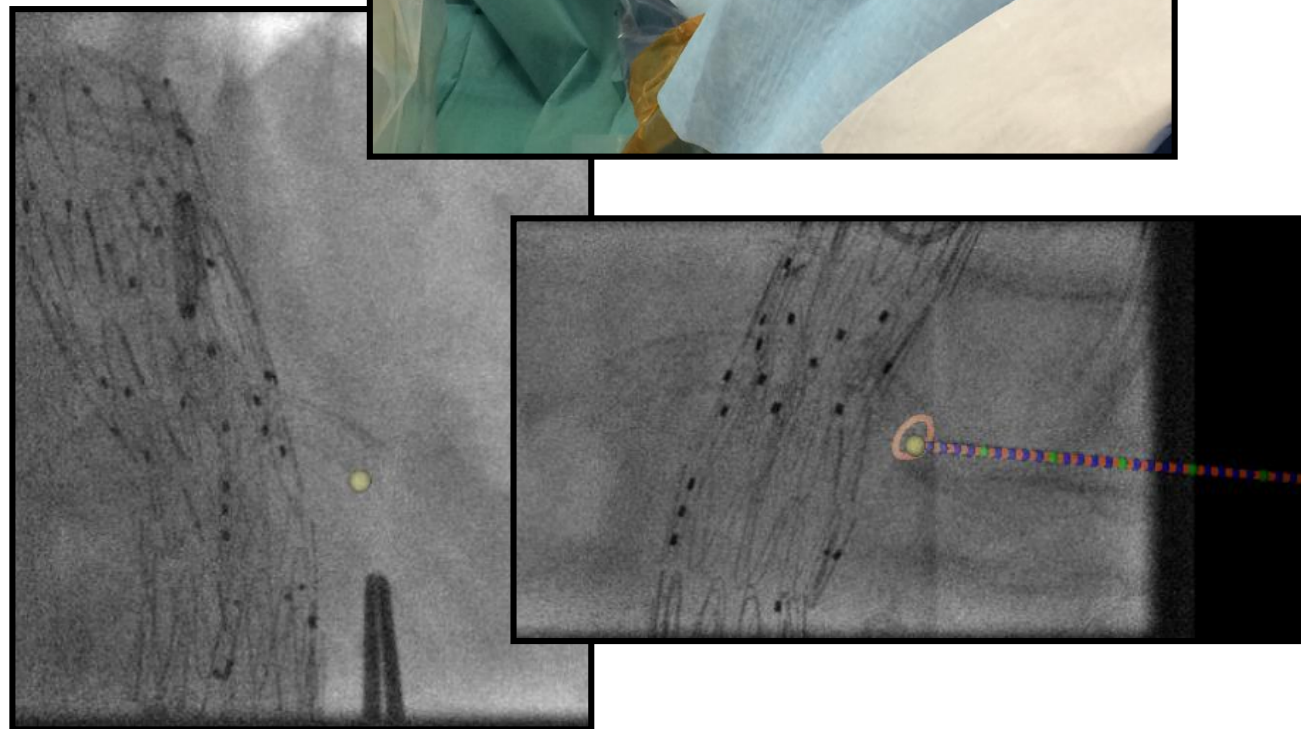
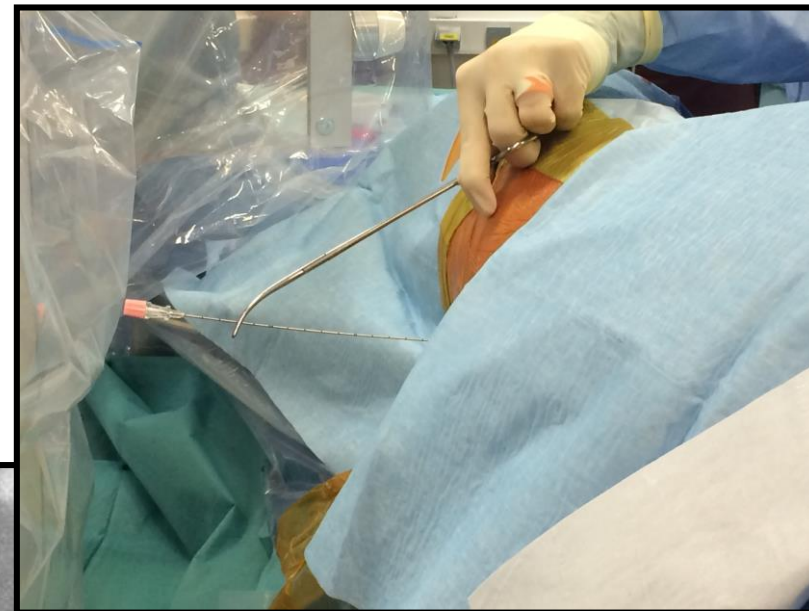
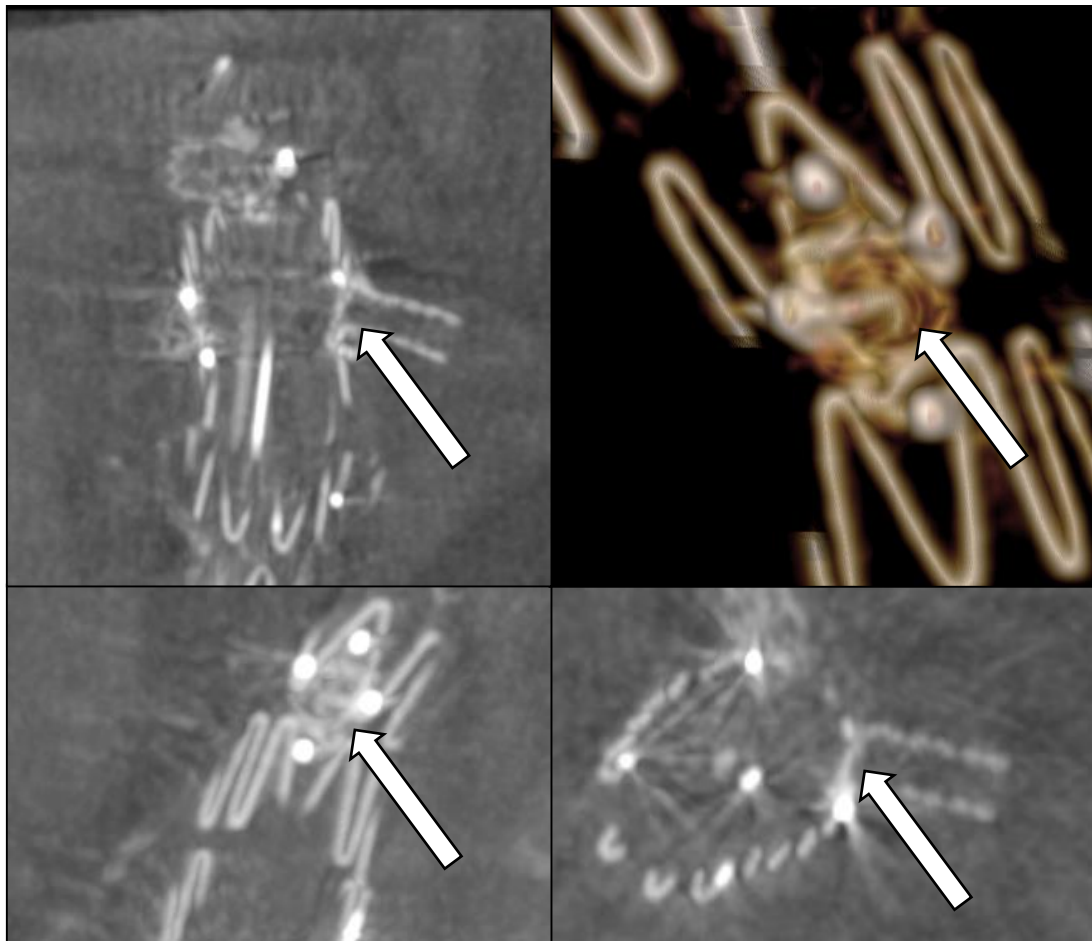Safe & efficient

Faster than transarterial for lumbar embolization

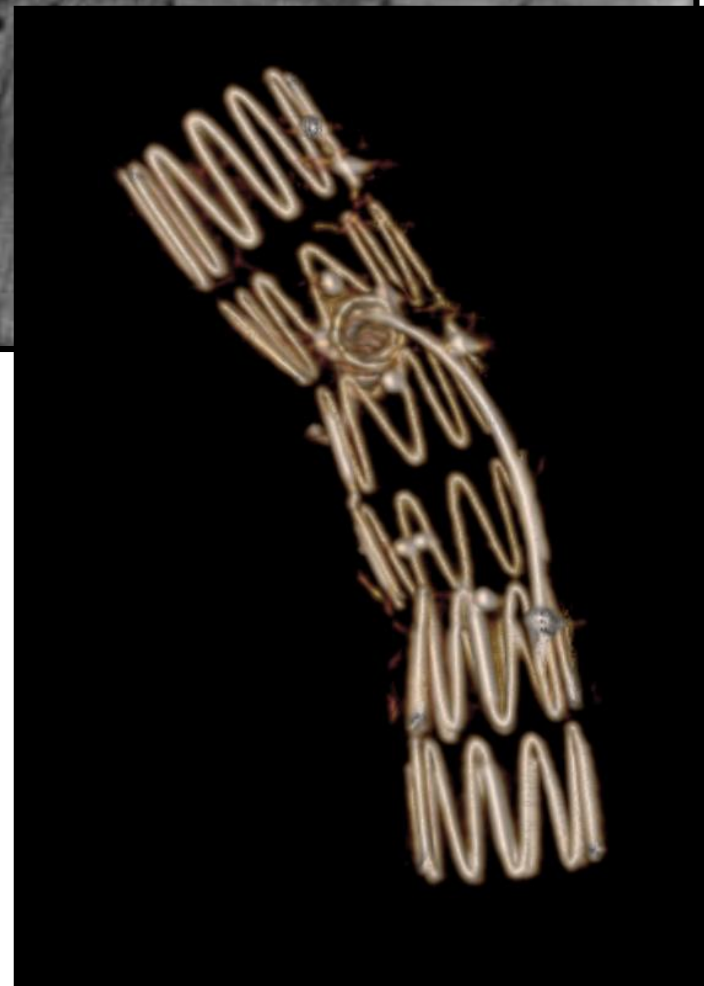
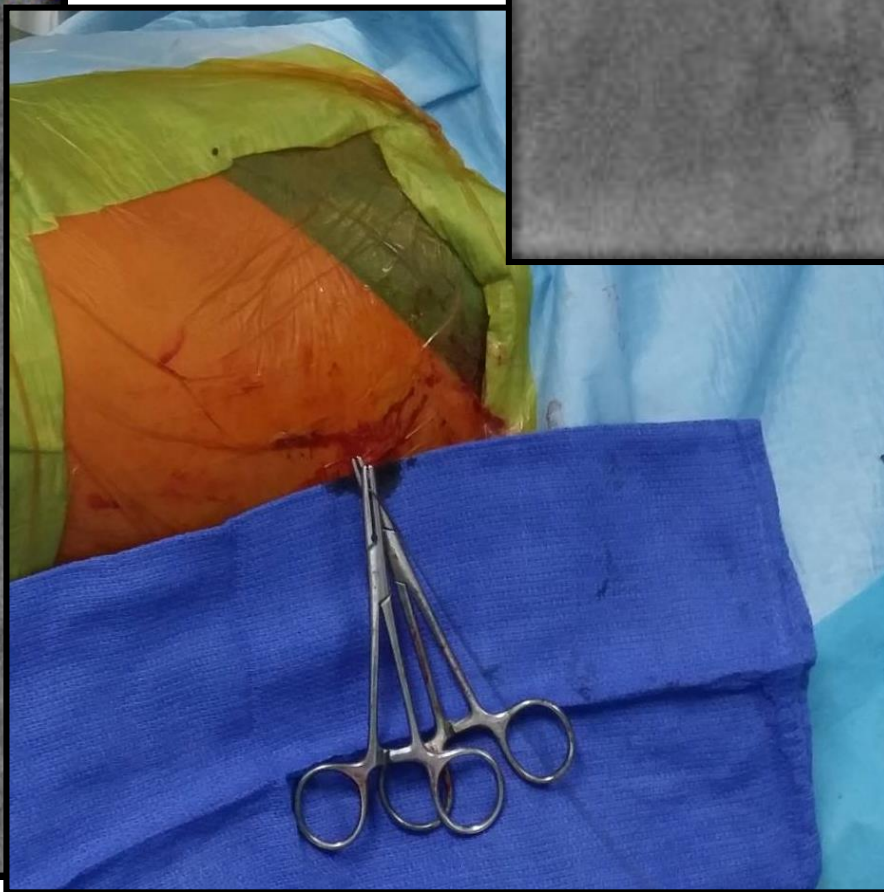
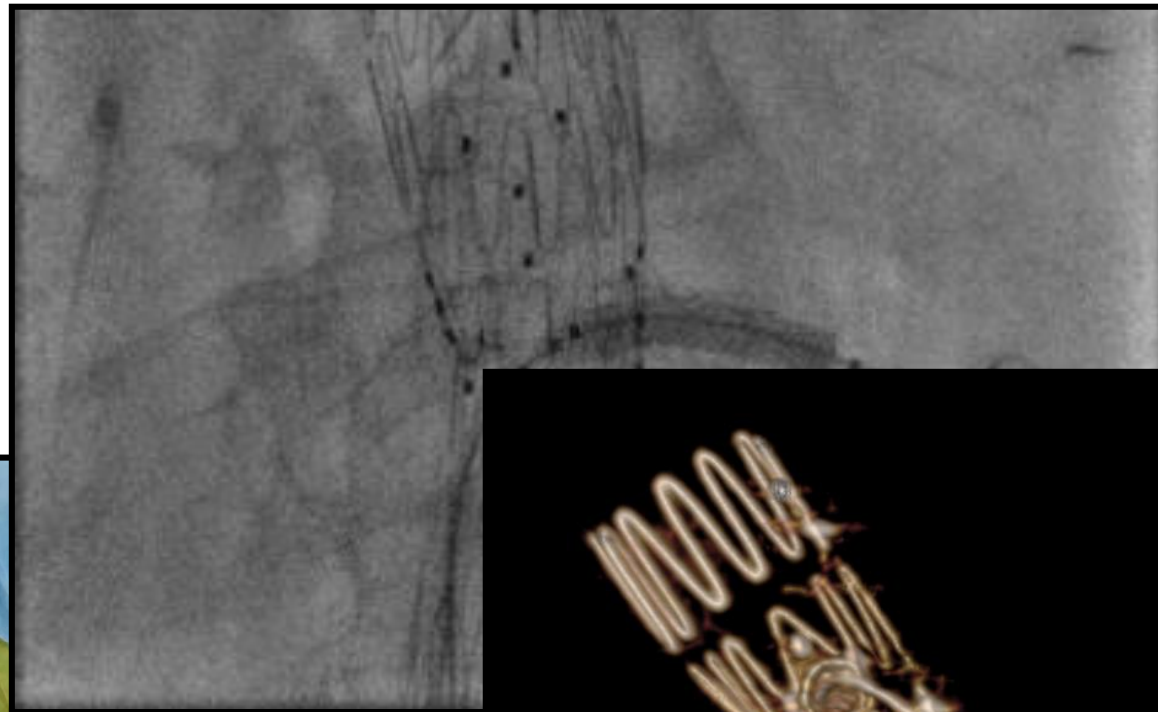
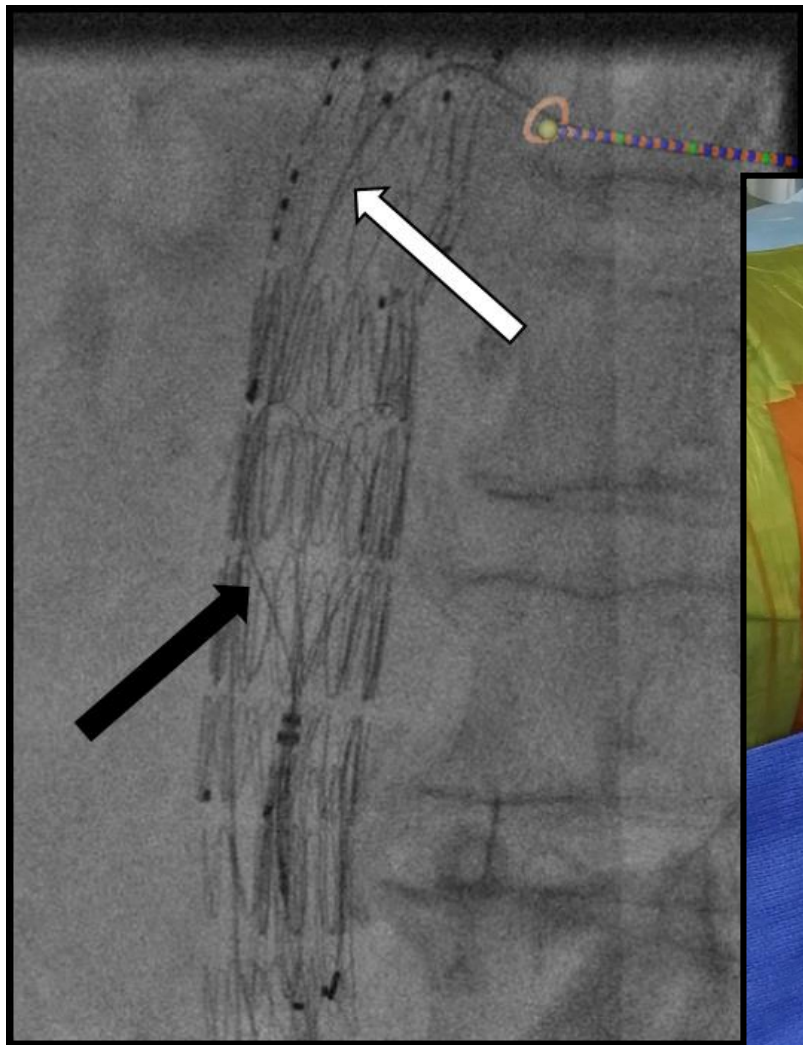
Easy with new gen HR and dedicated advanced imaging applications



Future applications?



Other applications





20TH INTERNATIONAL EXPERTS SYMPOSIUM
CRITICAL ISSUES
in aortic endografting **2016**
May **20 & 21** - LILLE - FRANCE



When a stab in the back works: translumbal type 2 endoleak embolization

A. Hertault, T. Martin-Gonzalez, R. Spear, R. Clough, R. Azzaoui, J. Sobocinski, S. Haulon