

# Chronic Dissections: Is There a Role for Branched and Fenestrated Endografts?

Stéphan Haulon,

J Sobocinski, B Maurel, M Guillou, R Azzaoui  
Vascular Surgery, Hôpital cardiologique,  
CHU Lille, France



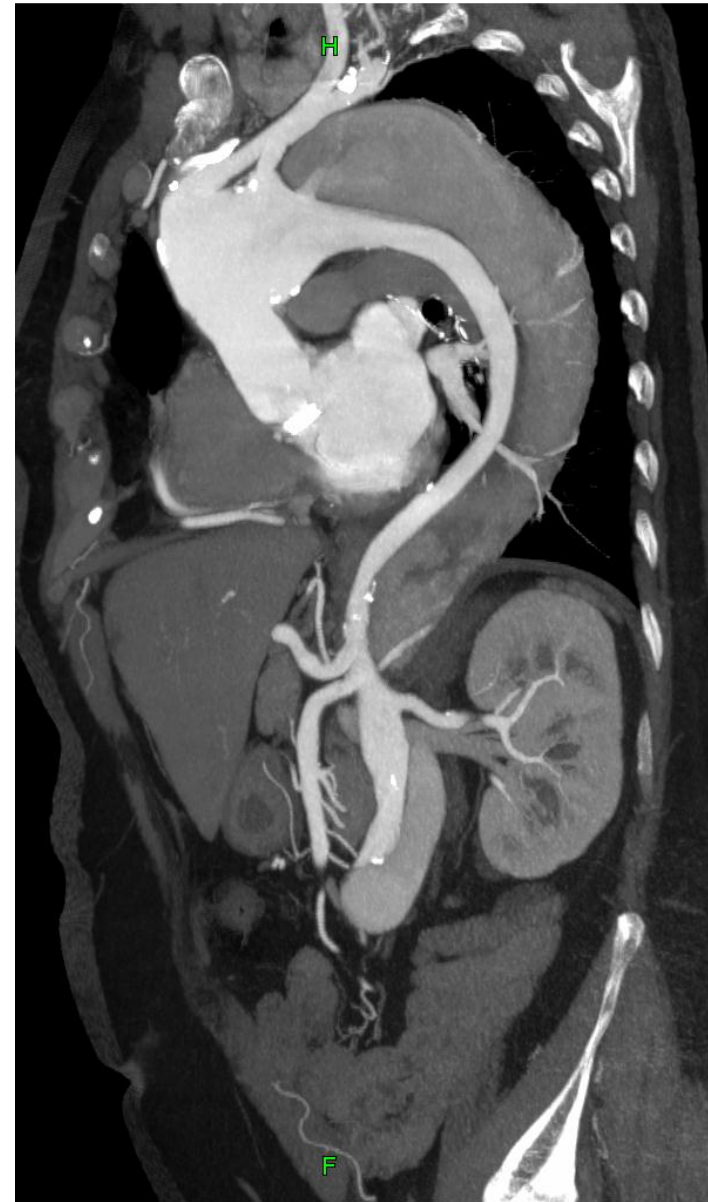
# Disclosures

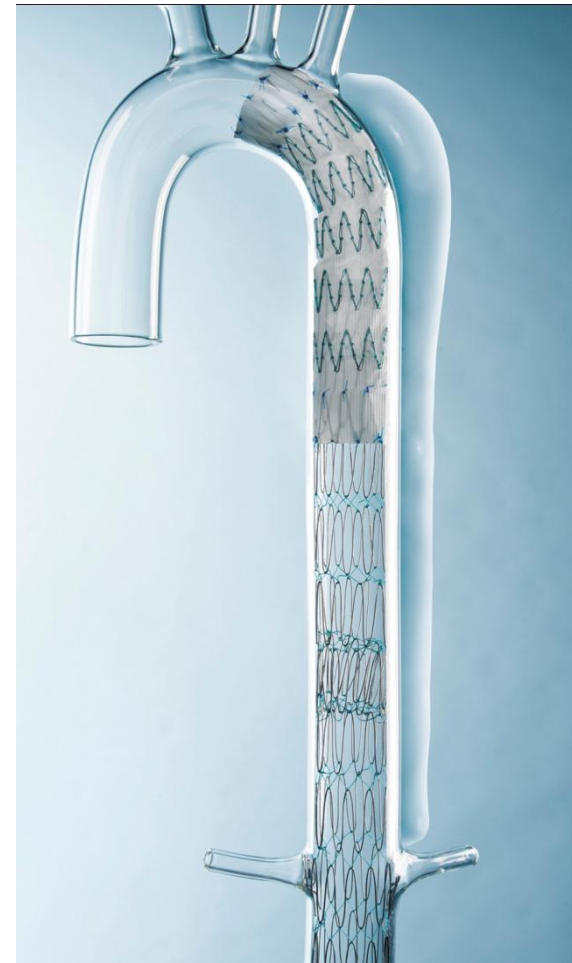
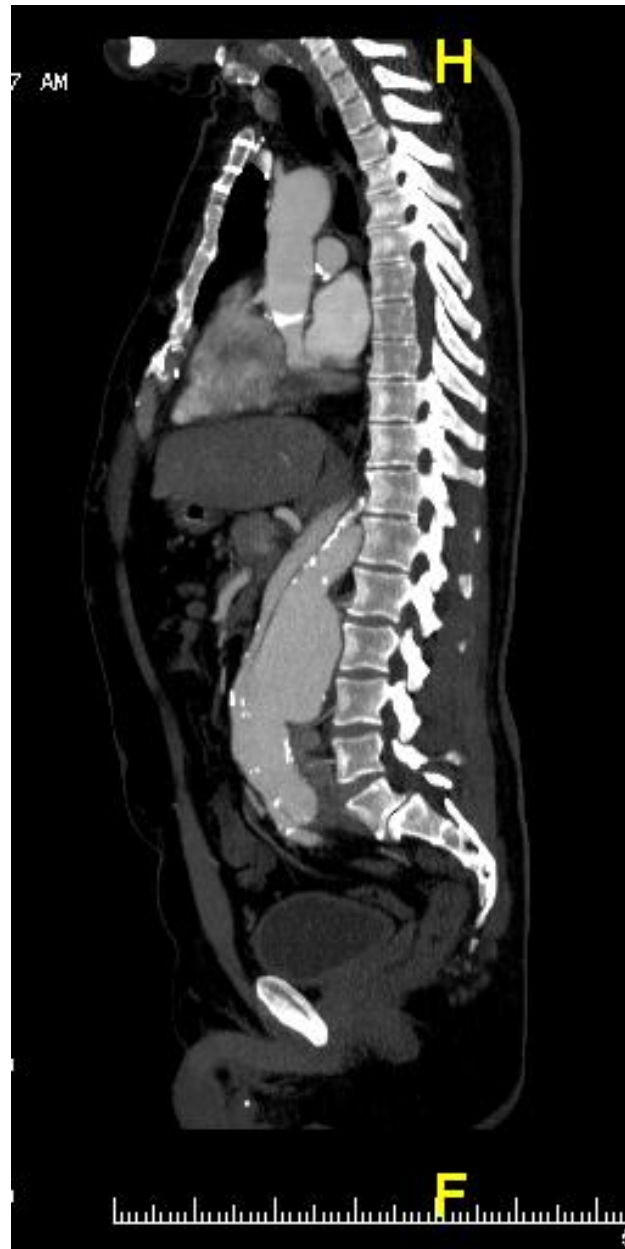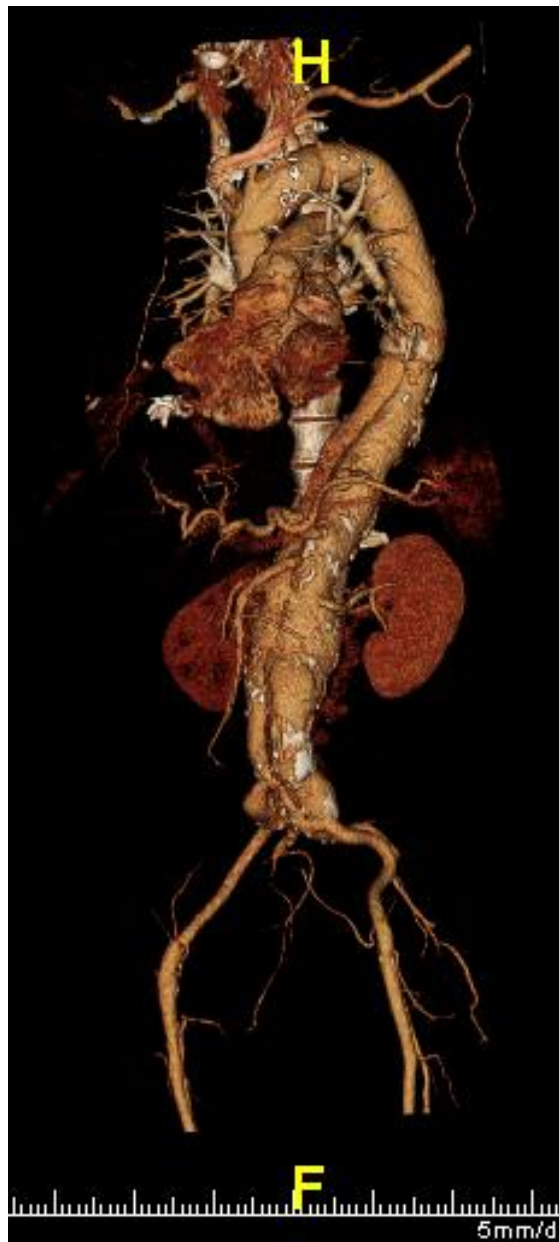- Research support, Consulting:
  - Cook Inc., GE

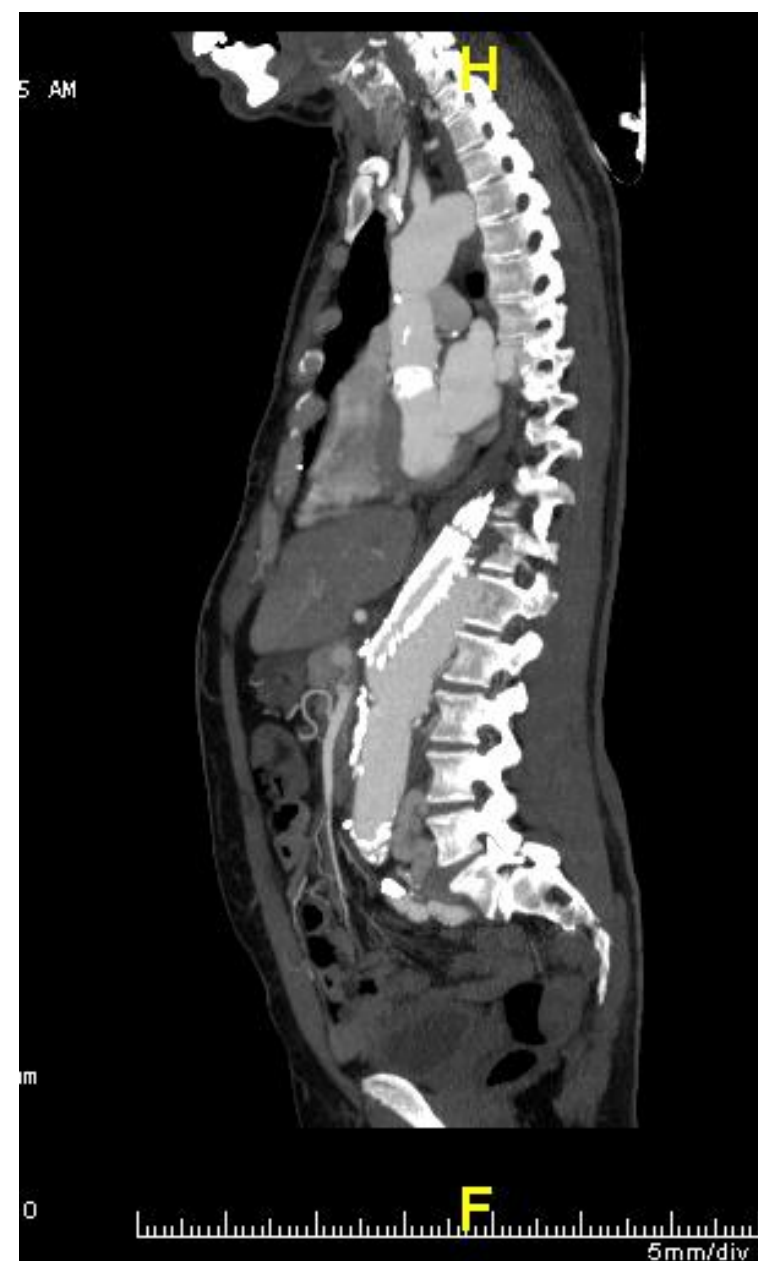
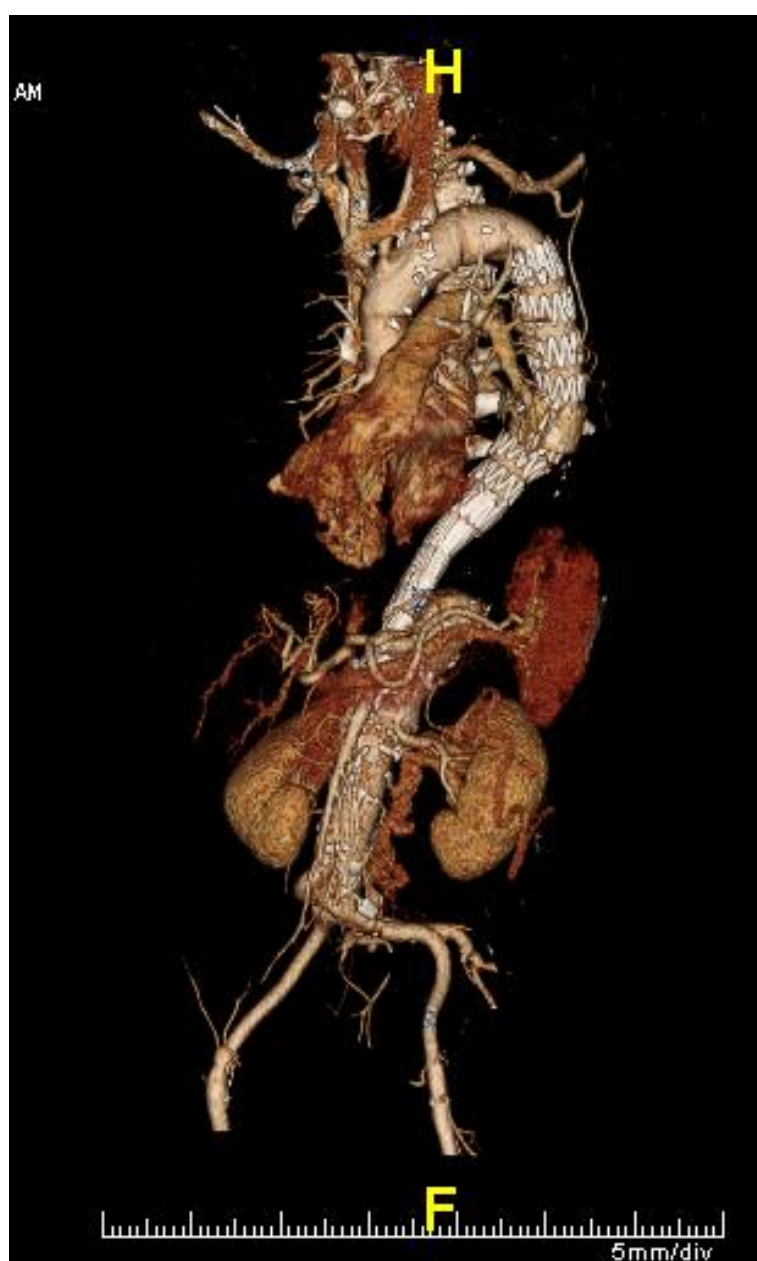
# Challenging Procedures

- Proximal and Distal Sealing
- Narrow true lumen
- Target vessels perfused by false lumen
- Limited experience

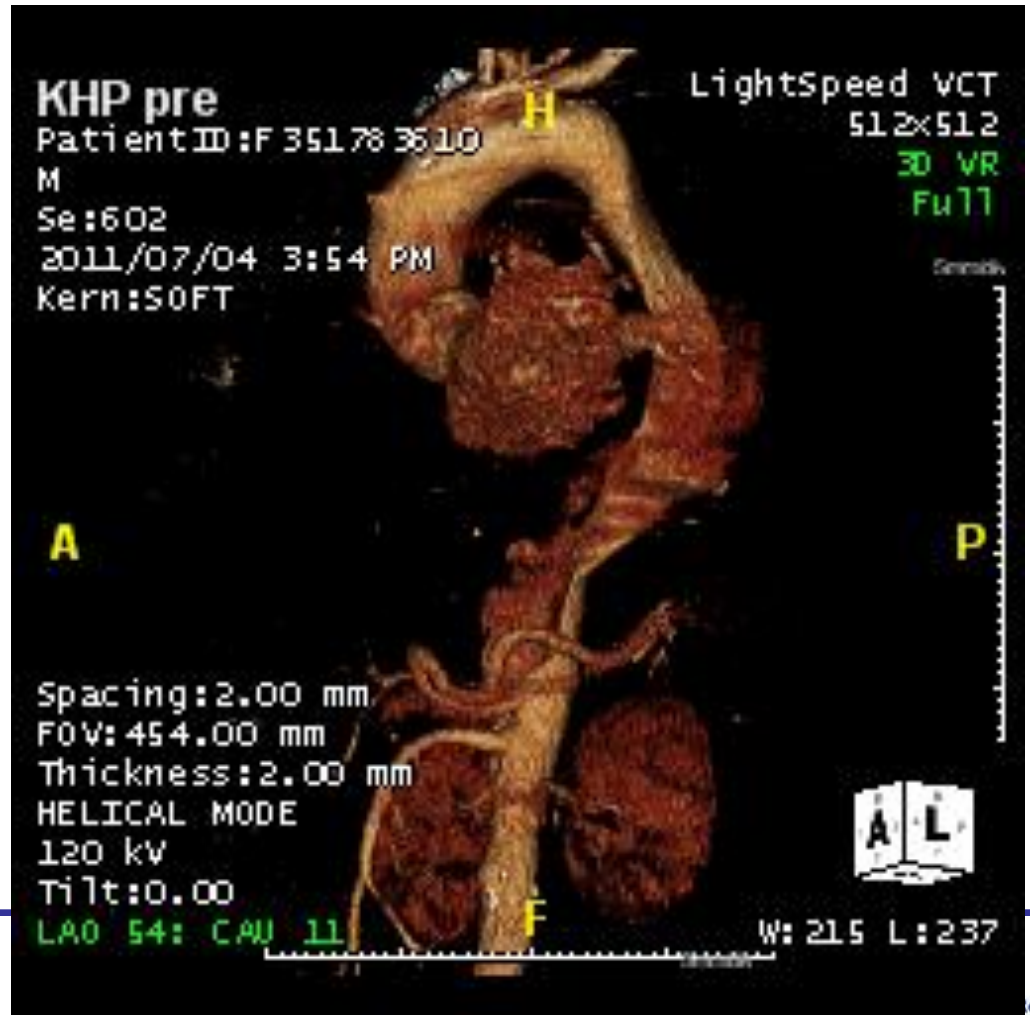
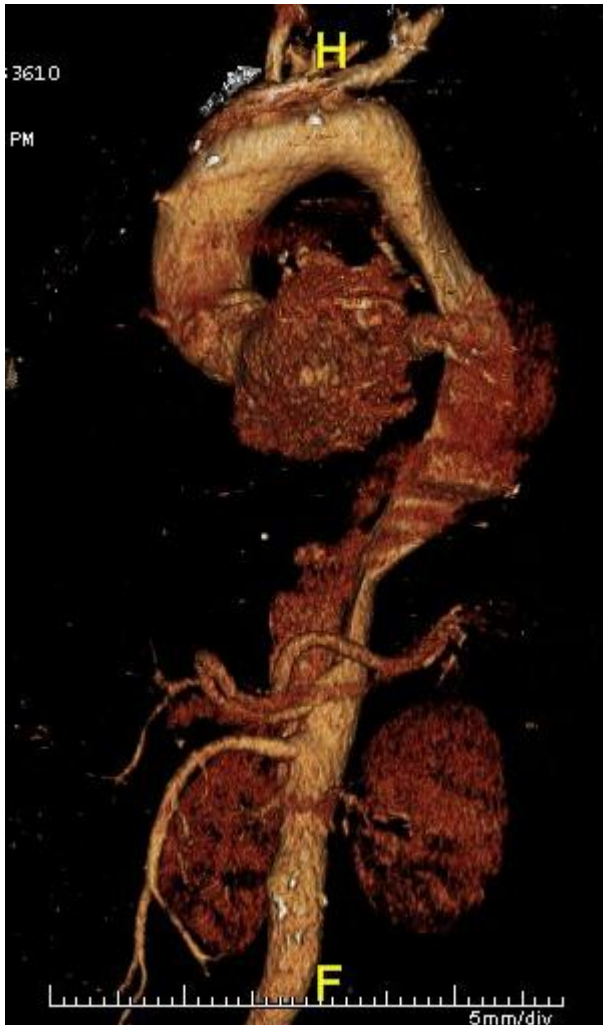






# 4-Fen Endograft

## KCH (MR Tyrrell, D Valenti, J Wilkins)



**KHP pre**

PatientID:F351783610

M

Se:602

2011/07/04 3:54 PM

Kern:SOFT

**A**

LightSpeed VCT  
512x512

MPR

Filter:None

**KHP pre**

PatientID:F351783610

M

Se:602

2011/07/04 3:54 PM

Kern:SOFT

**A**

LightSpeed VCT  
512x512

MPR

Filter:None

**R**

**L**

**R**

**L**

FOV:454.00 mm

HELICAL MODE

120 kV

Tilt:0.00

LAO 46; CAU 85

No: 5

**P**



TERARECON  
W:600 L:200

FOV:454.00 mm

HELICAL MODE

120 kV

Tilt:0.00

LAO 46; CAU 85

No: 6

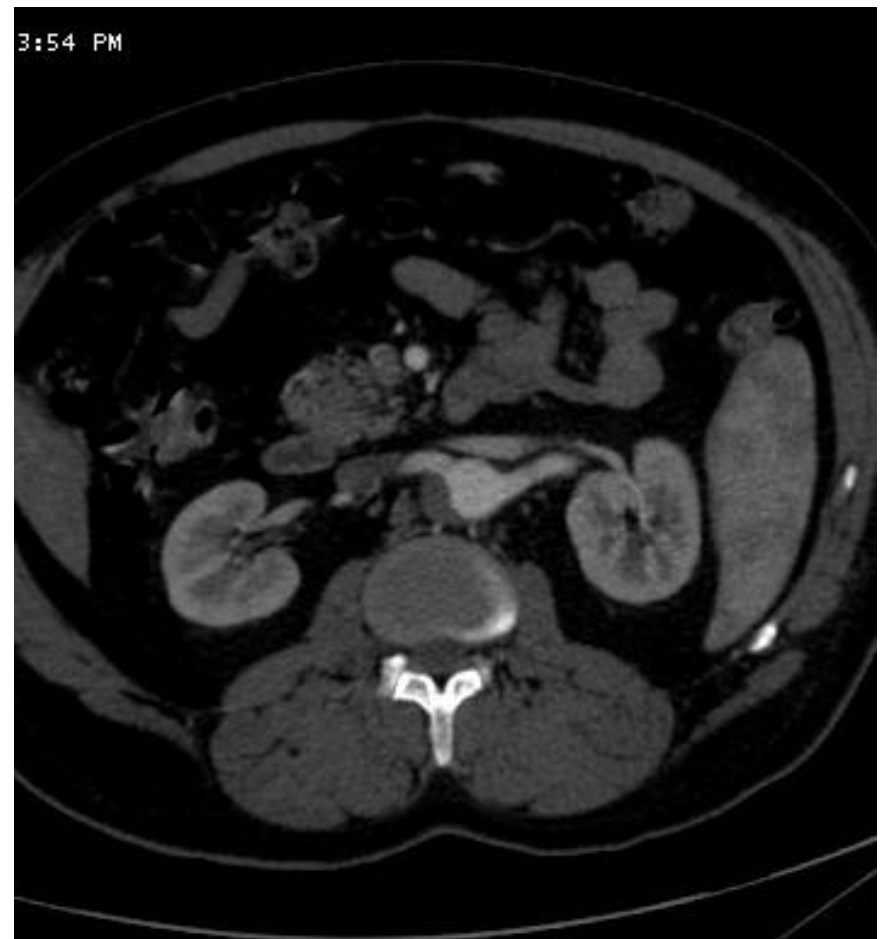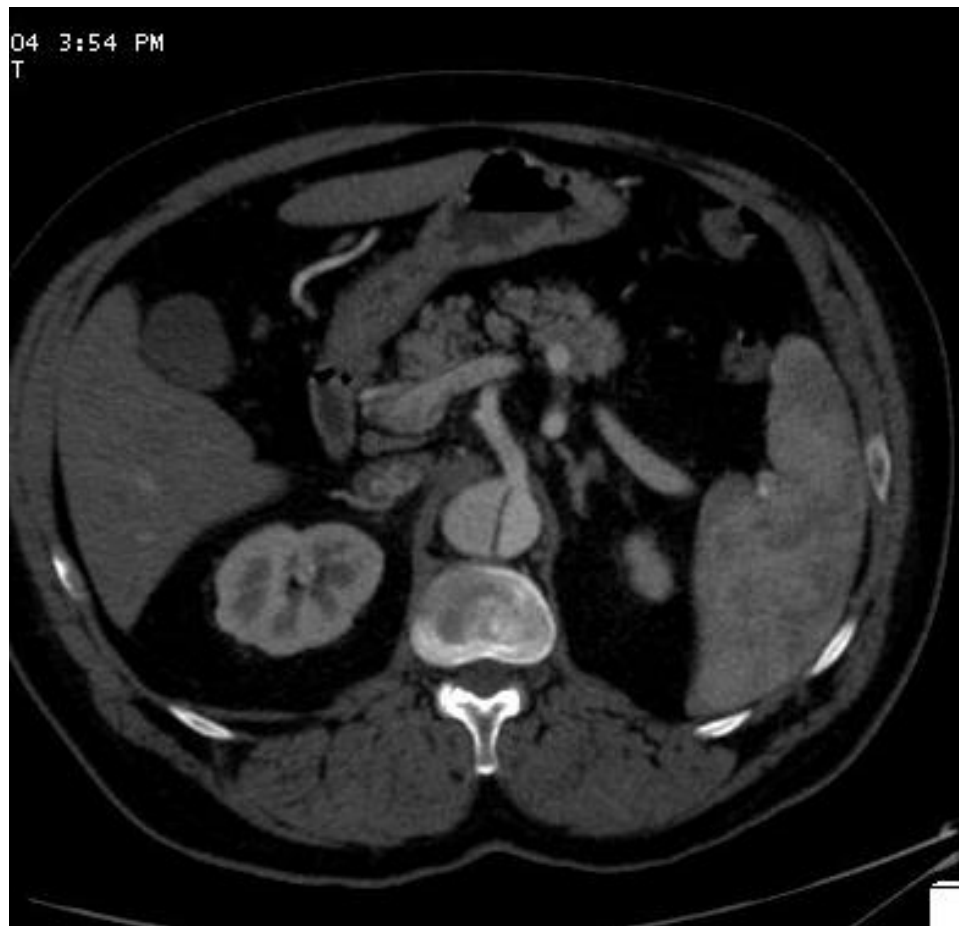**P**




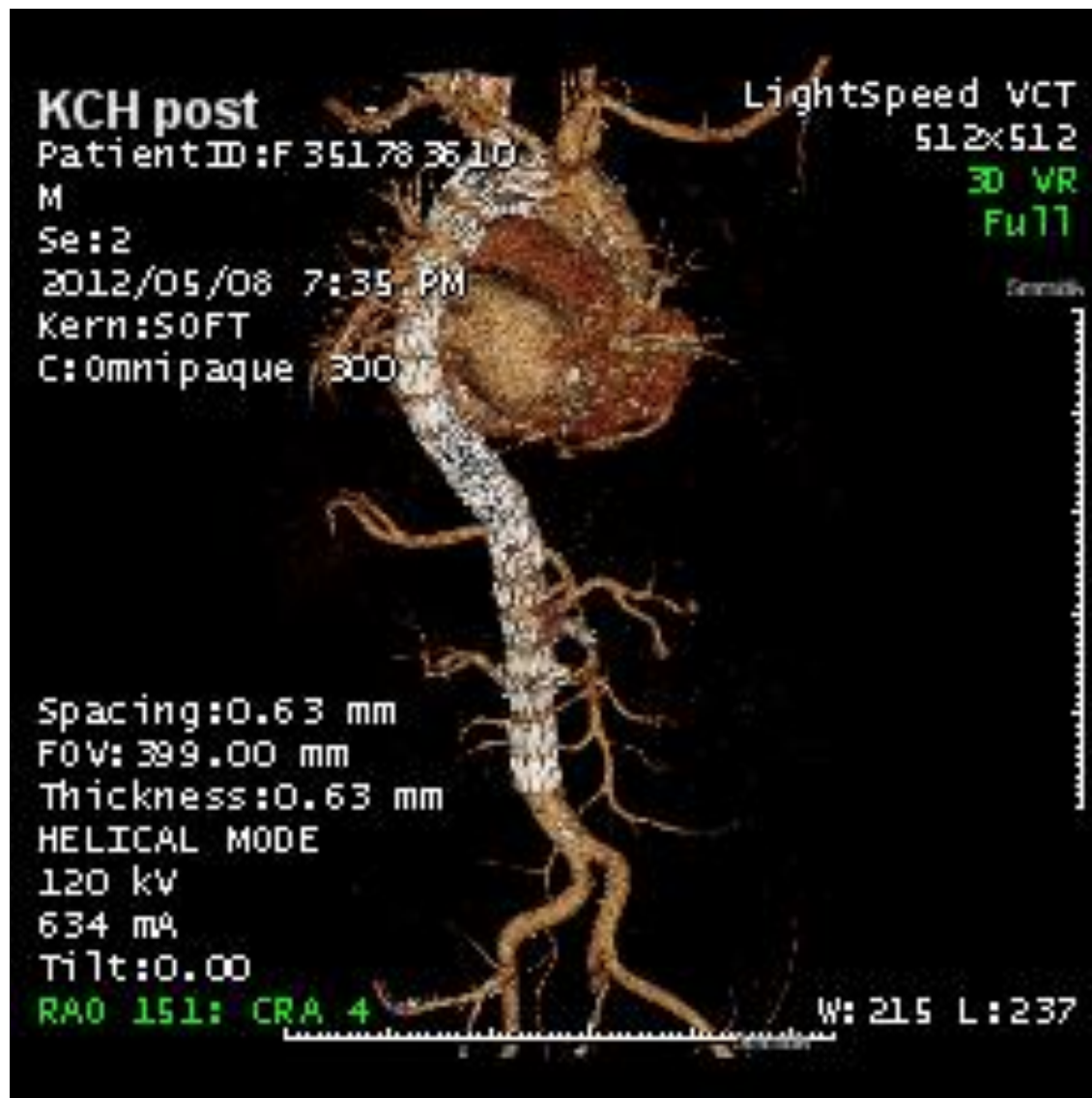
TERARECON  
W:600 L:200



Centre Hospitalier Régional  
Universitaire de Lille



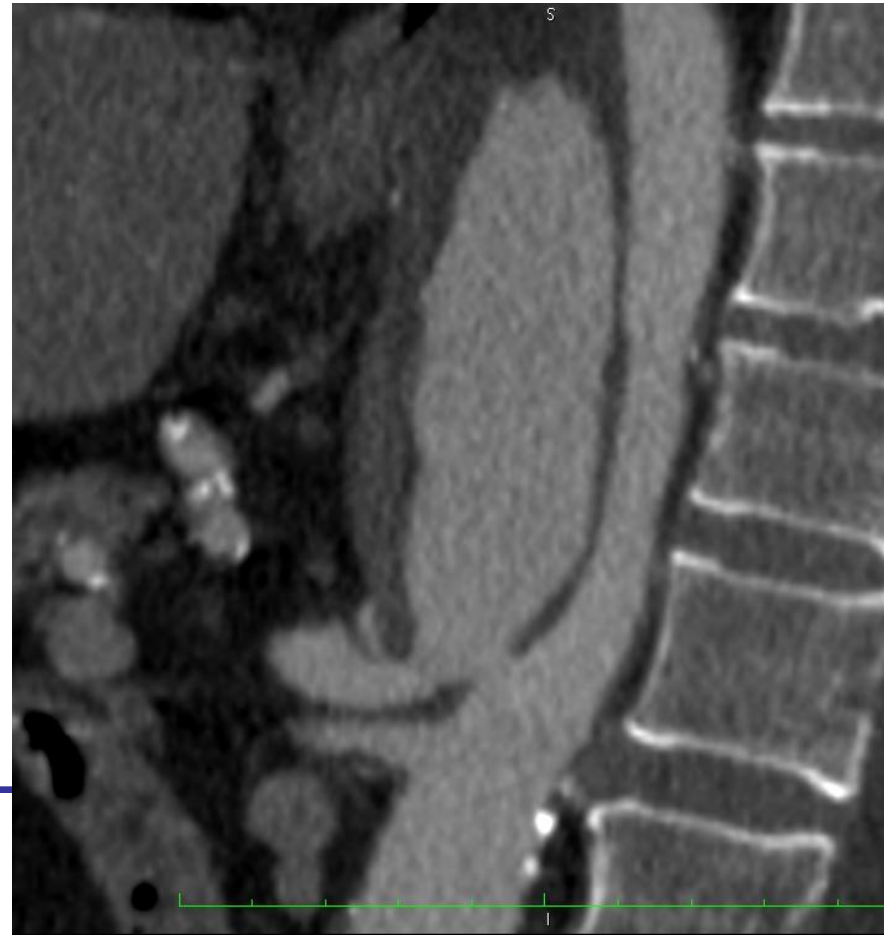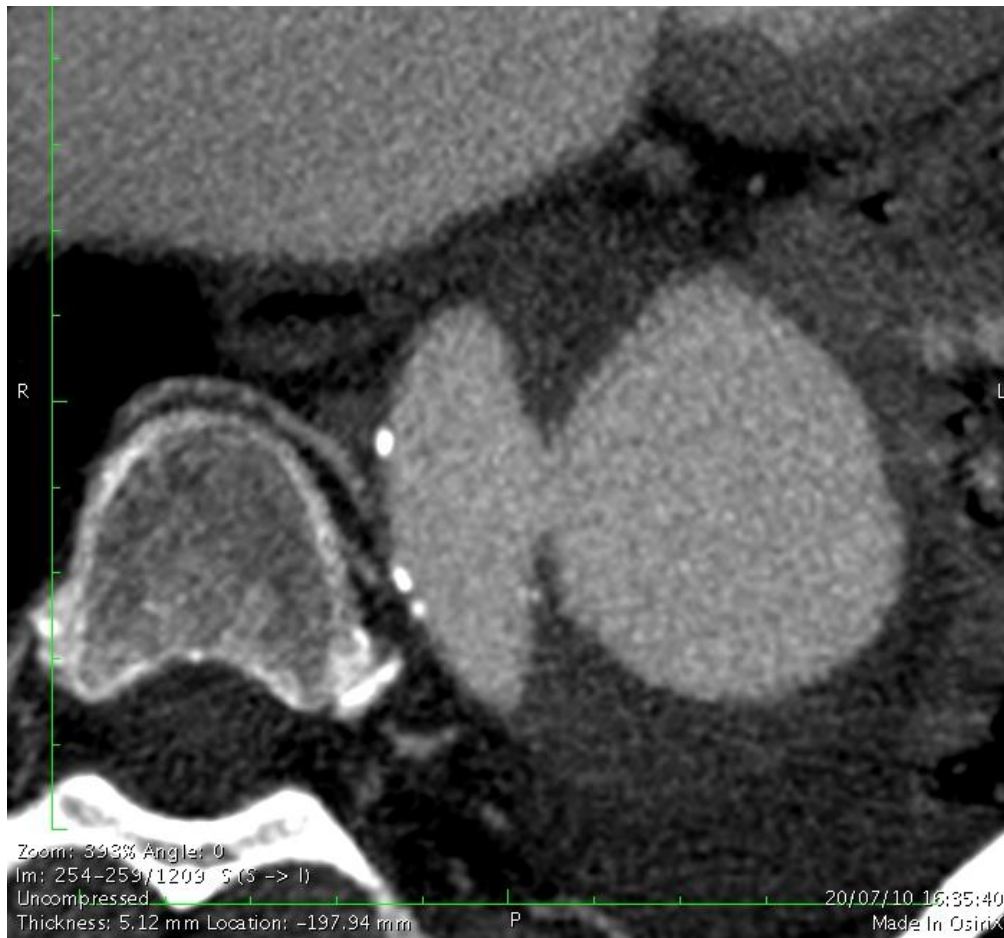



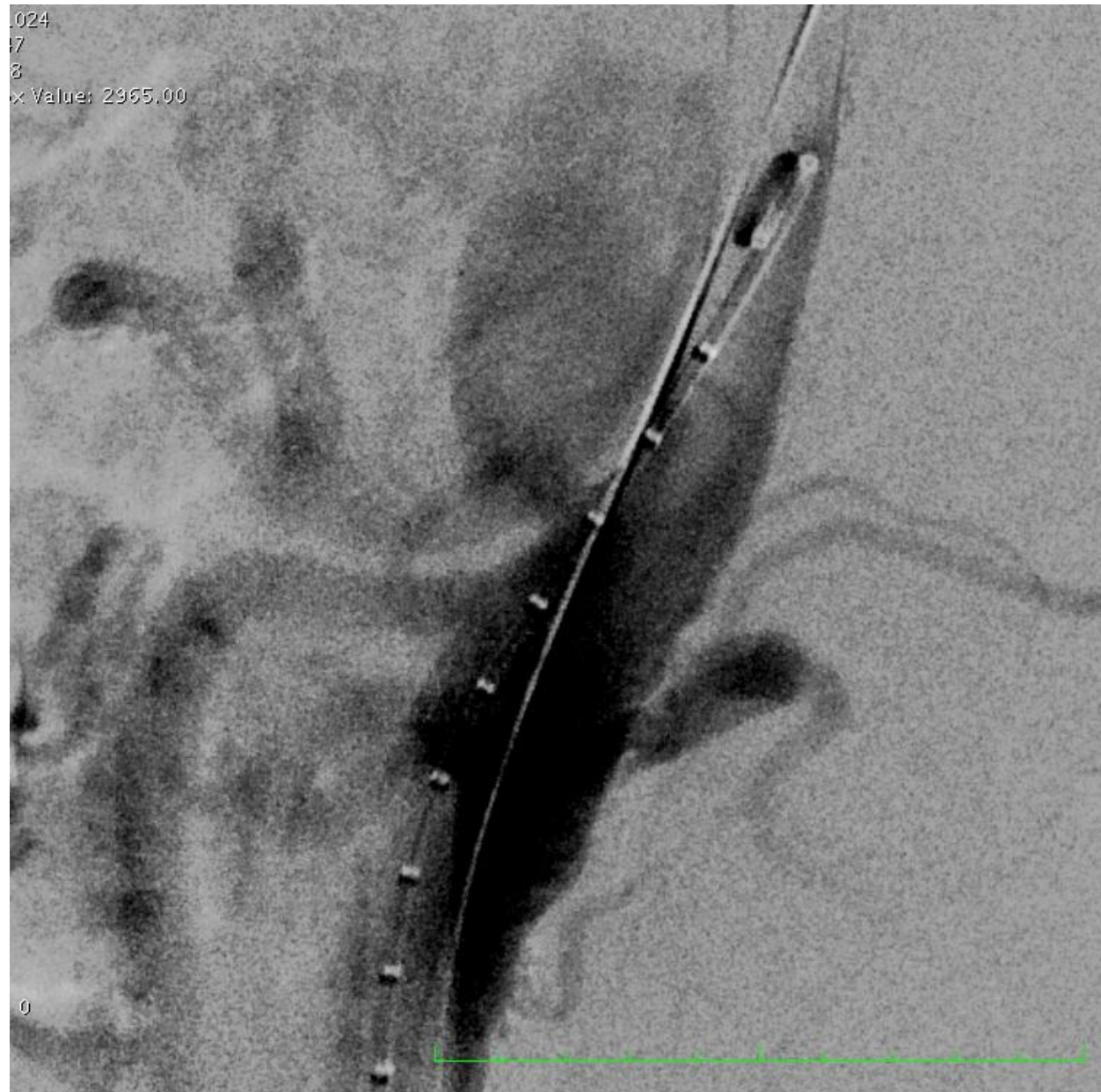
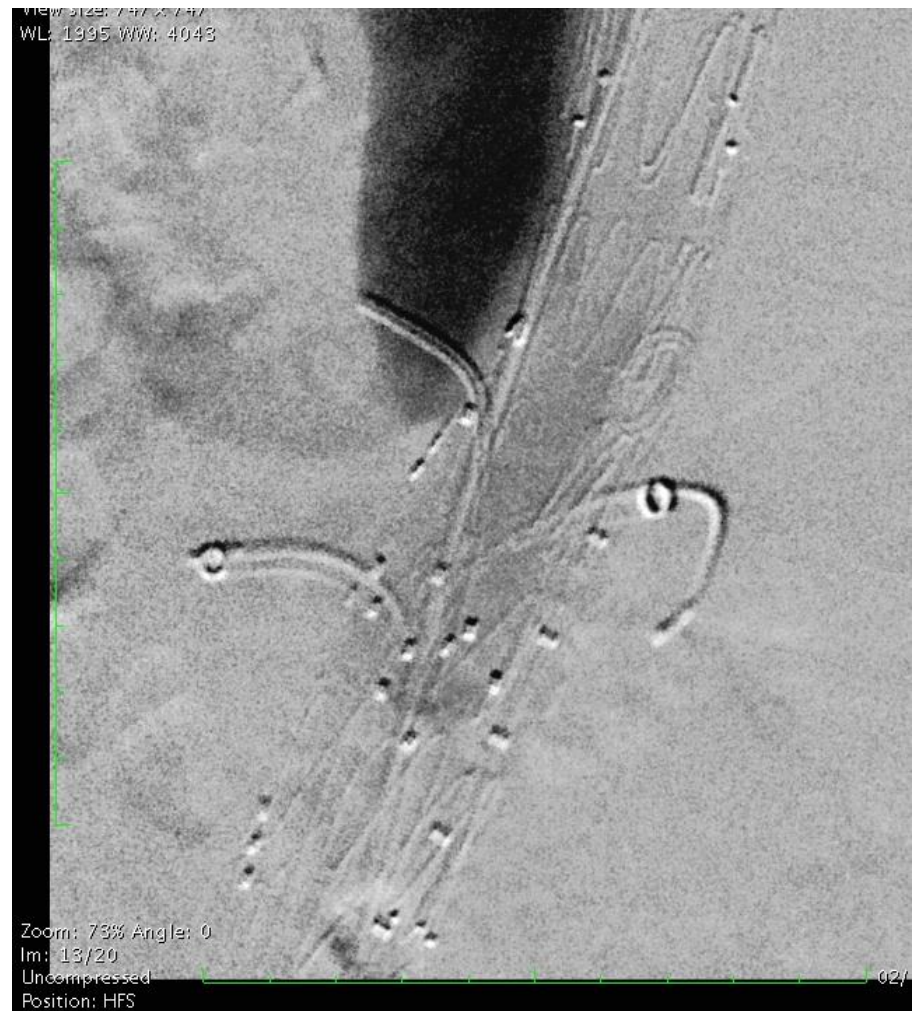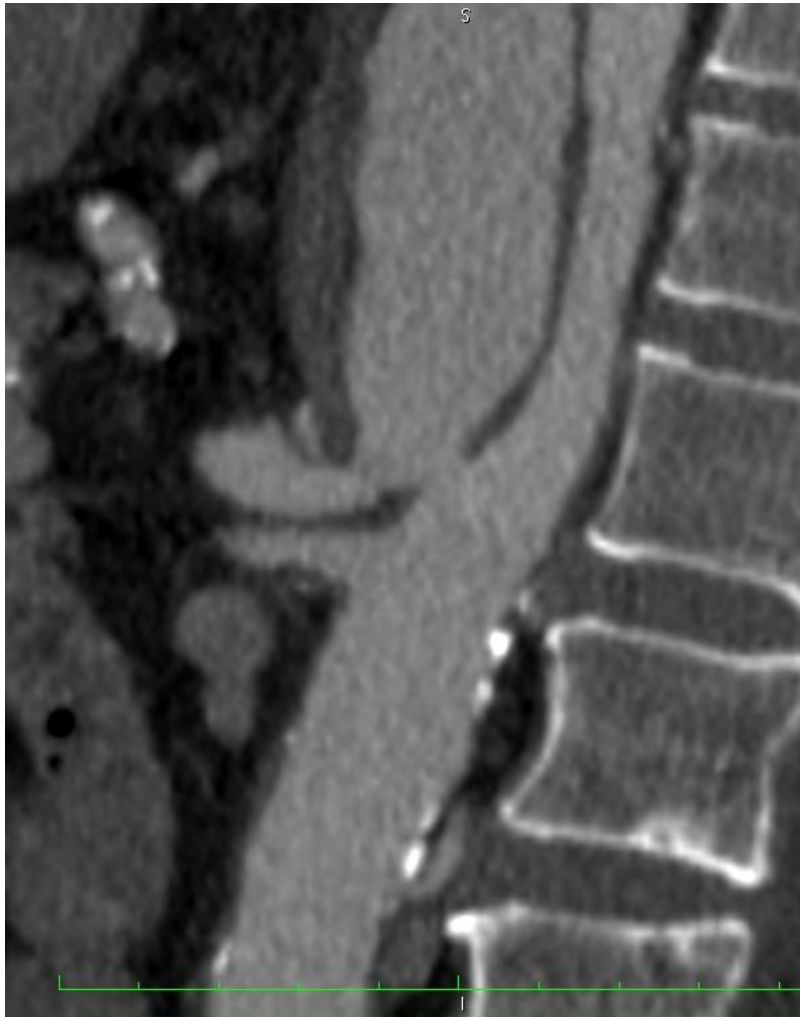
# False Lumen

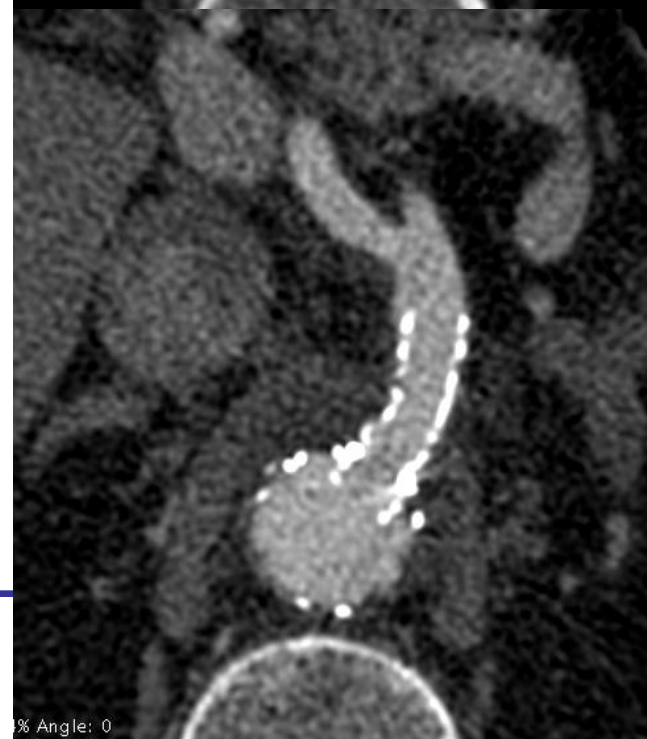
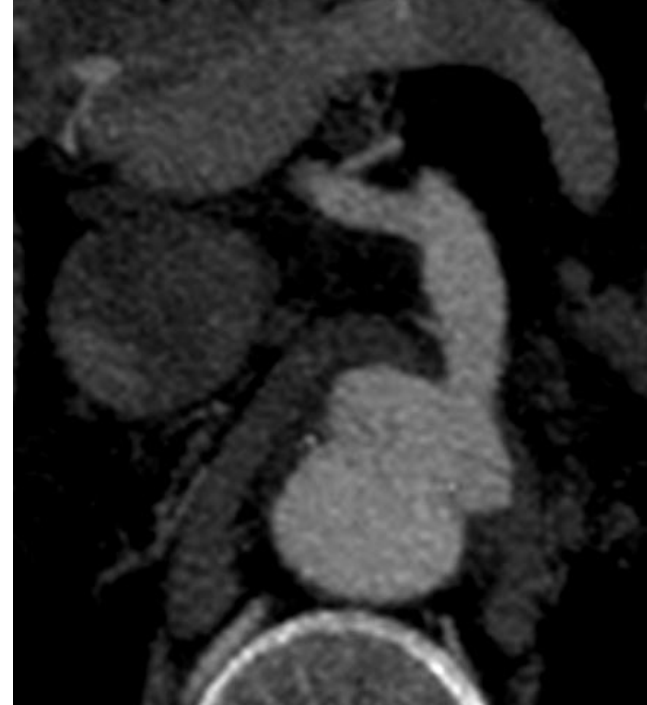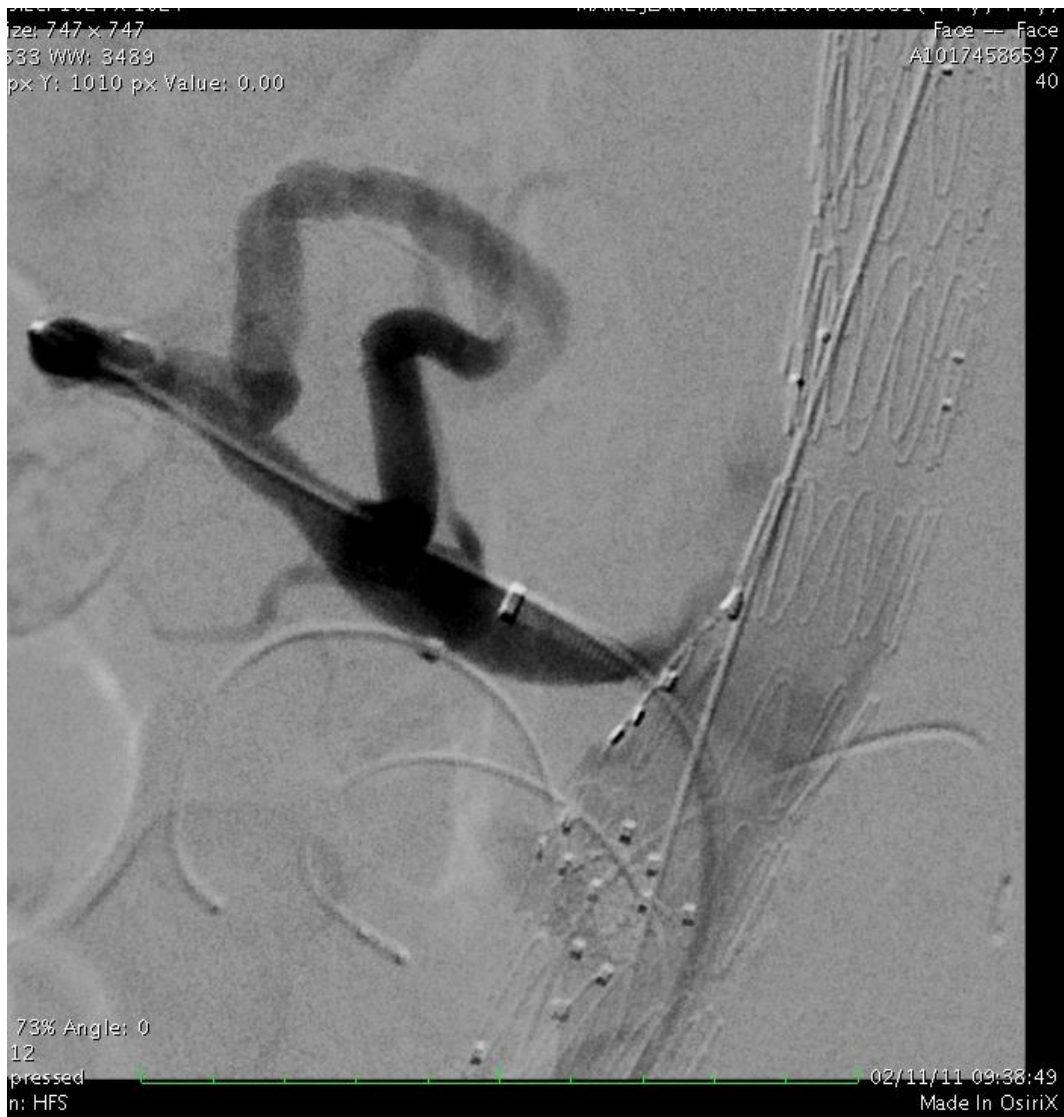## Target Vessel Access

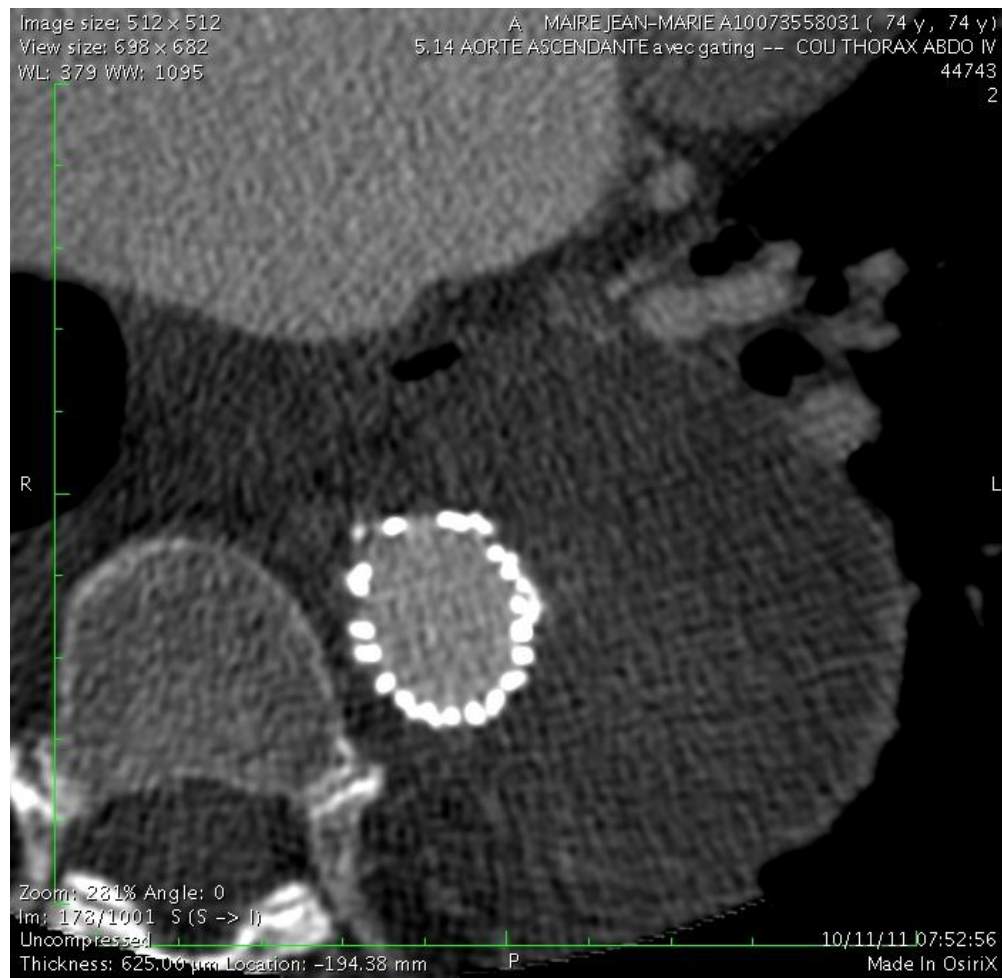
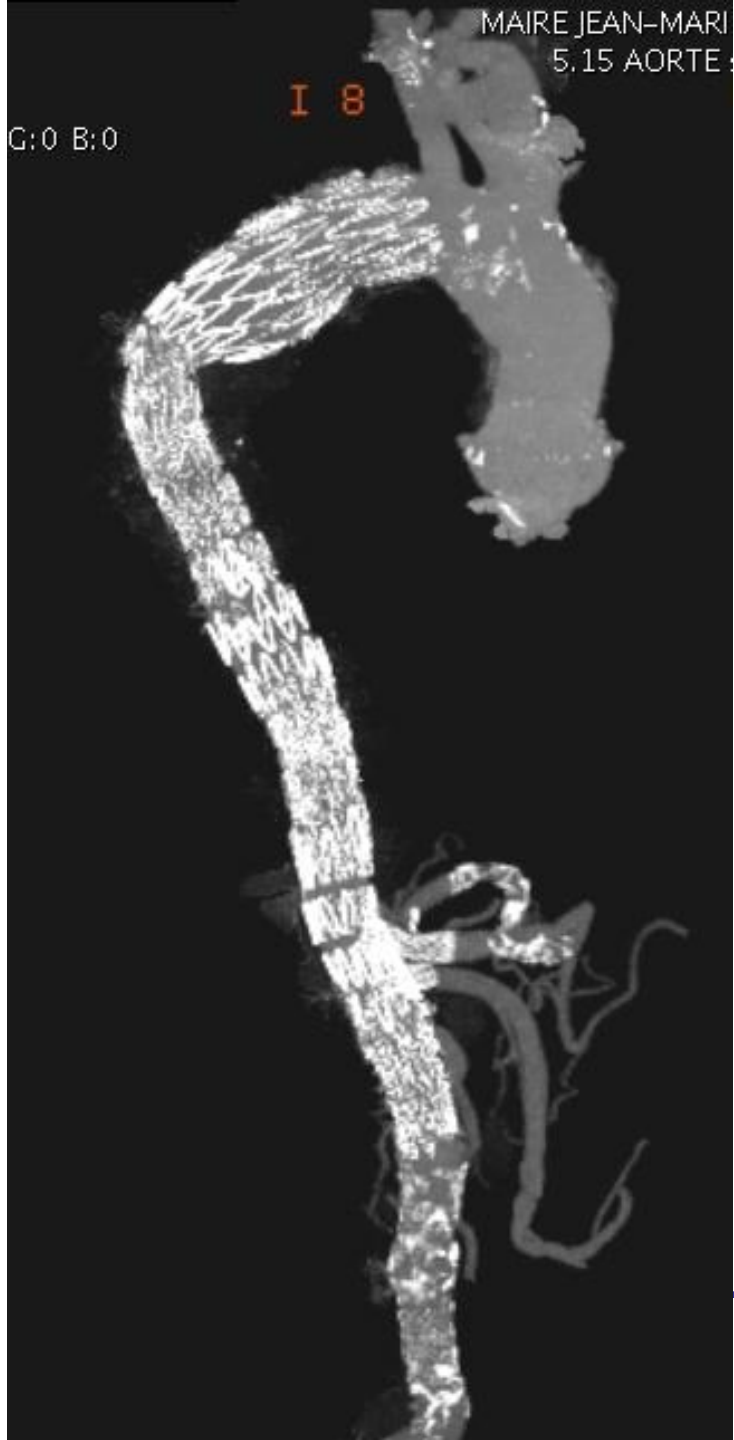
- Pr Serguei Malikov, CHU Nancy





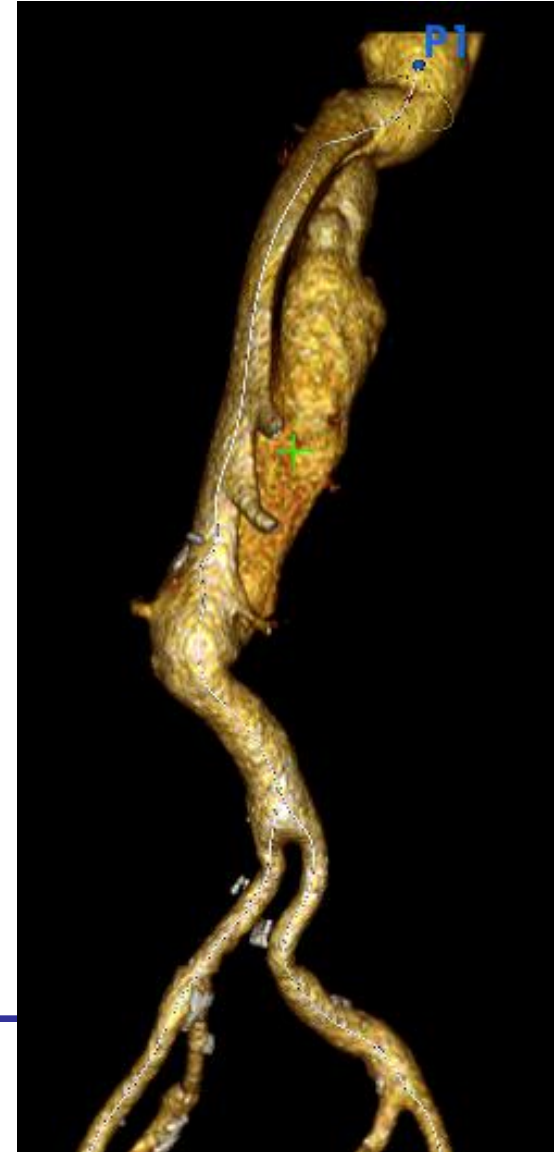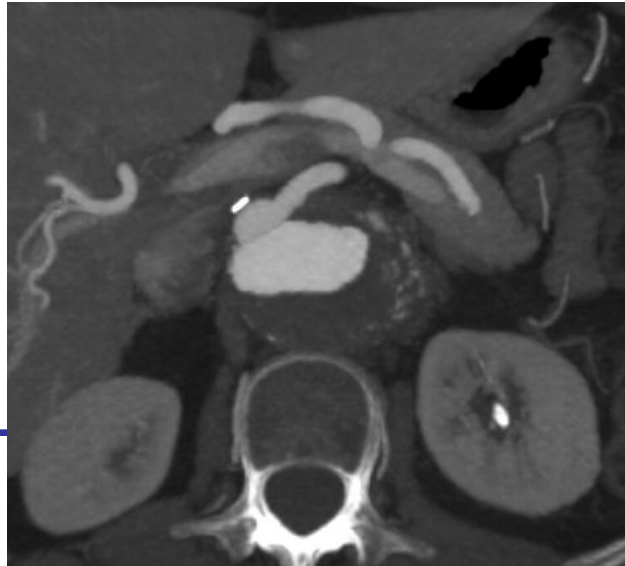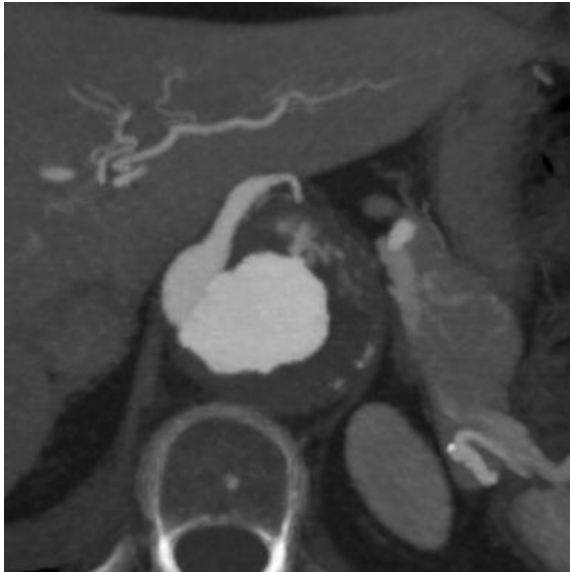







# TRUE/FALSE LUMEN NAVIGATION

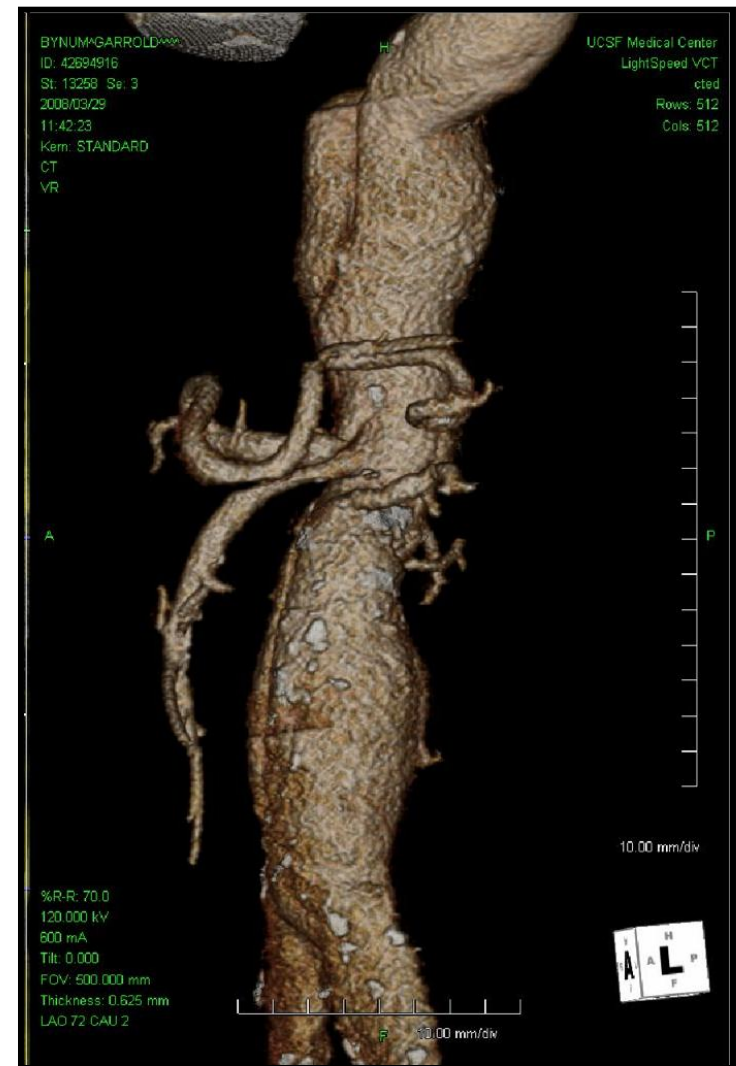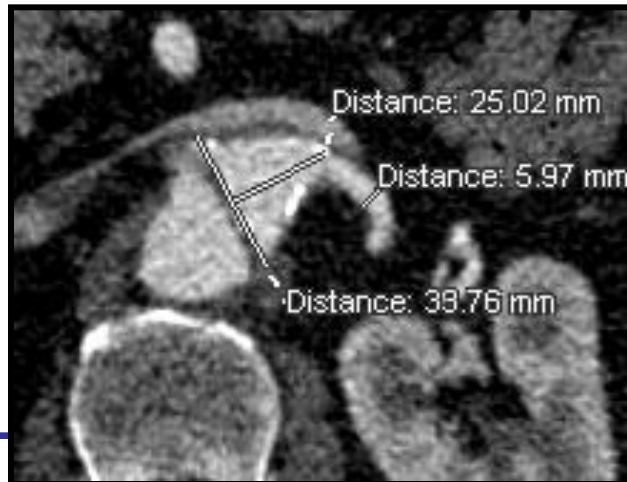
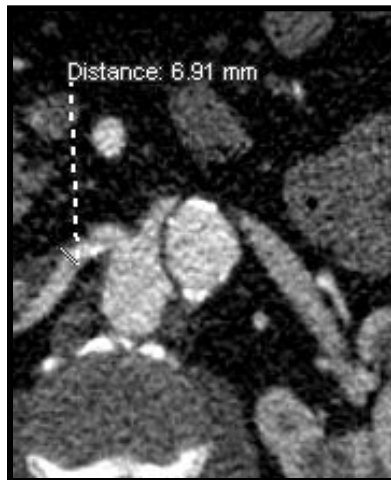
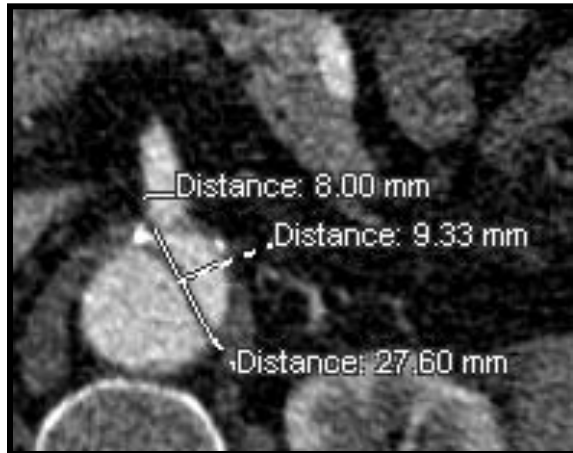
- JF Heutot, A Kaladji, CHU Rennes
- Fusion

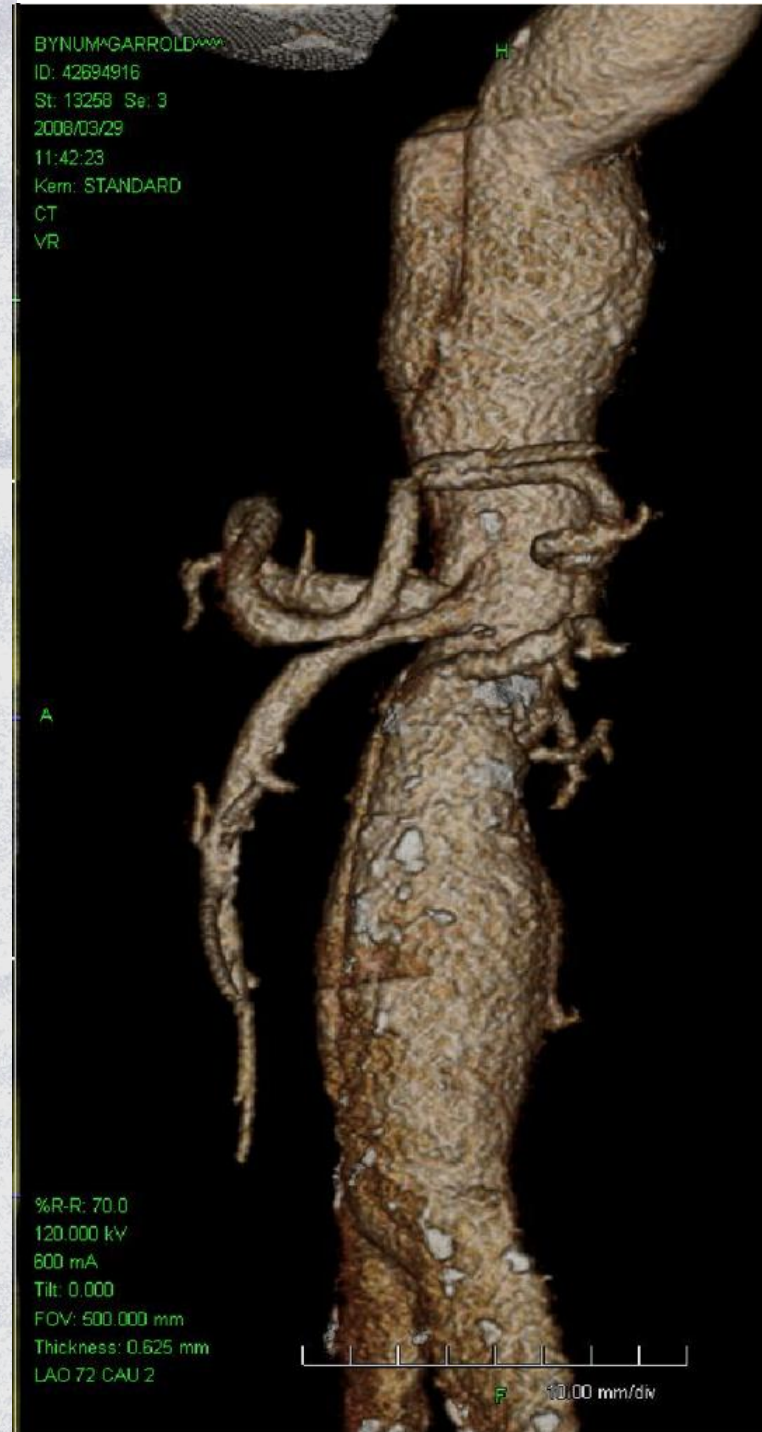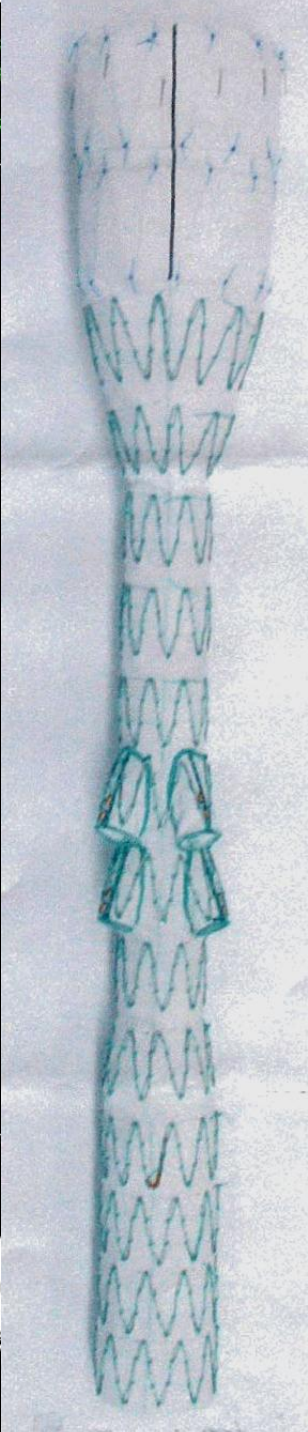

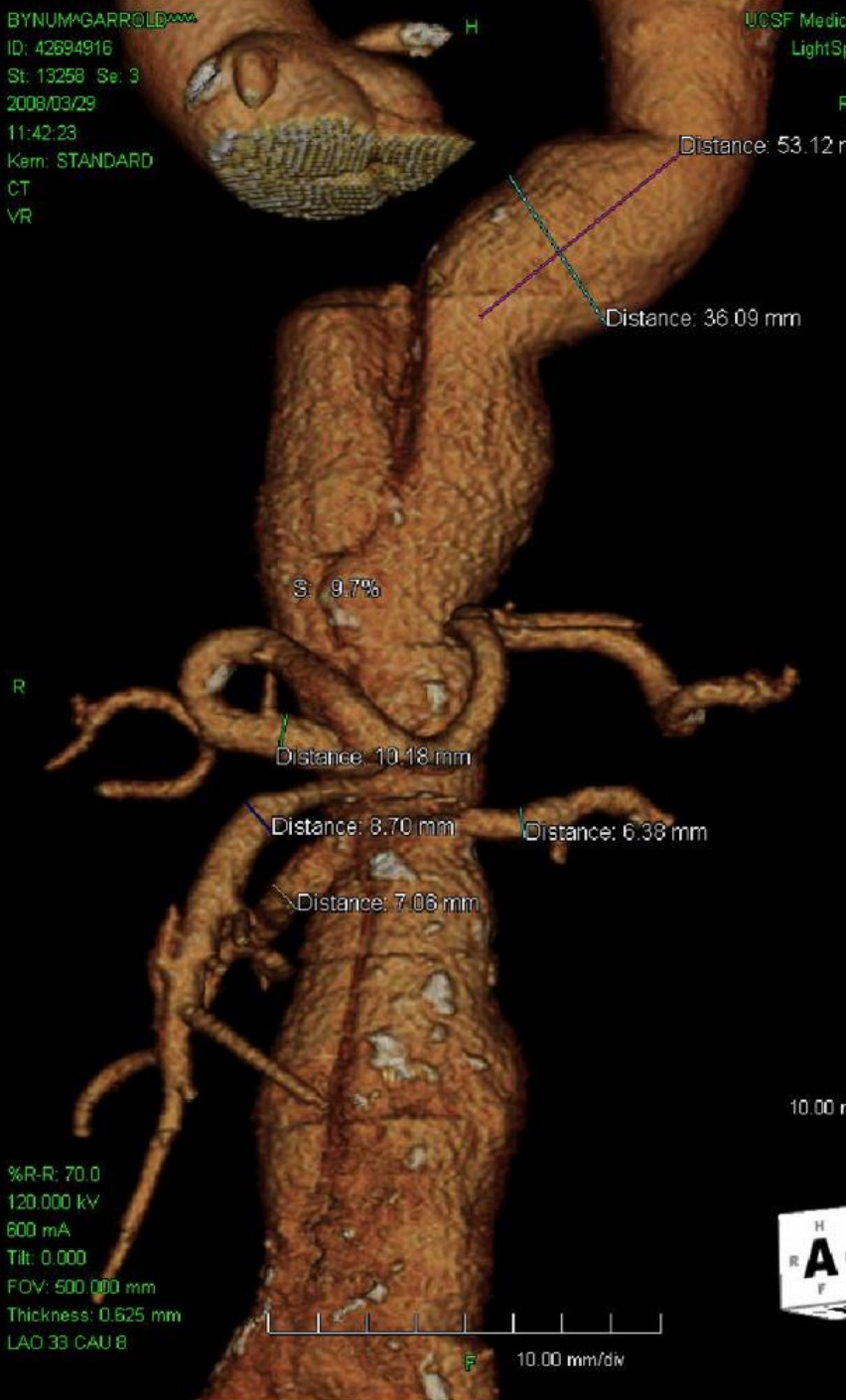
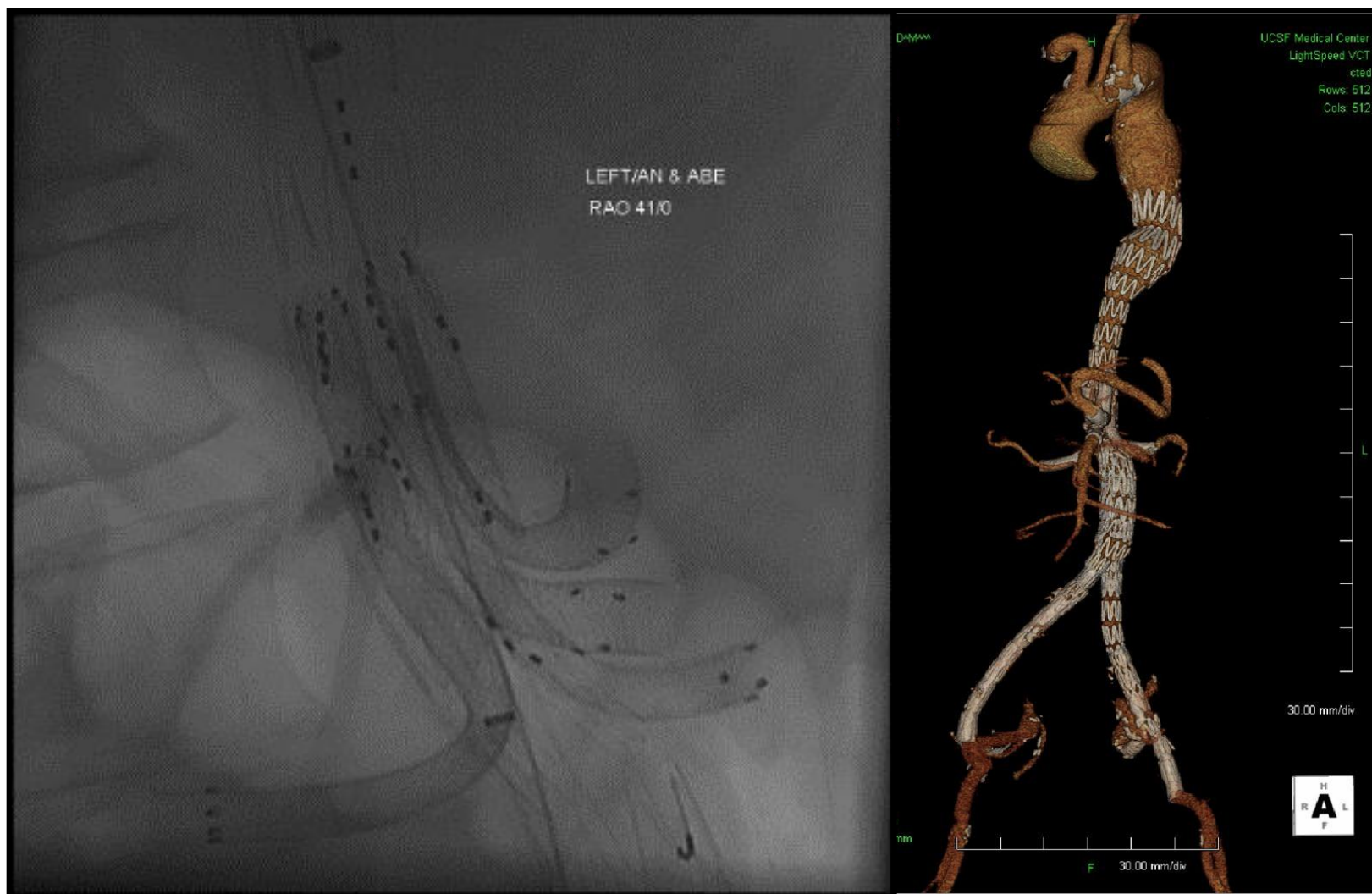


# Tim Chuter, UCSF

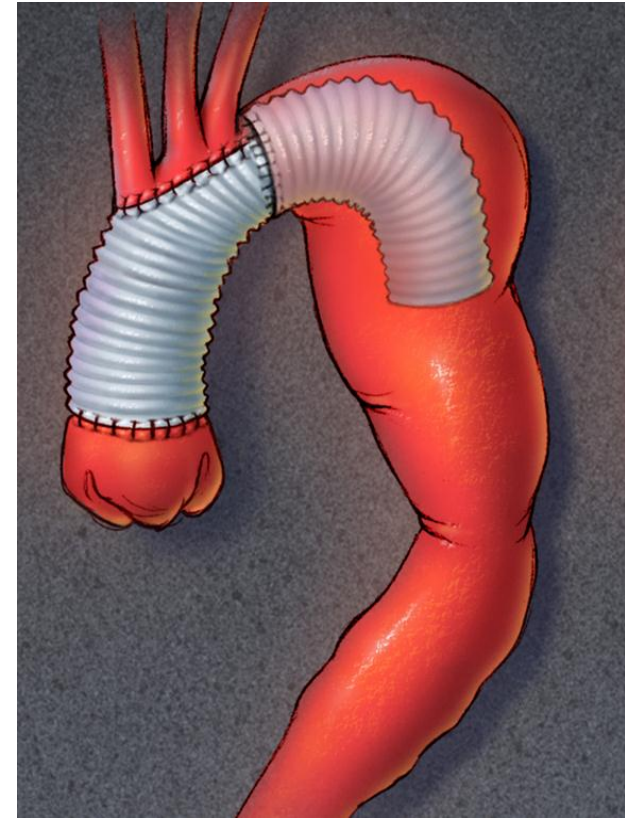
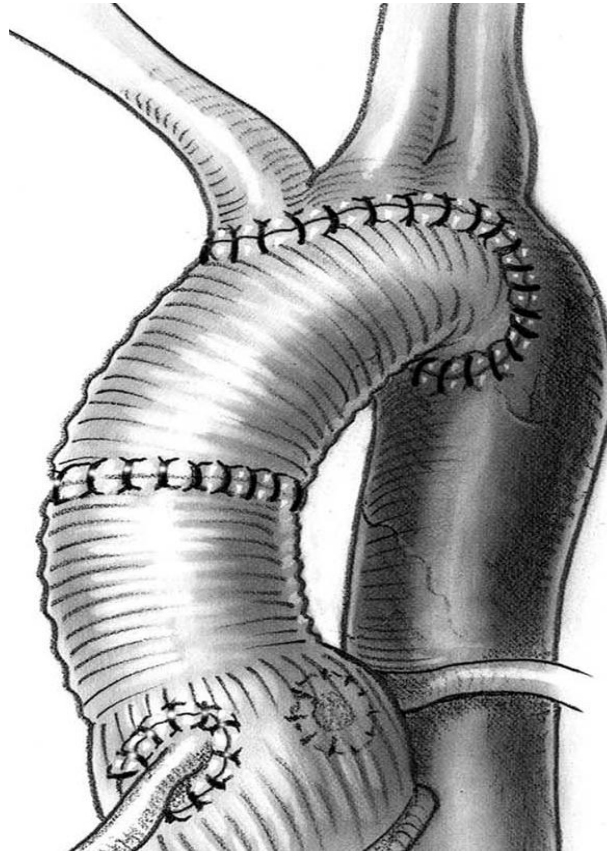
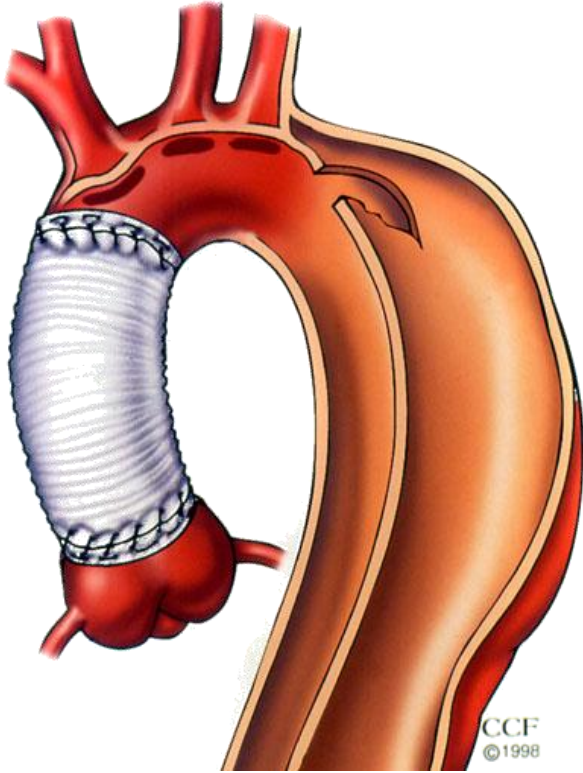
## 4-BRANCH Endograft



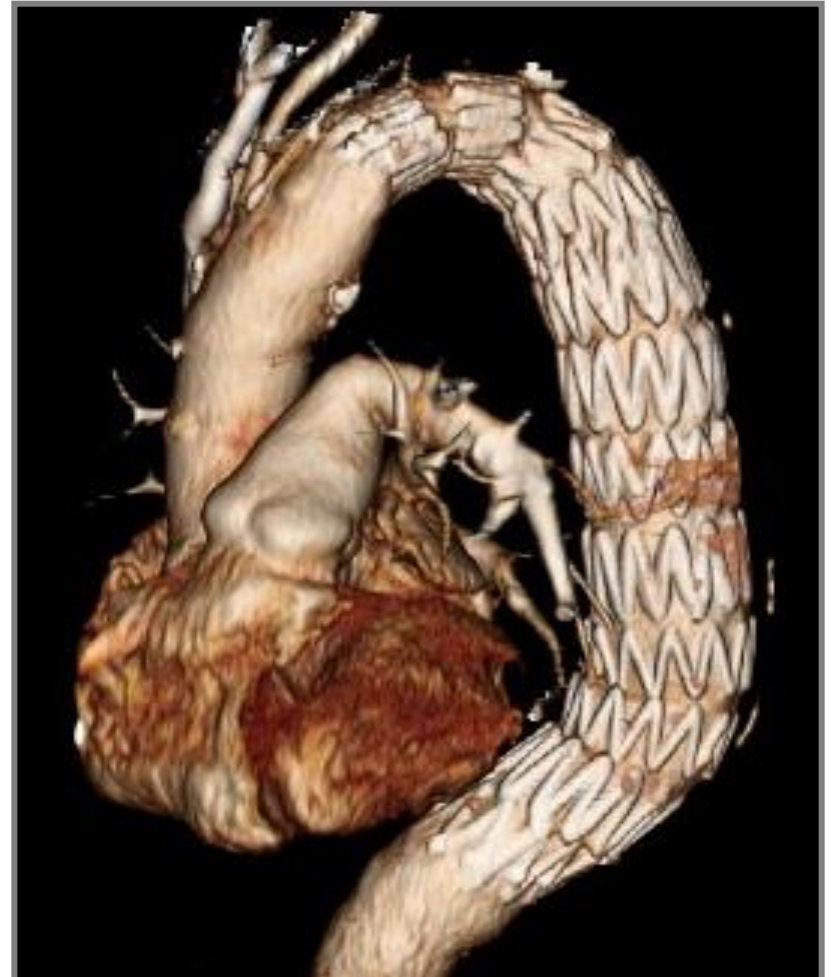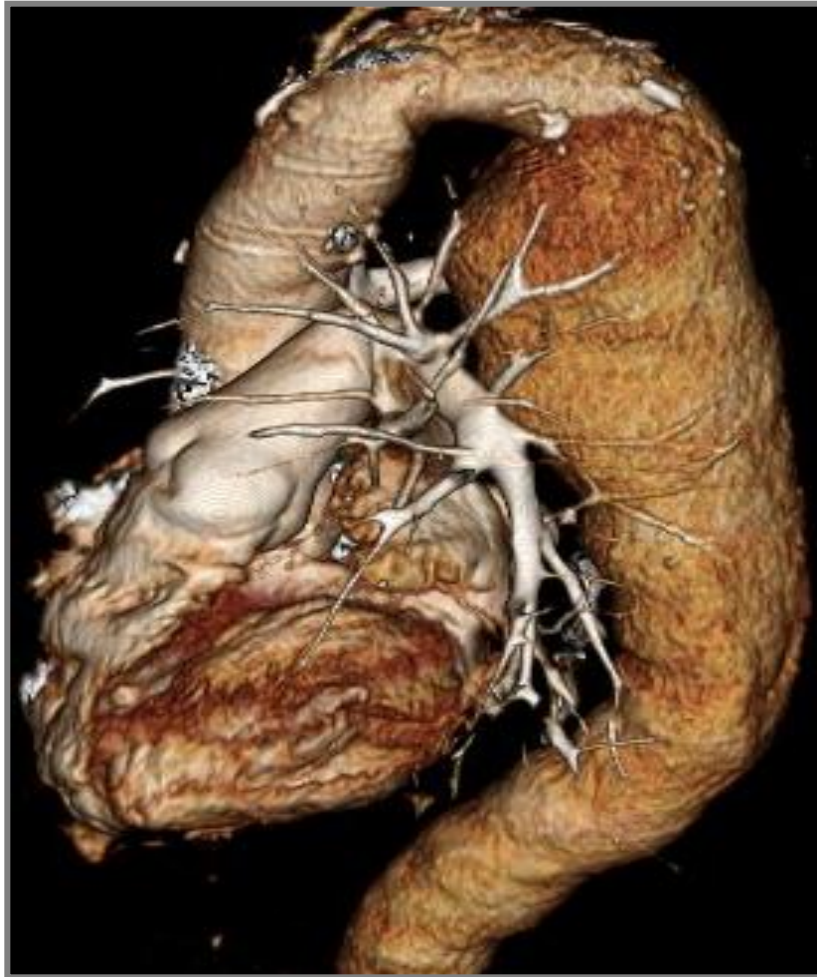




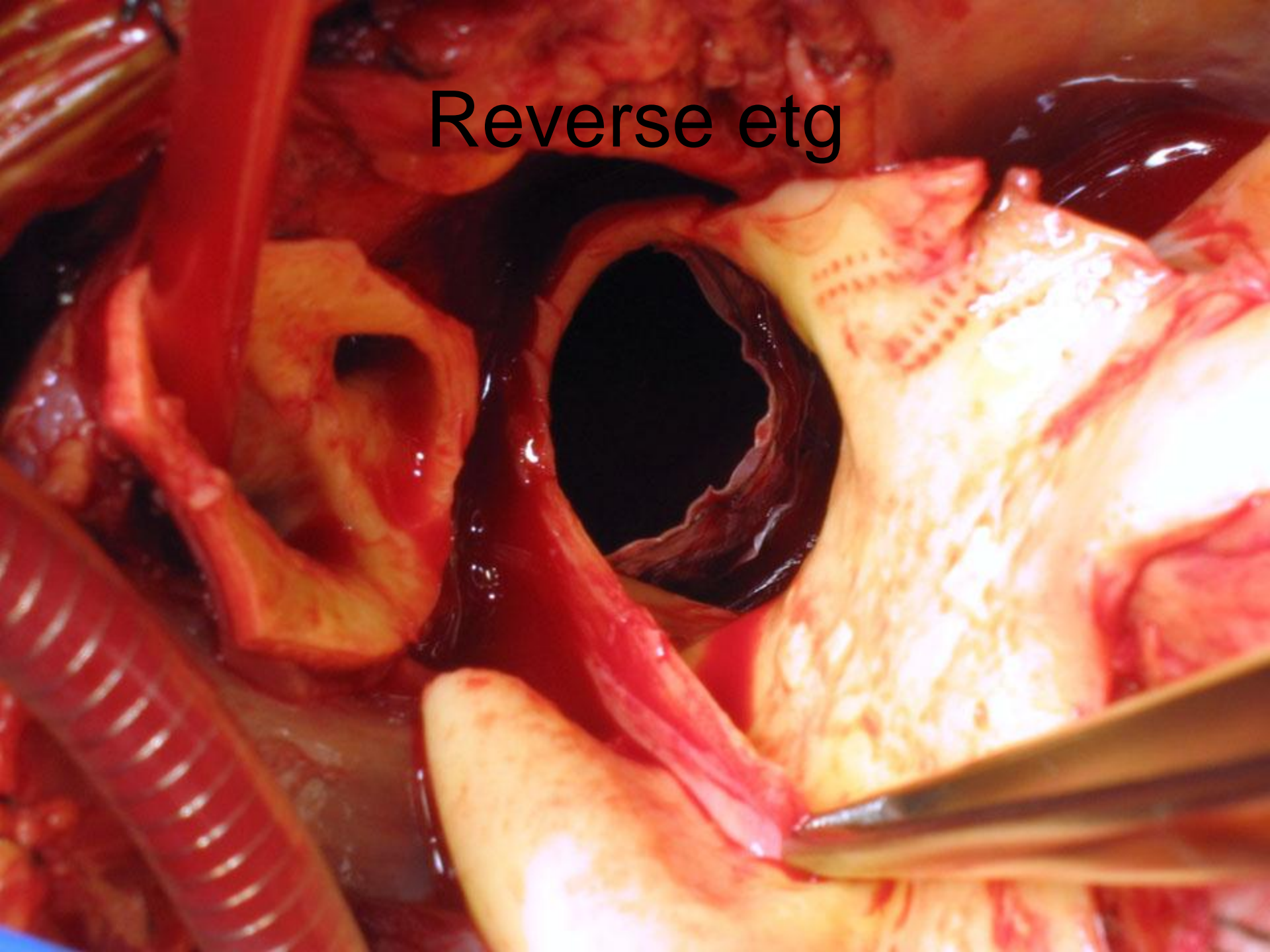
# Proximal Sealing Open Surgery Options

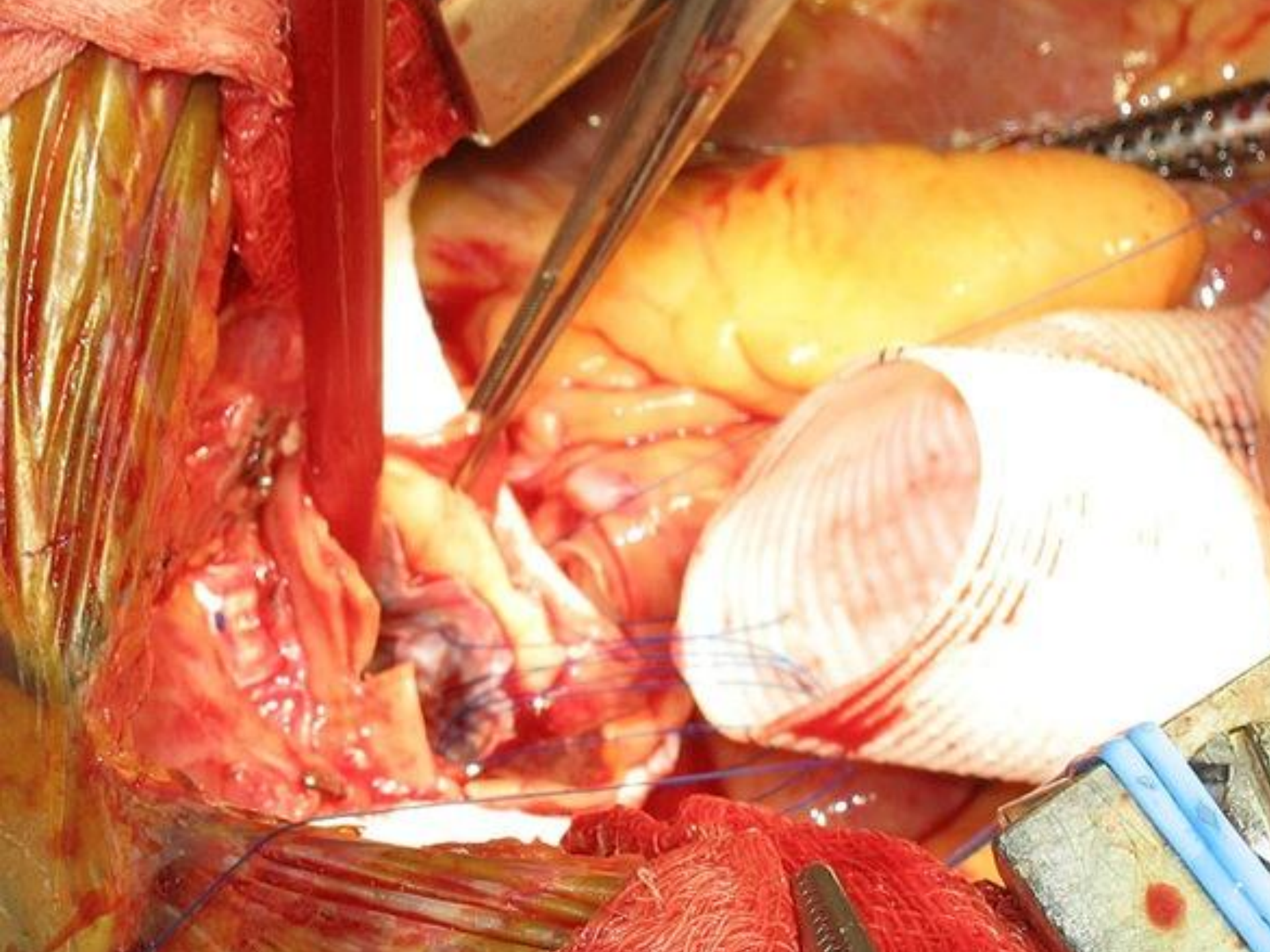


# ELEPHANT TRUNK

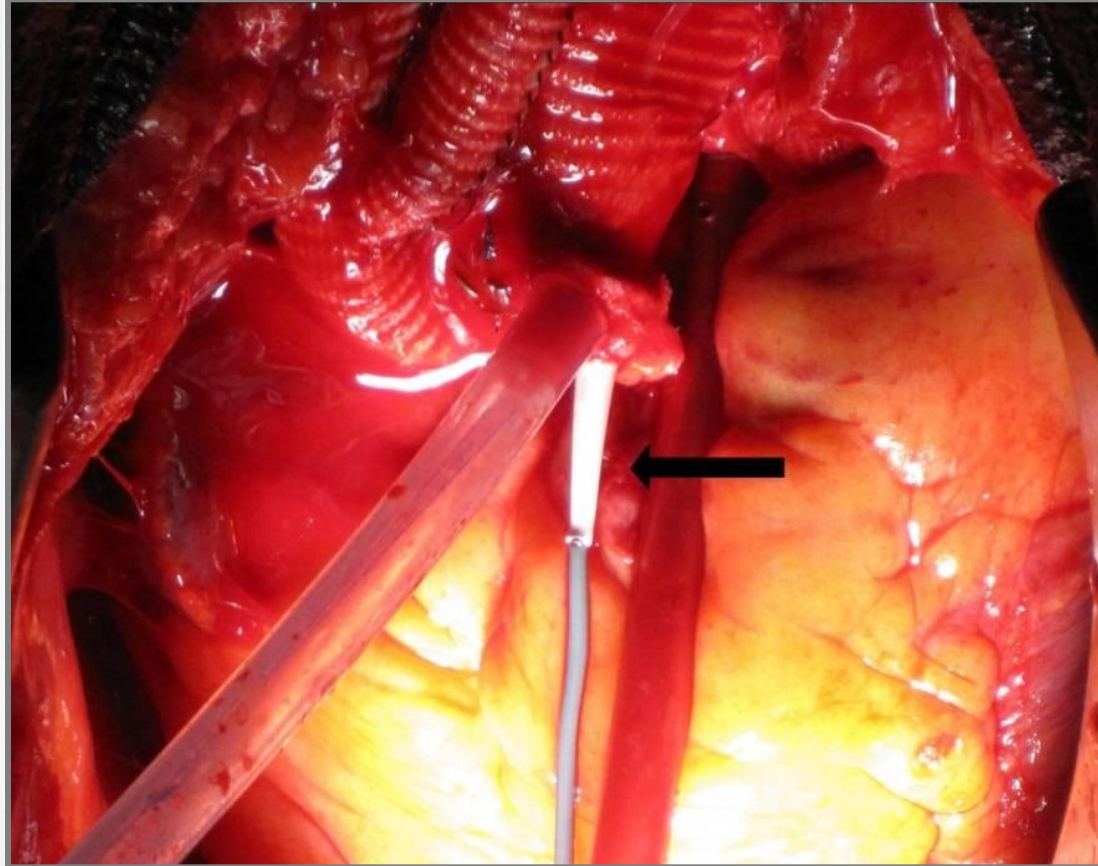
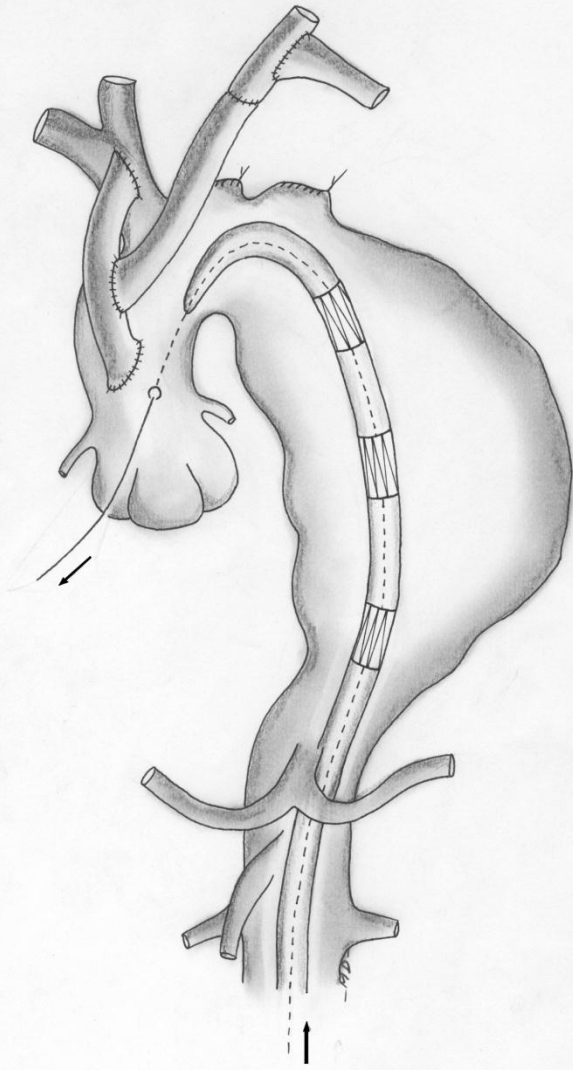


Reverse etg

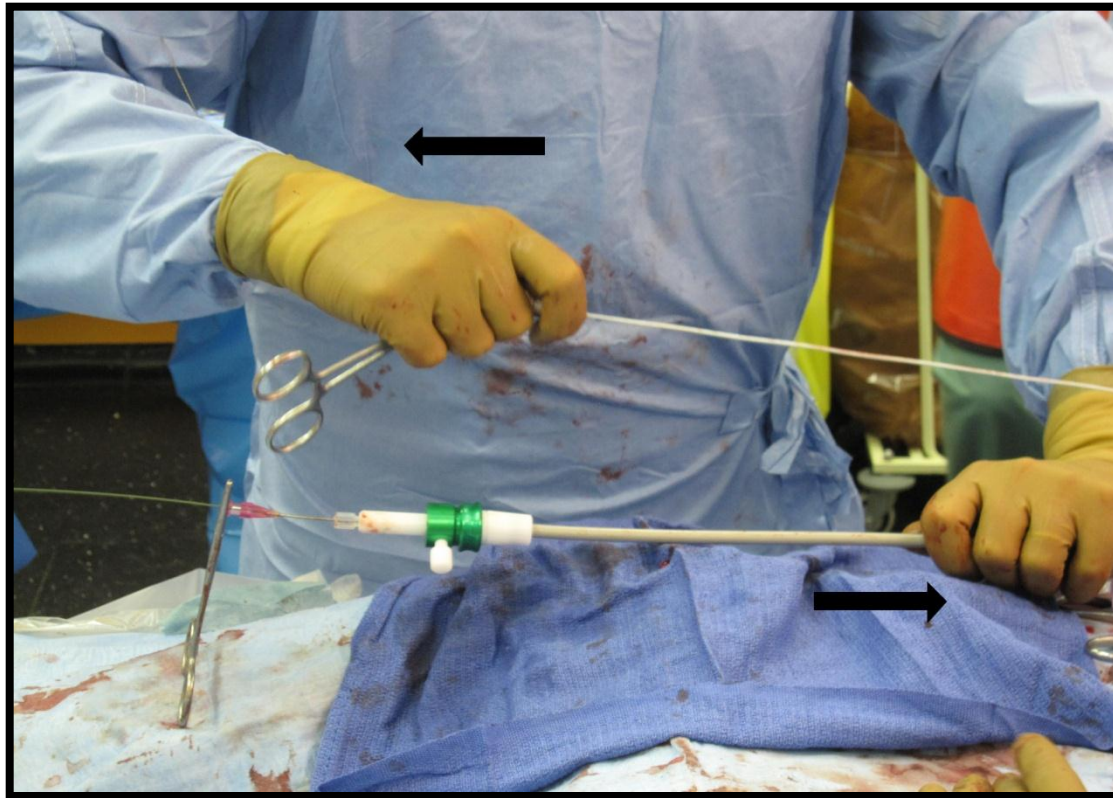




# HYBRID THROUGH AND THROUGH WIRE

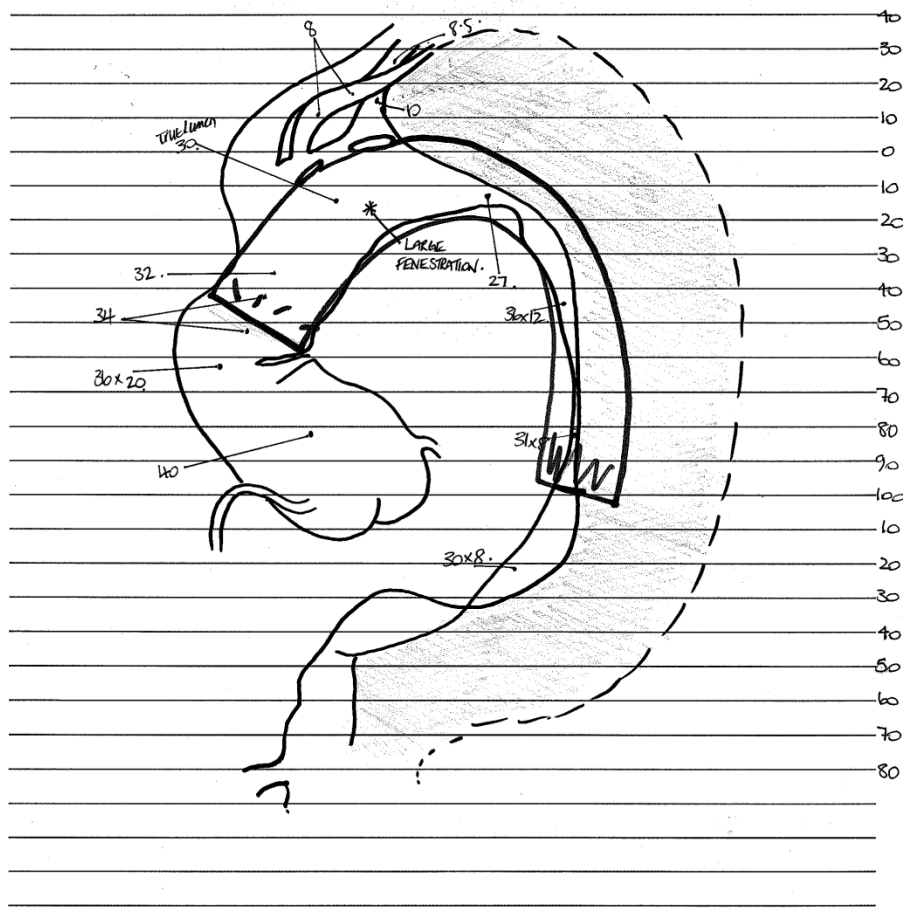


- Graft is advanced from the left femoral artery
- «Push-and-pull technique»



PHYSICIAN: Prof HALLON

100

[illegible]

DIAMETER: 8mm  
DIST FROM PROX EDGE: 12:30  
CLOCK: 48mm  
IVD: 30mm

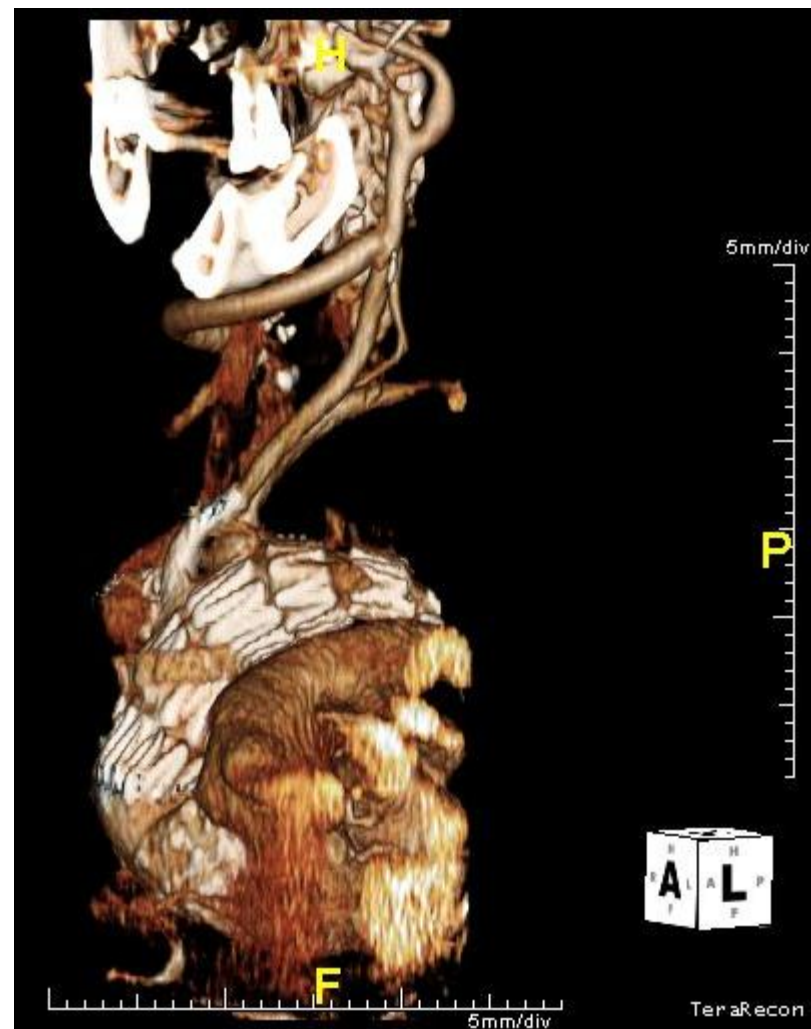
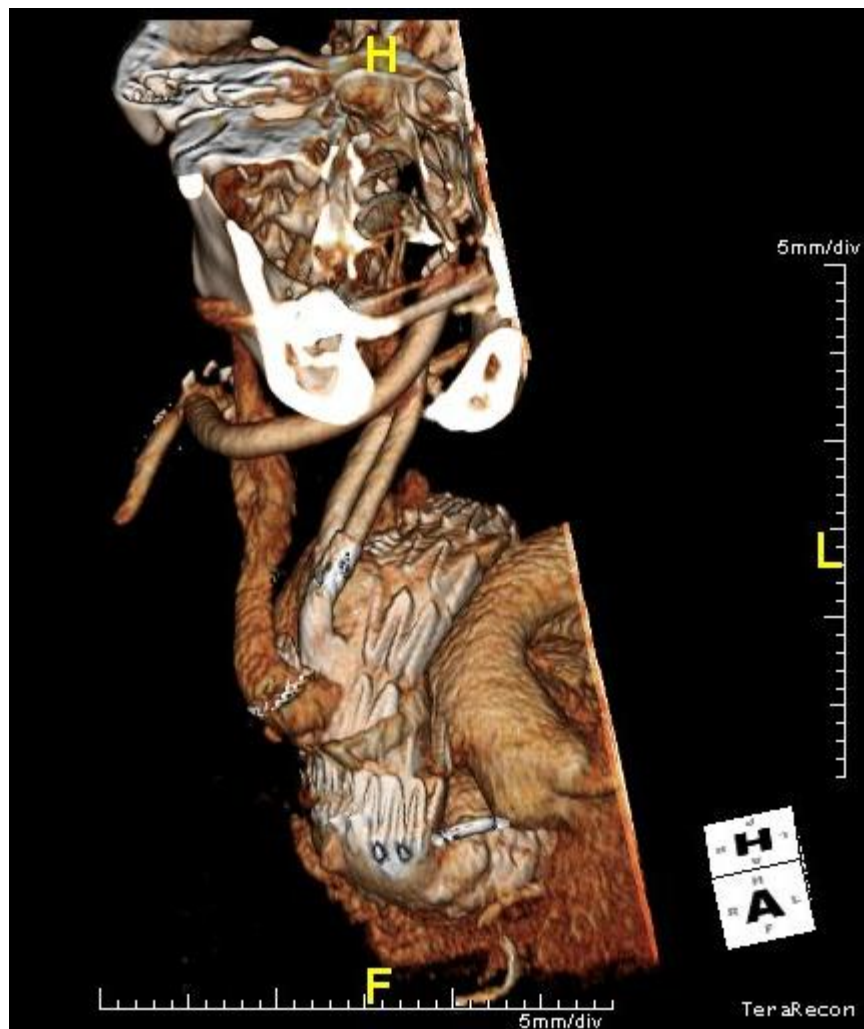\*\*\*Strut Free\*\*\*  
 \*\*\*Profoundly Comfortable & Winging\*\*\*  
 DIAMETER: 8mm  
 DIST FROM PROX EDGE: 65mm  
 CLOCK: 12x45  
 IVD: 30mm

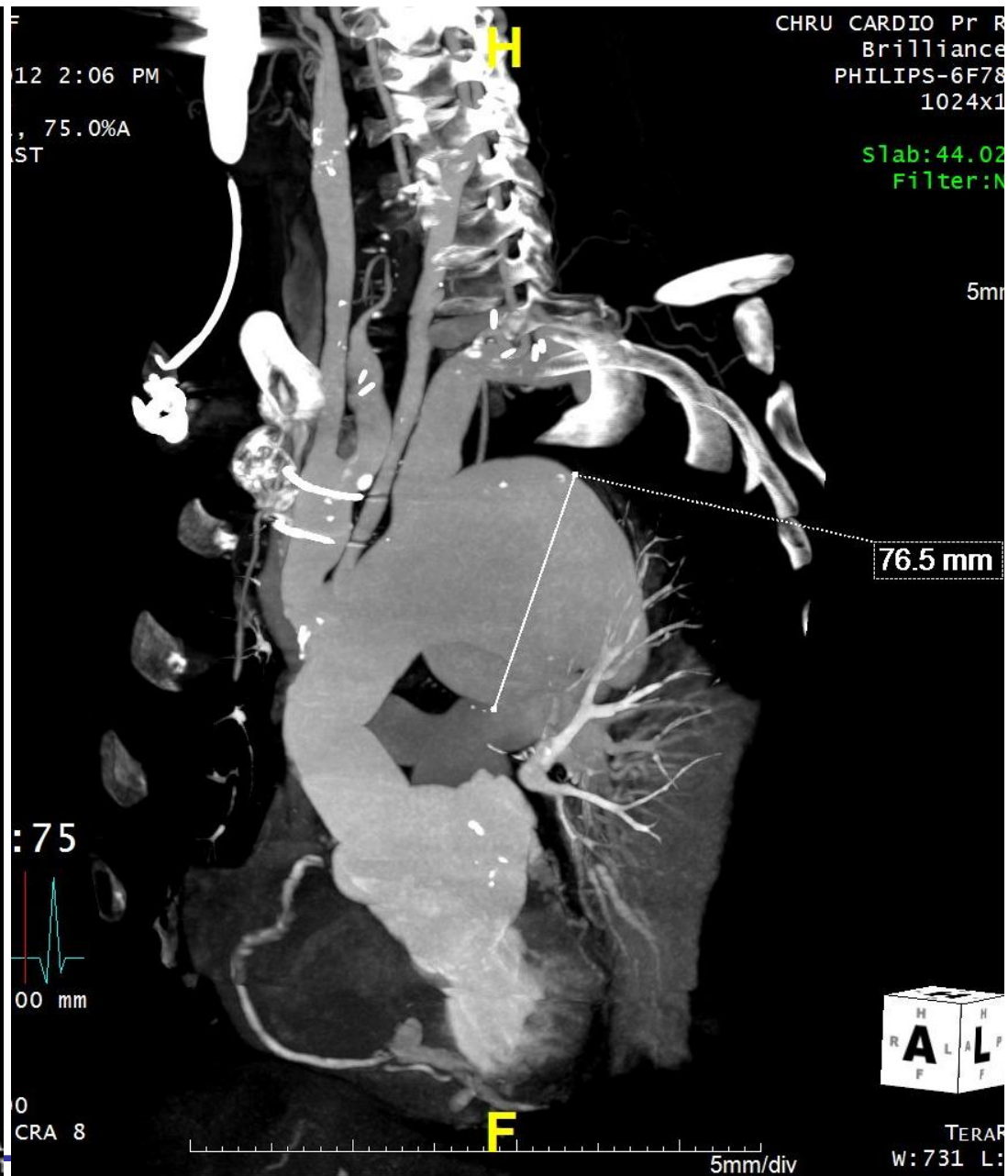
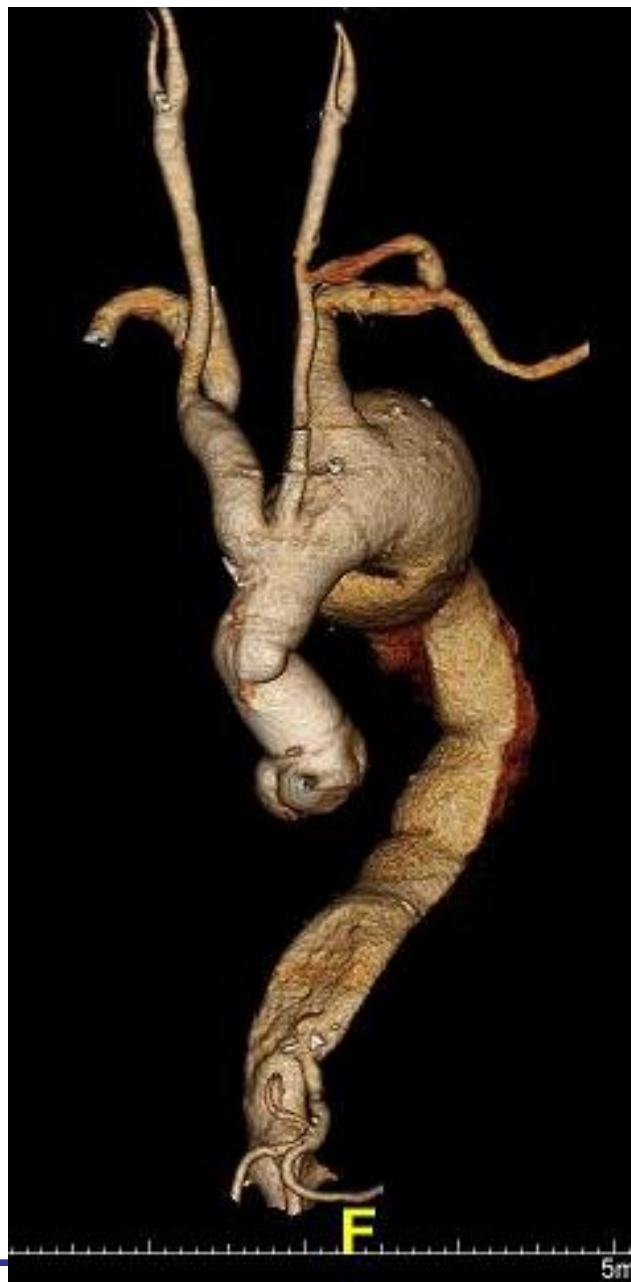- 60mm Introducer Tip with Orientation Notch
- Staged Release
- Gold Markers only as shown
- Curved Nitinol Cannula & Fimcor Sheath
- Spiral Attachment Wire

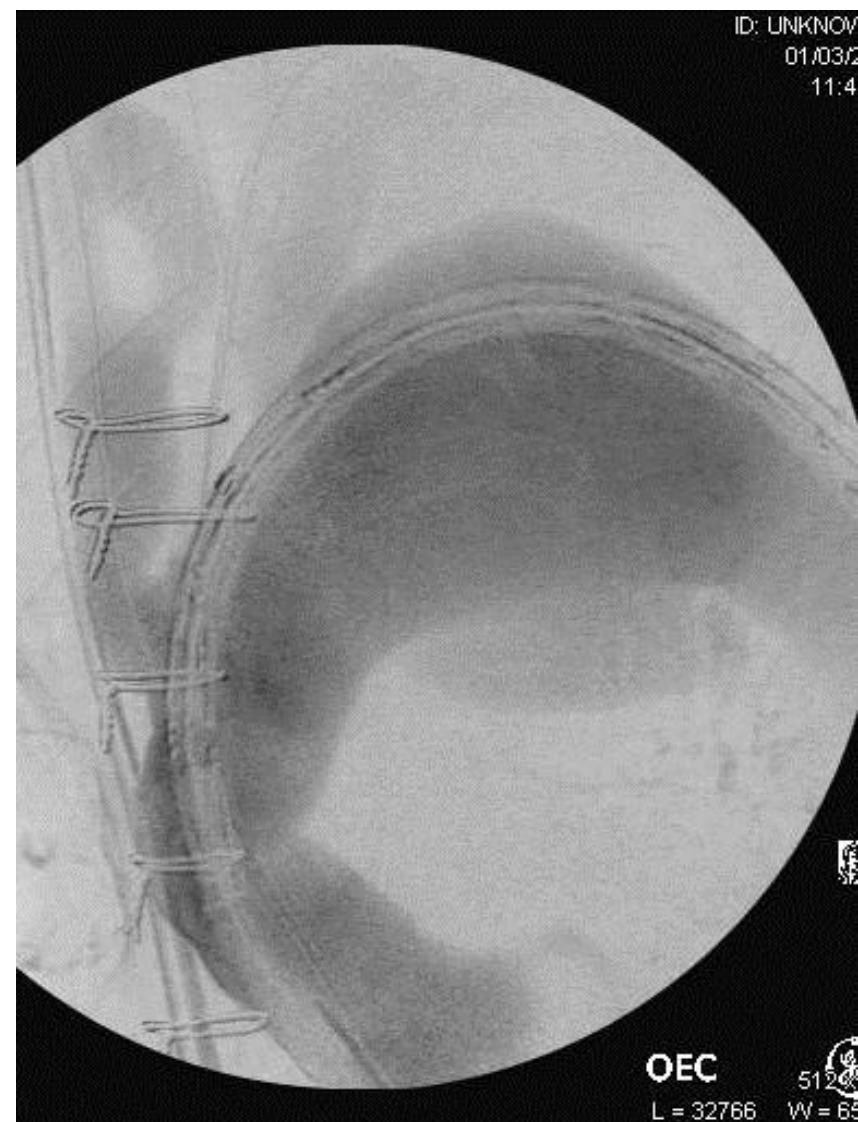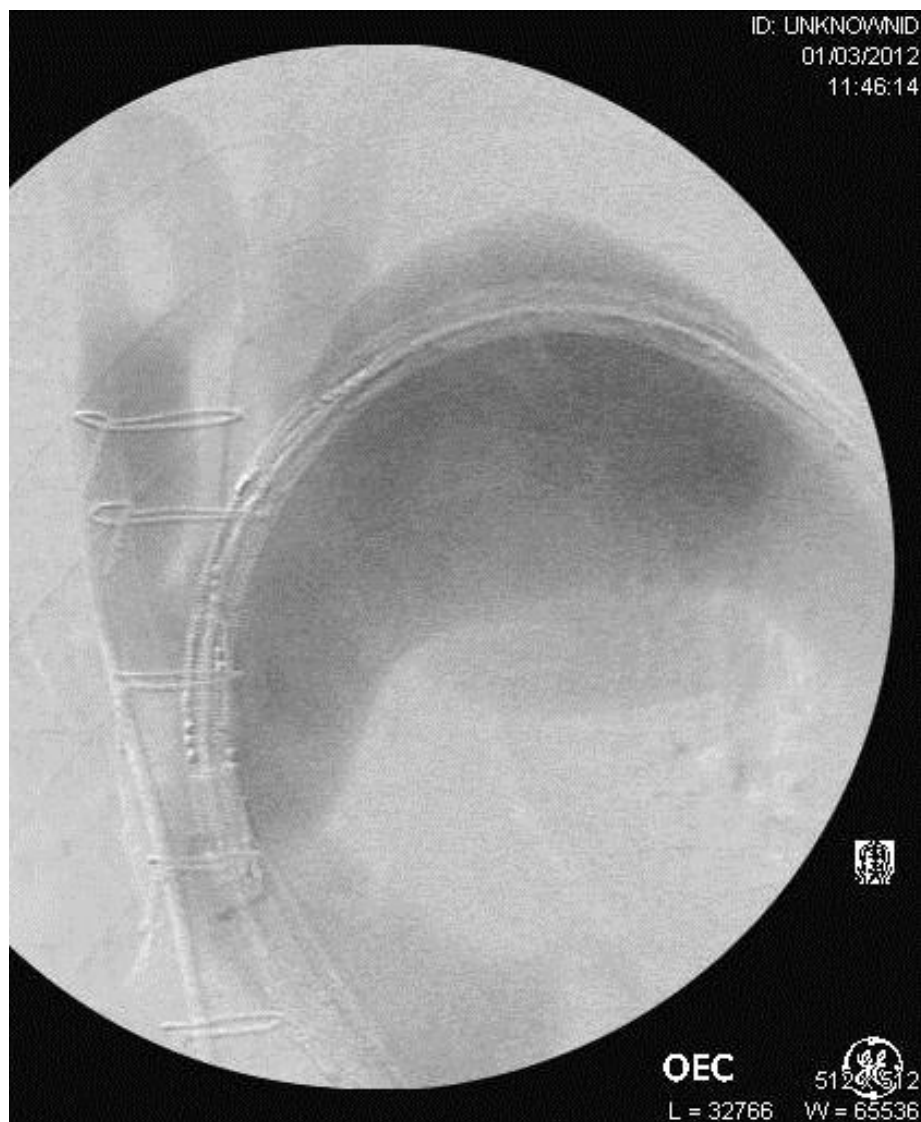Sheath Size:	24FR FLEXOR
O.D.:	8.1mm
Sheath Length:	75cm
Description:	PENETRATED TX GRAFT

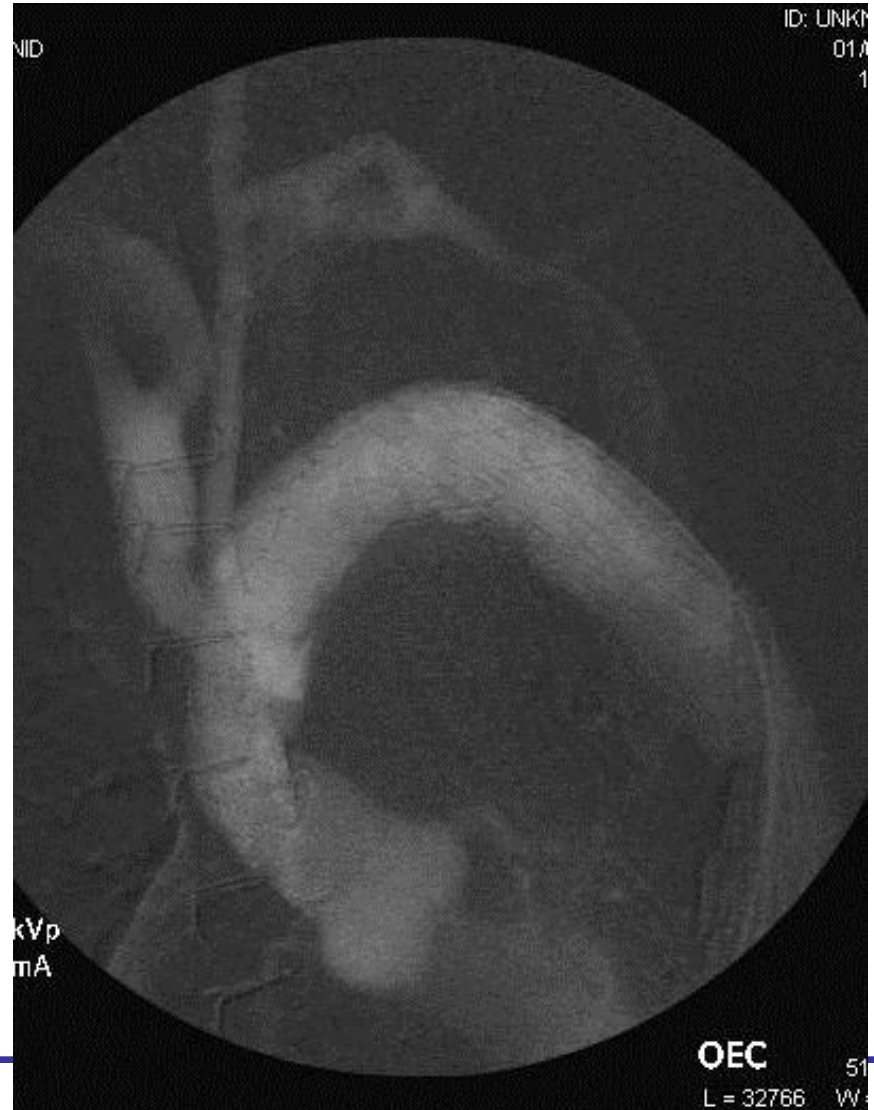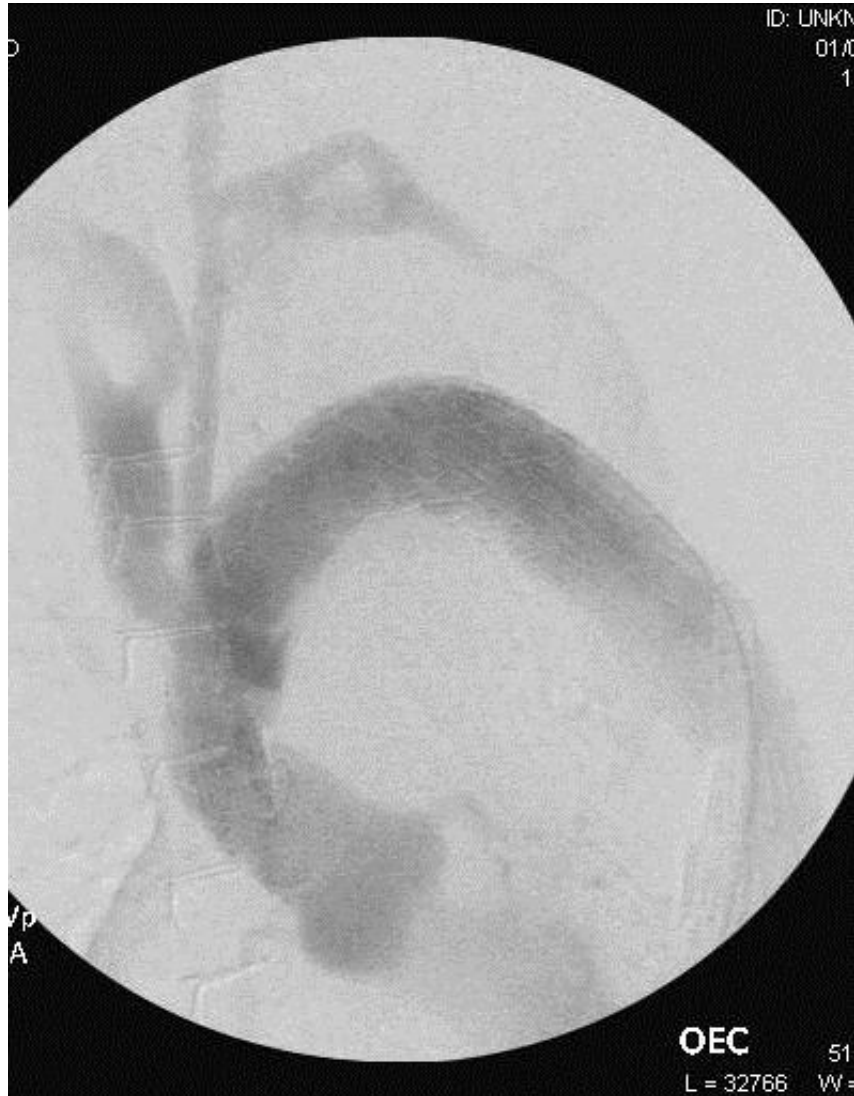Patient ID: \_\_\_\_\_  
 Doctor: \_\_\_\_\_  
 Hospital: \_\_\_\_\_  
 Date of Procedure: \_\_\_\_\_  
 Drs Signature: \_\_\_\_\_ Date: \_\_\_\_\_

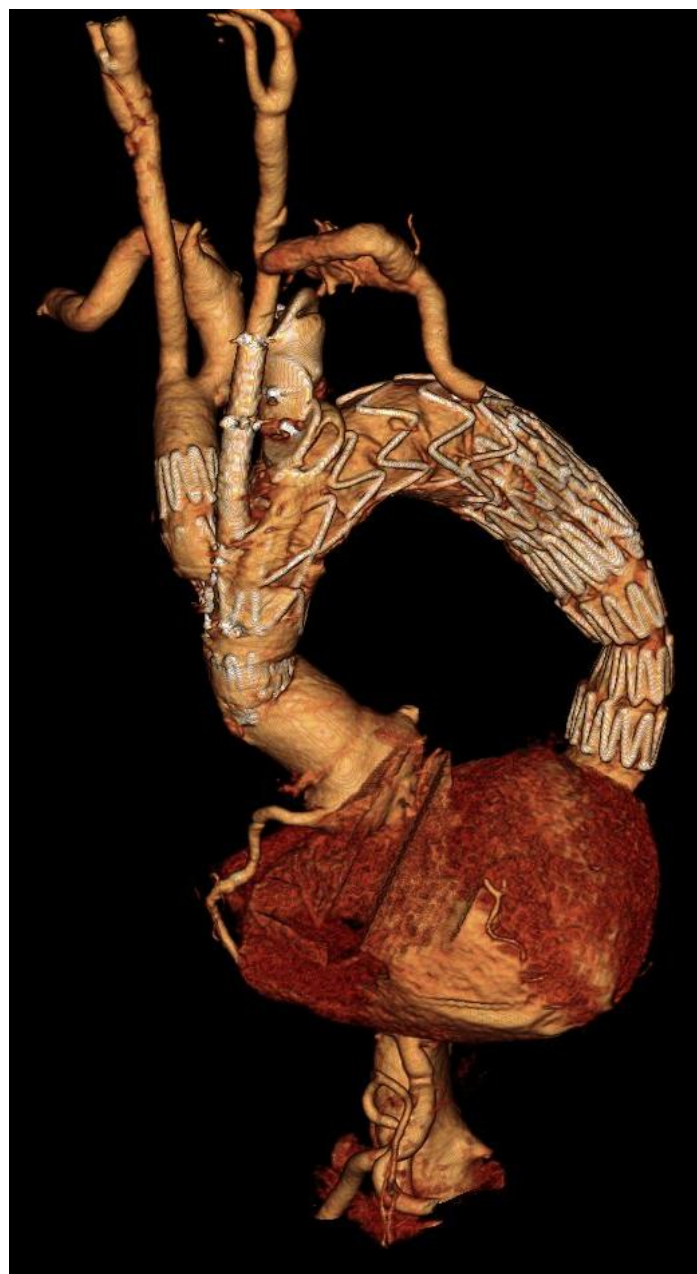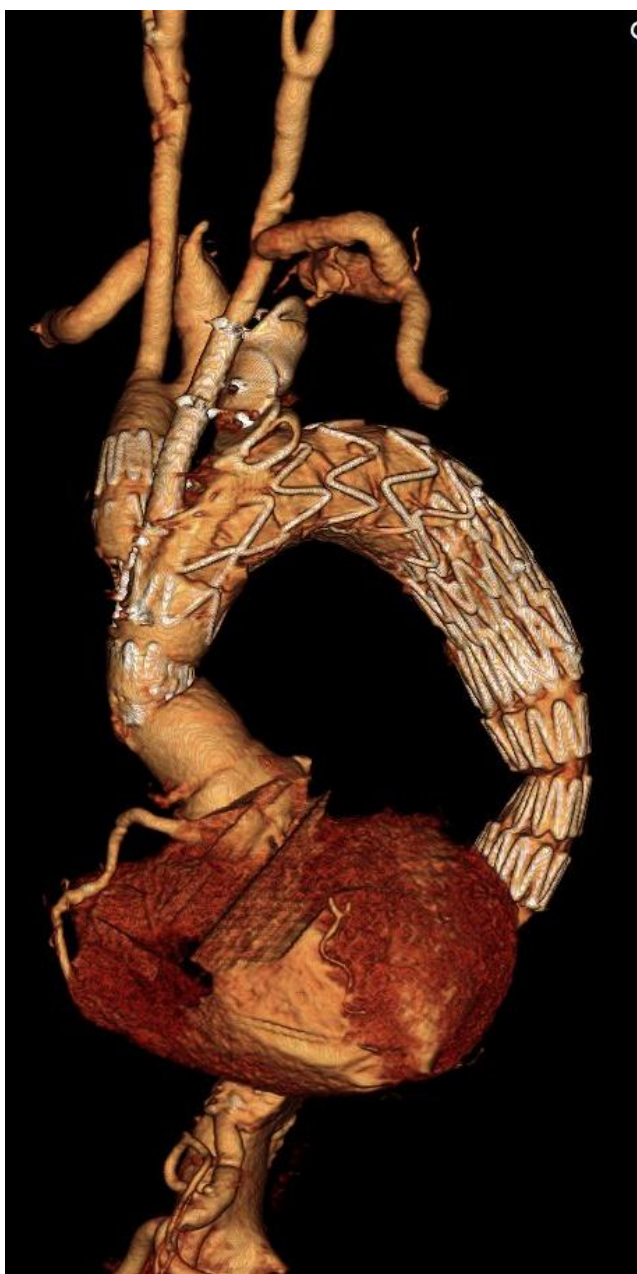ALL DIMENSIONS IN mm	NOT to scale if listed	Date: 11-Feb-10
----------------------	------------------------	-----------------











# CONCLUSIONS

- Branches or fenestrations?
- Staged procedures
- Limited experience

