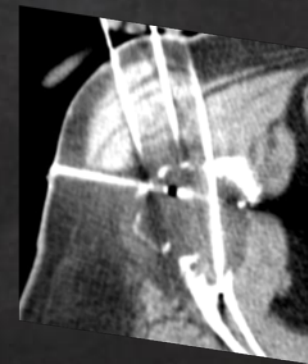
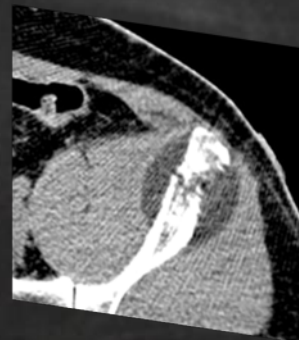
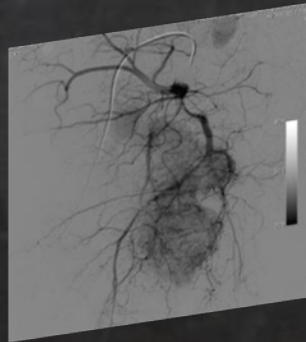
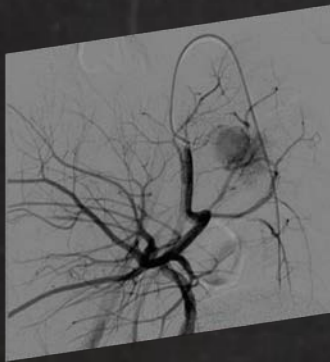
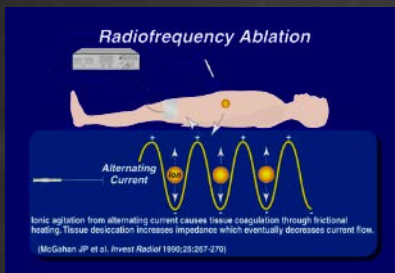


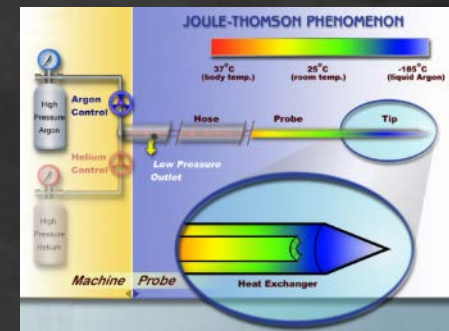
Techniques combinées du squelette axial: embolisation et ablation percutanée

F.Bing, J.Garnon, E. Boatta, G.Tsoumakidou,
MA Thenint, A. Gangi





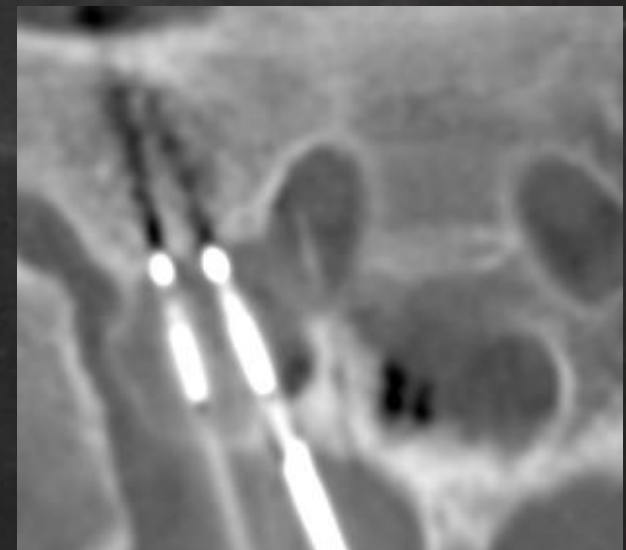
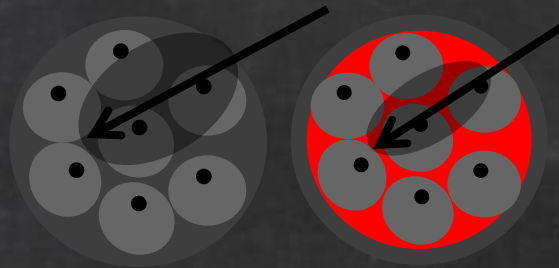
Contexte

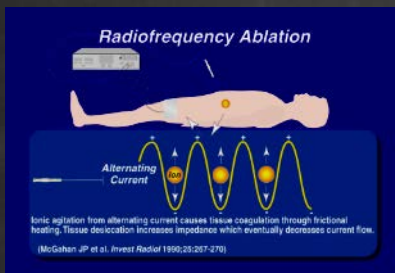


Finalité de l'ablation percutanée:

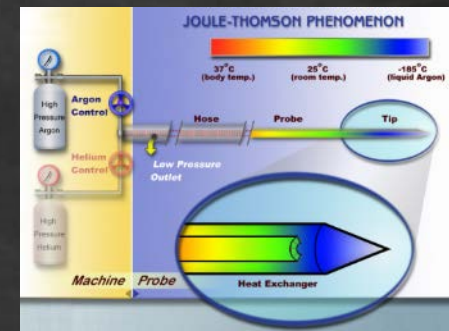
- Traitement curatif des lésions osseuses primitives
- Traitement palliatif des métastases osseuses

Limites de l'ablation percutanée: lésions hypervasculaires





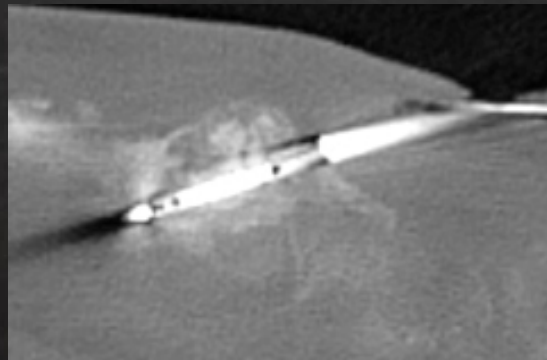
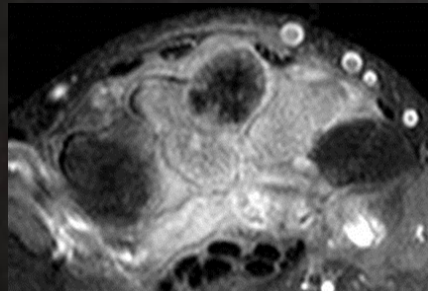
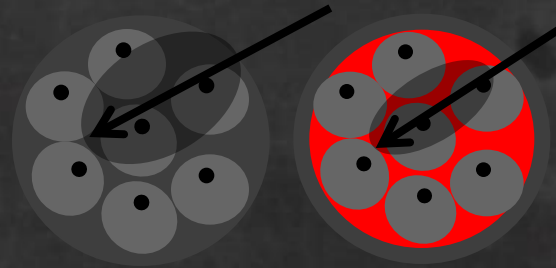
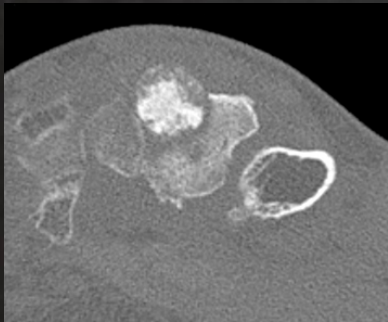
Contexte

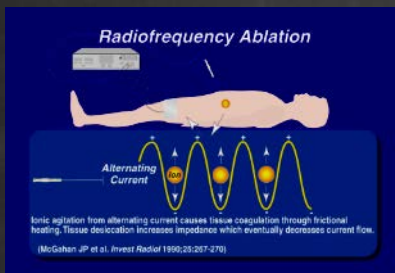


Finalité de l'ablation percutanée:

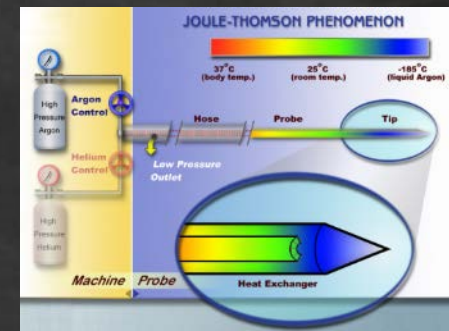
- Traitement curatif des lésions osseuses primitives
- Traitement palliatif des métastases osseuses

Limites de l'ablation percutanée: lésions hypervasculaires





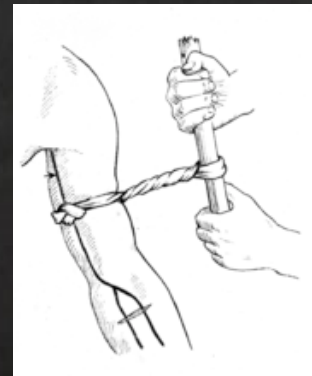
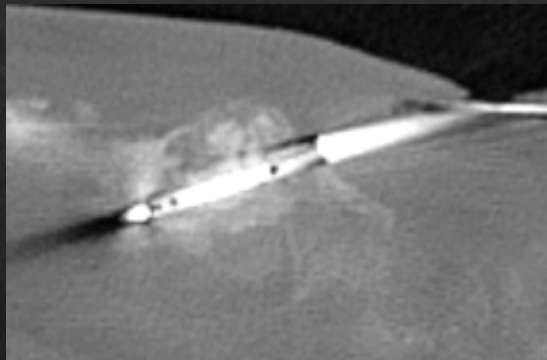
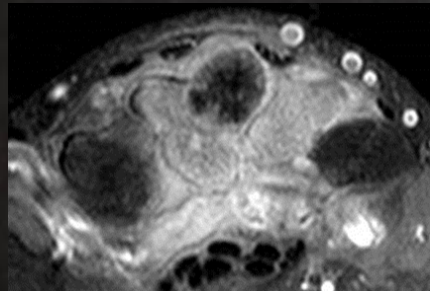
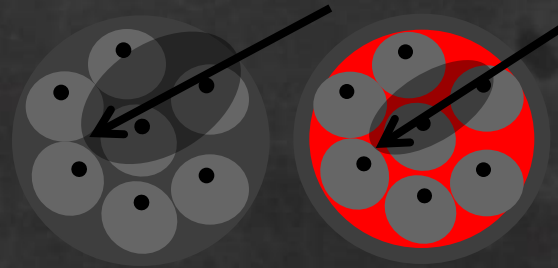
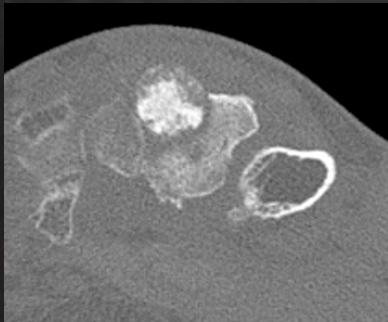
Contexte

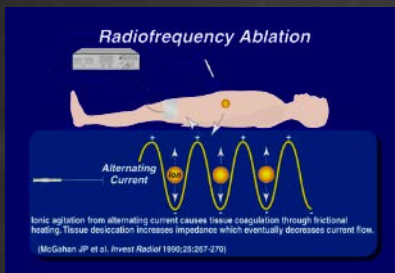


Finalité de l'ablation percutanée:

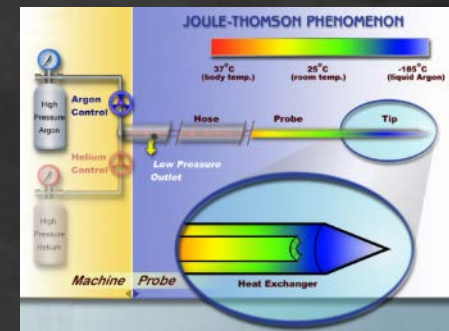
- Traitement curatif des lésions osseuses primitives
- Traitement palliatif des métastases osseuses

Limites de l'ablation percutanée: lésions hypervasculaires





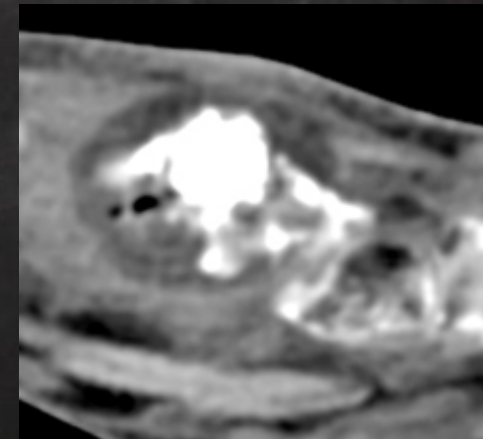
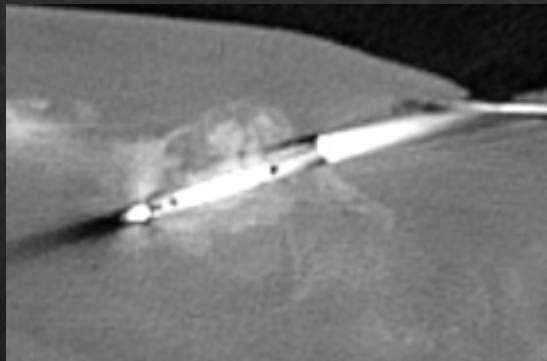
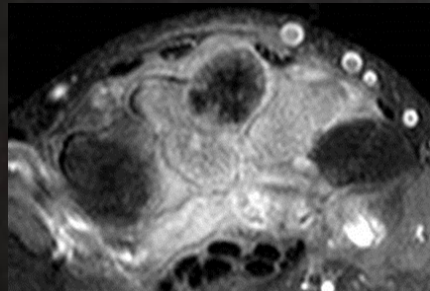
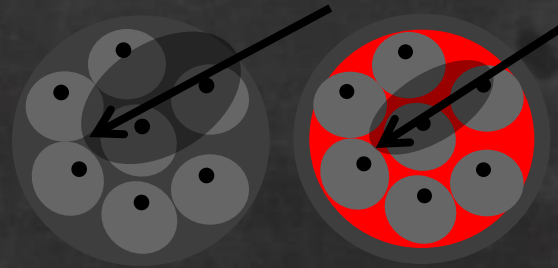
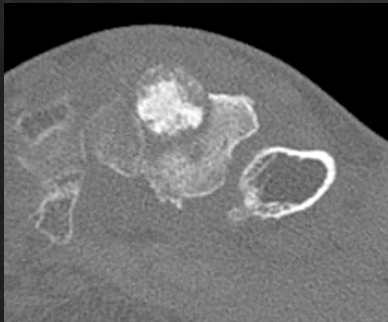
Contexte

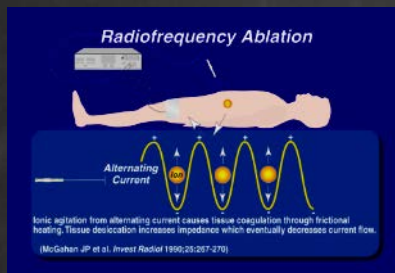


Finalité de l'ablation percutanée:

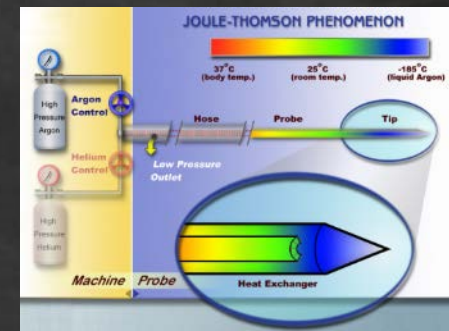
- Traitement curatif des lésions osseuses primitives
- Traitement palliatif des métastases osseuses

Limites de l'ablation percutanée: lésions hypervasculaires





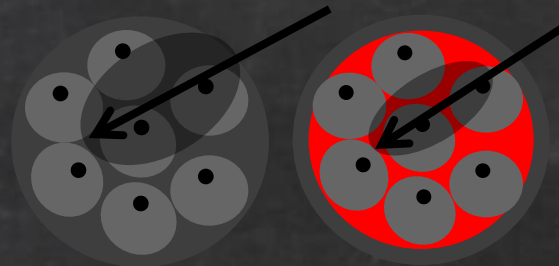
Contexte



Finalité de l'ablation percutanée:

- Traitement curatif des lésions osseuses primitives
- Traitement palliatif des métastases osseuses

Limites de l'ablation percutanée: lésions hypervasculaires



Embolisation ou chimioembolisation des métastases hypervasculaires

Rossi et al. *Radiol Med.* 2013 Koike et al. *CVIR* 2011

Potentialisation de l'action carcinologique de l'ablation par l'embolisation

Pellerin O et al. *CVIR* 2013
Lee et al. *Interv Neuroradiol.* 2013

Objectif

Rapporter notre expérience concernant les techniques combinées associant embolisation et ablation percutanée des lésions hypervasculaires primitives ou secondaires douloureuses du squelette axial

Matériel et méthode

- Six patients (âge moyen 42,4 ans) présentant:
 - angiome sacré agressif
 - ostéoblastomes (n=2)
 - métastases hypervasculaires:
 - thyroïdiennes
 - rénales (n=2)
 - neuro-endocrines

Matériel et méthode

- Six patients (âge moyen 42,4 ans) présentant:
 - angiome sacré agressif
 - ostéoblastomes (n=2)
 - métastases hypervasculaires:
 - thyroïdiennes
 - rénales (n=2)
 - neuro-endocrines
- Traitement curatif
- Traitement palliatif
- Un traitement associant embolisation et ablation percutanée a été proposé (8 lésions traitées)
 - L'ablation percutanée était effectuée au plus tôt le lendemain de l'embolisation (2 patients ont été traités en un temps)

Age	Site	Tumeur	Technique post-embolisation	Résultats
18	Sacrum	Ostéoblastome	Cryothérapie	Pas de douleur
21	Sacrum	Ostéoblastome déjà traité par RF et cryo	Cryothérapie	Pas de douleur

Age	Site	Tumeur	Technique post-embolisation	Résultats
18	Sacrum	Ostéoblastome	Cryothérapie	Pas de douleur
21	Sacrum	Ostéoblastome déjà traité par RF et cryo	Cryothérapie	Pas de douleur
32	Sacrum	Angiome agressif déjà traité par cimento et alcoolisation	Alcoolisation	Gène persistante

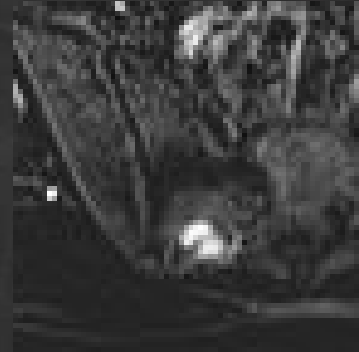
Age	Site	Tumeur	Technique post-embolisation	Résultats
18	Sacrum	Ostéoblastome	Cryothérapie	Pas de douleur
21	Sacrum	Ostéoblastome déjà traité par RF et cryo	Cryothérapie	Pas de douleur
32	Sacrum	Angiome agressif déjà traité par cimento et alcoolisation	Alcoolisation	Gène persistante
43	Aile iliaque	Tumeur neuro-endocrine	Cryothérapie vissage	Sans douleur à la marche
69	L3	Métastase rénale	Cryothérapie Cimento Radiothérapie	Diminution des douleurs Progression générale
65	Sacrum	Métastase thyroïde	Cryothérapie (3 séances)	Diminution des douleurs Progression générale

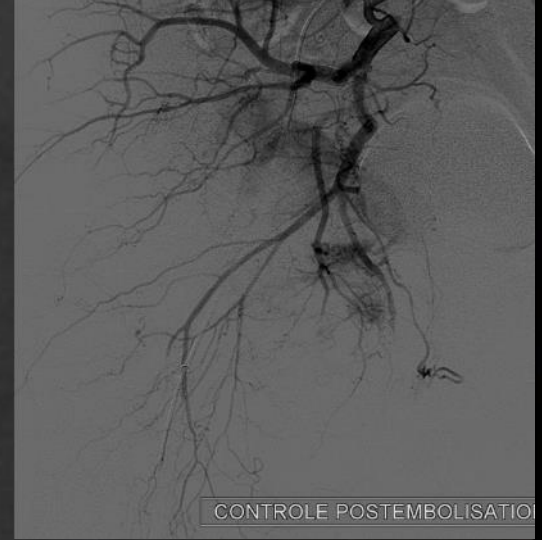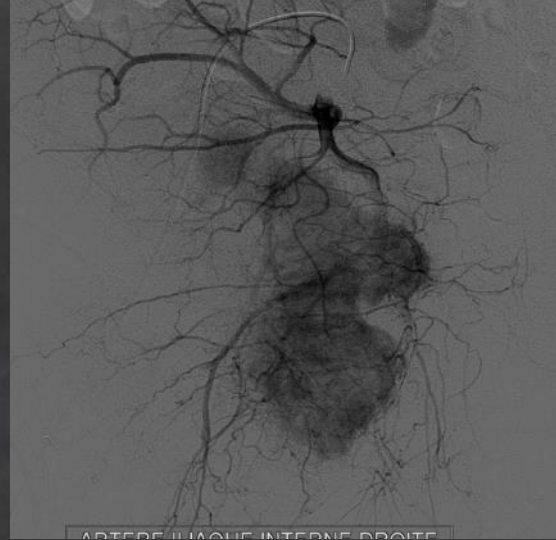
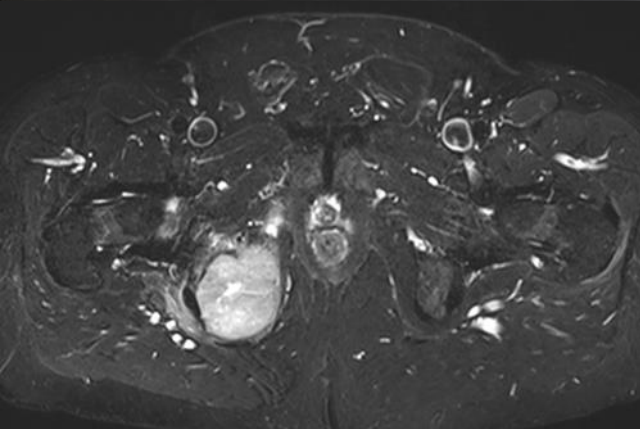
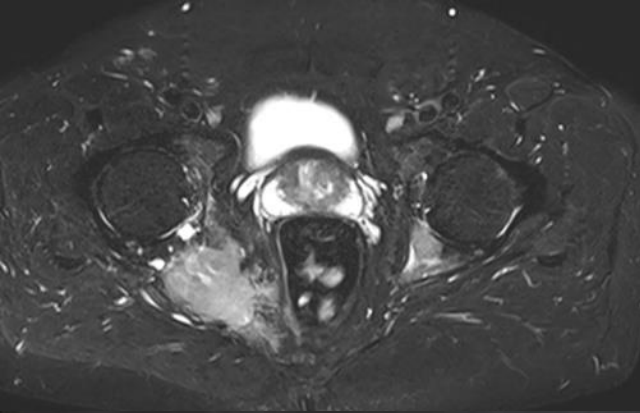
Résultats

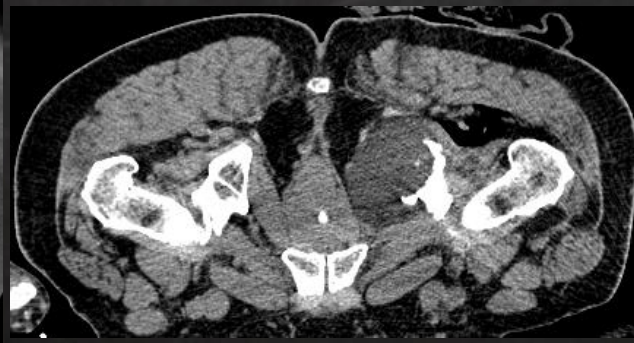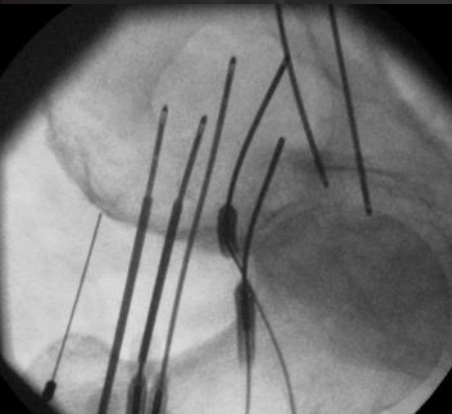
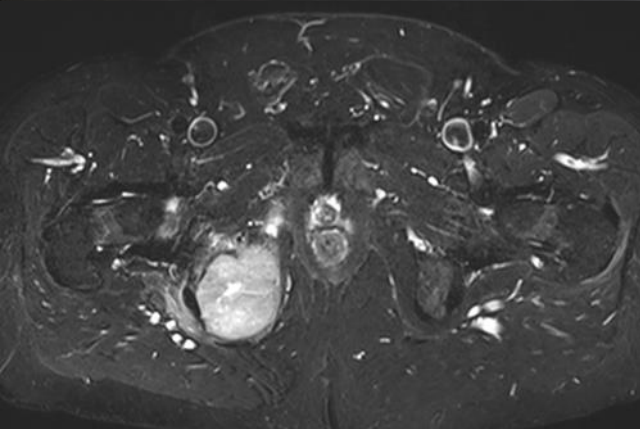
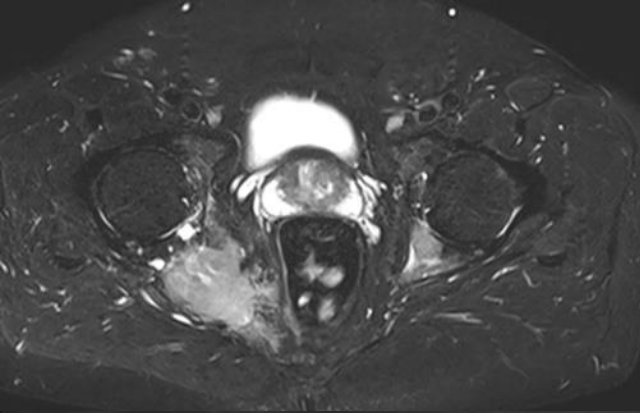
- Durée moyenne d'hospitalisation: 4.4 jours (2-12)

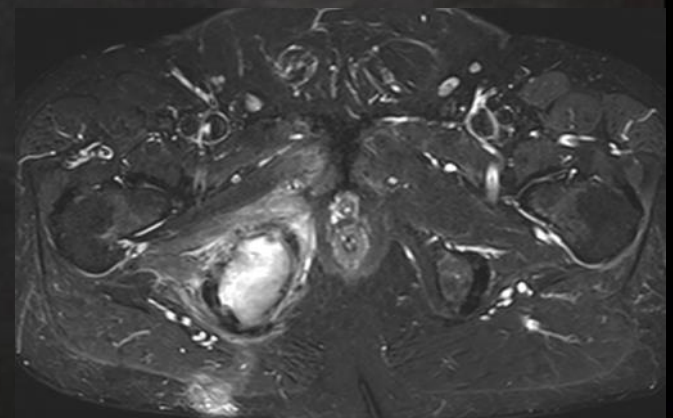
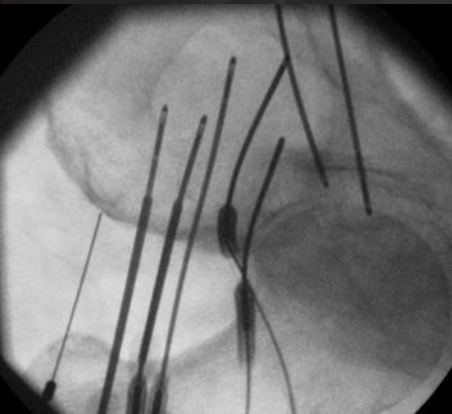
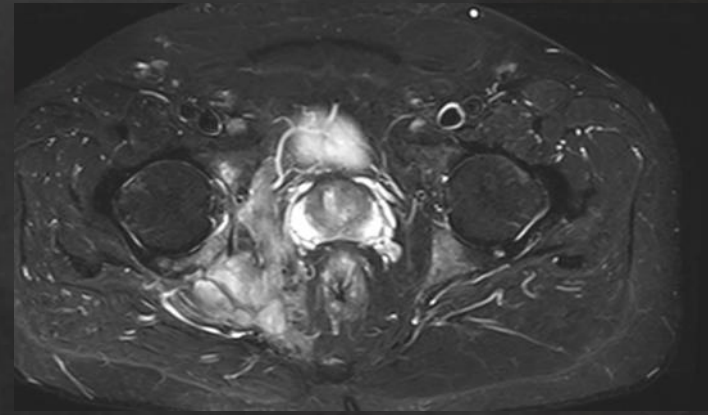
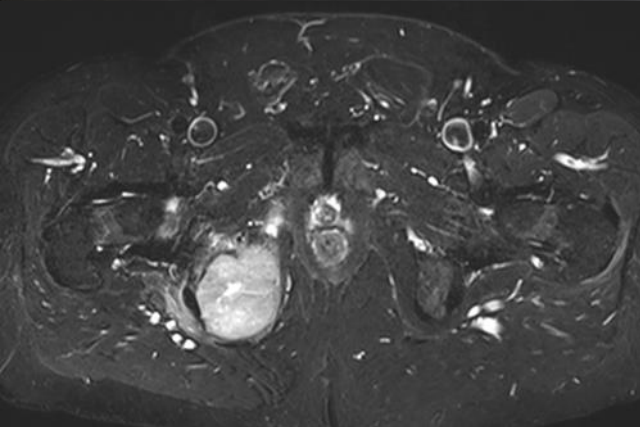
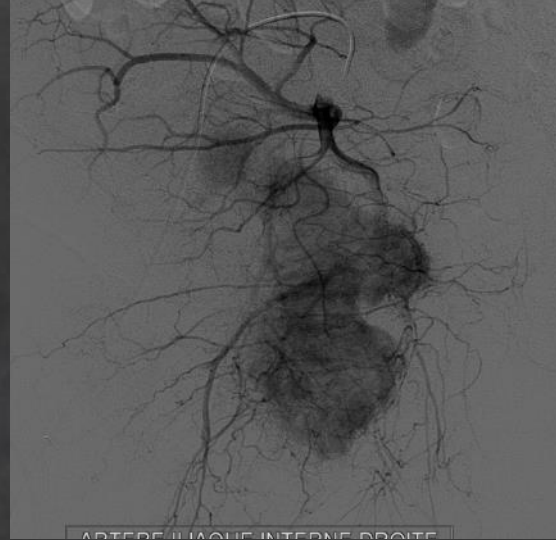
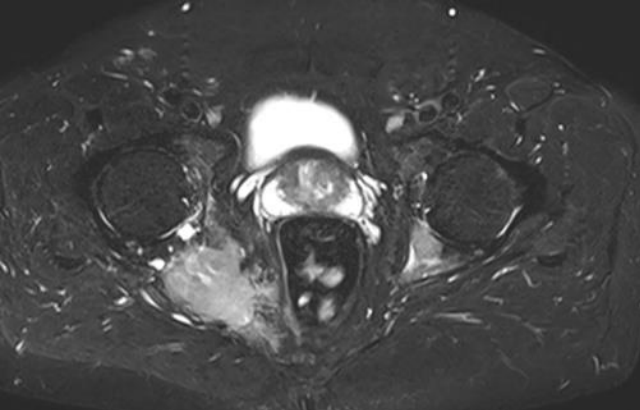
Résultats

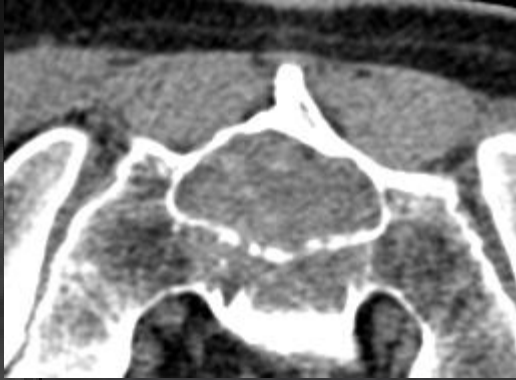
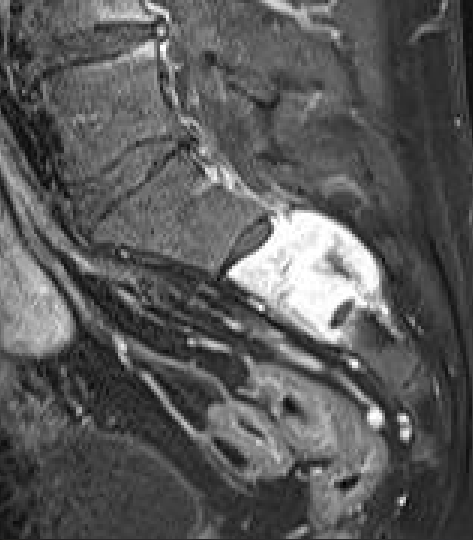
- Durée moyenne d'hospitalisation: 4.4 jours (2-12)
 - **Traitement curatif:**
 - succès clinique
 - possible reliquat dans un cas
 - **Traitement palliatif:**
 - contrôle de la douleur
 - contrôle local dans les trois cas
 - évolution générale dans les 3 cas (un décès)
- Complications: déficit sciatique réversible dans 2 cas

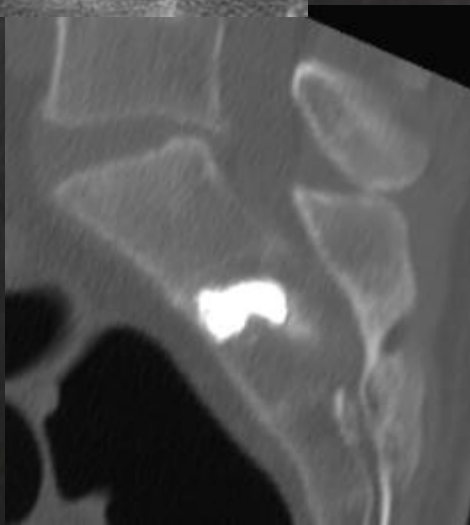
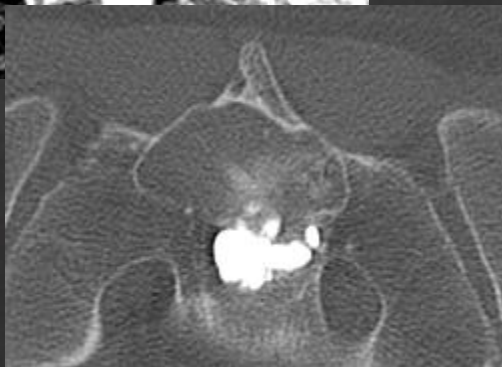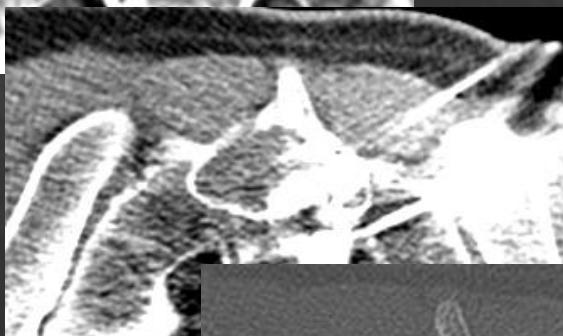
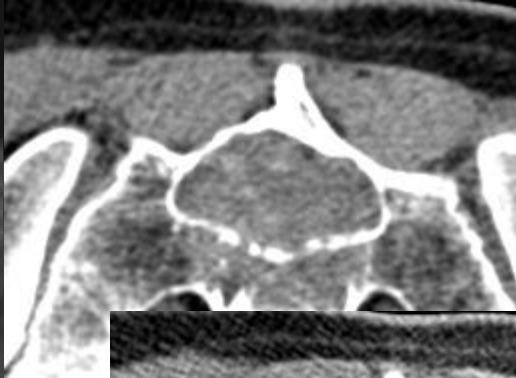
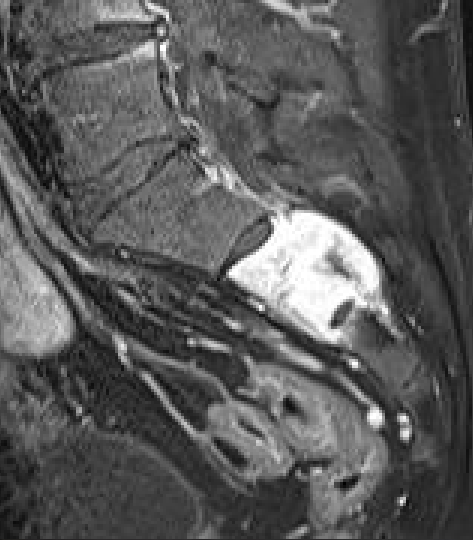


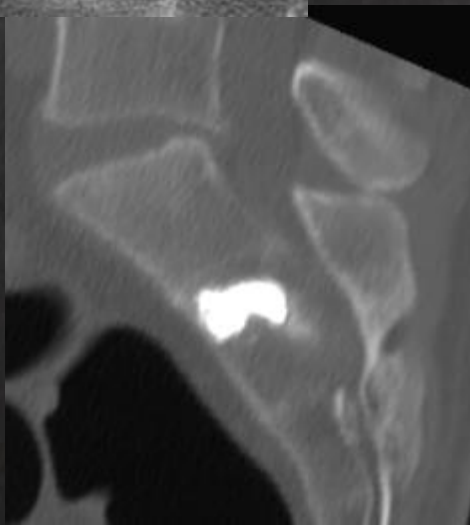
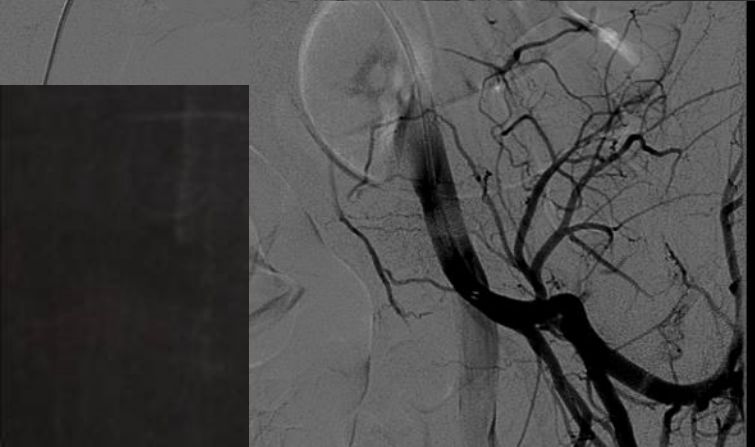
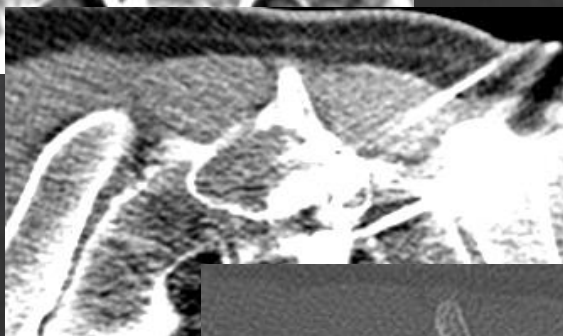
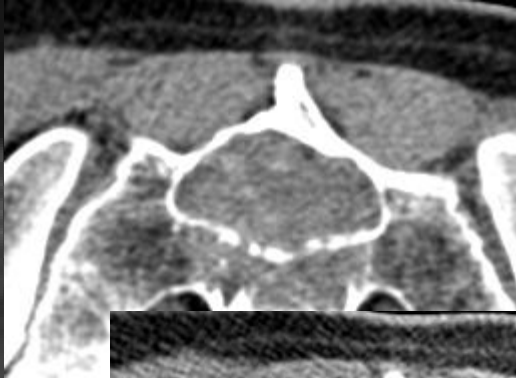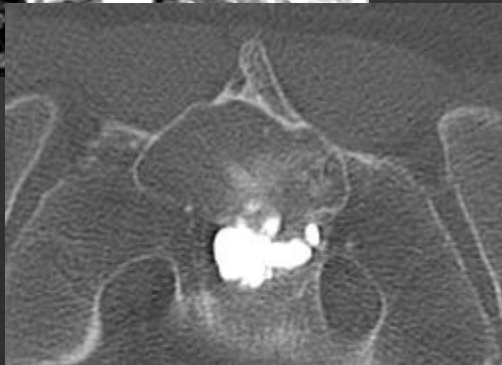
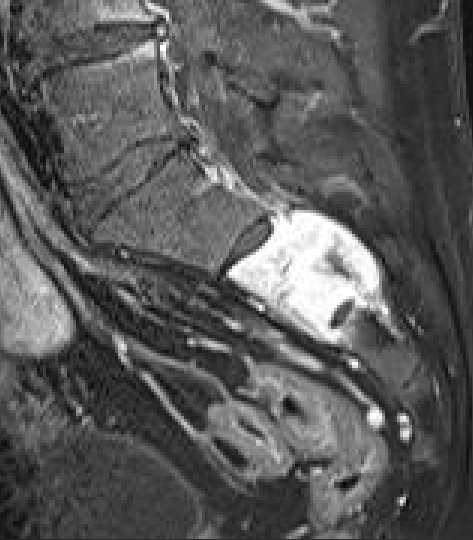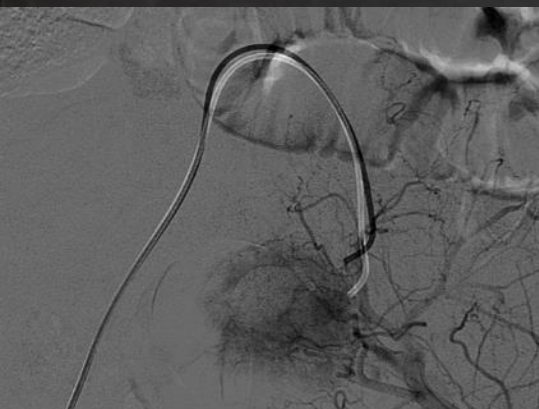


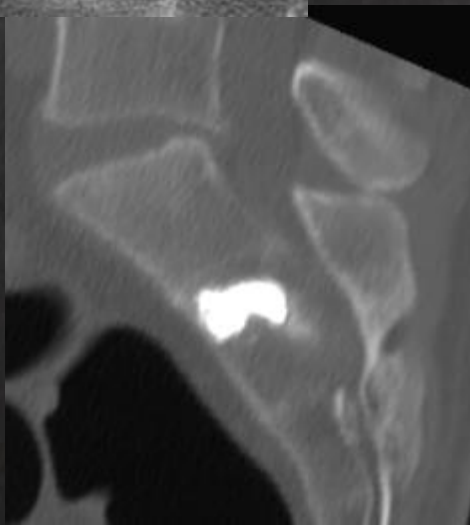
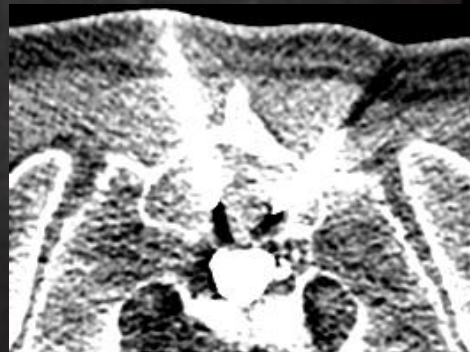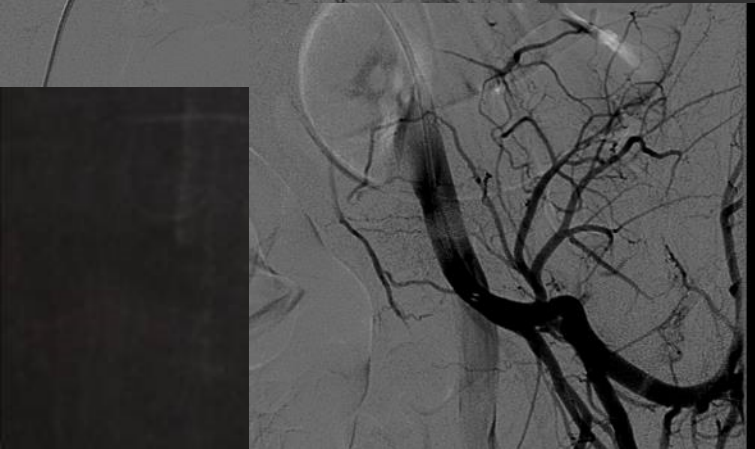
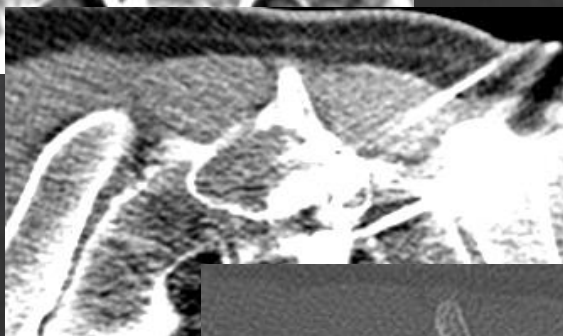
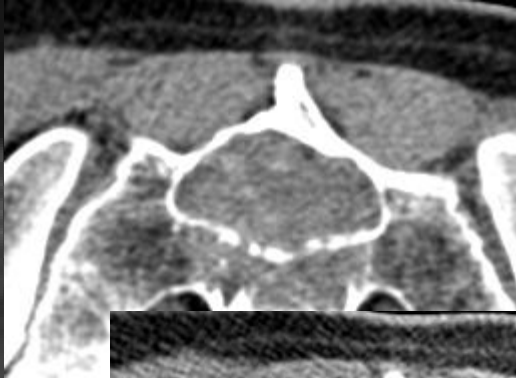
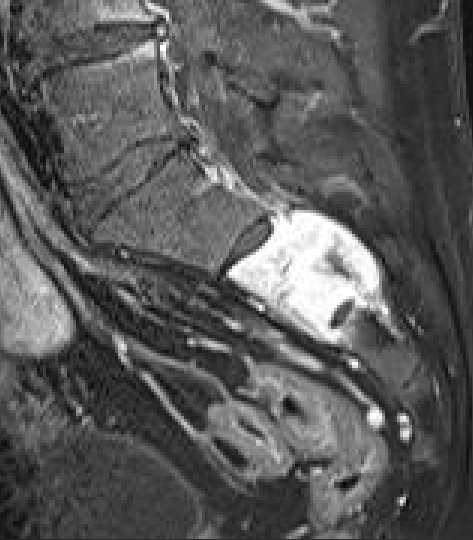


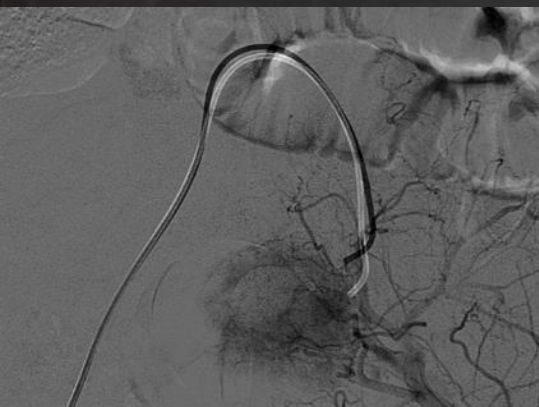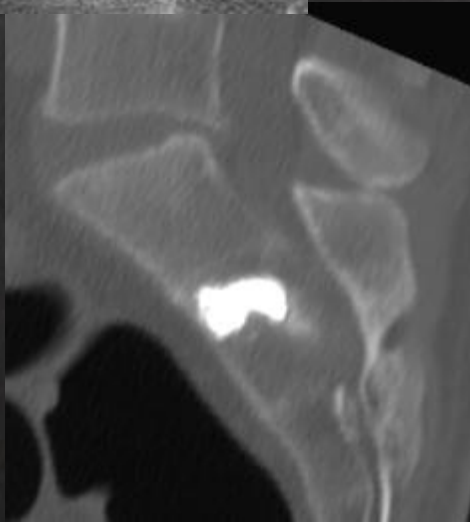
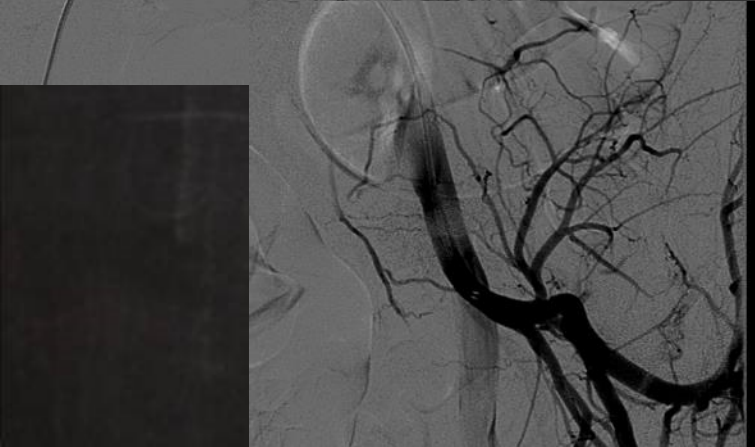
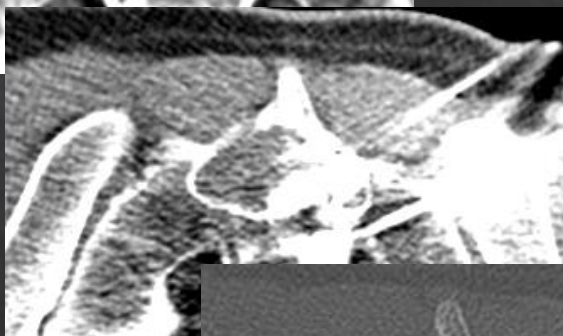
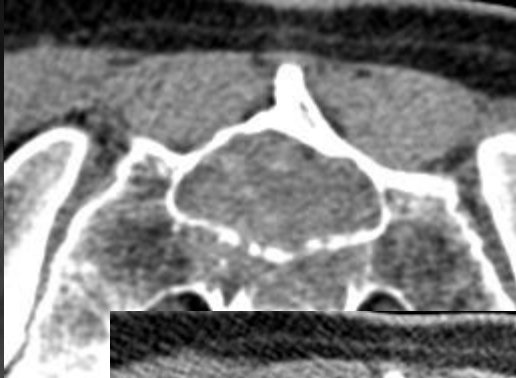
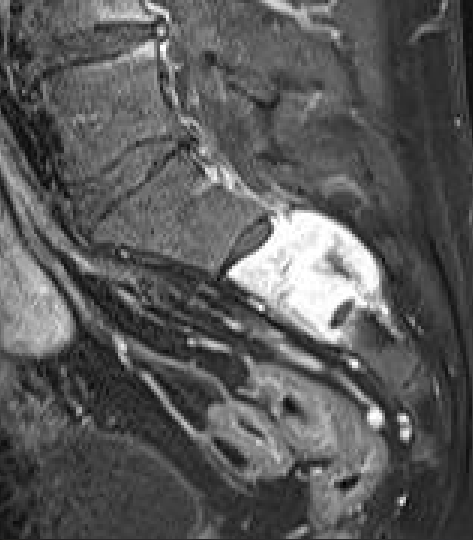


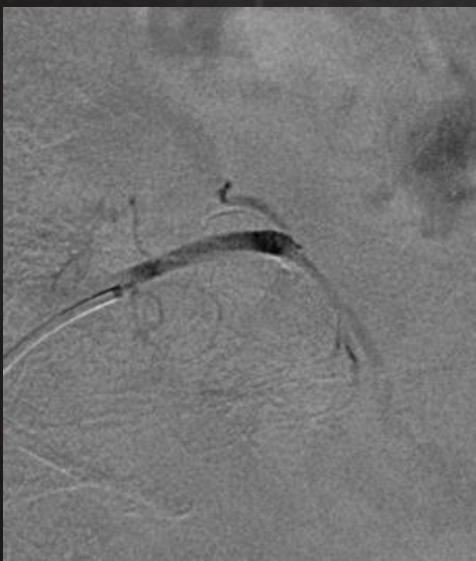


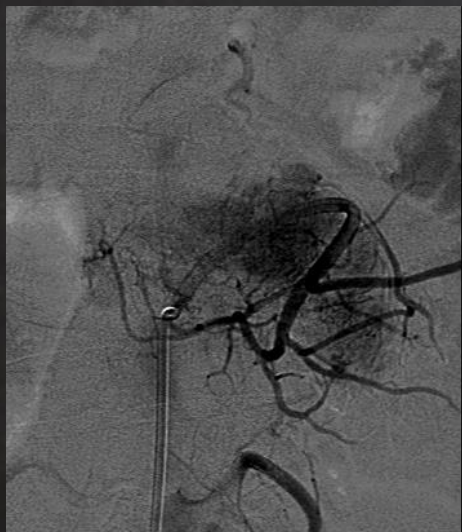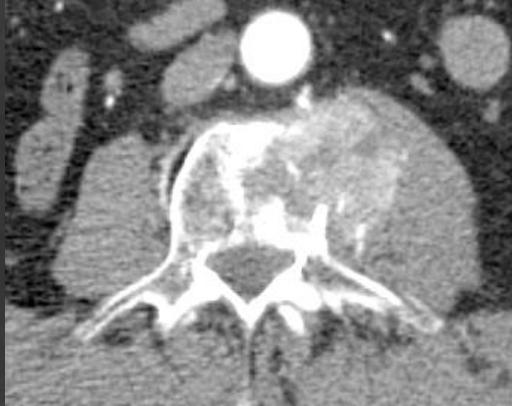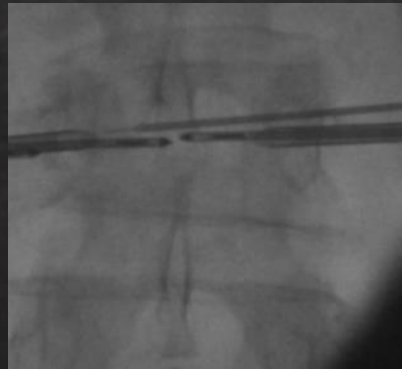
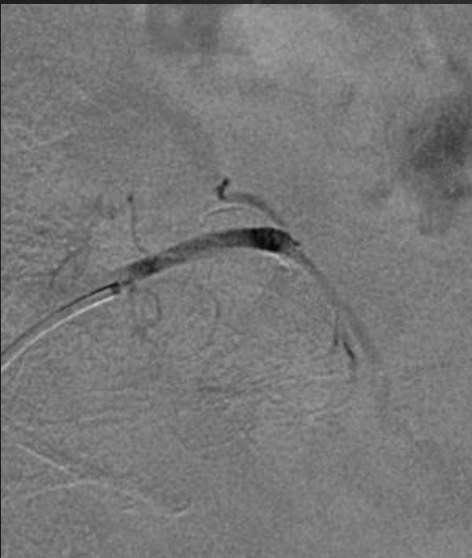
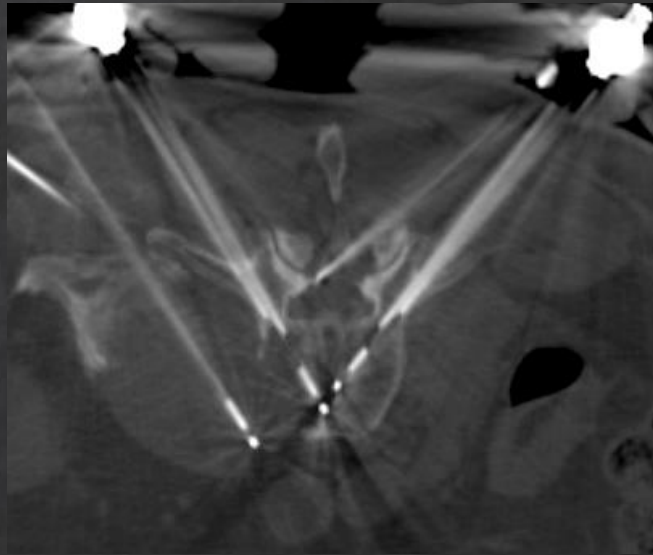
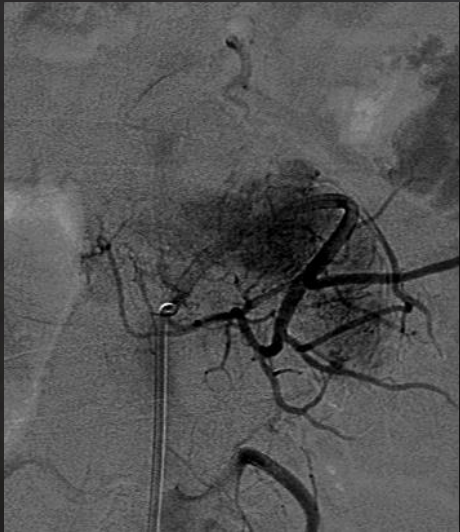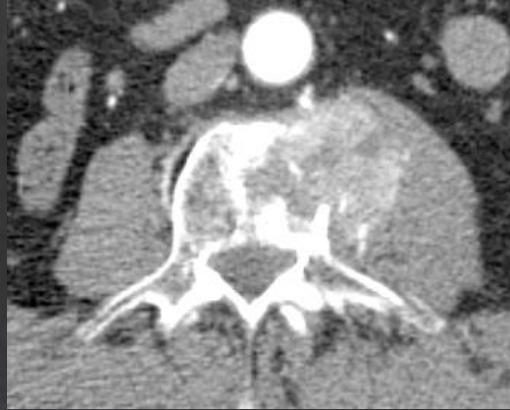


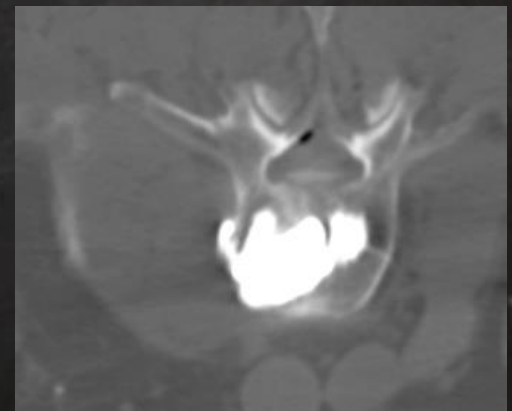
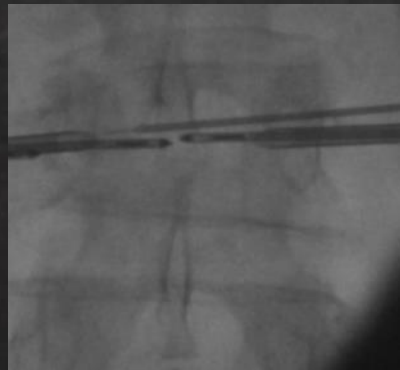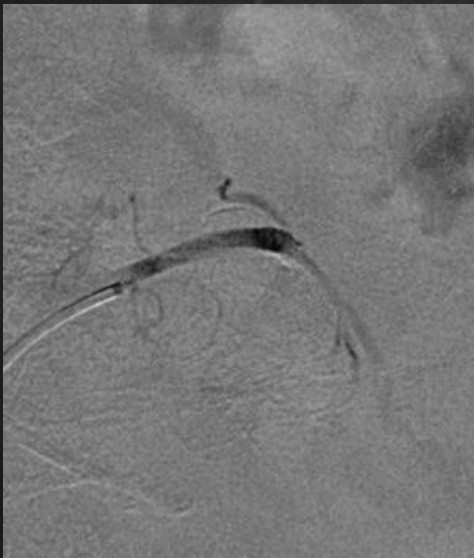
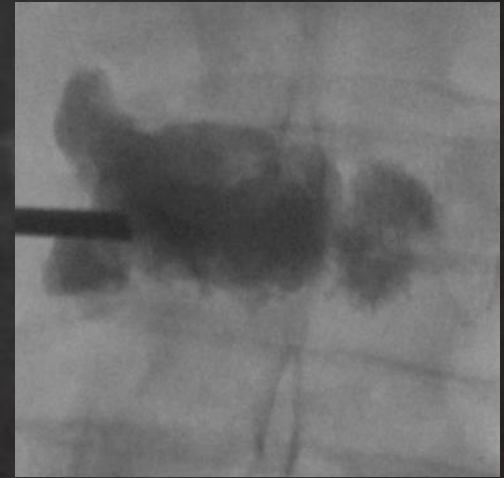
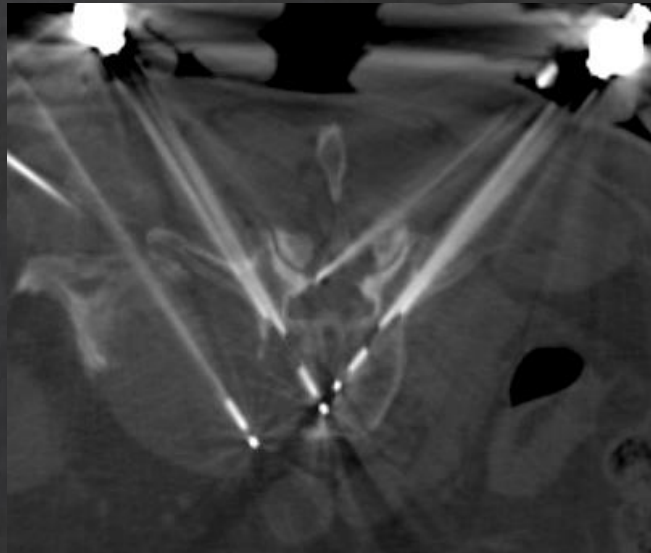
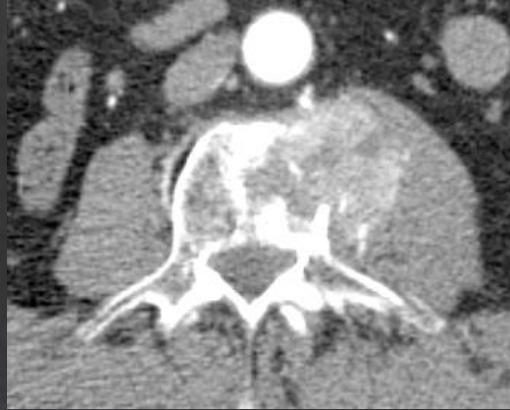


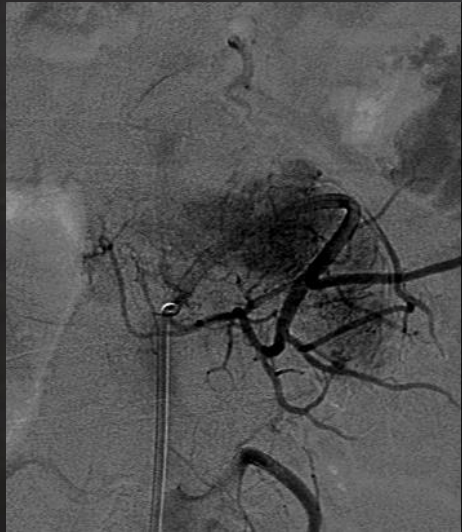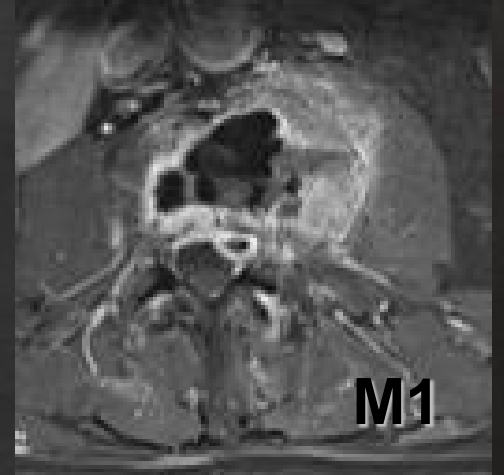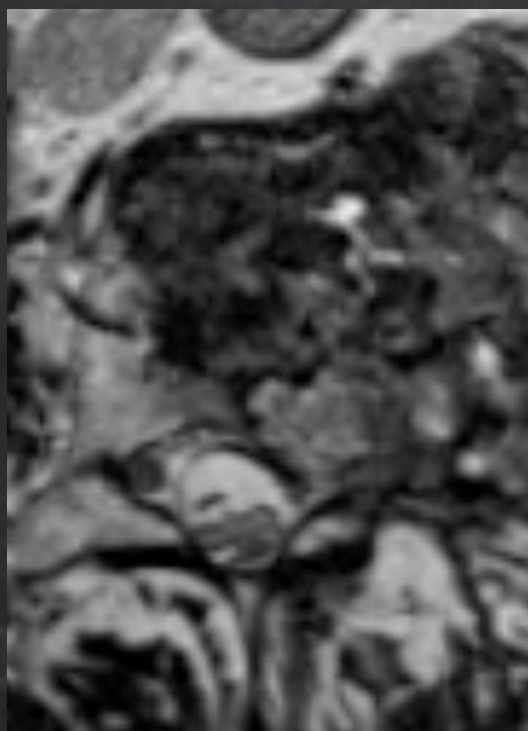
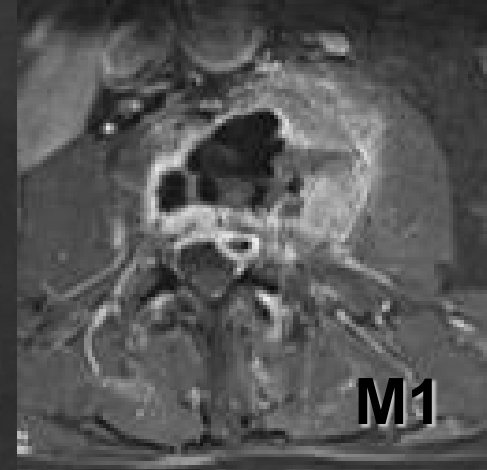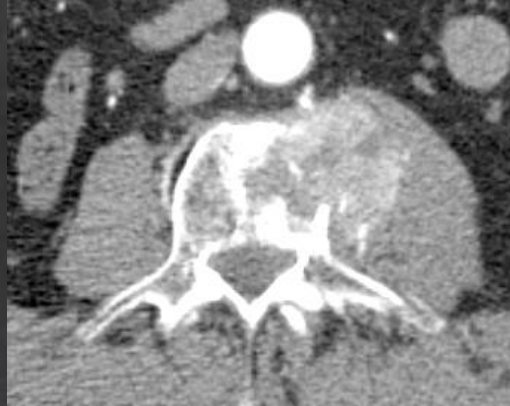




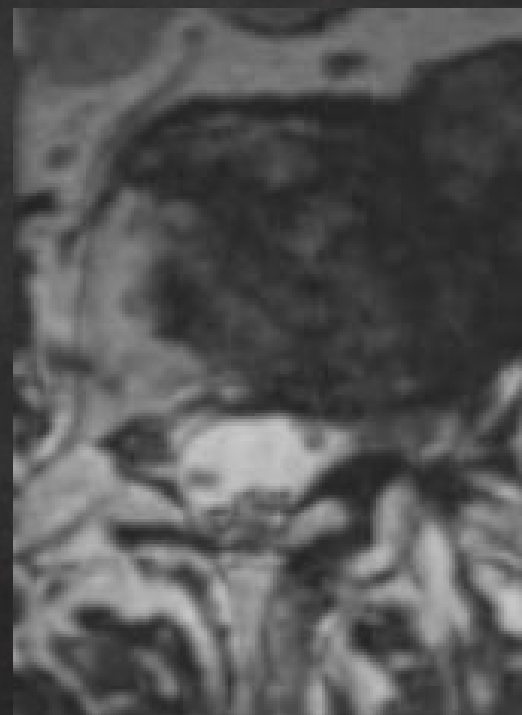




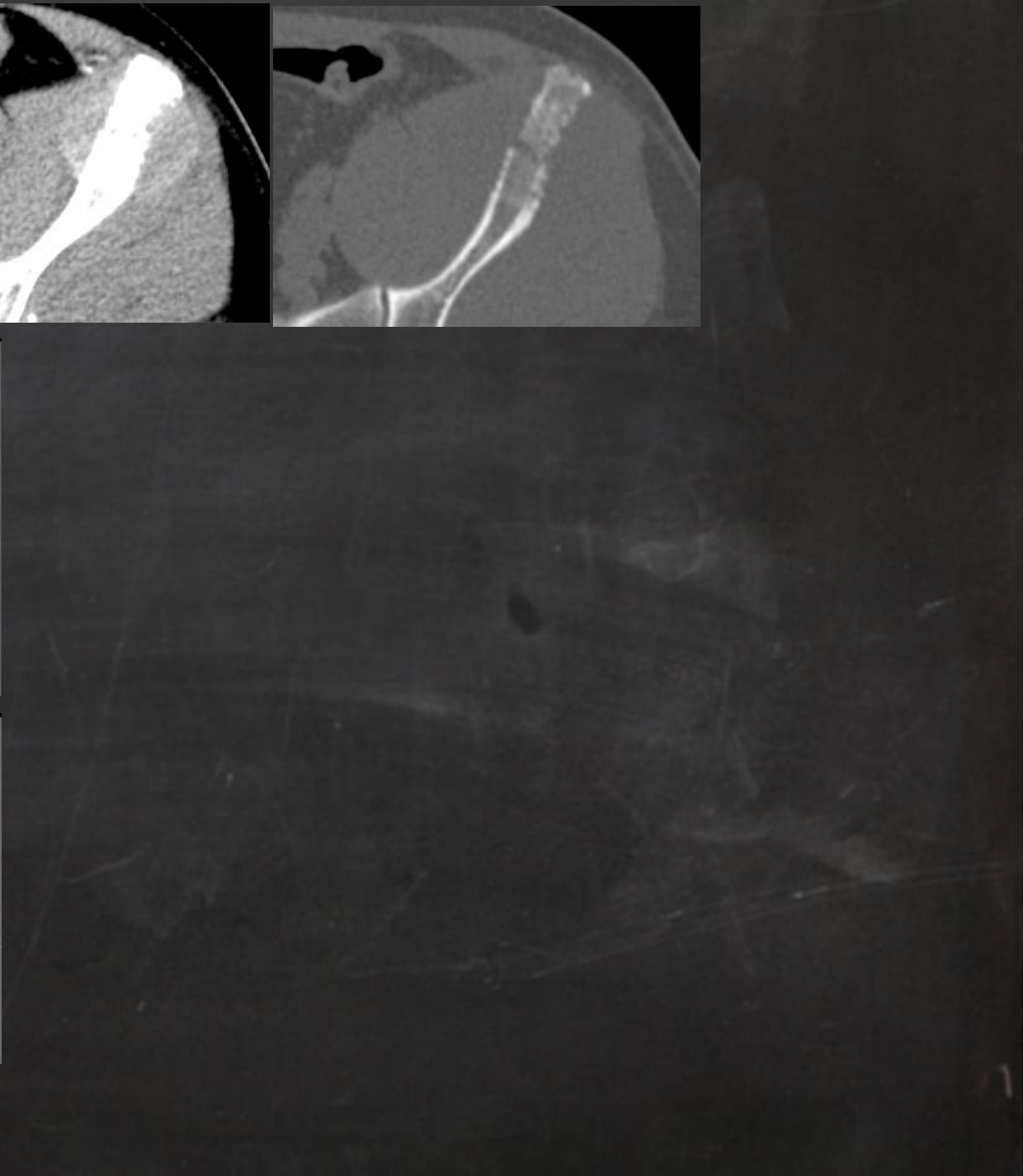
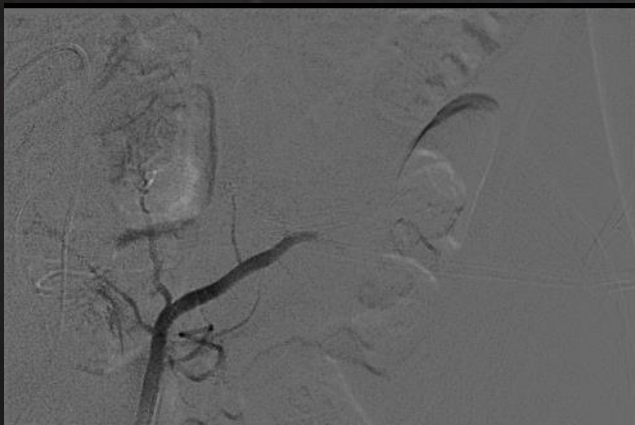
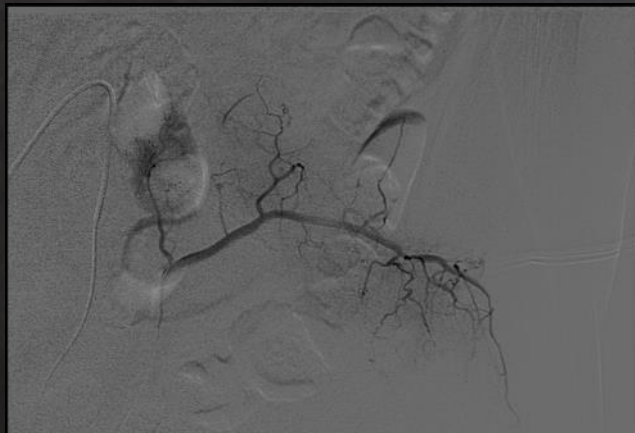


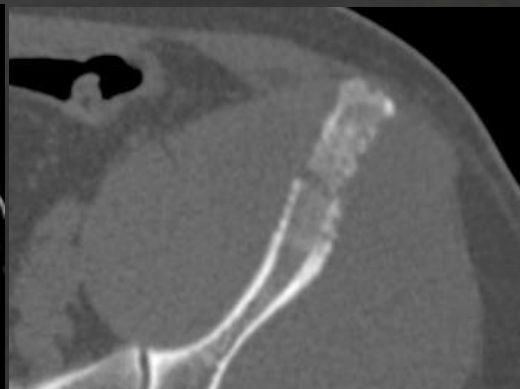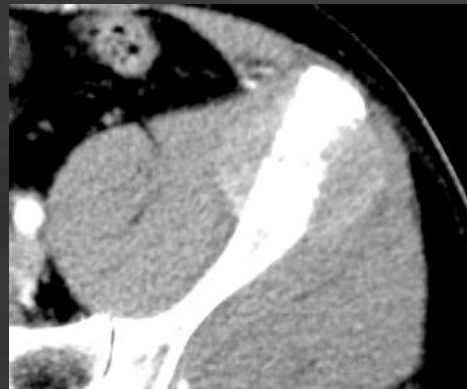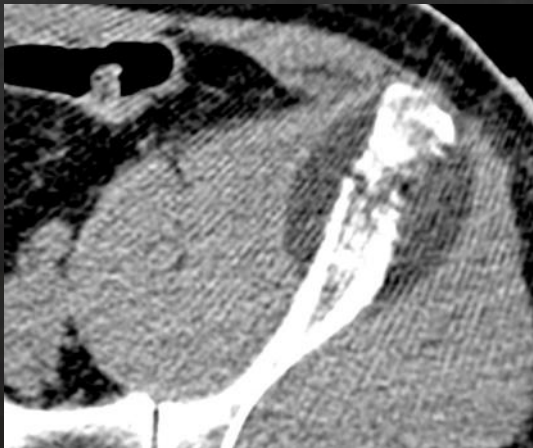
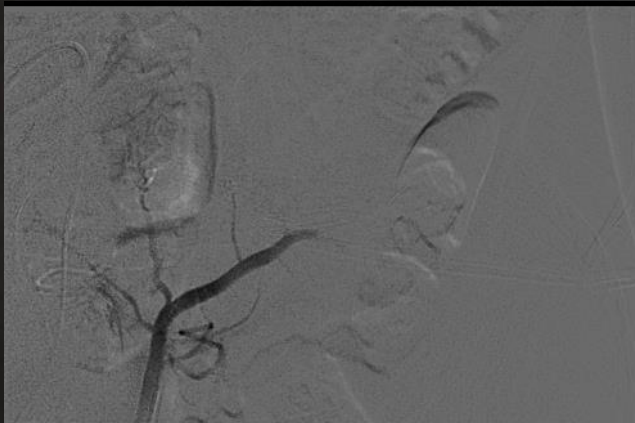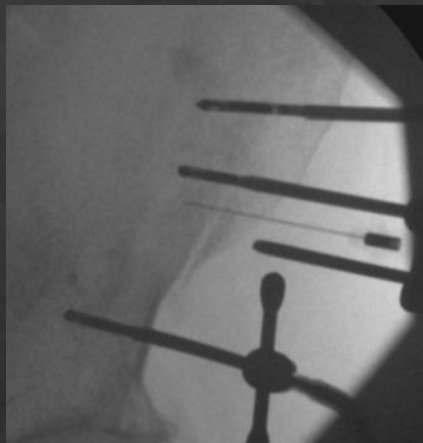
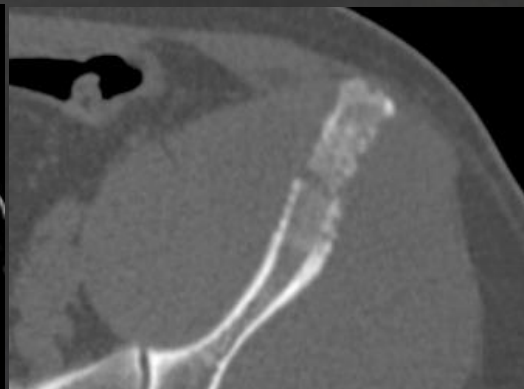


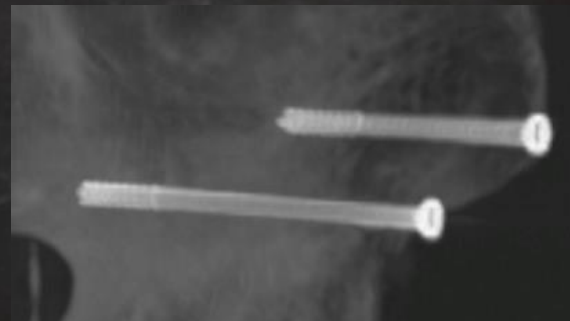
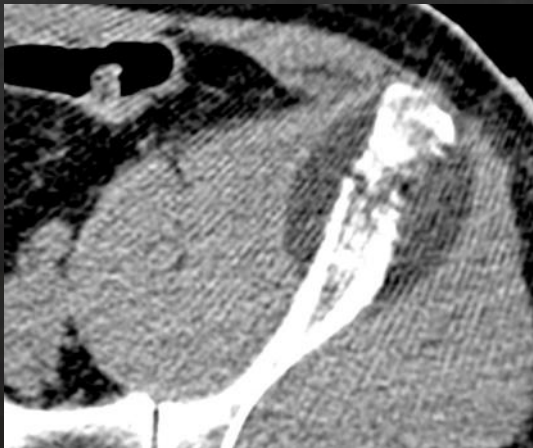
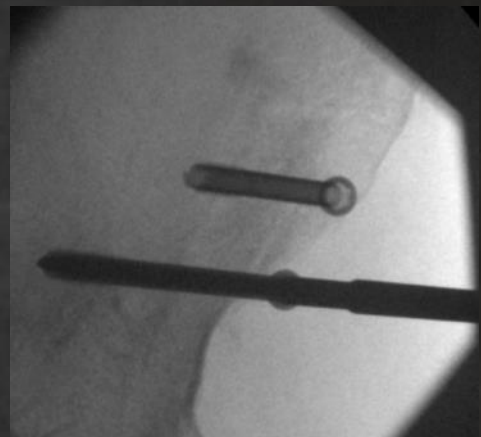
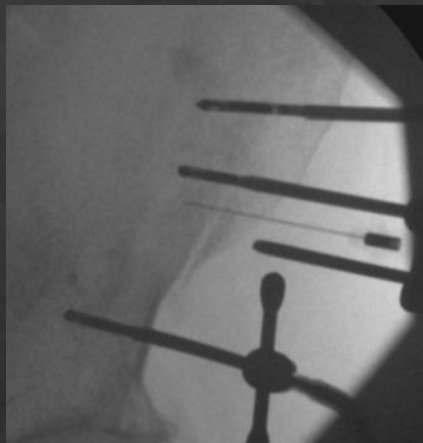
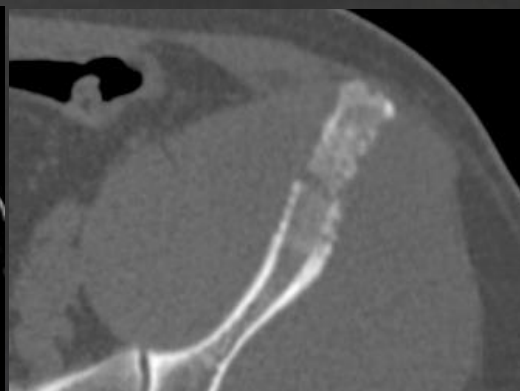
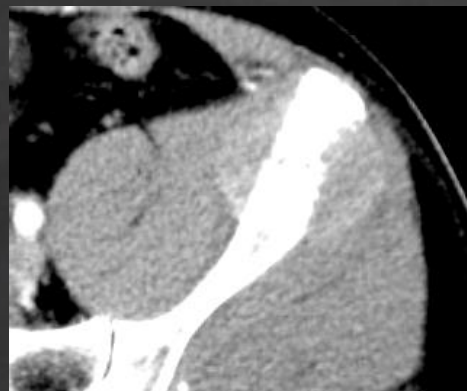5 mois après IR



3 mois après
radiothérapie







Conclusion

L'embolisation artérielle:

- permet une réduction du flux intratumoral des lésions vasculaires primitives ou secondaires du squelette axial

- semble augmenter l'efficacité des techniques d'ablation percutanée