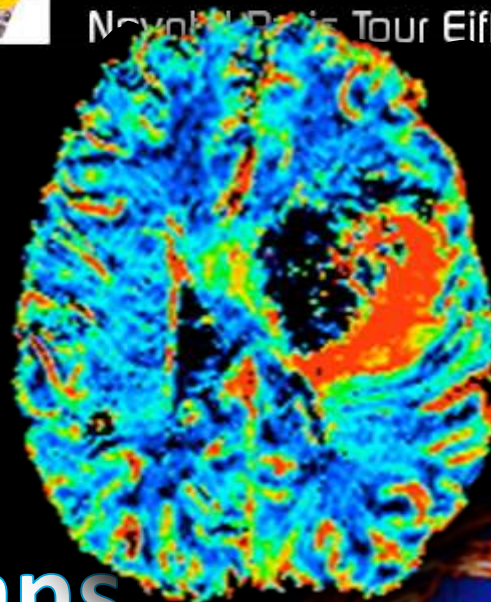




41^{ème} CONGRÈS ANNUEL
de la **Société Française**
de **NeuroRadiologie**

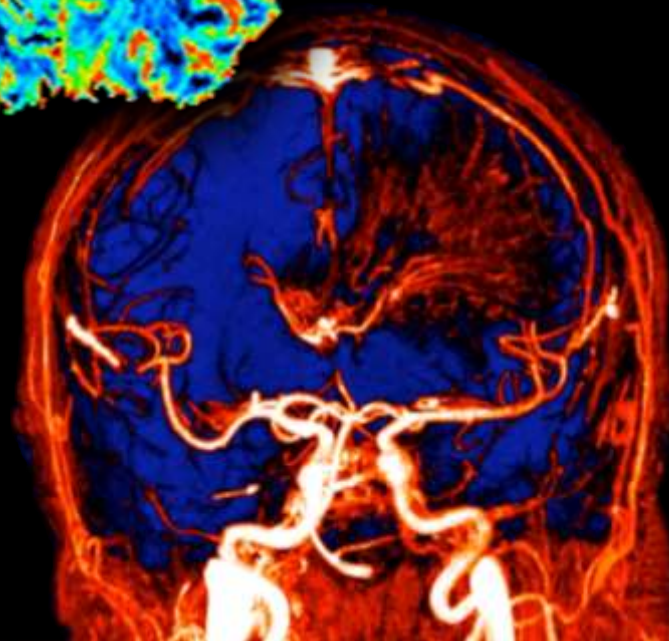
Session thématique
Imagerie de perfusion

IRM de perfusion dans le suivi des tumeurs

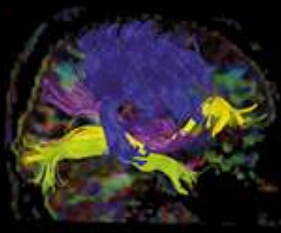


Présidente du congrès
Pr Alessandra Biondi

Président de la SFNR
Pr Alain Bonafé



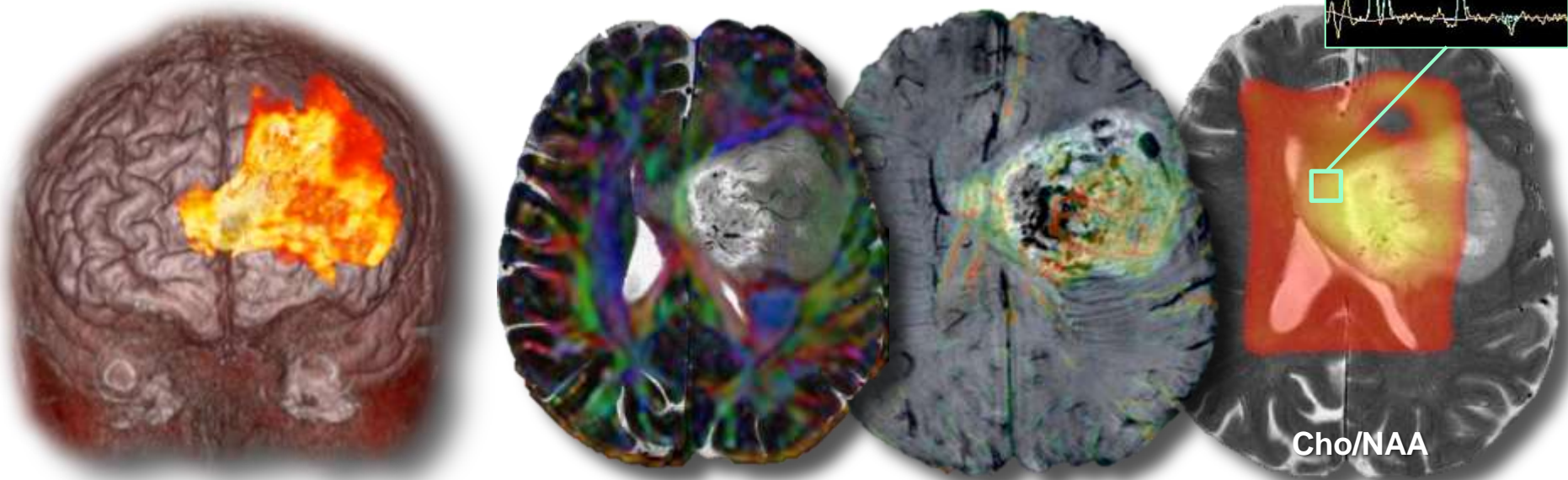
Dr Julien Savatovsky
Fondation Rothschild, Service d'Imagerie
IRM Paris 13



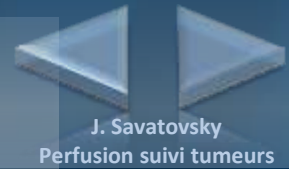
Conflit d'intérêt : aucun en rapport avec le cours

Remerciements :

- L'équipe de manipulateurs de l'IRM Paris 13 et IRM Peupliers,
- L'équipe de manipulateurs de la FOR,
- L'équipe de neuro-oncologie de la Pitié-Salpêtrière

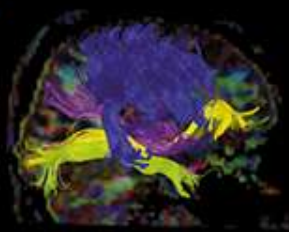


Objectifs

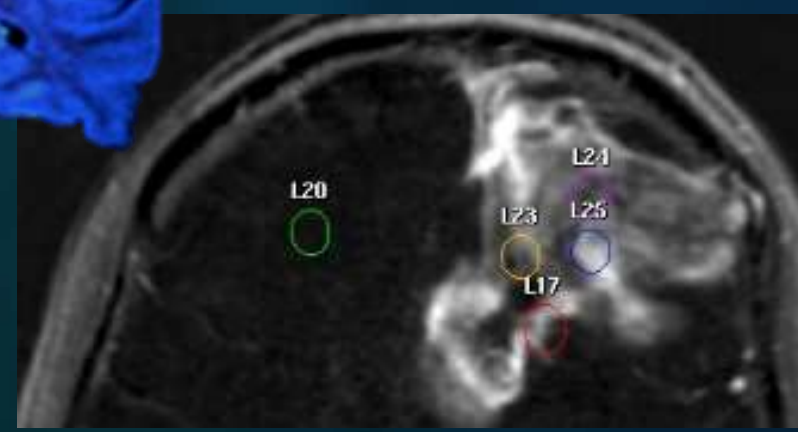
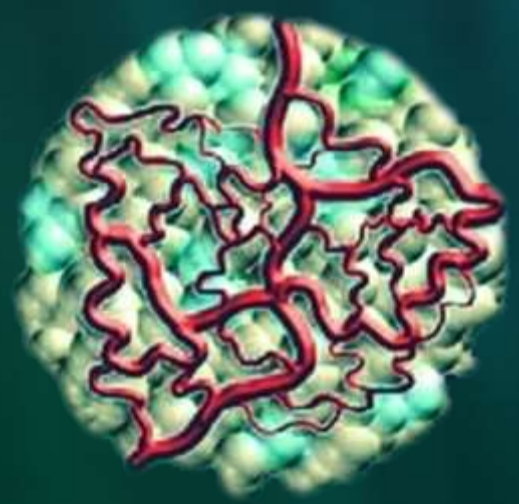
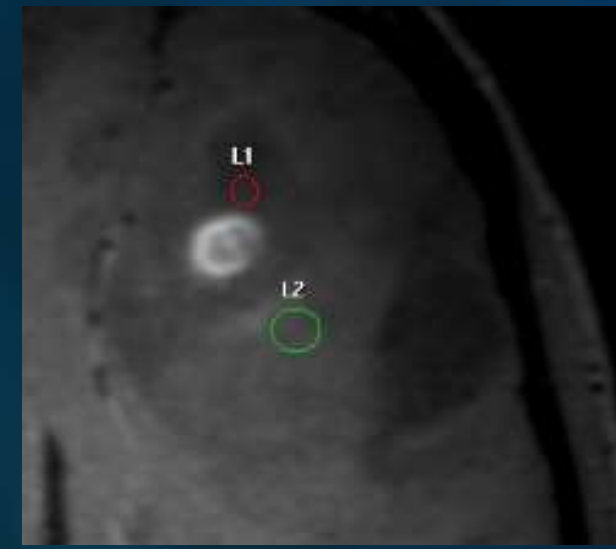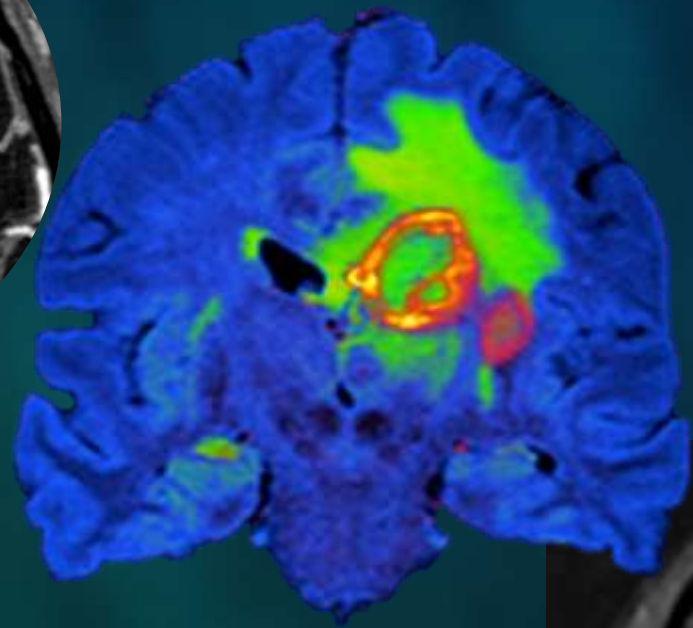
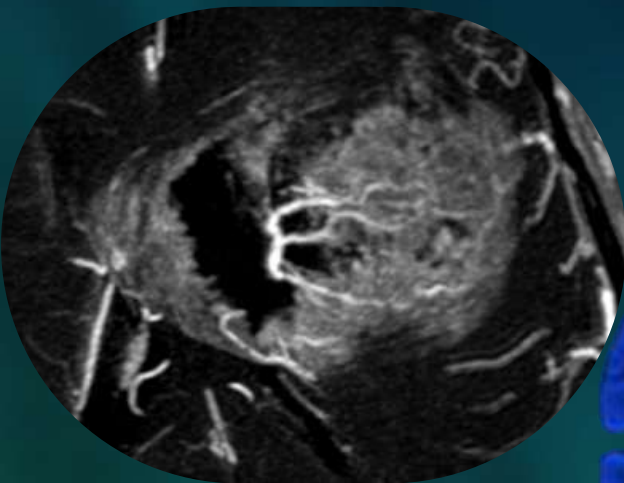


Après ce cours, vous serez capables de :

- Rappeler les prérequis pour réaliser une **perfusion DSC** dans le cadre d'un suivi de tumeur et citer les modalités de **placement des régions d'intérêt** et **d'interprétation des courbes** de perfusion
- **Implémenter la perfusion DSC en pratique clinique** afin d'aider à l'identification des entités suivantes :
 - **Virage anaplasique** d'un bas grade
 - **Pseudo-progression** d'un gliome de haut grade irradié
 - **Radionécrose** d'une localisation secondaire irradiée
- Comprendre les **difficultés d'évaluation et erreurs de mesure potentielles du rCBV**



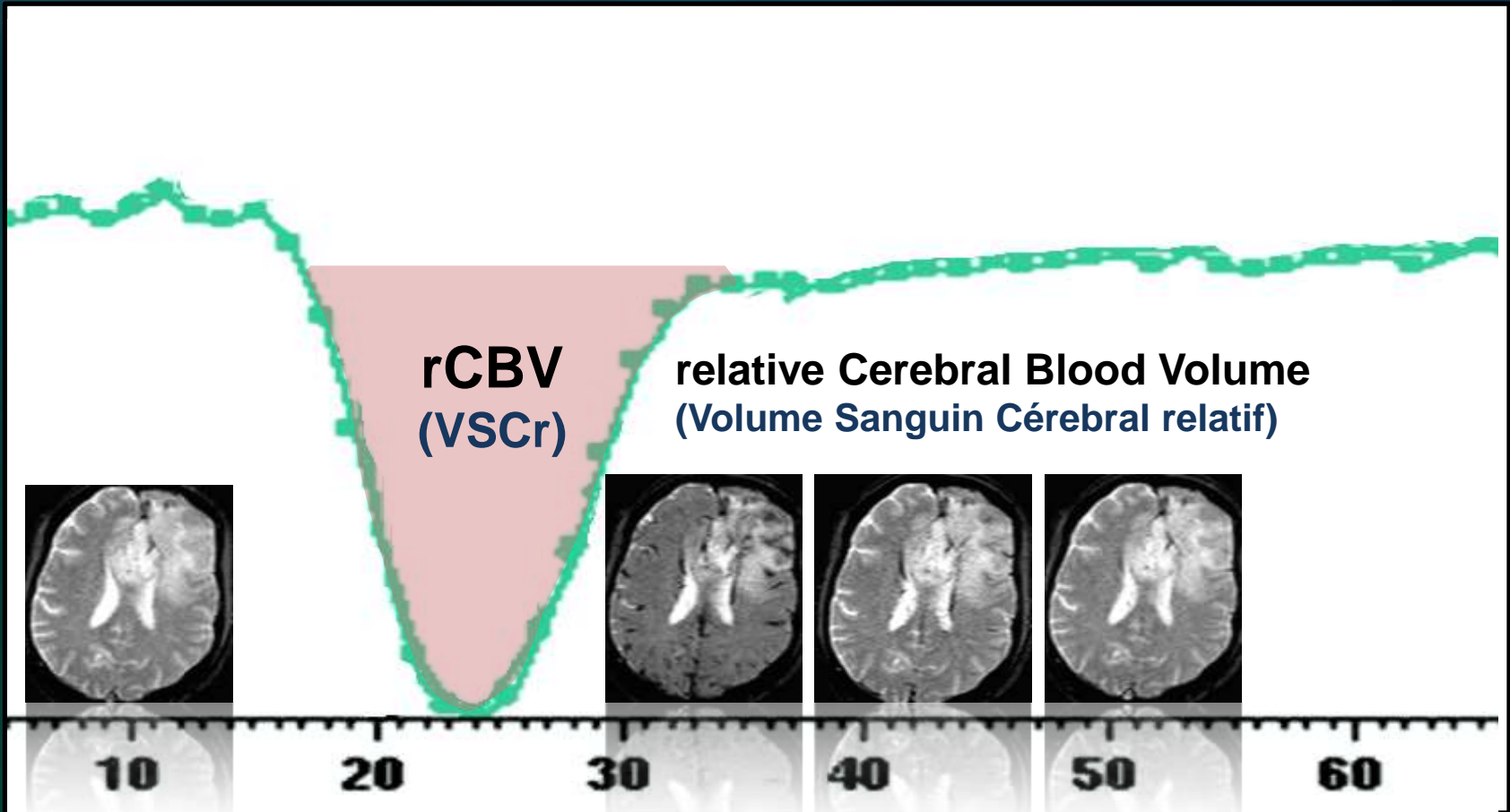
Prérequis et placement des ROI



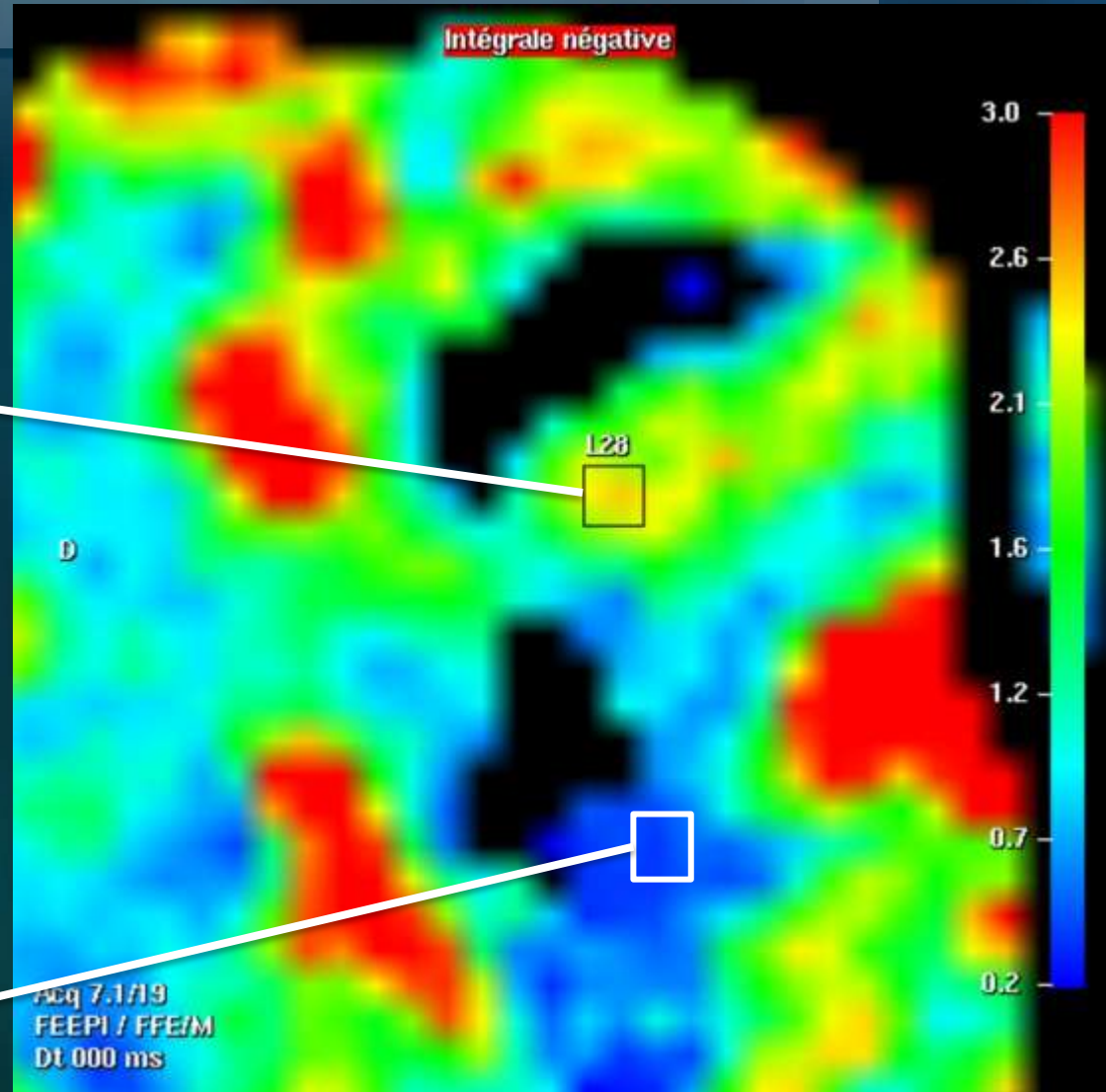

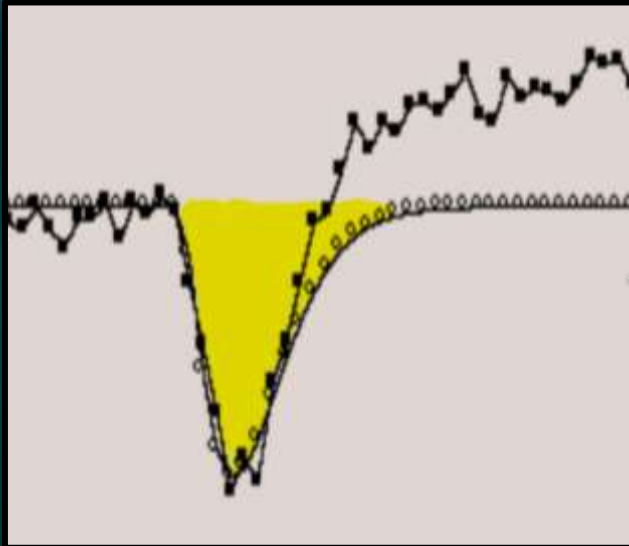
Prérequis

- Toutes les IRM ont la séquence
- Logiciels de post-traitement
 - Solution constructeur, incluse à l'achat de la machine
 - +/- convivial (penser au flux de travail)
 - +/- pertinent (correction de l'effet T1 ?)
 - Solution tierce (vendeur-indépendant)
- Matériel pour injection en bolus

Définition des paramètre

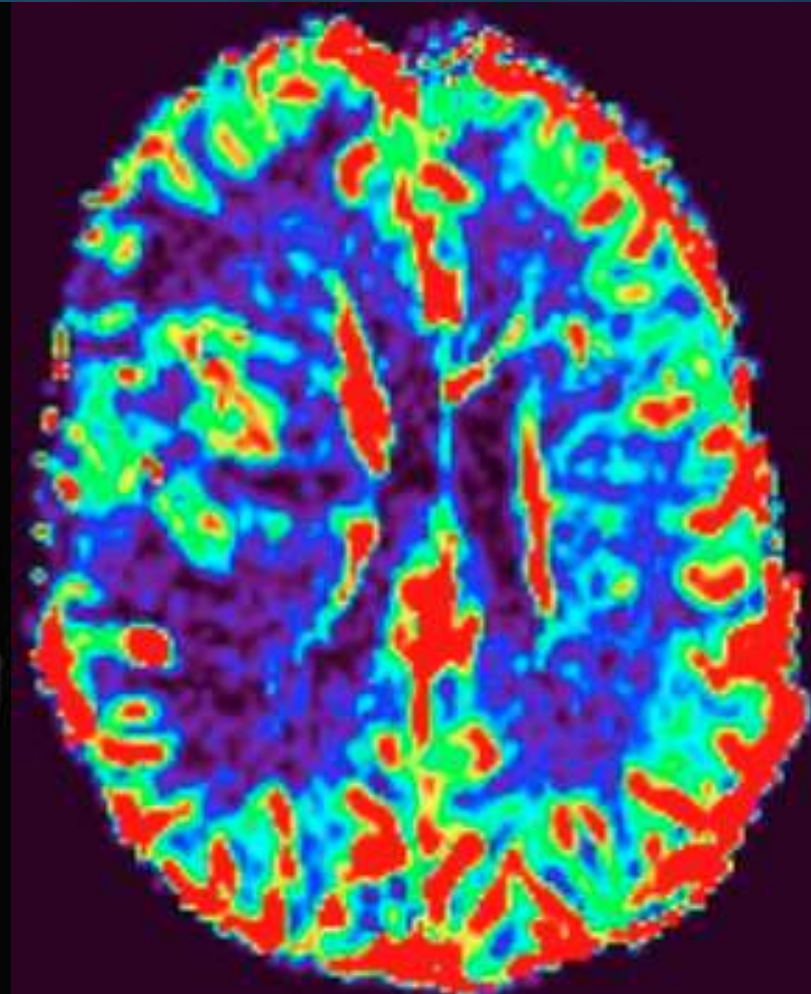
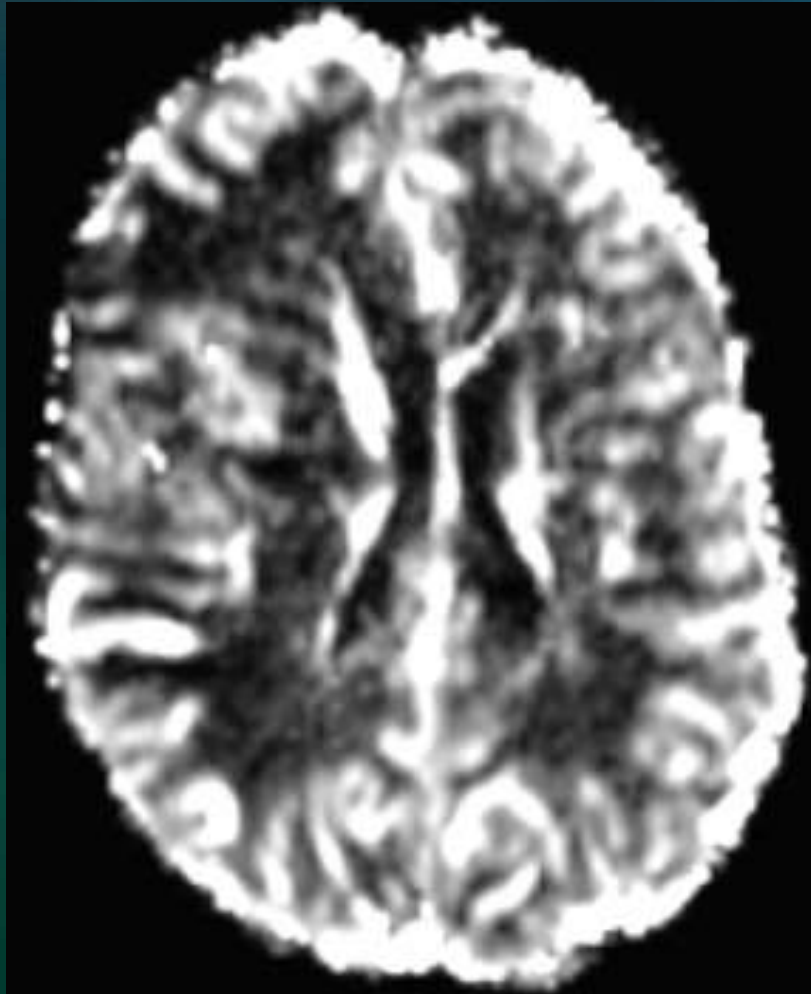


Cartographie du rCBV



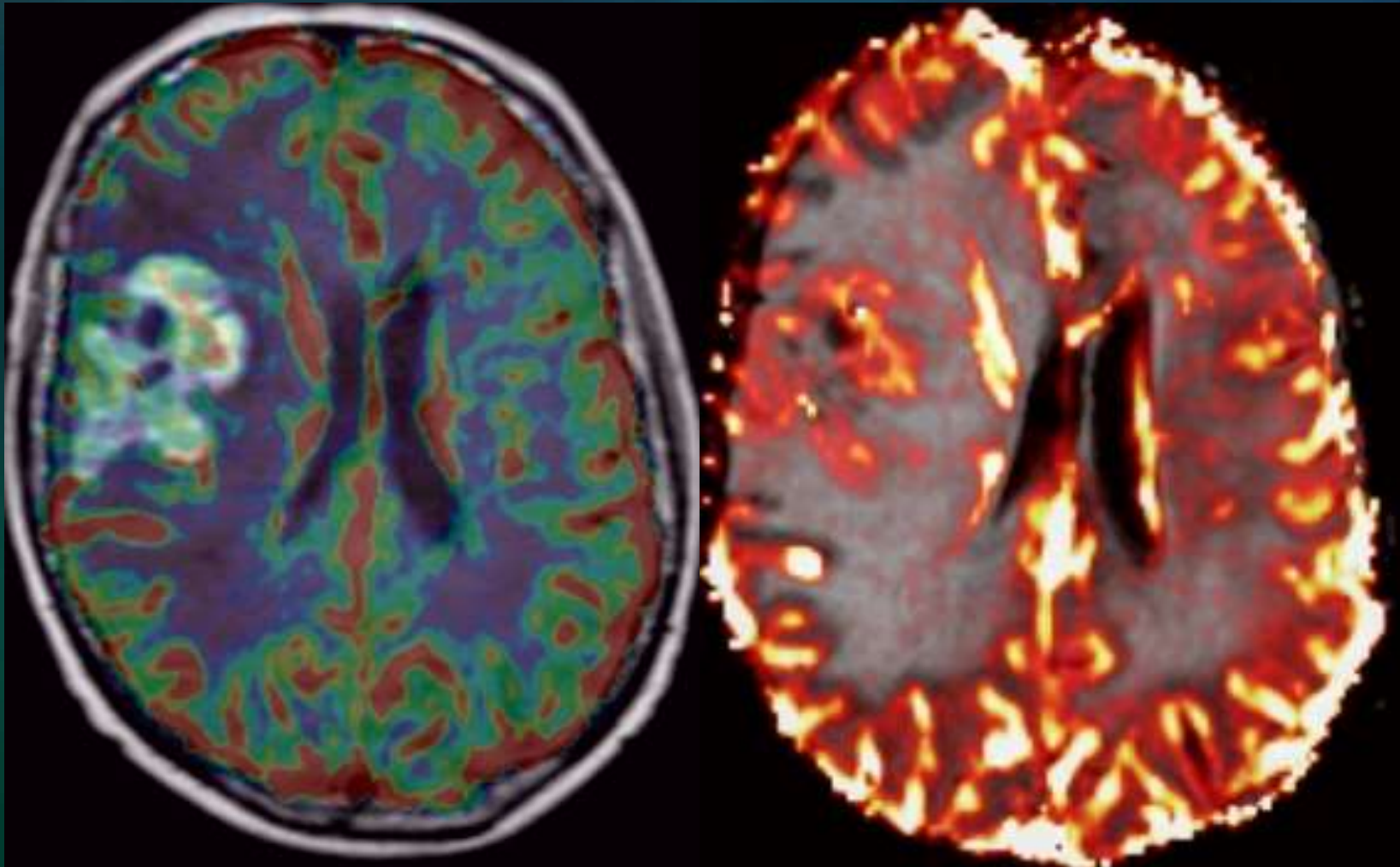
Cartographie du rCBV

Représentations possibles



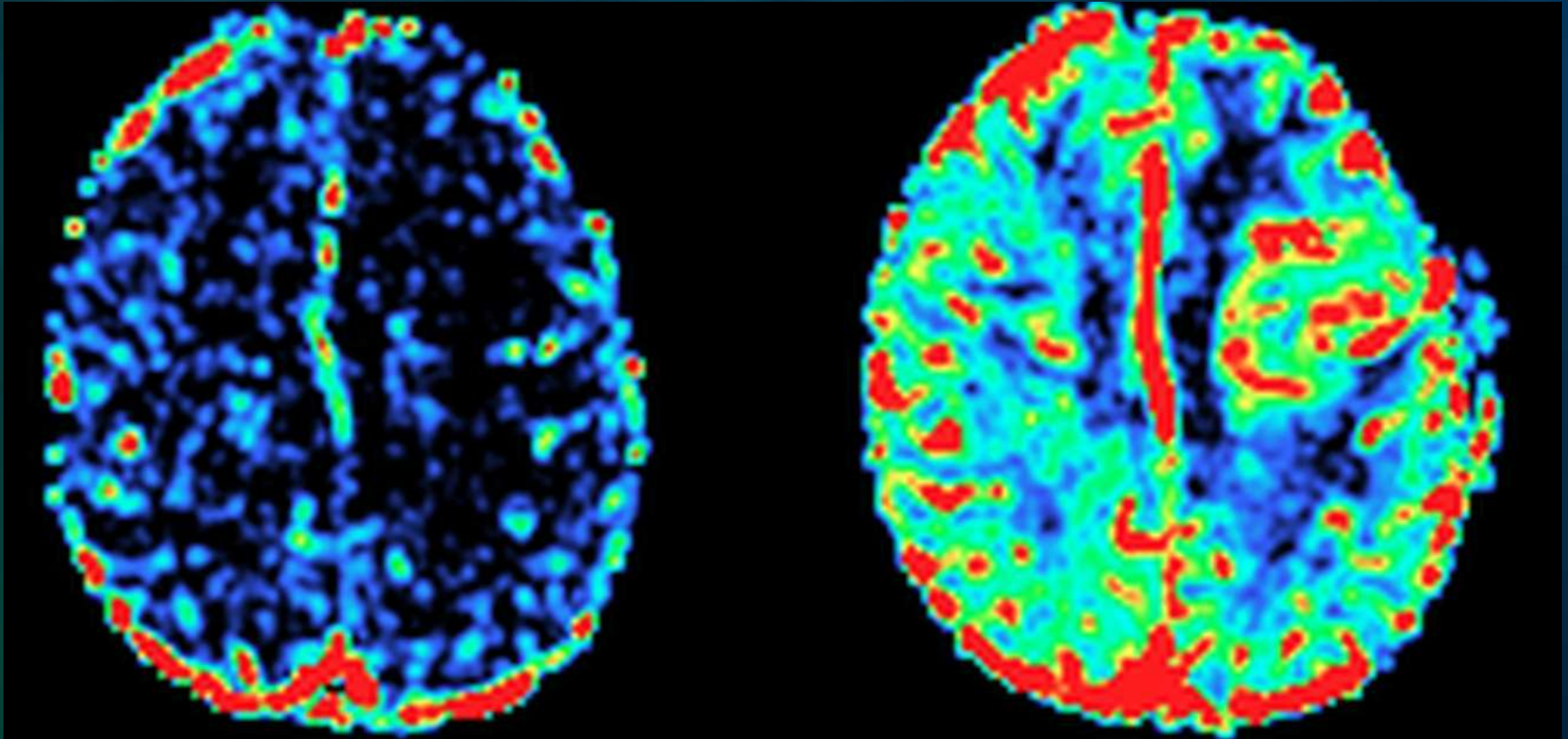
Cartographie du rCBV

Représentations possibles



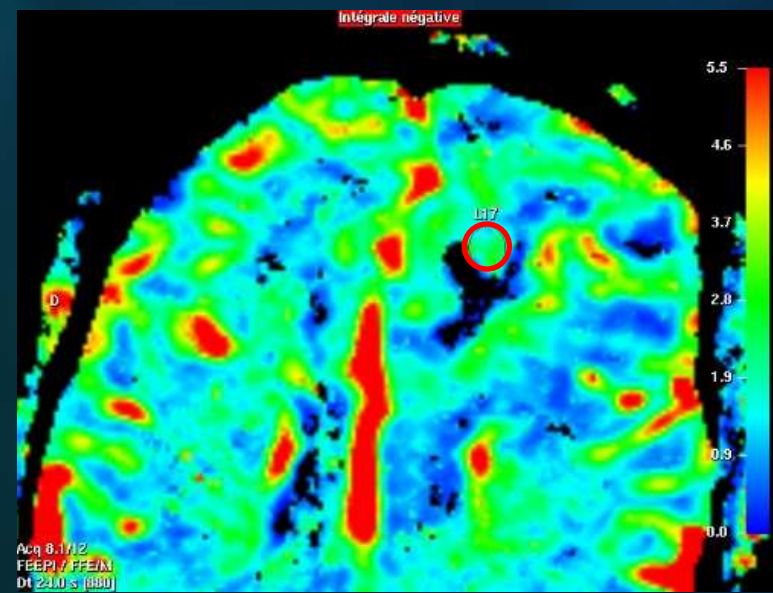
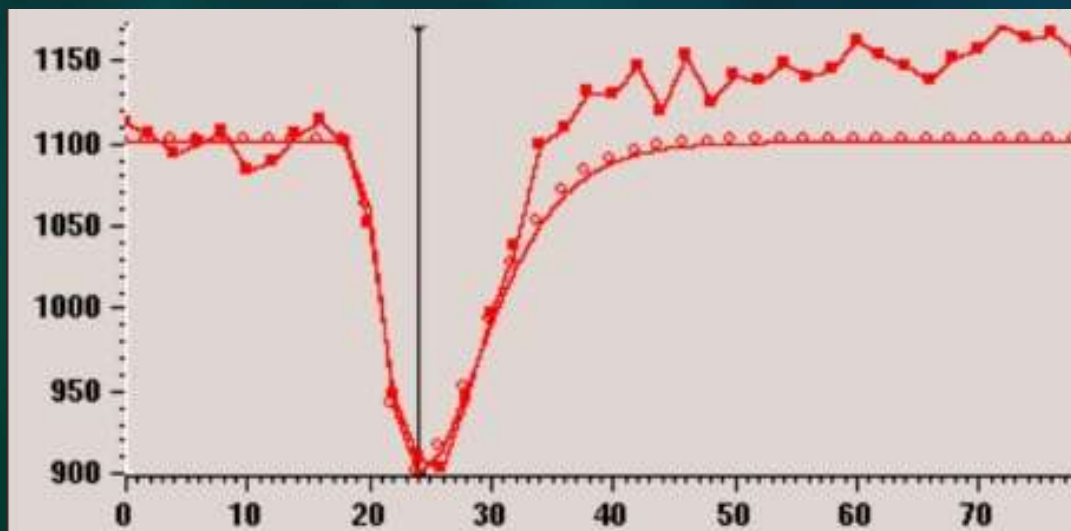
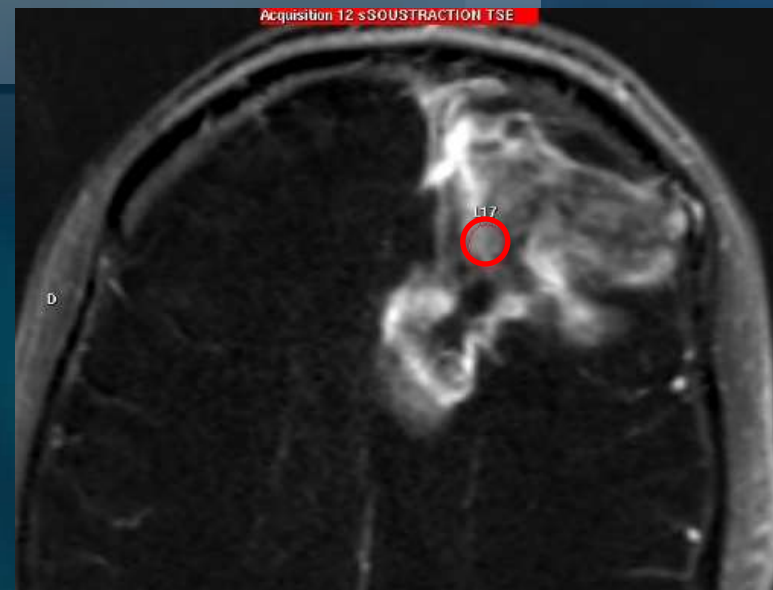
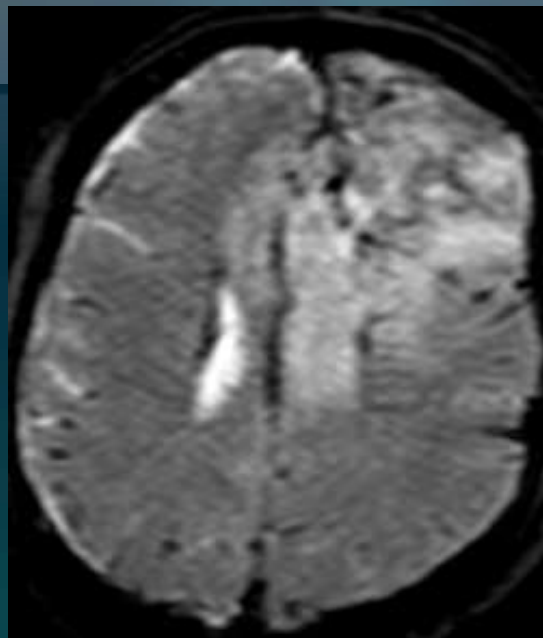
Analyse qualitative du rCBV

Même patient même jour : **perf ratée** / **perf réussie**



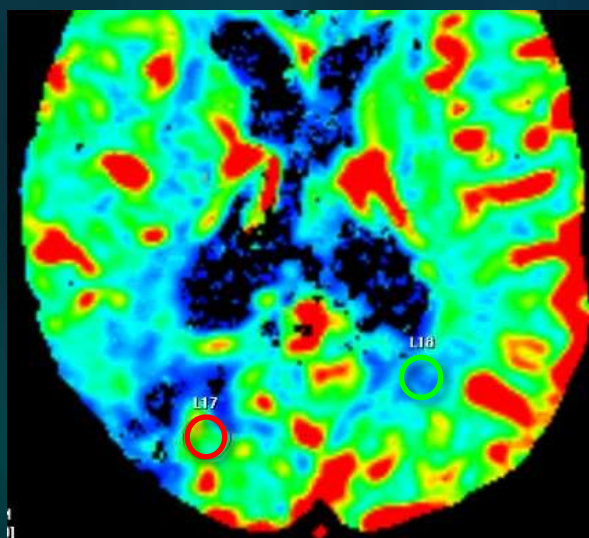
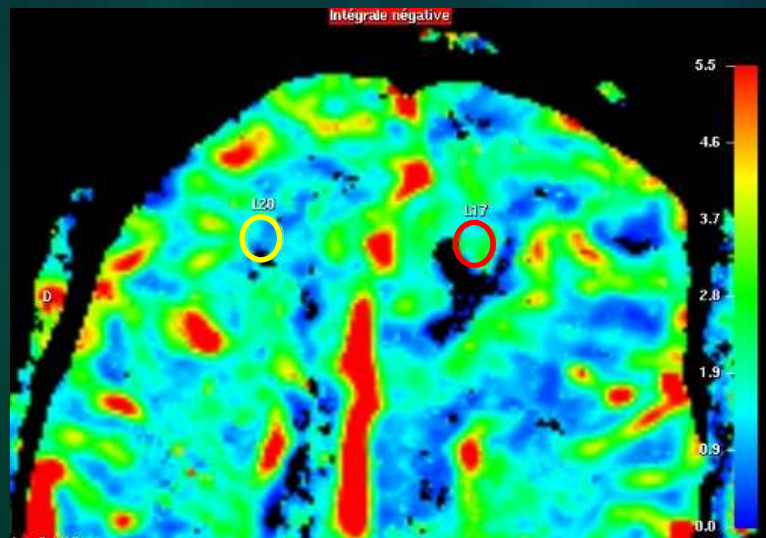
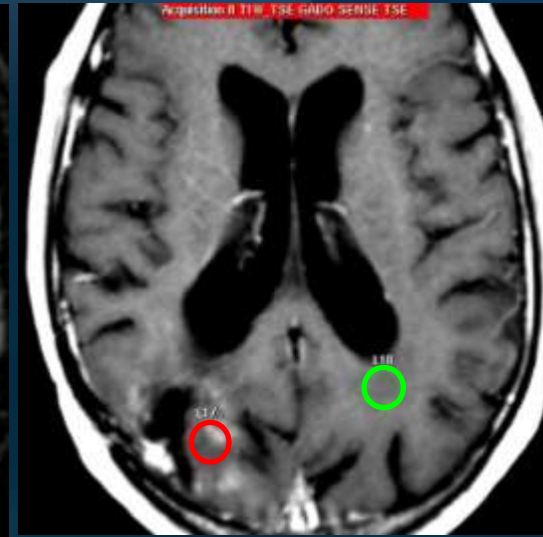
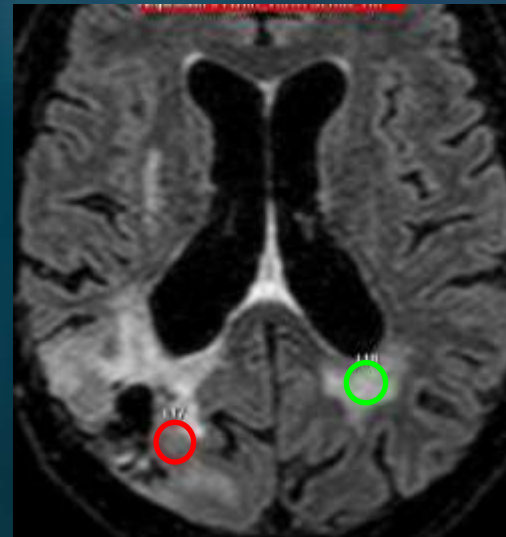
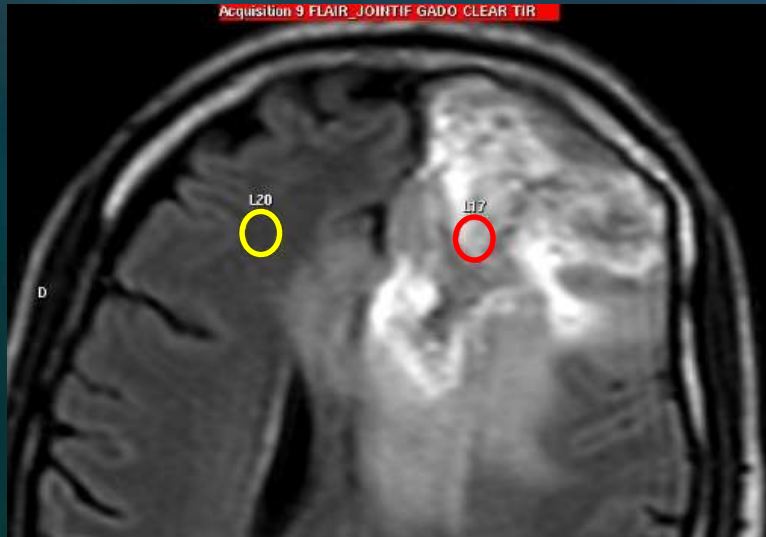
Placement des ROI

Où ?



Placement des ROI

Valeurs de référence

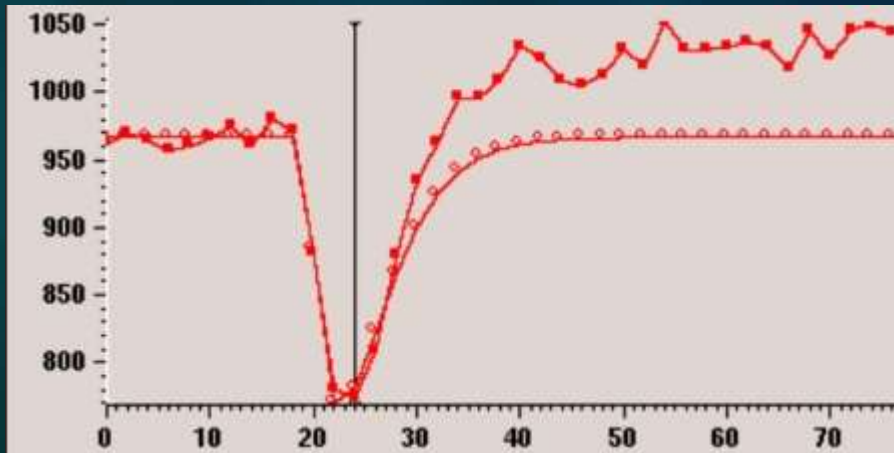
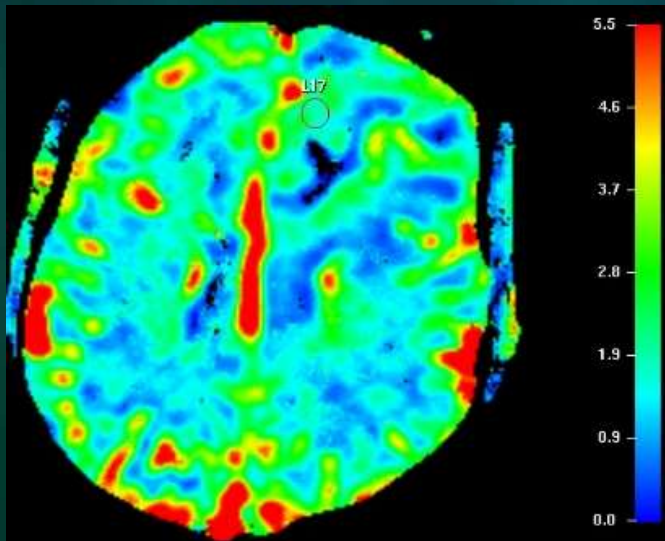
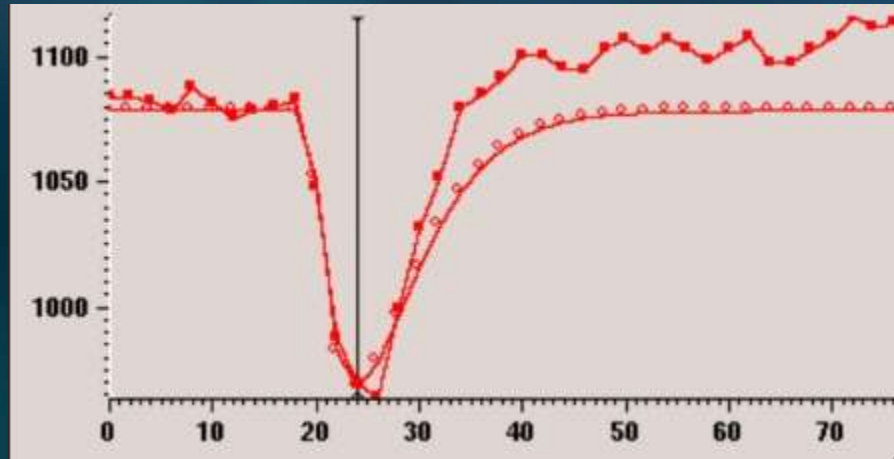
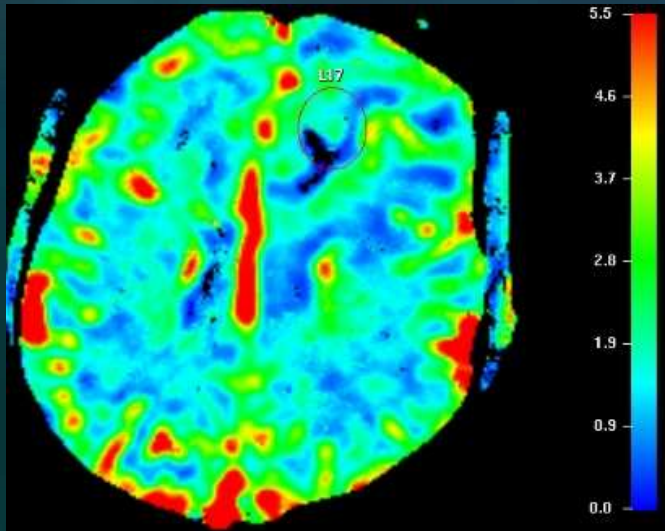


Placement incorrect:

SB anormale sur la
ROI de référence
(leucopathie post-radique)

**Risque de surestimation
Du rCBV**

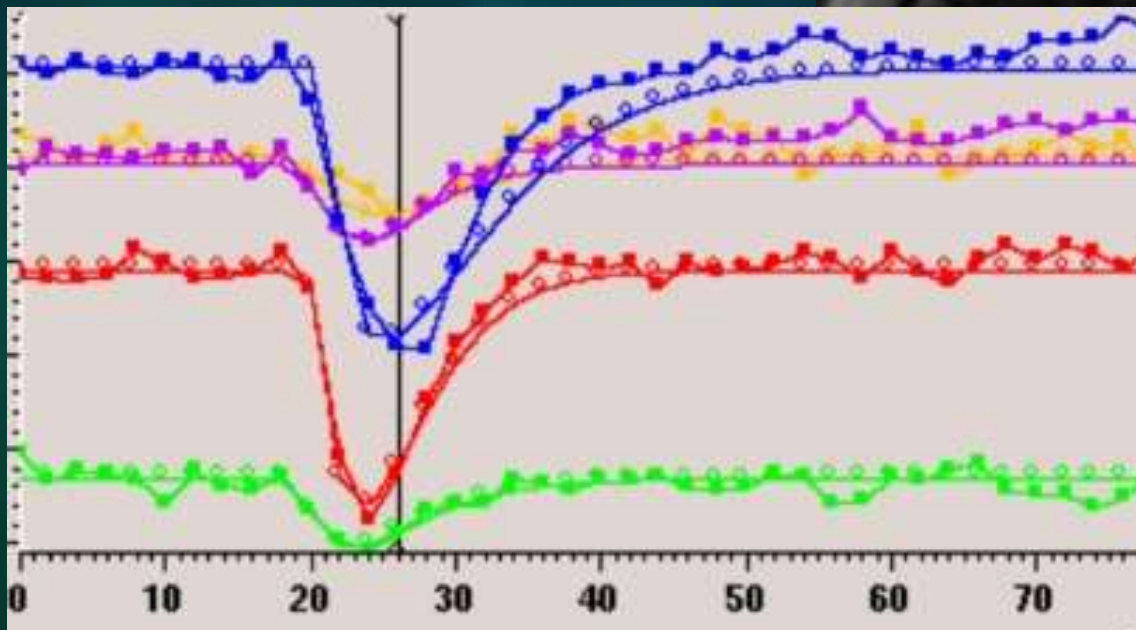
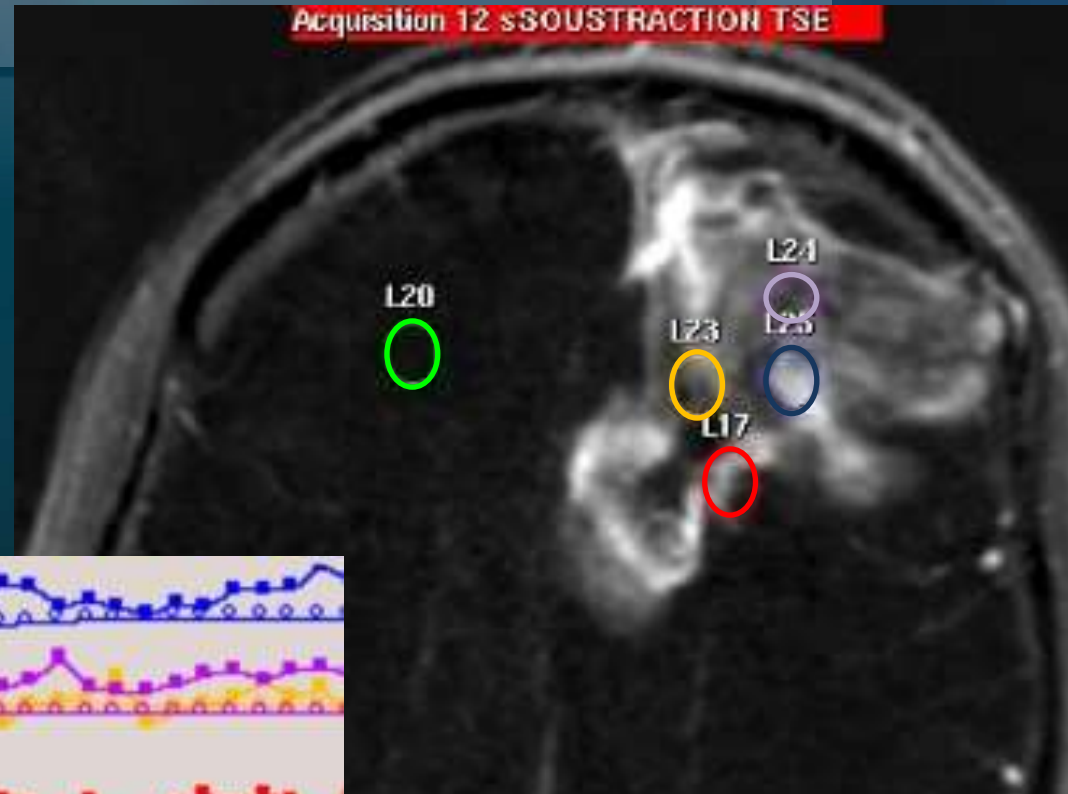
Placement des ROI Quelle taille ?



Placement des ROI Combien ?

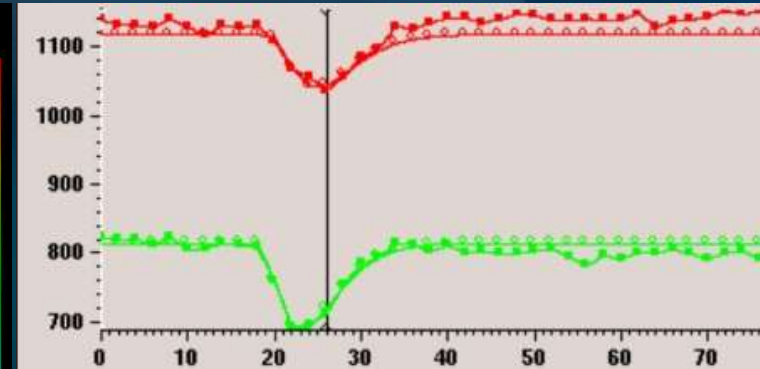
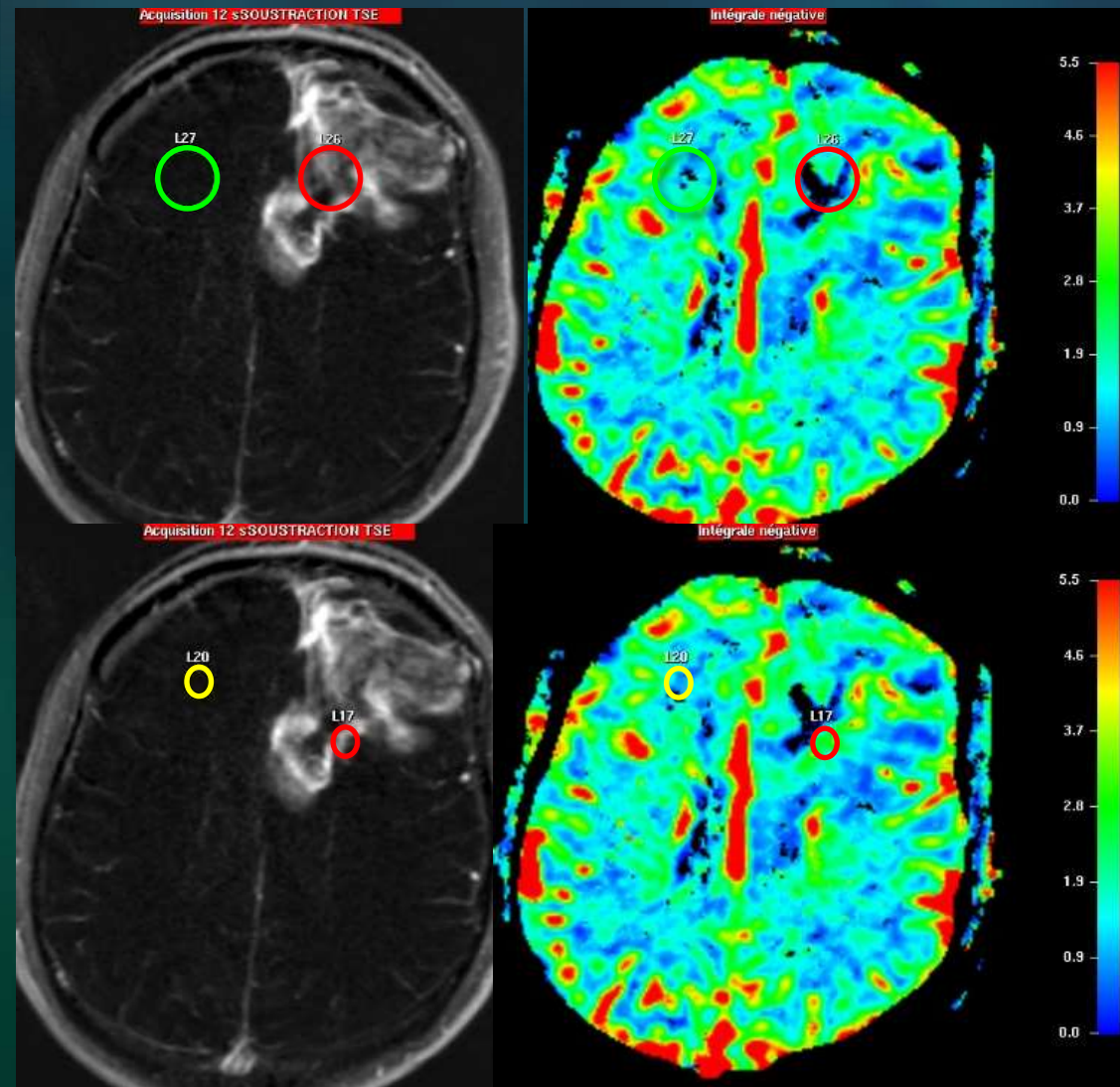
Lésion homogène : 1 – 3 ROI
Lésion hétérogène : 4 – 10 ROI
Zone de rCBV maximal

Prendre des ROI sur plusieurs
niveaux de coupe

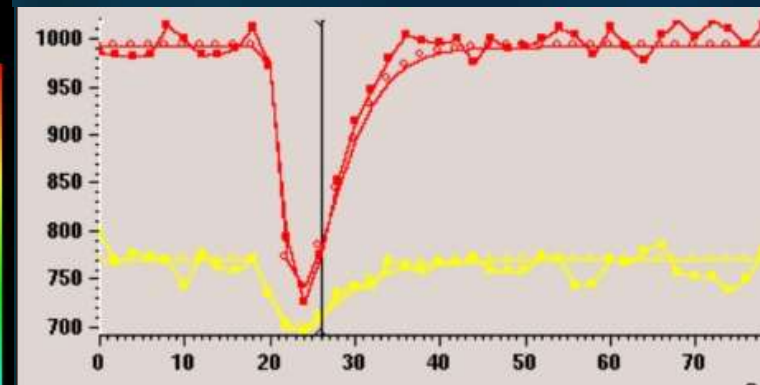


Placement des ROI - pièges

Hétérogénéité lésionnelle



rCBV=0.5 (hypoperfusion)

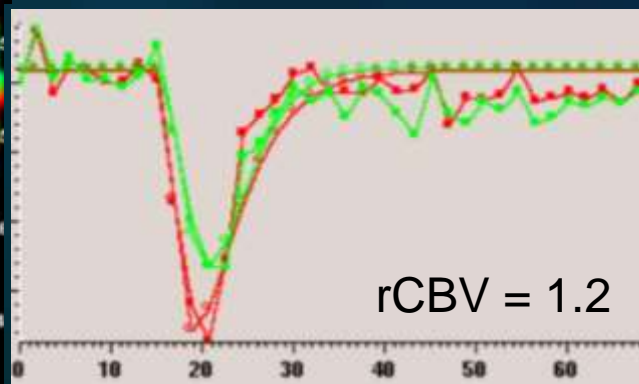
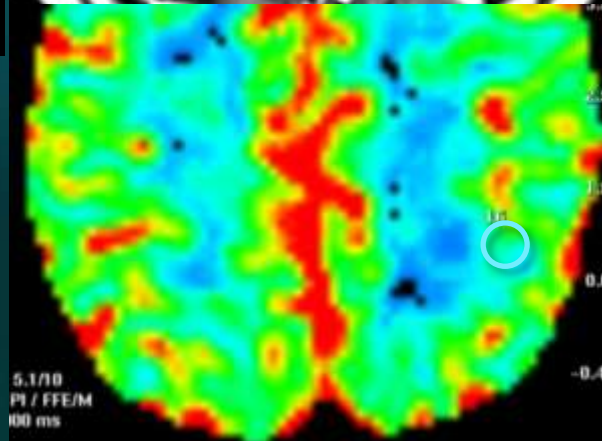
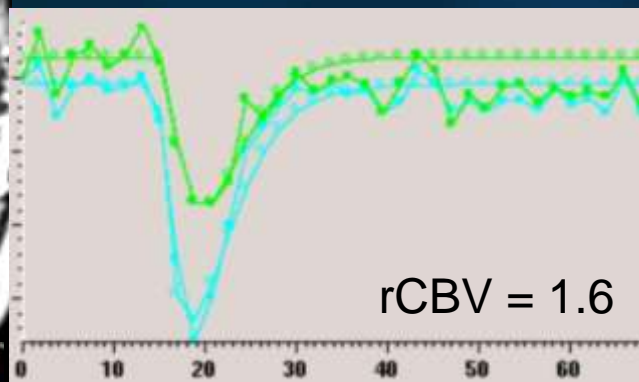
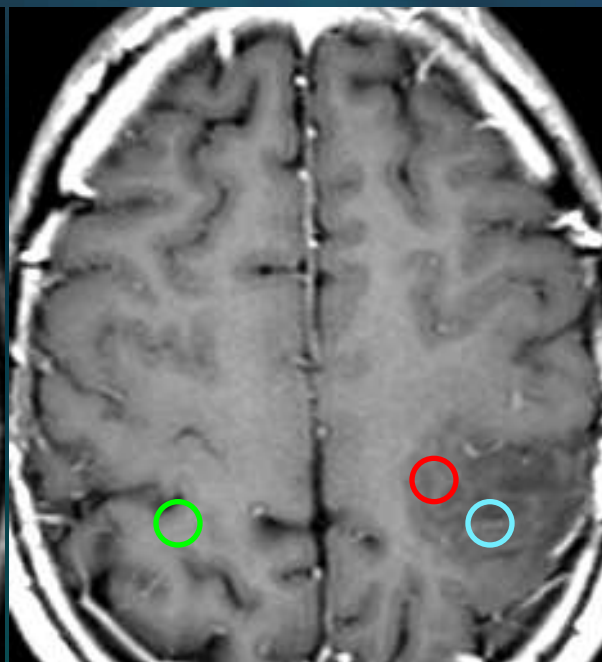
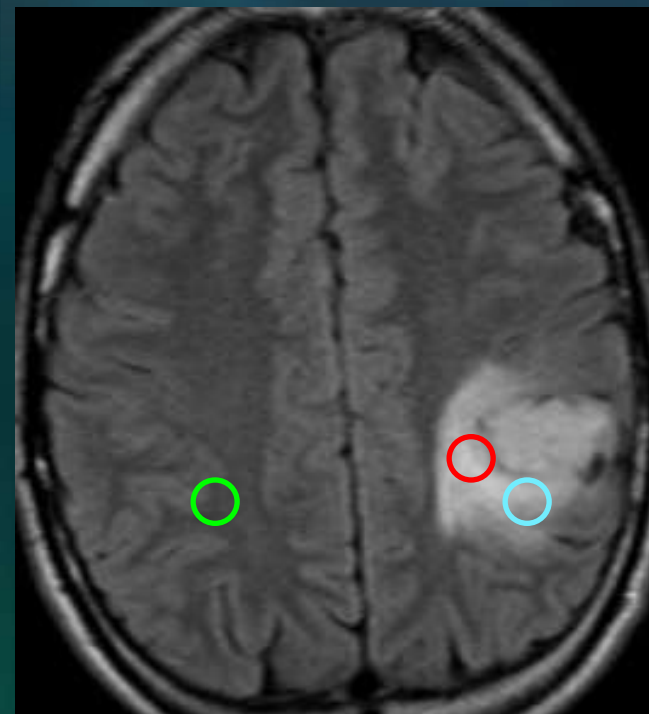


rCBV=2.6 (néoangiogenèse)

Placement des ROI - pièges

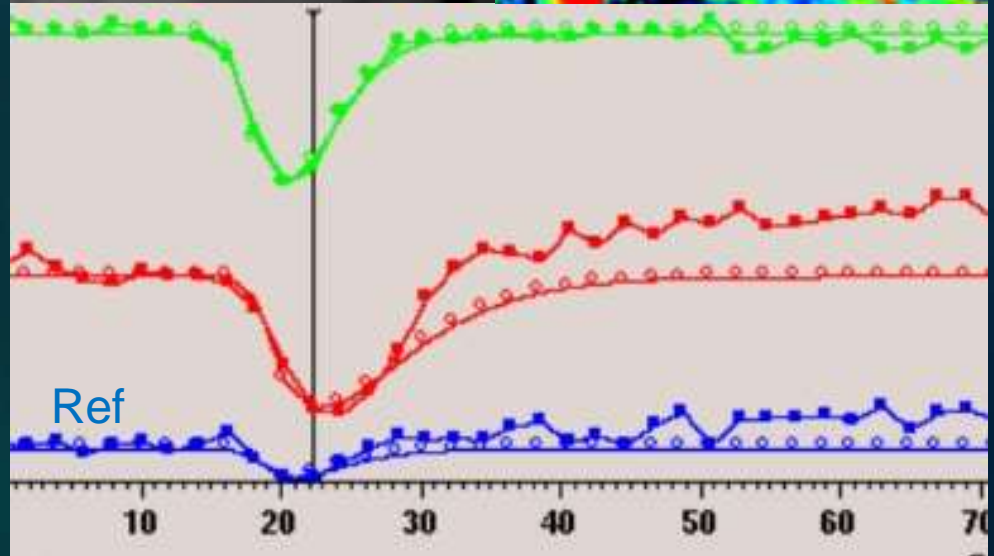
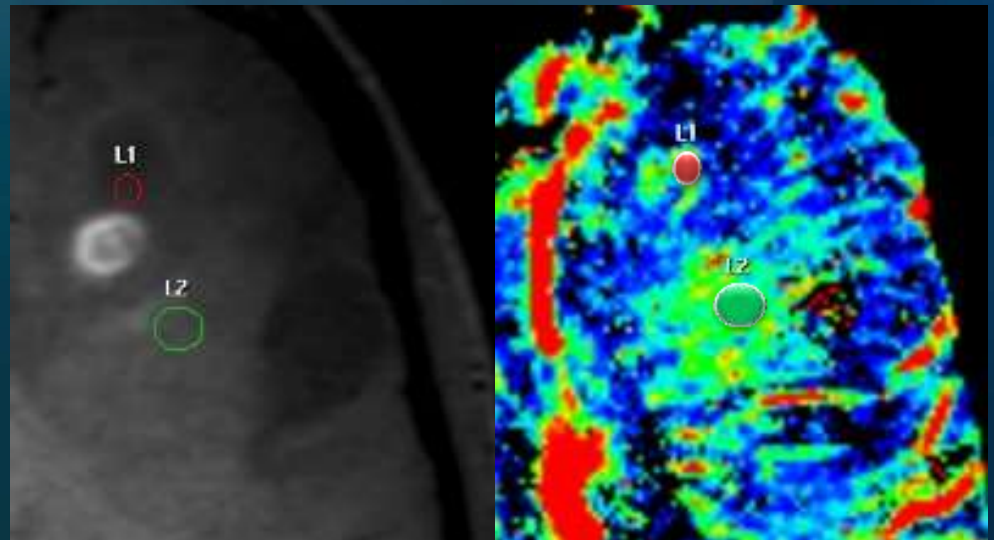
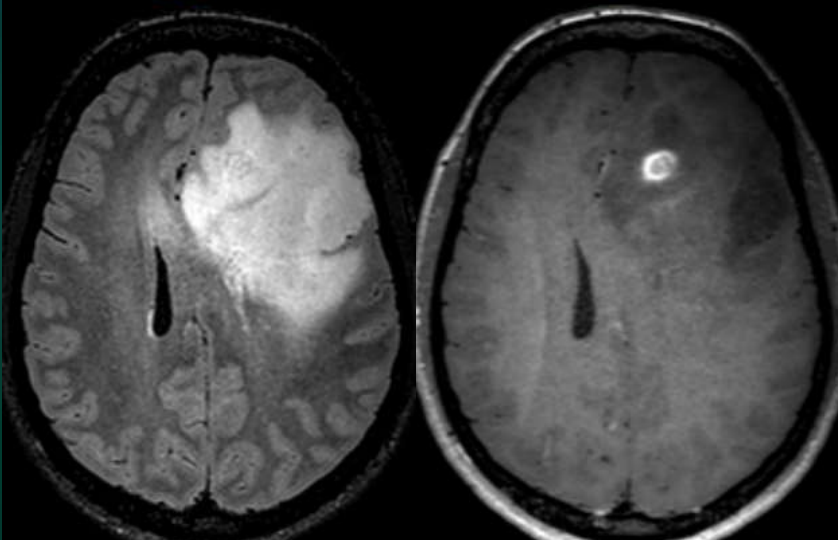
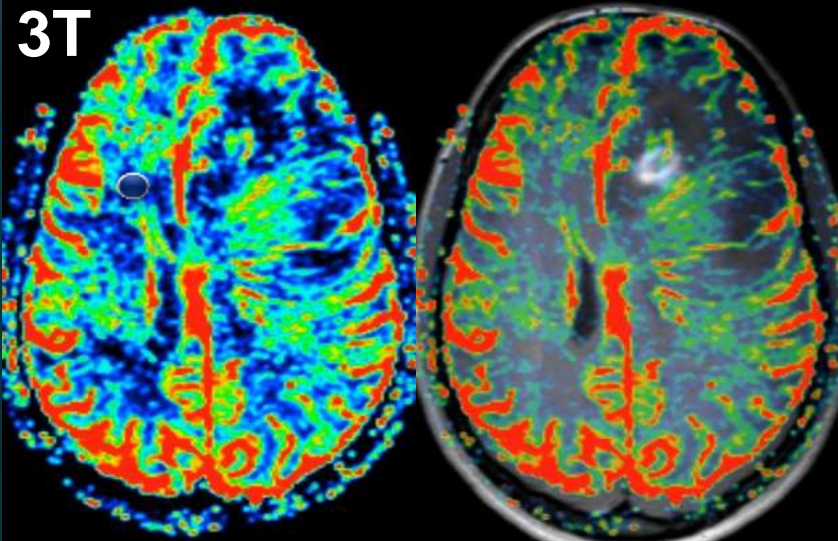
Vaisseaux normaux

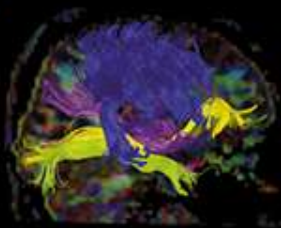
Gliome de bas grade
Suivi à 2 ans : pas de transformation



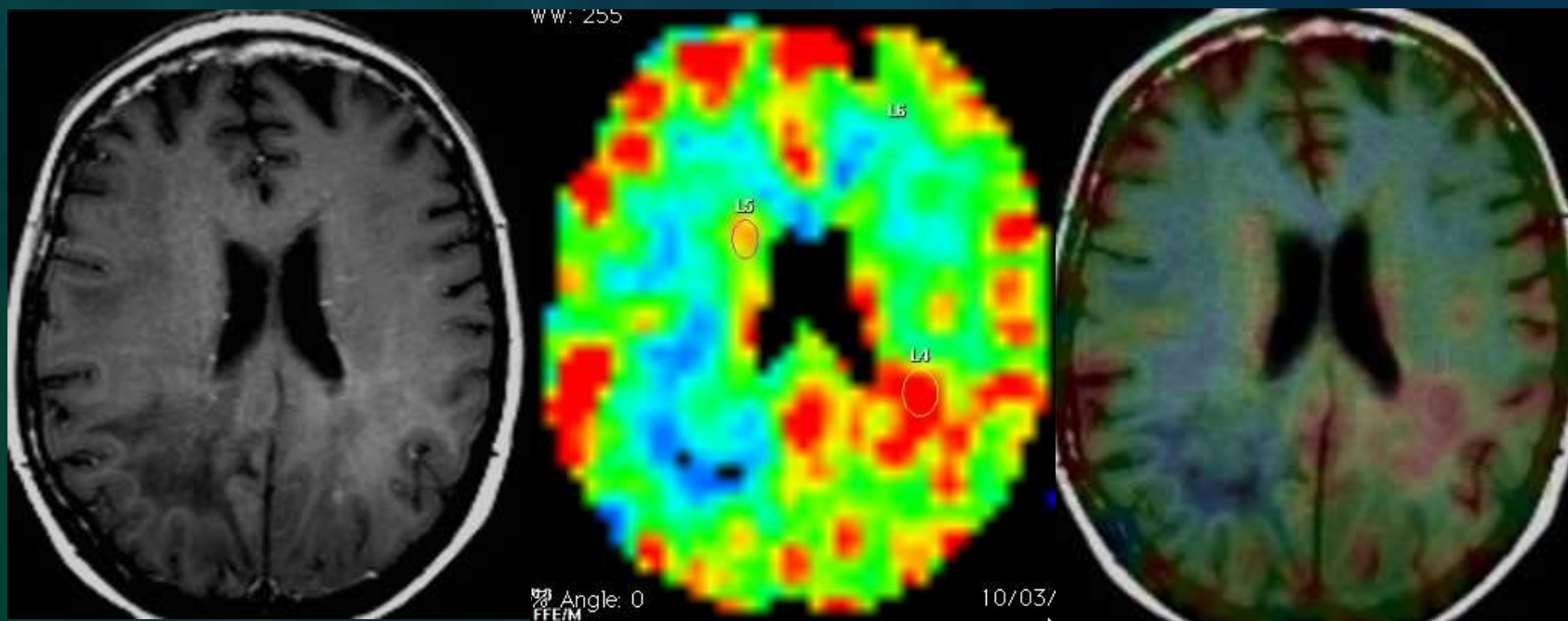
Placement des ROI – pièges

Décalage et néoangiogenèse sans PDC



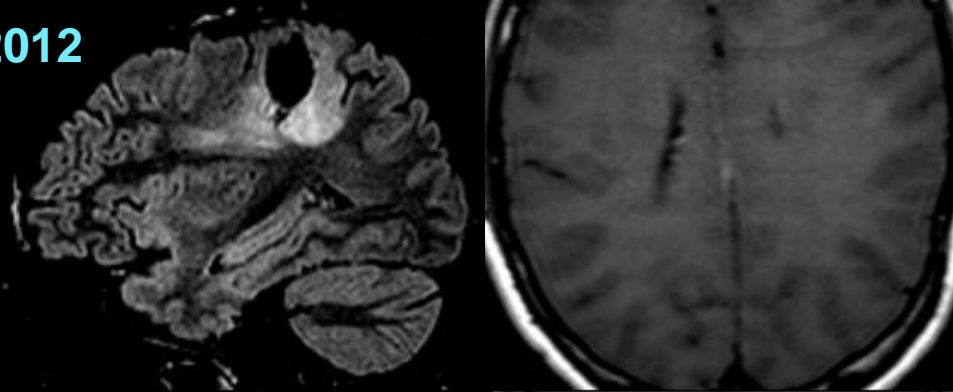


Implémenter la perfusion pour éviter les pièges diagnostiques du suivi : Transformation anaplasique

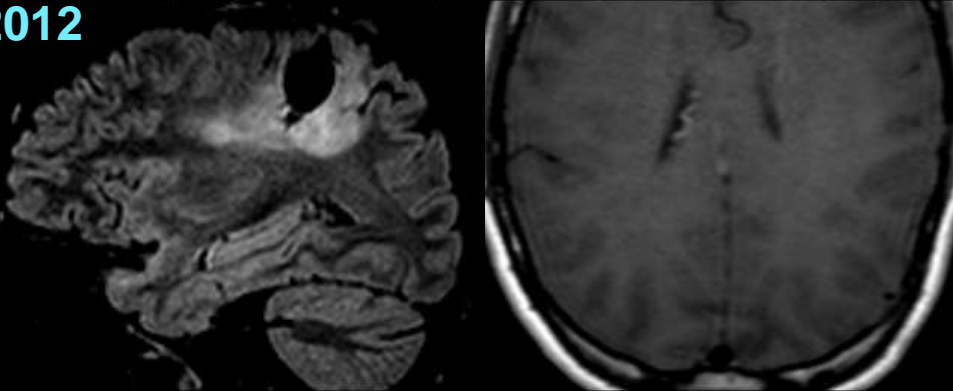


Gliome de bas grade : transformation anaplasique ?

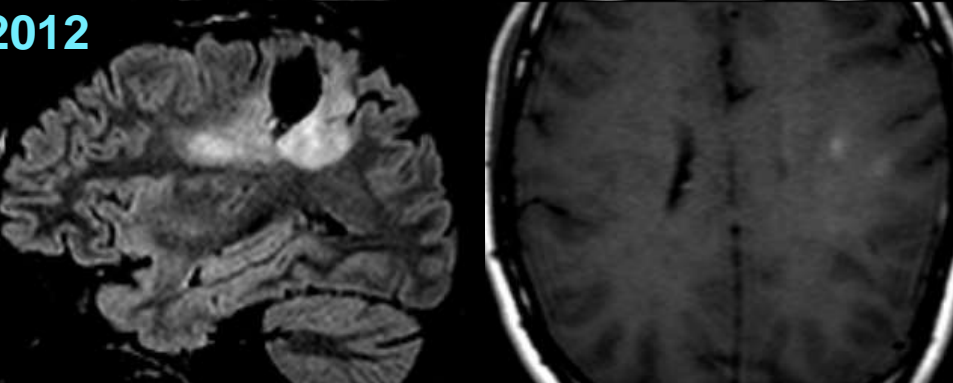
06/2012



10/2012

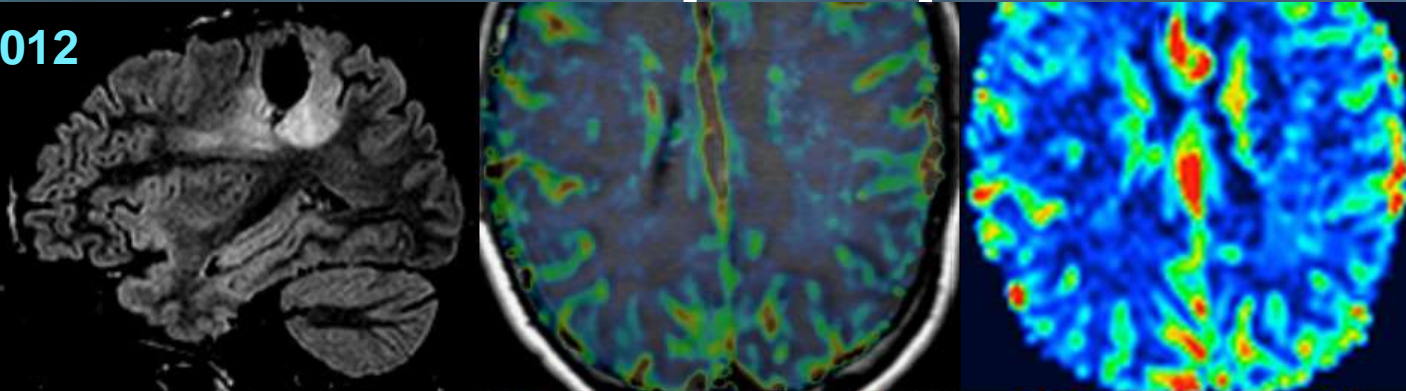


12/2012

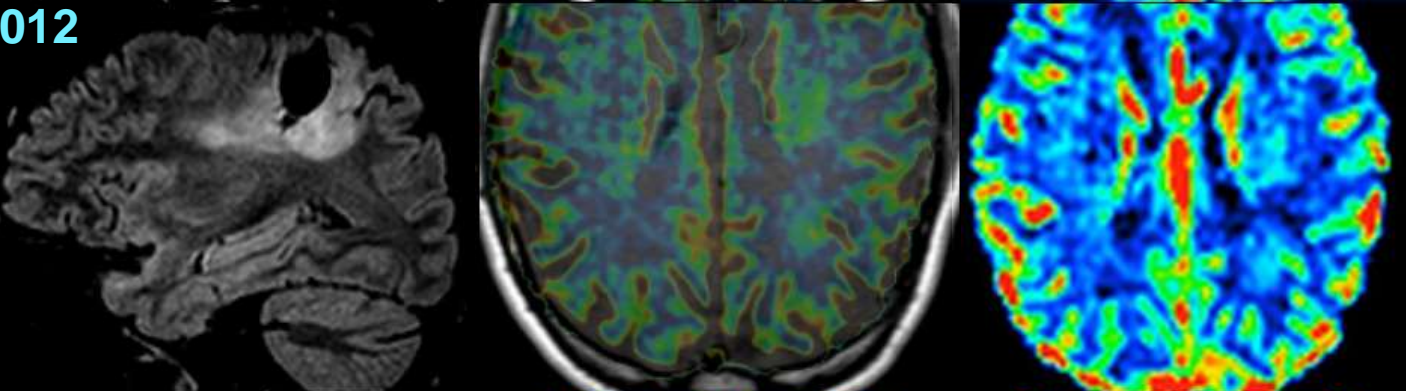


Gliome de bas grade : transformation anaplasique ?

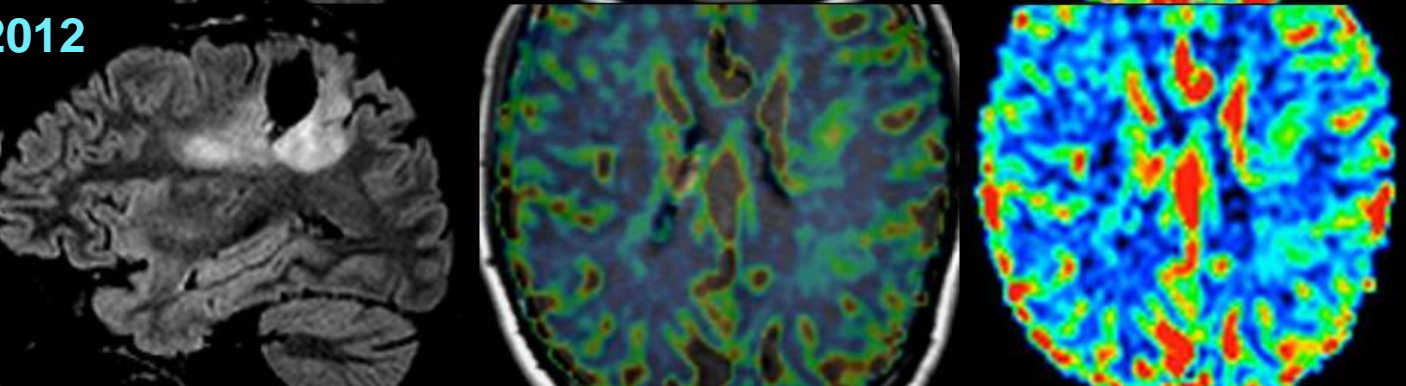
06/2012

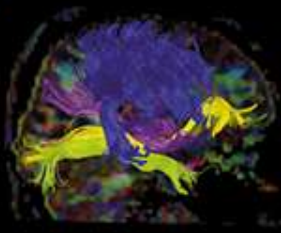


10/2012

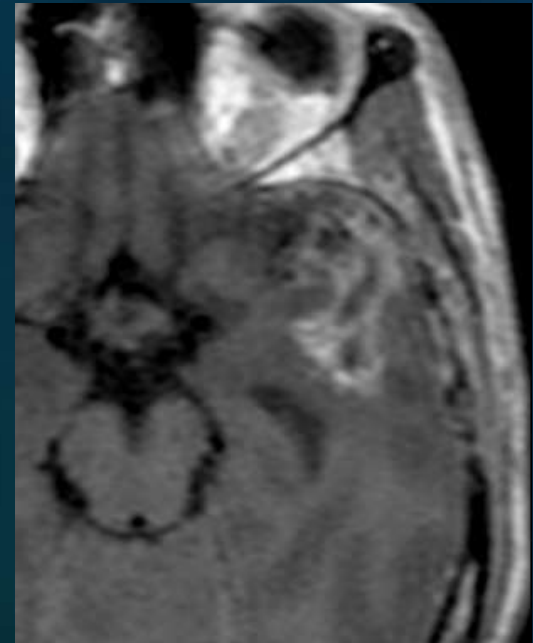
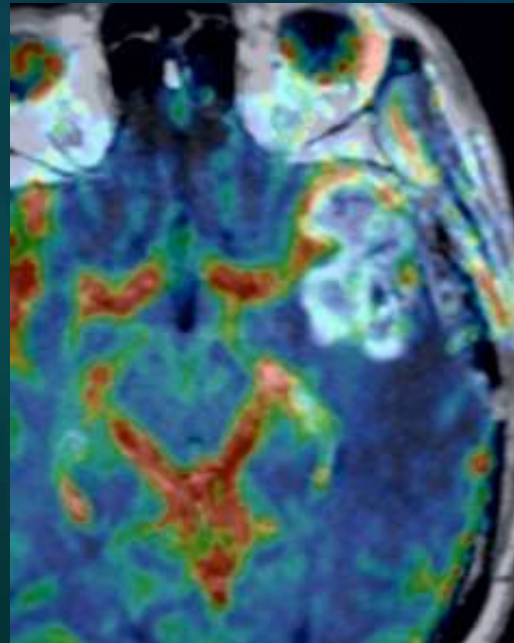
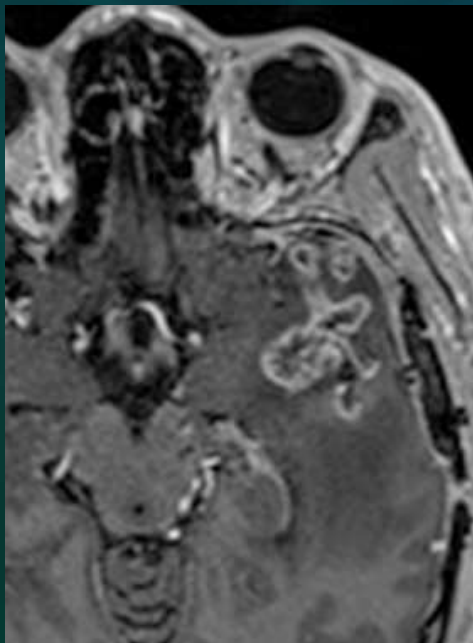


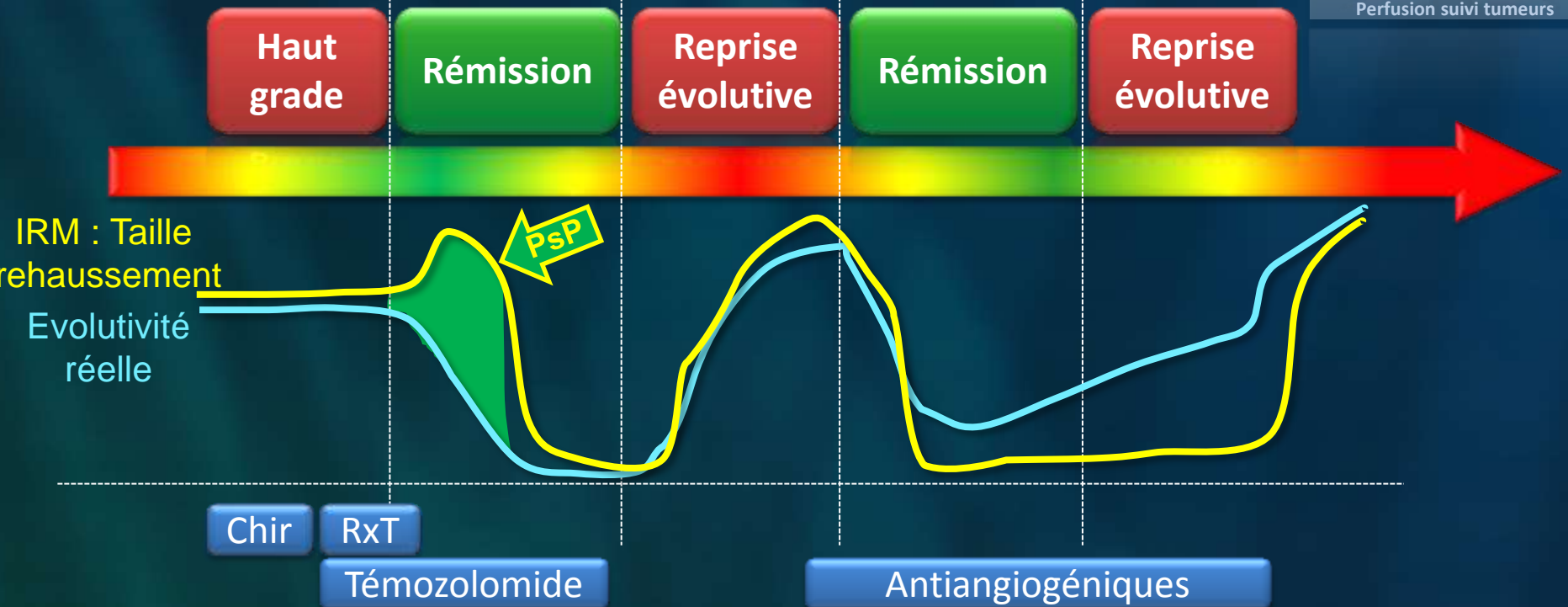
12/2012





Implémenter la perfusion pour éviter les pièges diagnostiques du suivi : Pseudo-progression





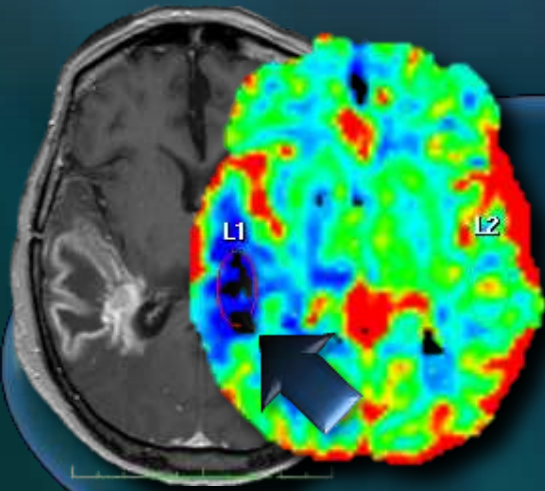
Augmentation de taille du **rehaussement**
malgré l'efficacité du traitement
Diagnostic erroné de progression

Nécrose
Inflammation

Pseudo-progression

But de la perfusion :

« C'est quoi cette prise de contraste T1 ? »



Rupture de
la BHE

Gliome de haut grade
Evolutifs

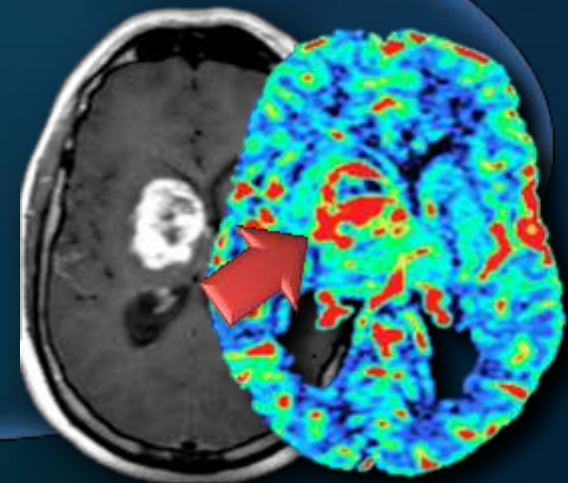
Gliome de haut grade
Evolutifs

Néo-
angiogenèse

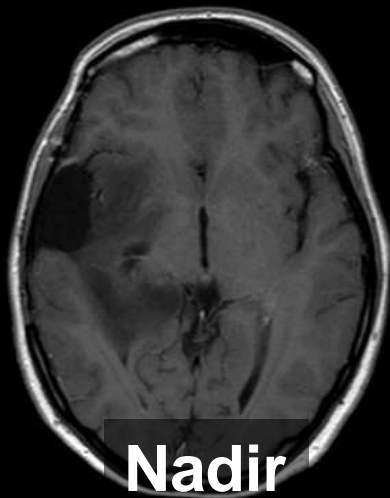
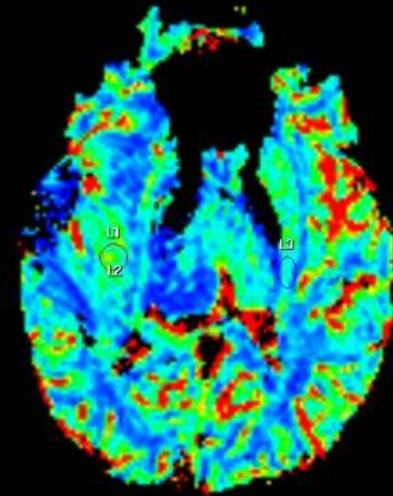
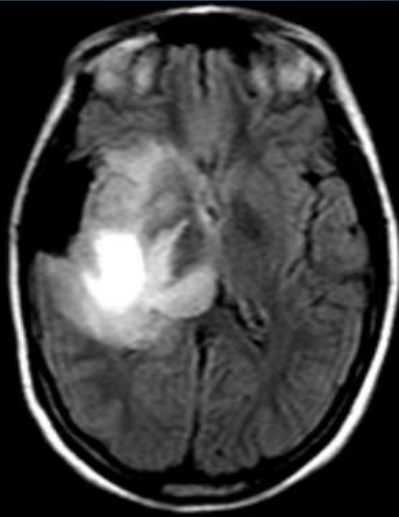
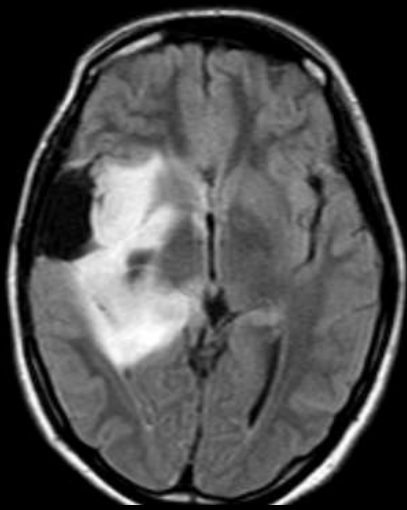
Pseudoprogression

Radionécrose

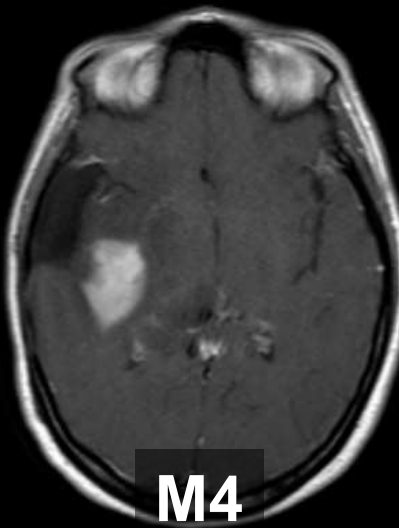
Réaction cytotoxique
post-op



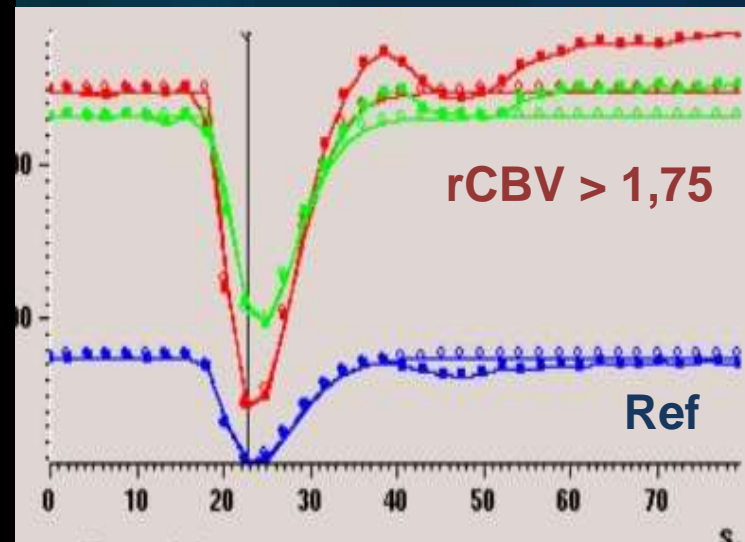
F, 37 ans, Astro III Stupp, 18 mois après RT



Nadir



M4

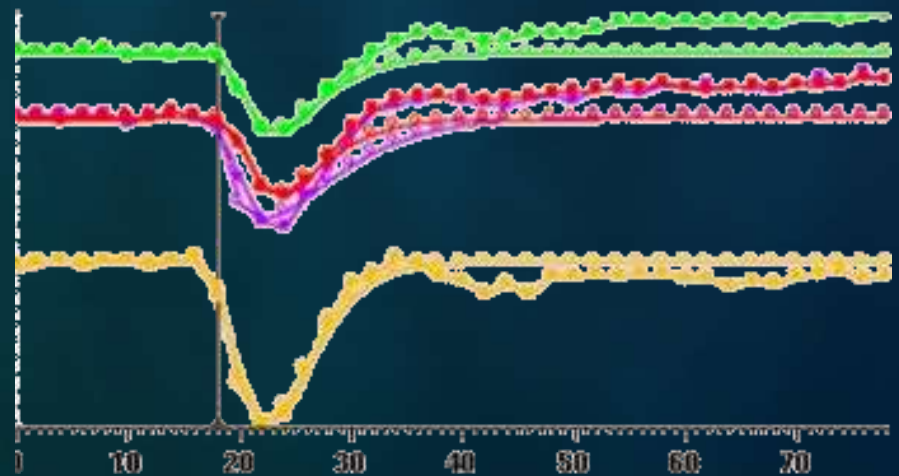
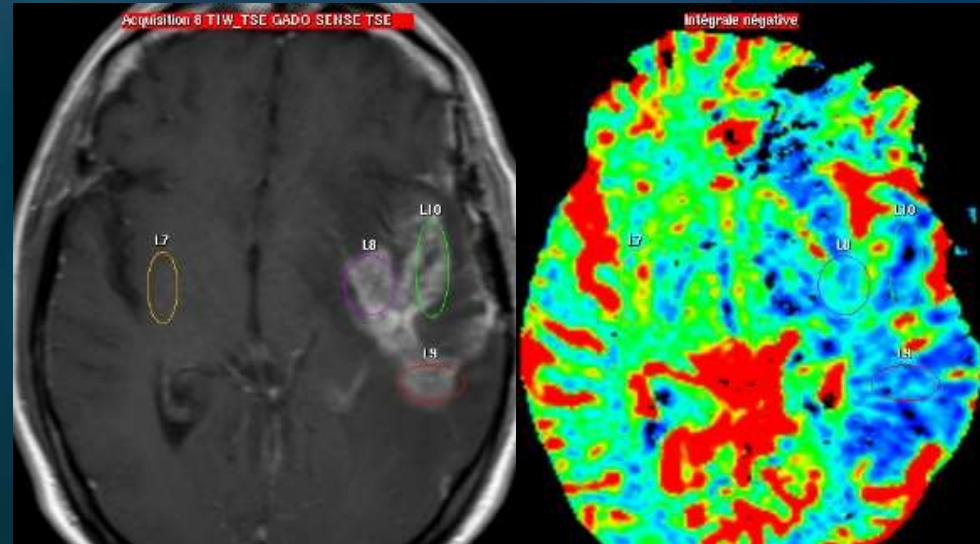
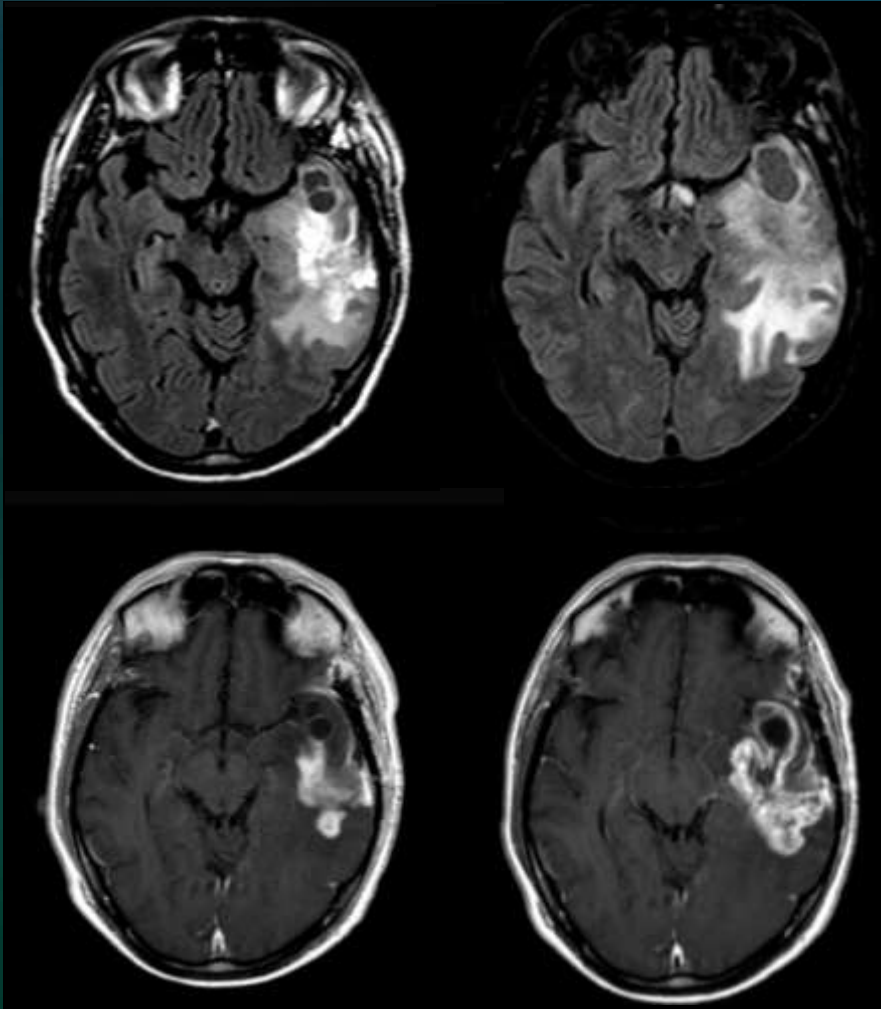


Homme, 52 ans

GBM, chir puis rayons + TMZ

M0

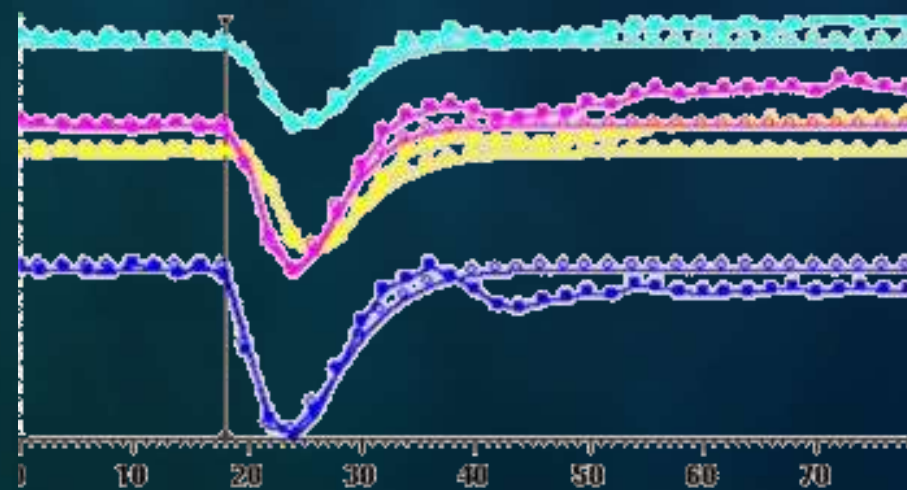
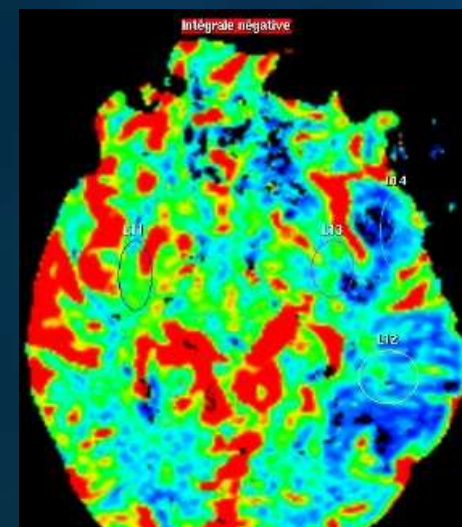
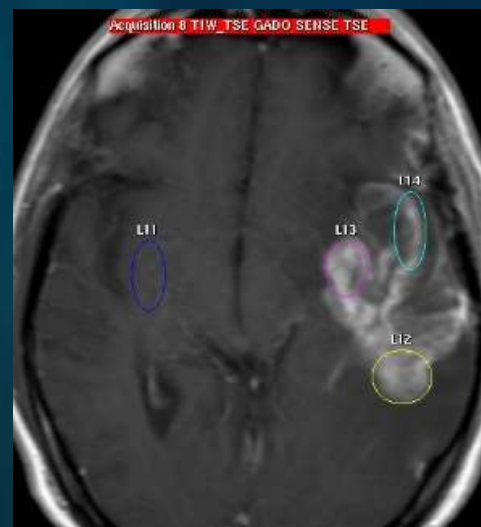
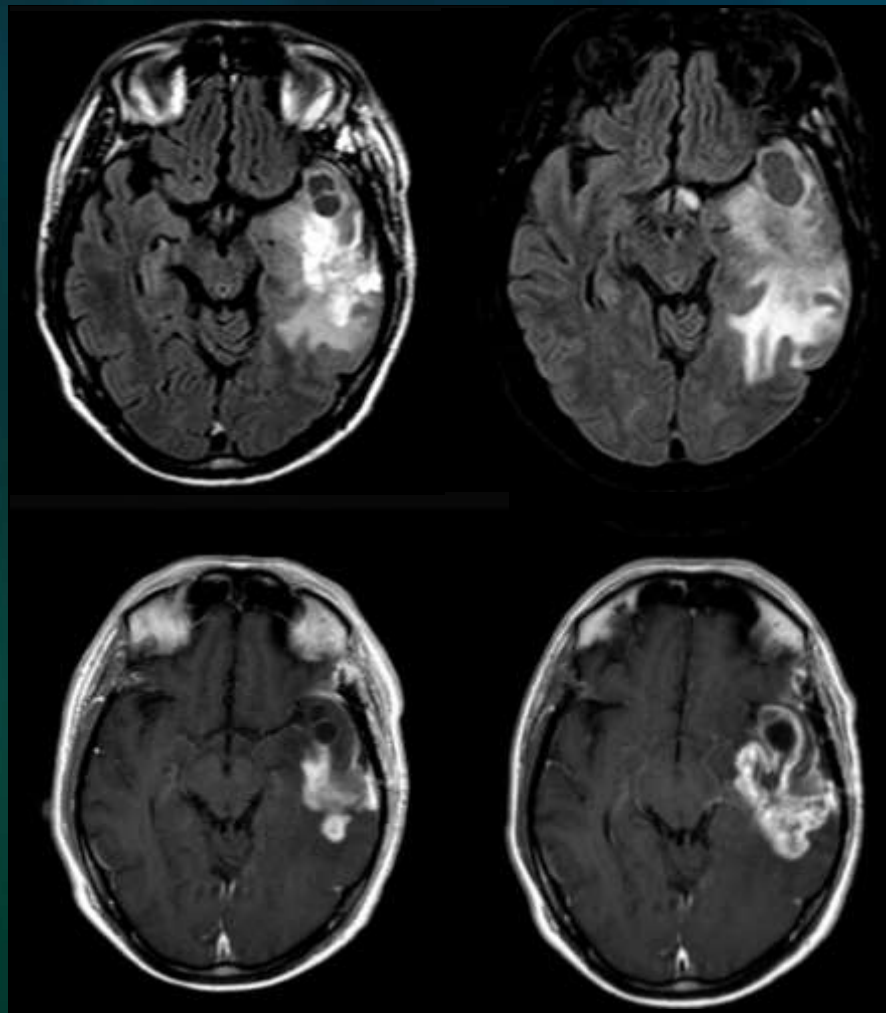
M4





M0

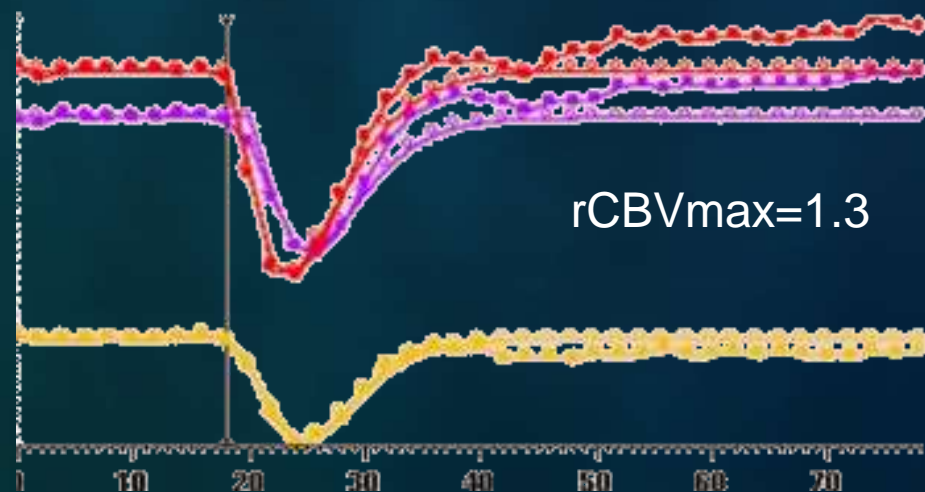
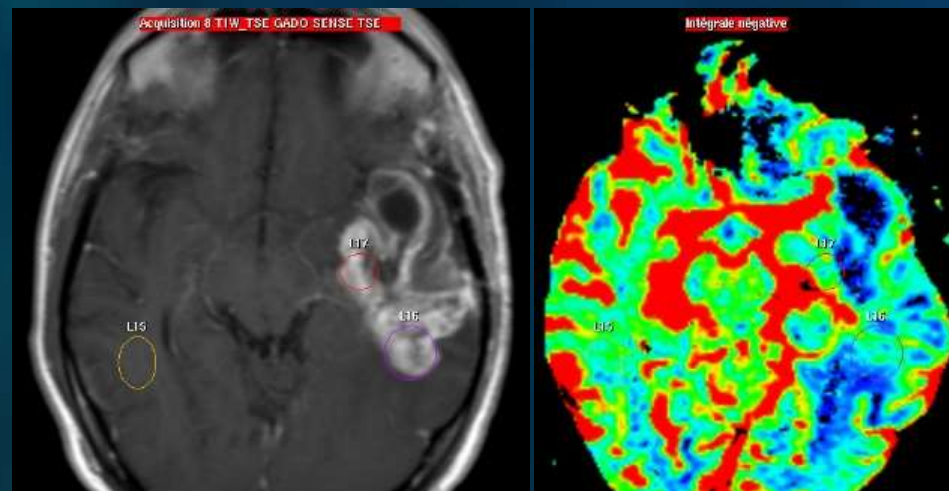
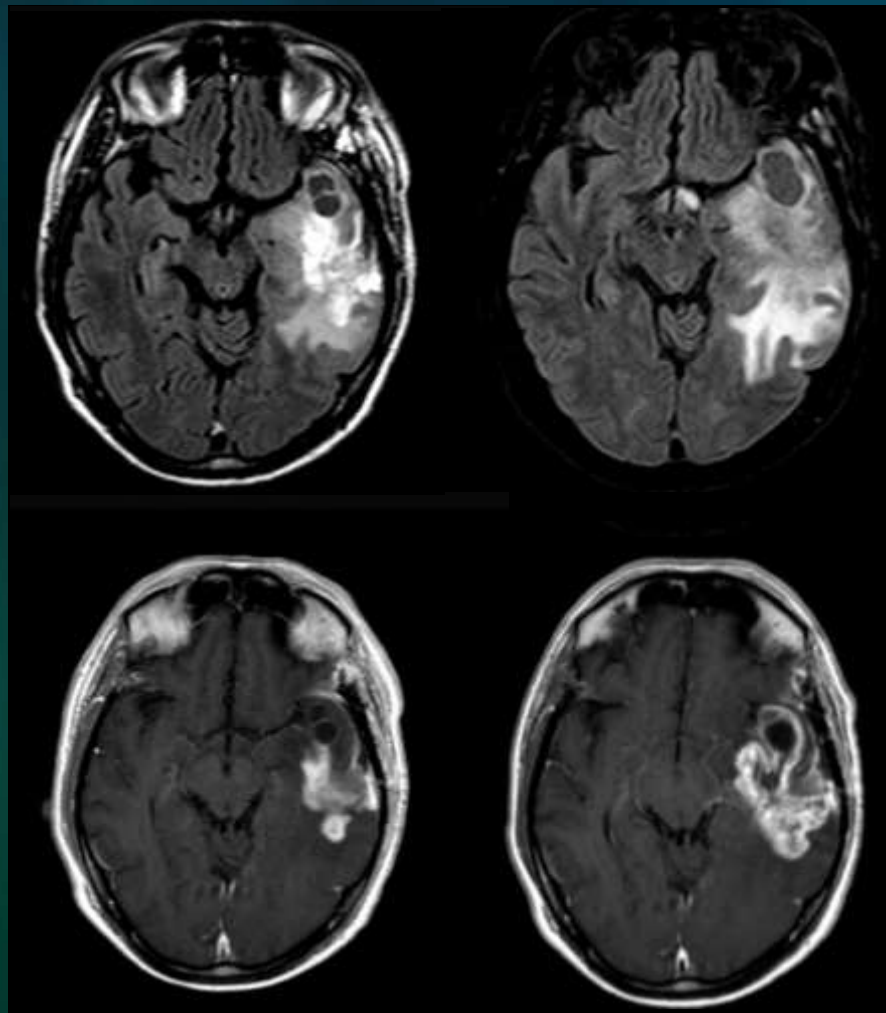
M4





M0

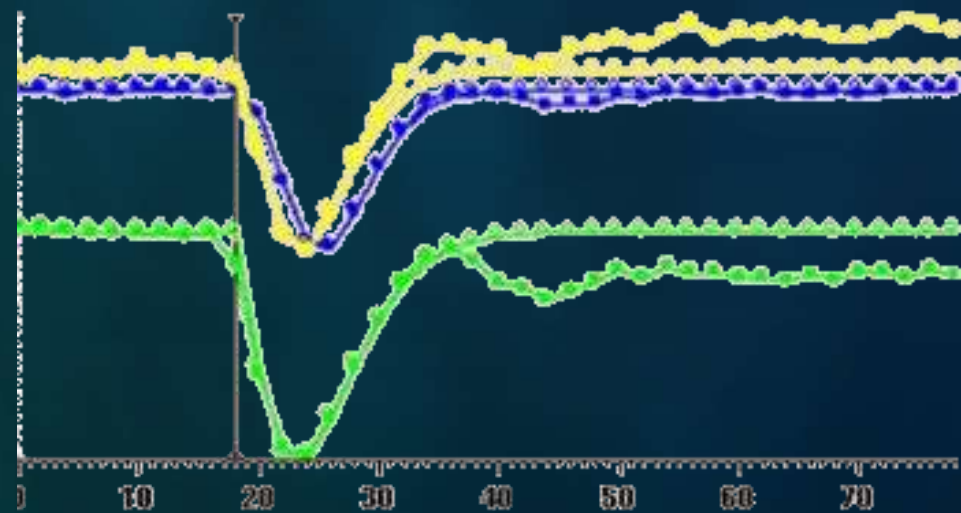
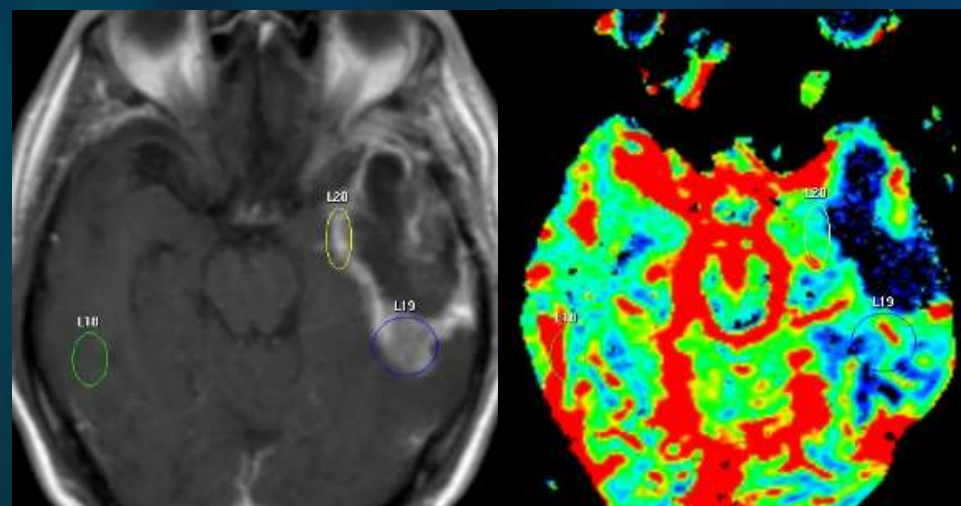
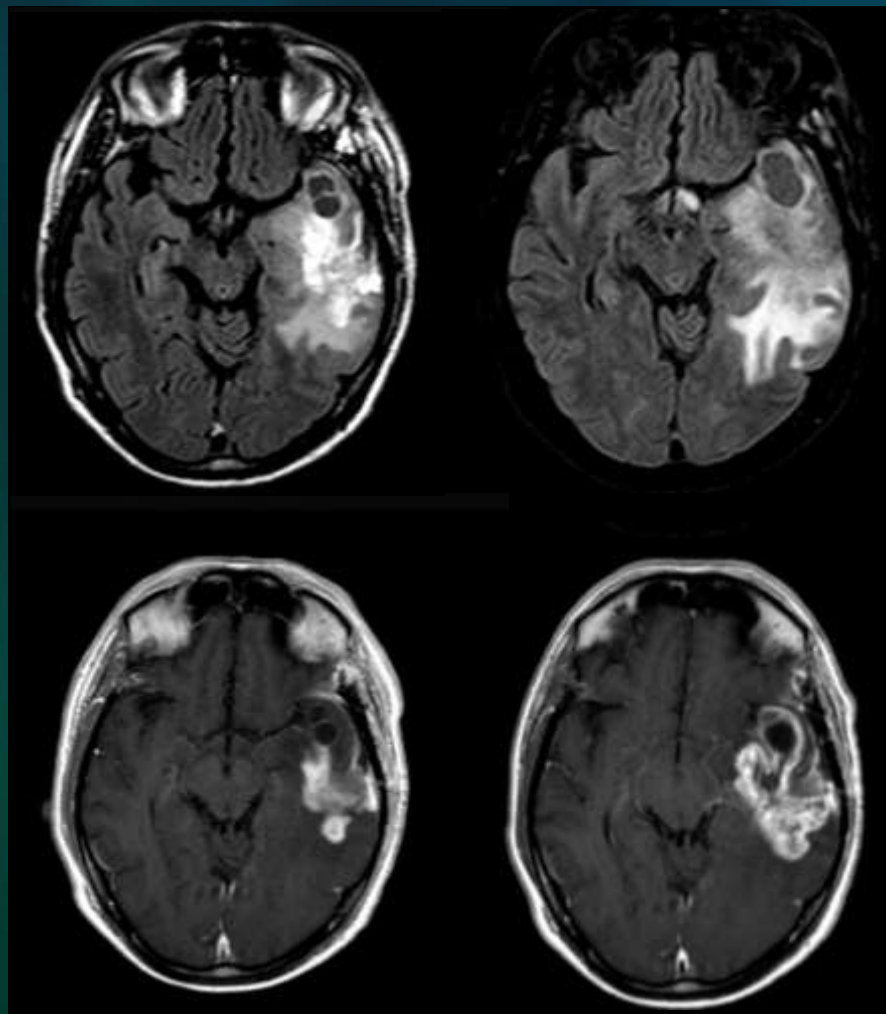
M4





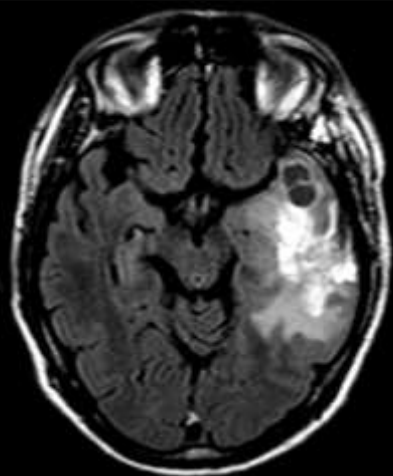
M0

M4

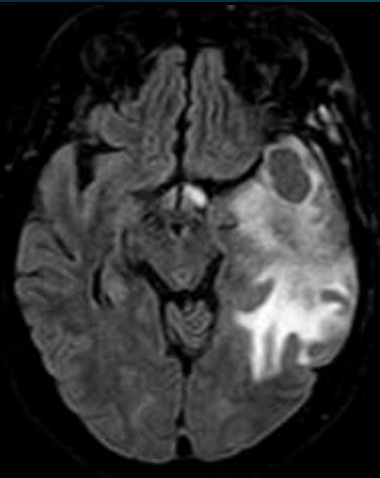




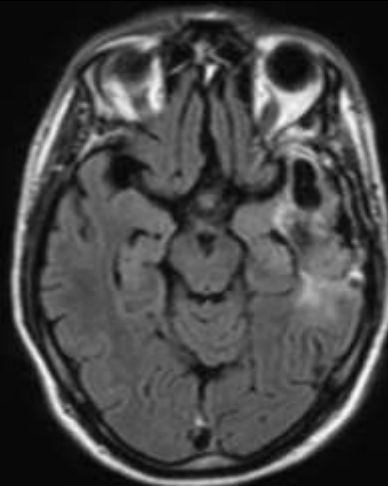
M0



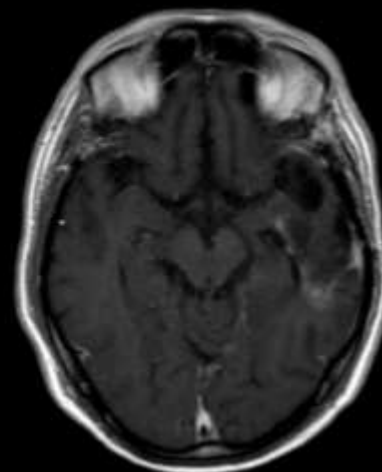
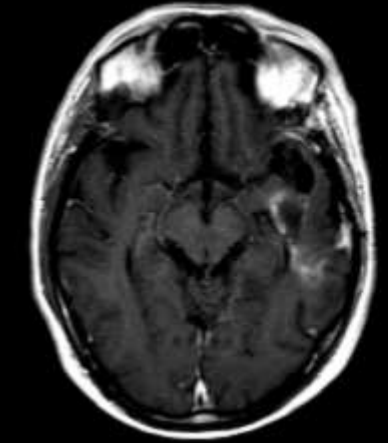
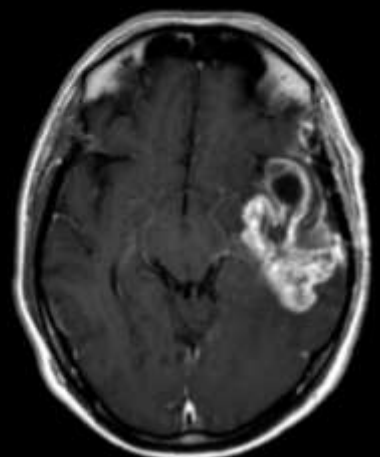
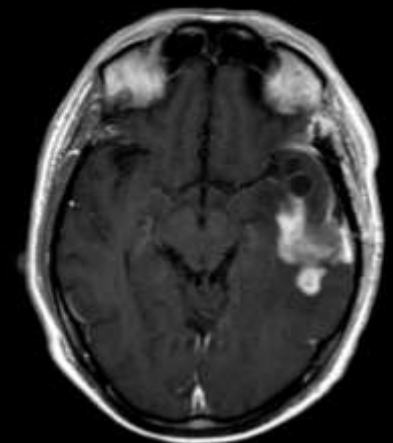
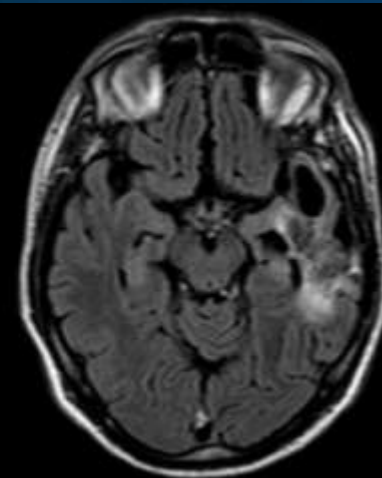
M4



M5



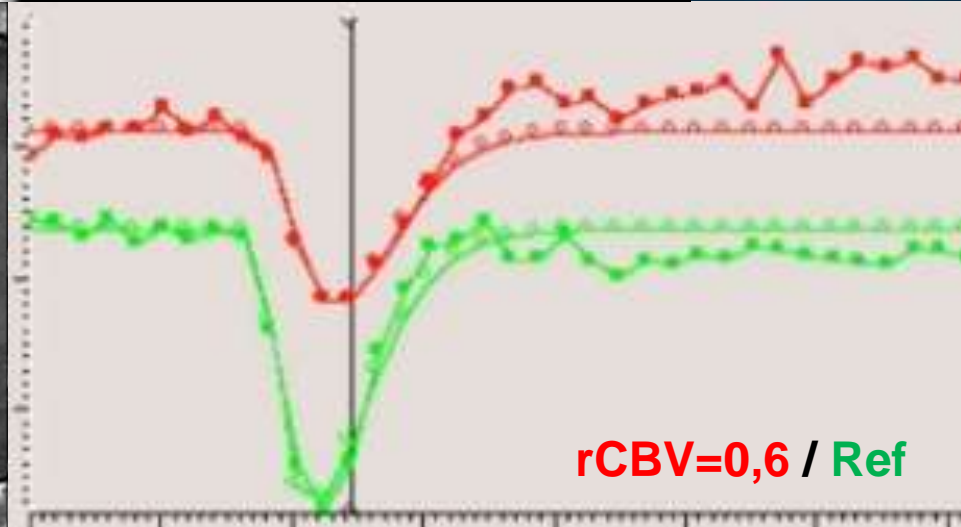
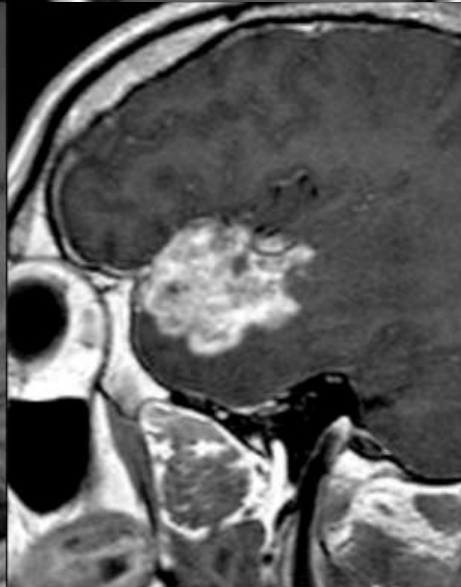
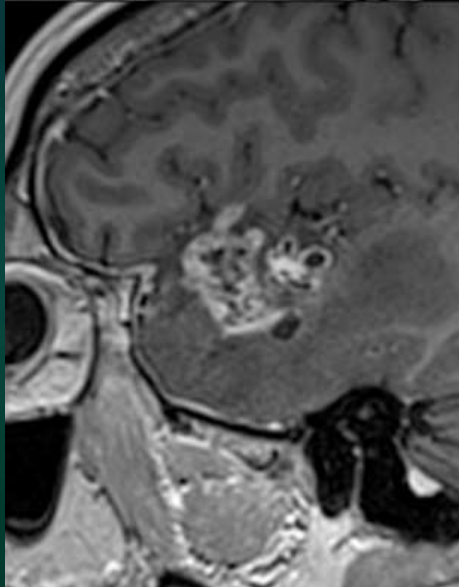
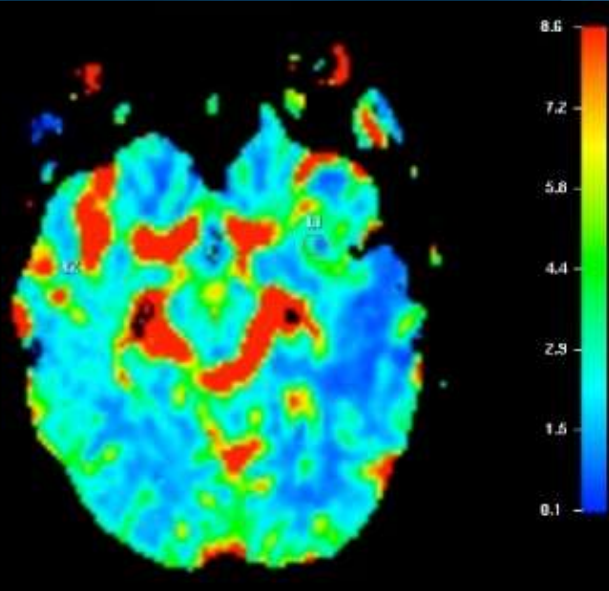
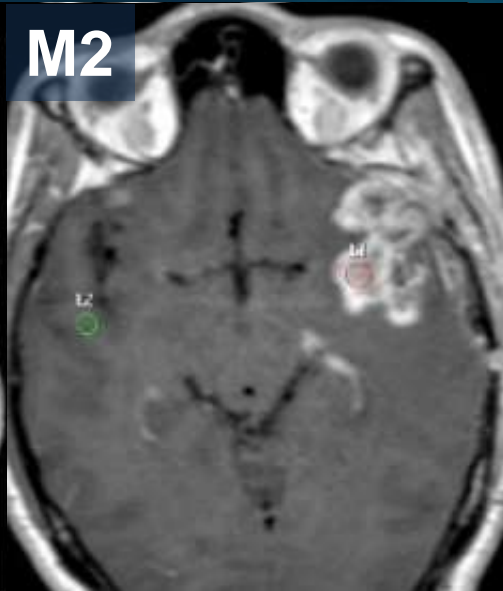
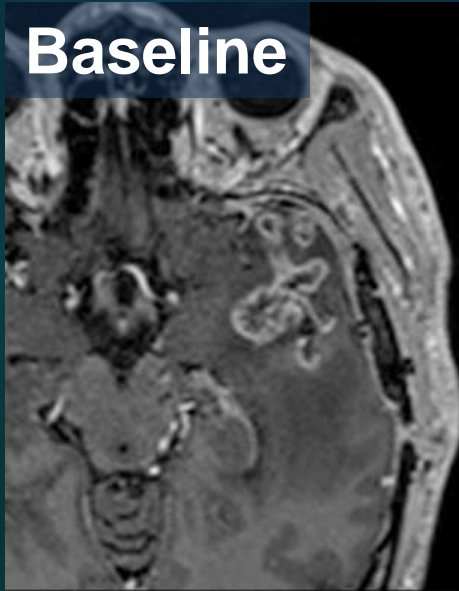
M7



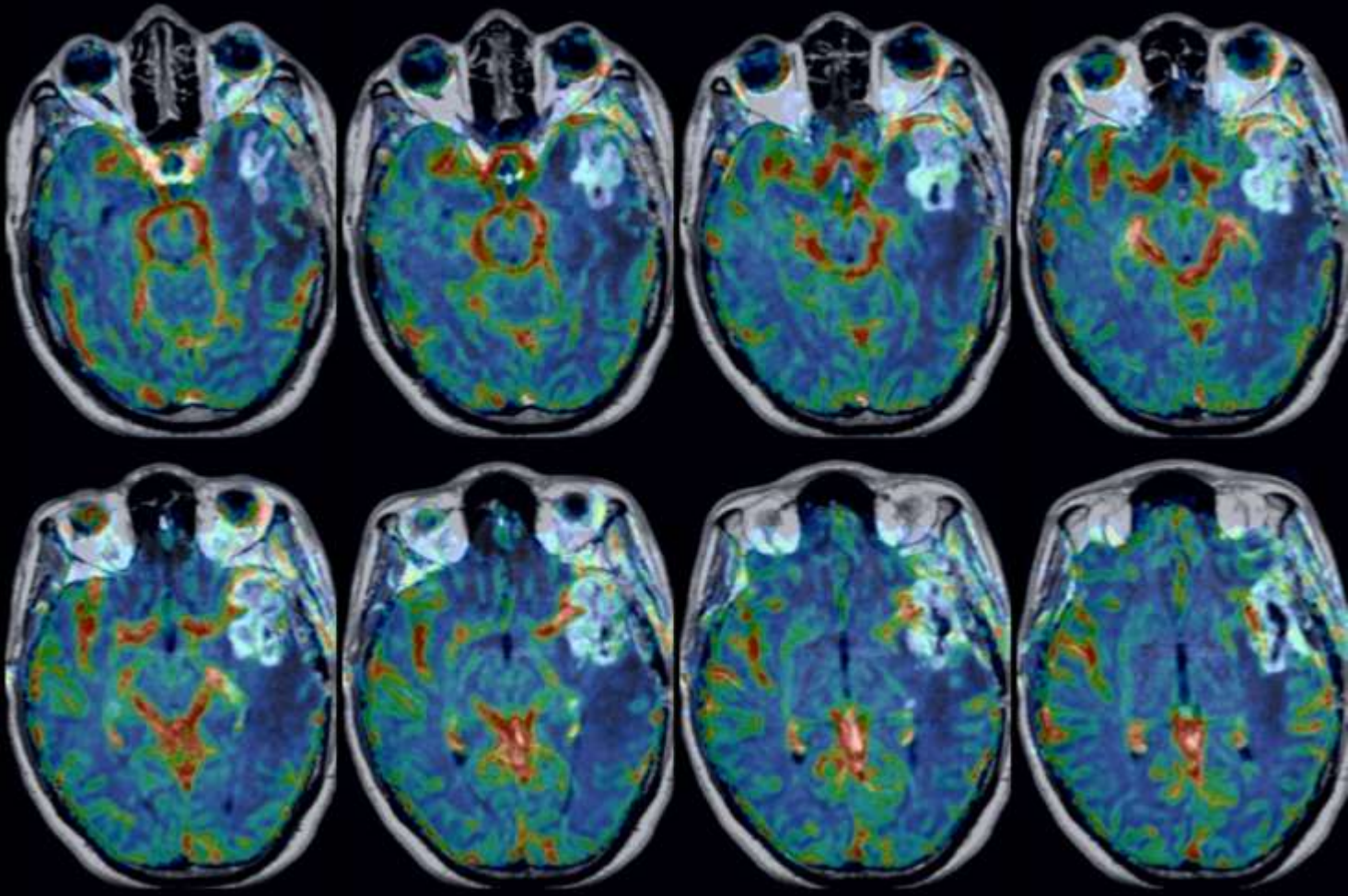
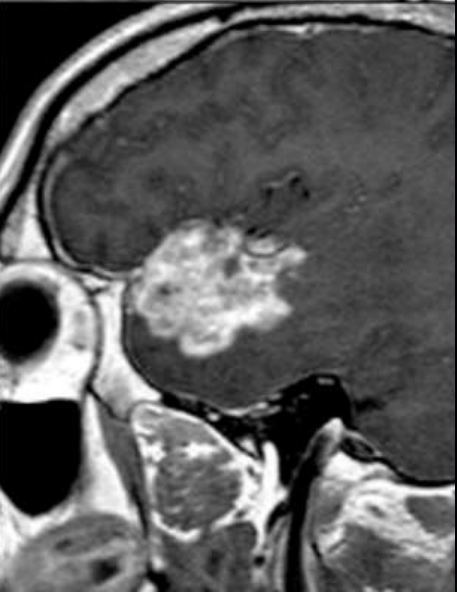
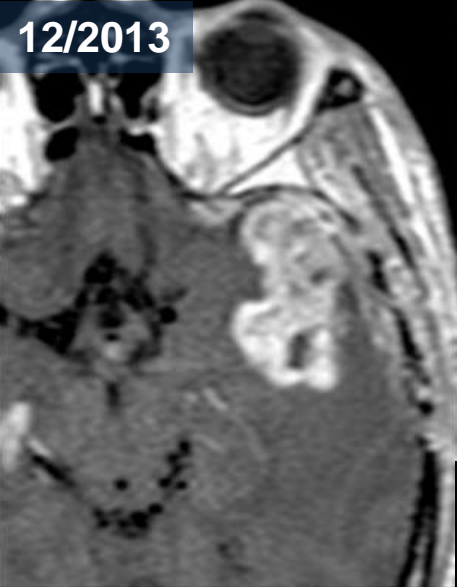
H, 43 ans, Oligo III, Stupp

Baseline

M2



12/2013



J. Savatovsky
Perfusion suivi tumeurs

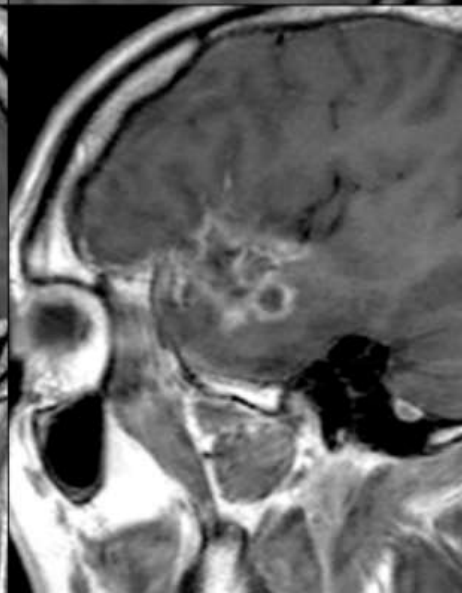
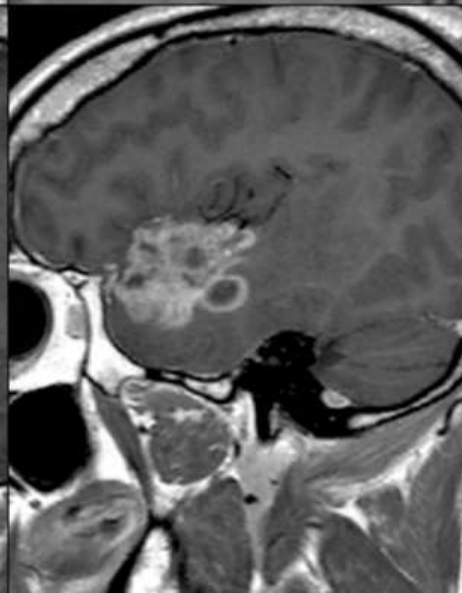
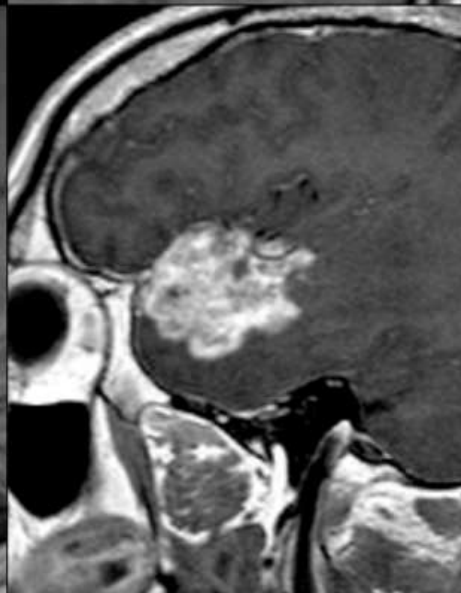
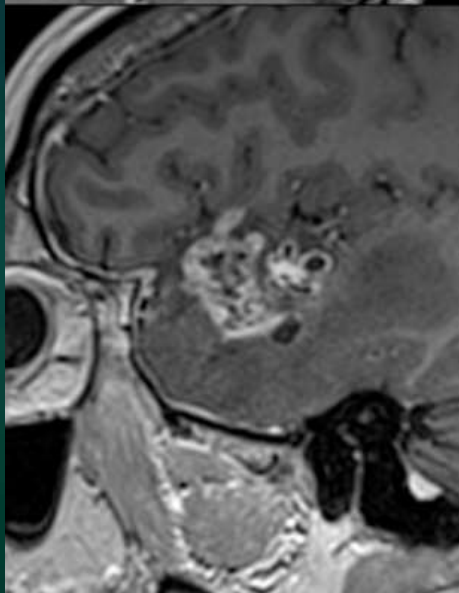
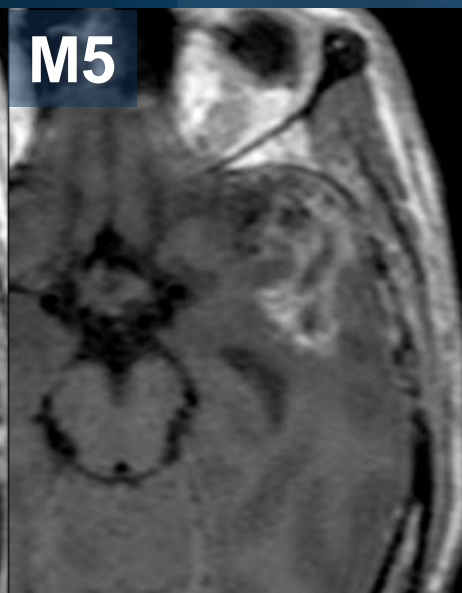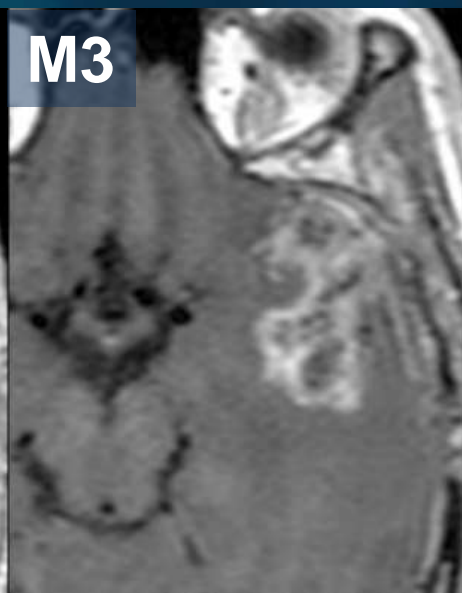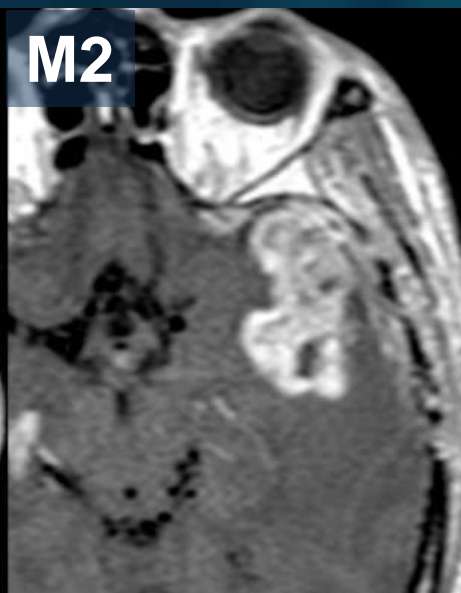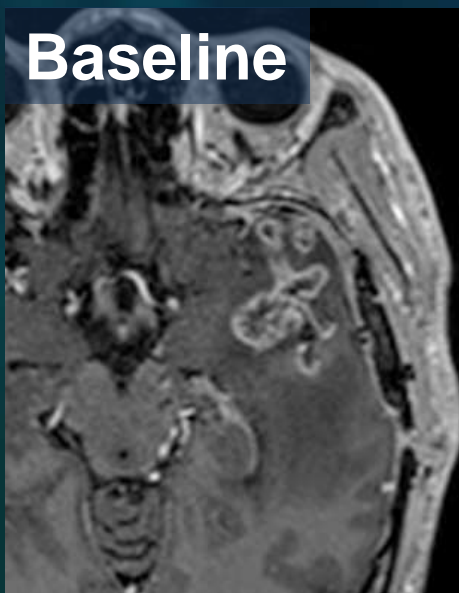


Baseline

M2

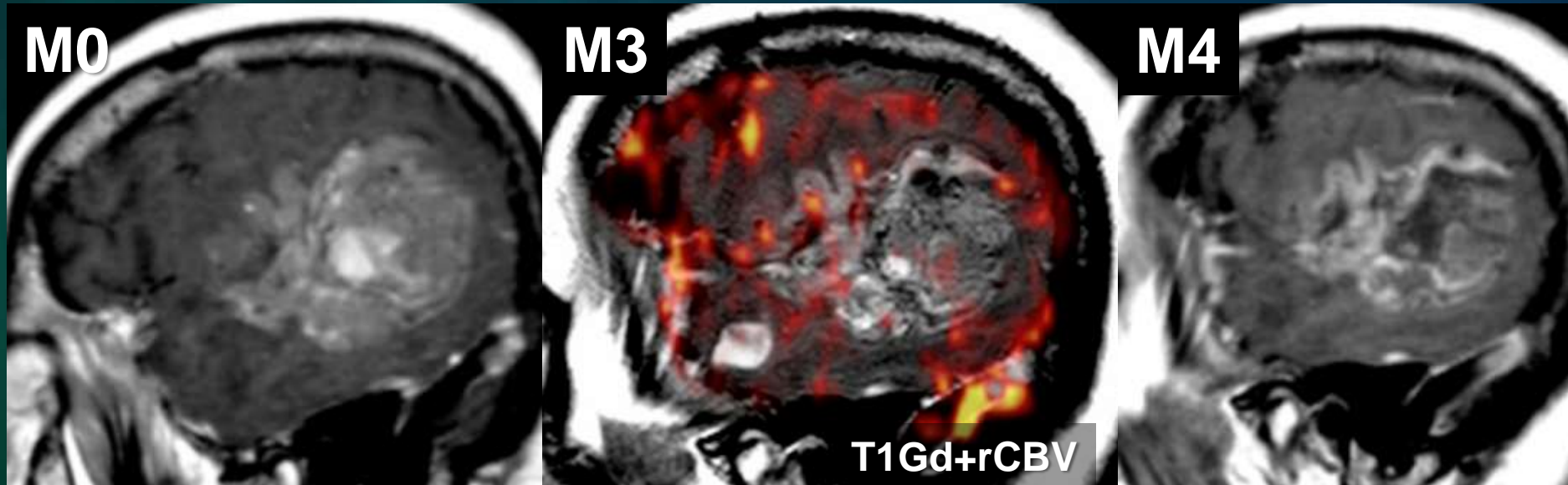
M3

M5

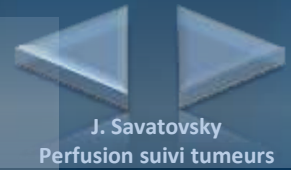


Pseudo-progression avec nouveau rehaussement

- Séparé du rehaussement cible
- Dans le champ de radiothérapie
- Pas de néoangiogenèse



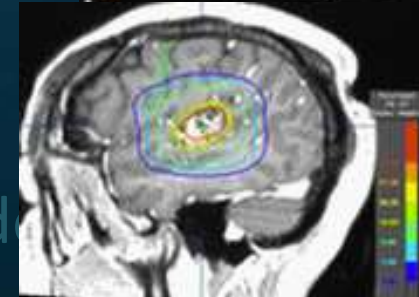
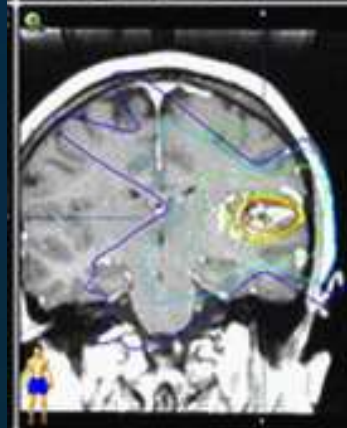
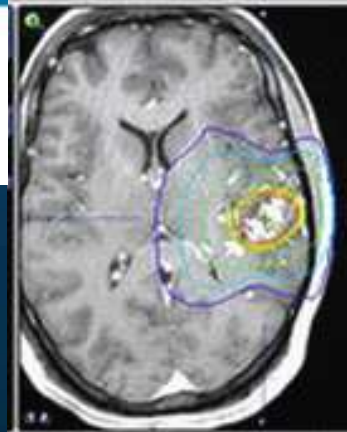
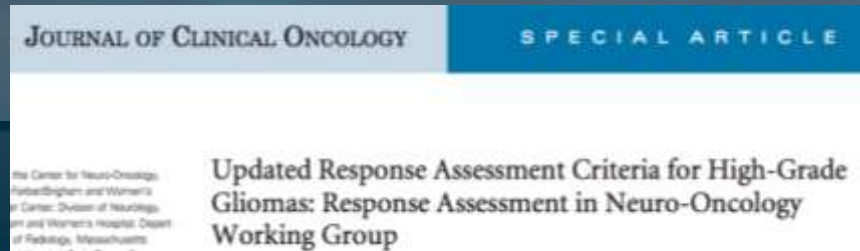
Critères pour une pseudo-progression



- Clinique
 - Fréquent : 30% ?
 - Dans les 6 mois suivant la RT
 - Méthylation du promoteur de MGMT connue
- Imagerie conventionnelle
 - Rehaussement peu solide, « troué »
 - Dans le champ de RT
 - Contrôle rapproché : stabilité ou amélioration
- Perfusion
 - Absence de néoangiogenèse sur la majorité de la PDC

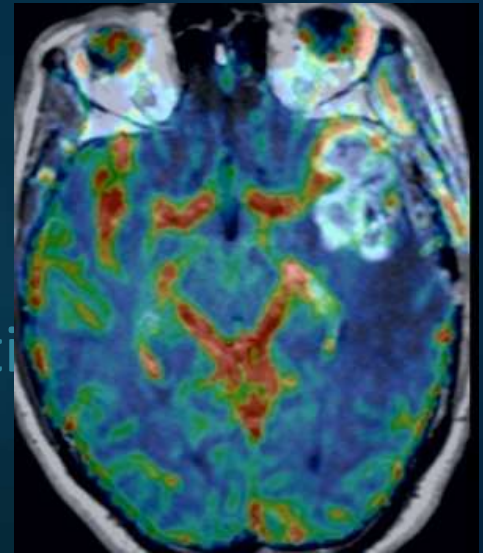
Critères pour une pseudo-progression

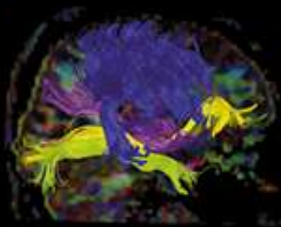
- Clinique
 - Fréquent : 30% ?
 - Dans les 6 mois suivant la RT
 - Méthylation du promoteur de MGMT connue
- Imagerie conventionnelle
 - Rehaussement peu solide, « troué »
 - Dans le champ de RT
 - Contrôle rapproché : stabilité ou amélioration
- Perfusion
 - Absence de néoangiogenèse sur la majorité d



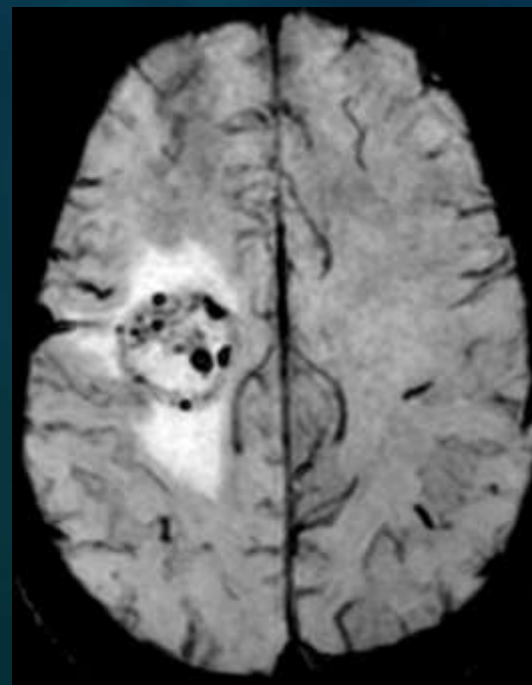
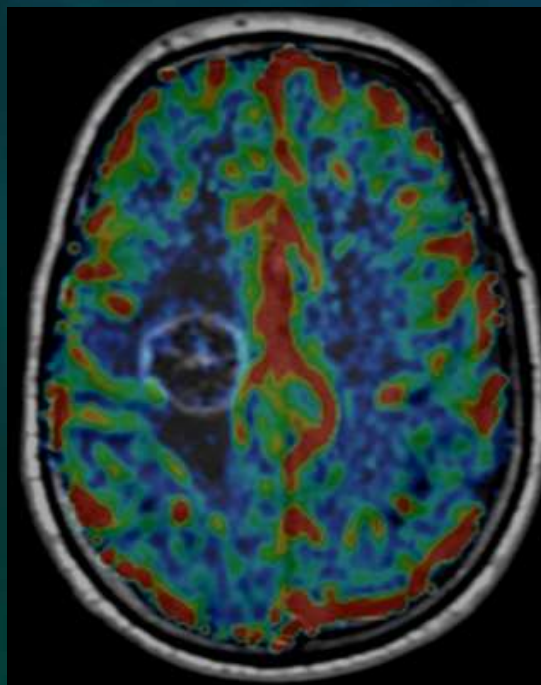
Critères pour une pseudo-progression

- Clinique
 - Fréquent : 30% ?
 - Dans les 6 mois suivant la RT
 - Méthylation du promoteur de MGMT connue
- Imagerie conventionnelle
 - Rehaussement peu solide, « troué »
 - Dans le champ de RT
 - Contrôle rapproché : stabilité ou amélioration
- Perfusion
 - Absence de néoangiogenèse sur la majorité de la PDC

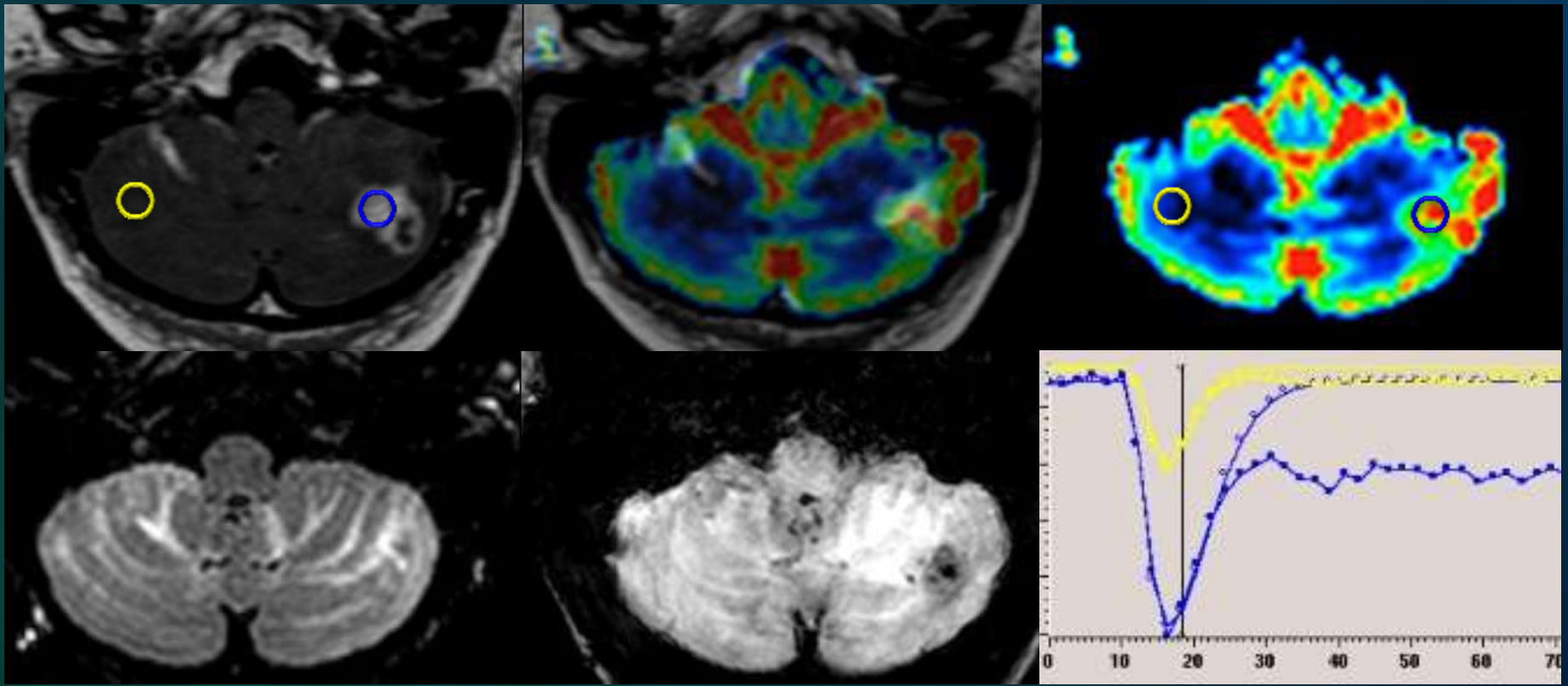




Implémenter la perfusion pour éviter les pièges diagnostiques du suivi : Radionécrose



Localisation secondaire traitée évolutive



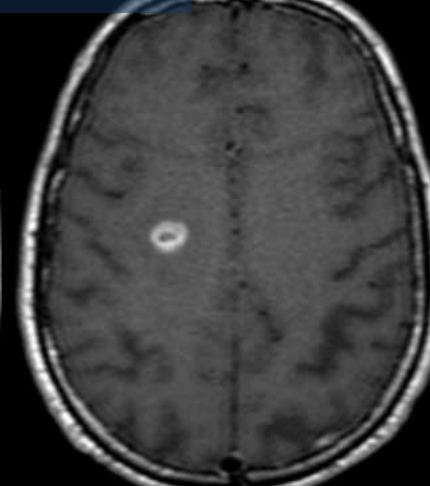
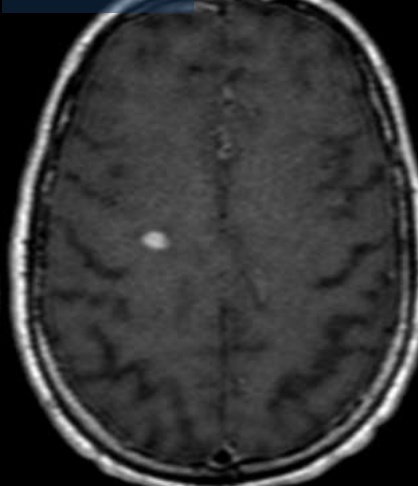
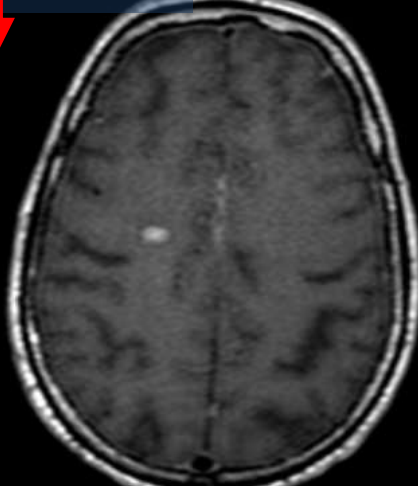
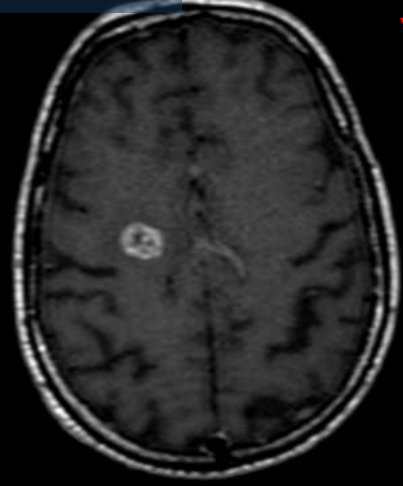
H, 65 ans, méta poumon. Radiochirurgie en décembre 2010

11/2010

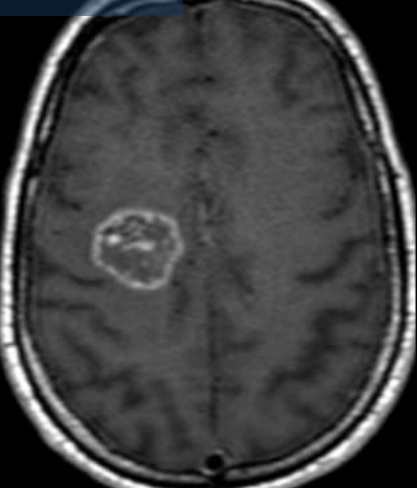
01/2011

02/2011

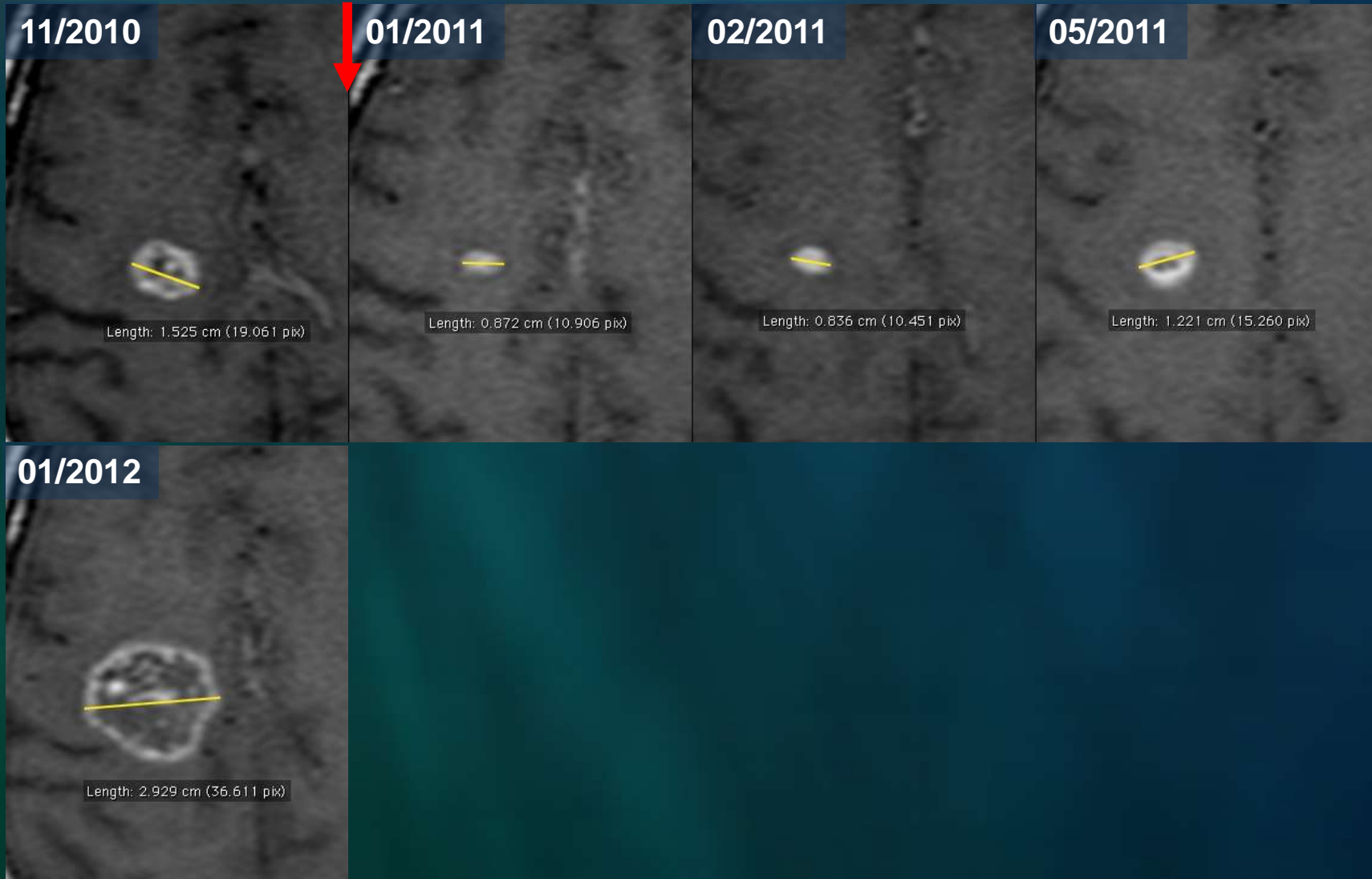05/2011

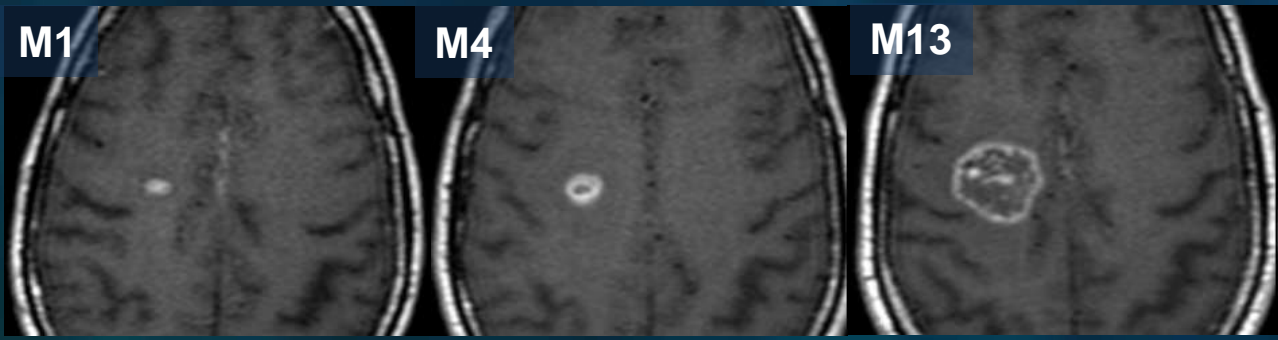


01/2012

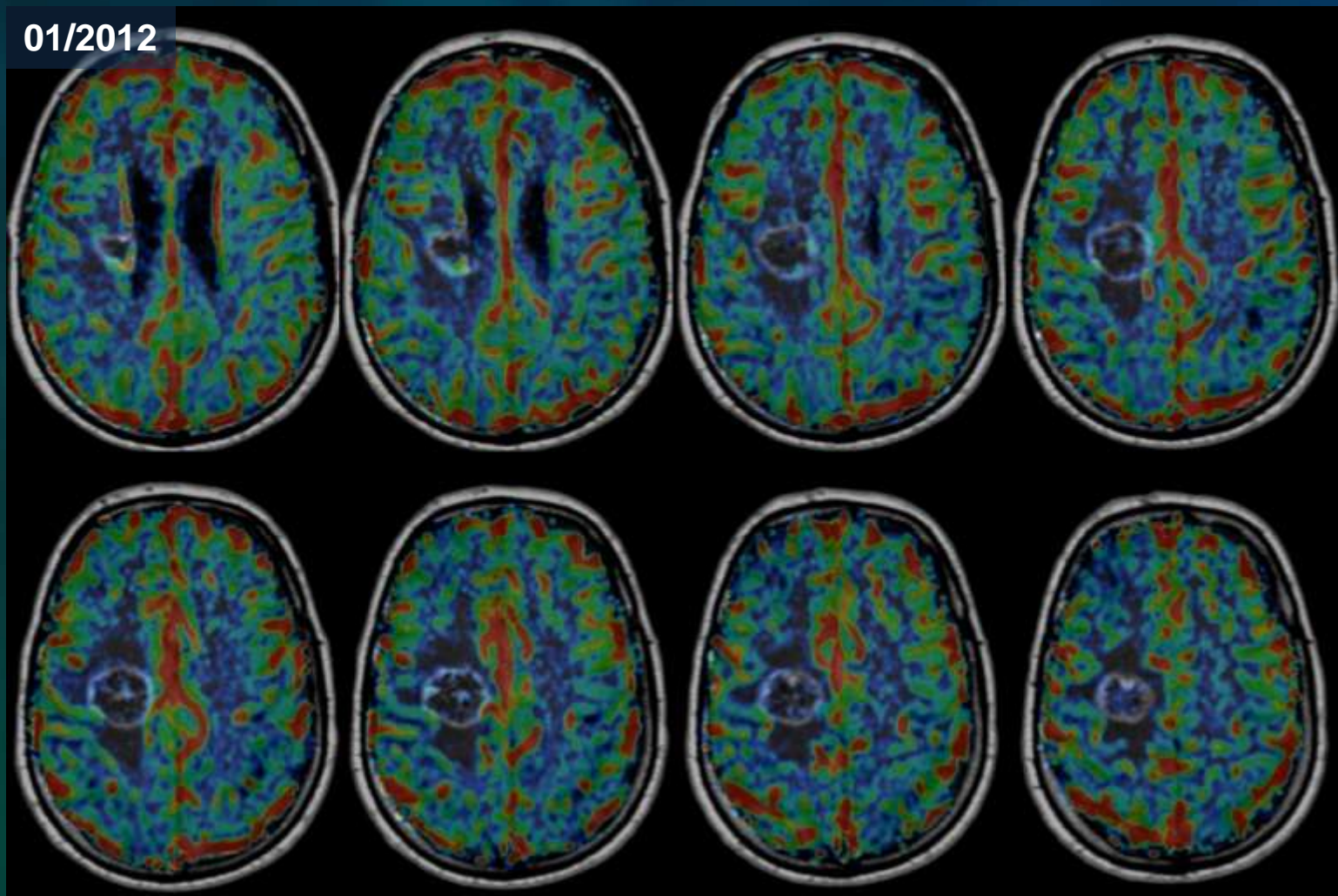


H, 65 ans, méta poumon. Radiochirurgie en décembre 2010

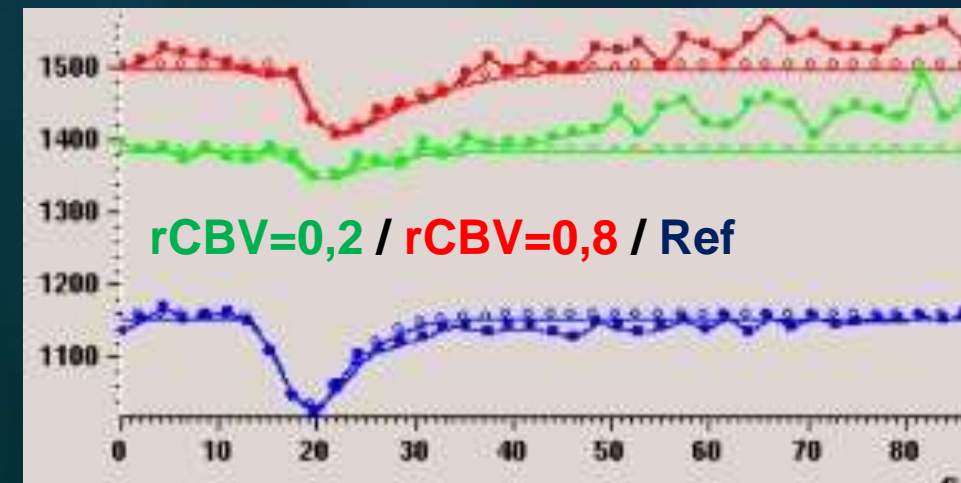
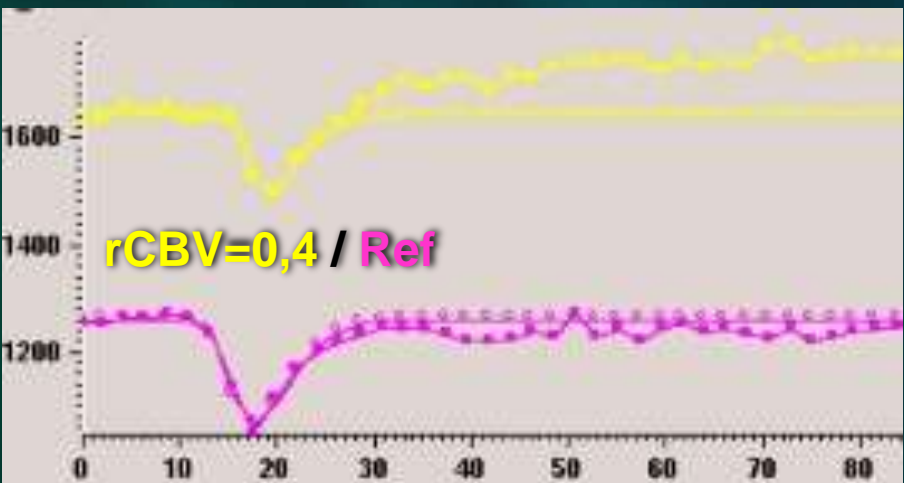
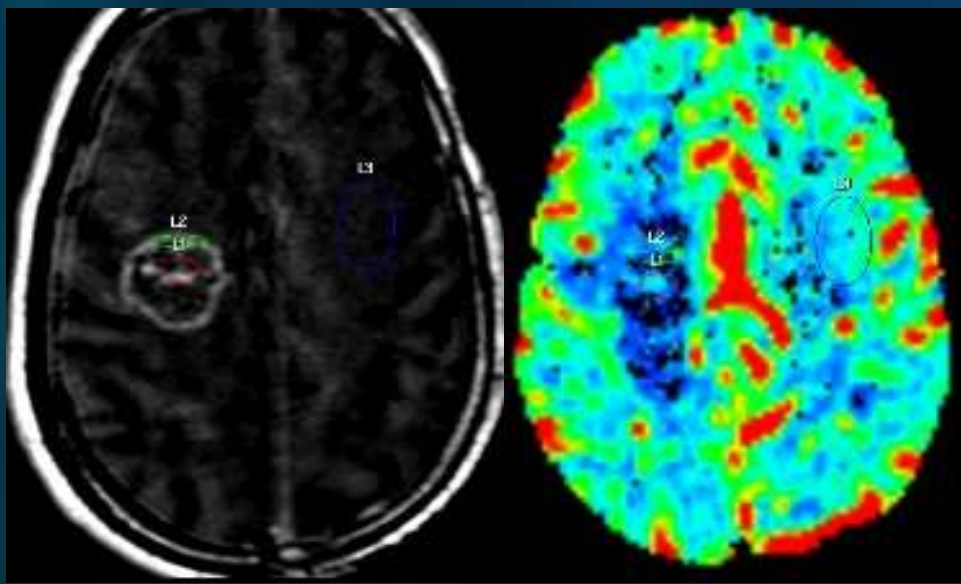
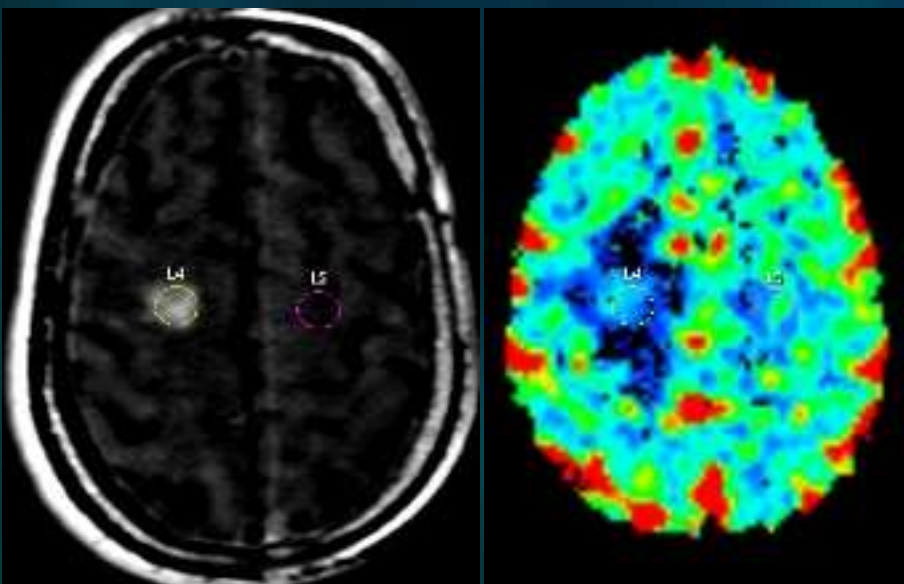


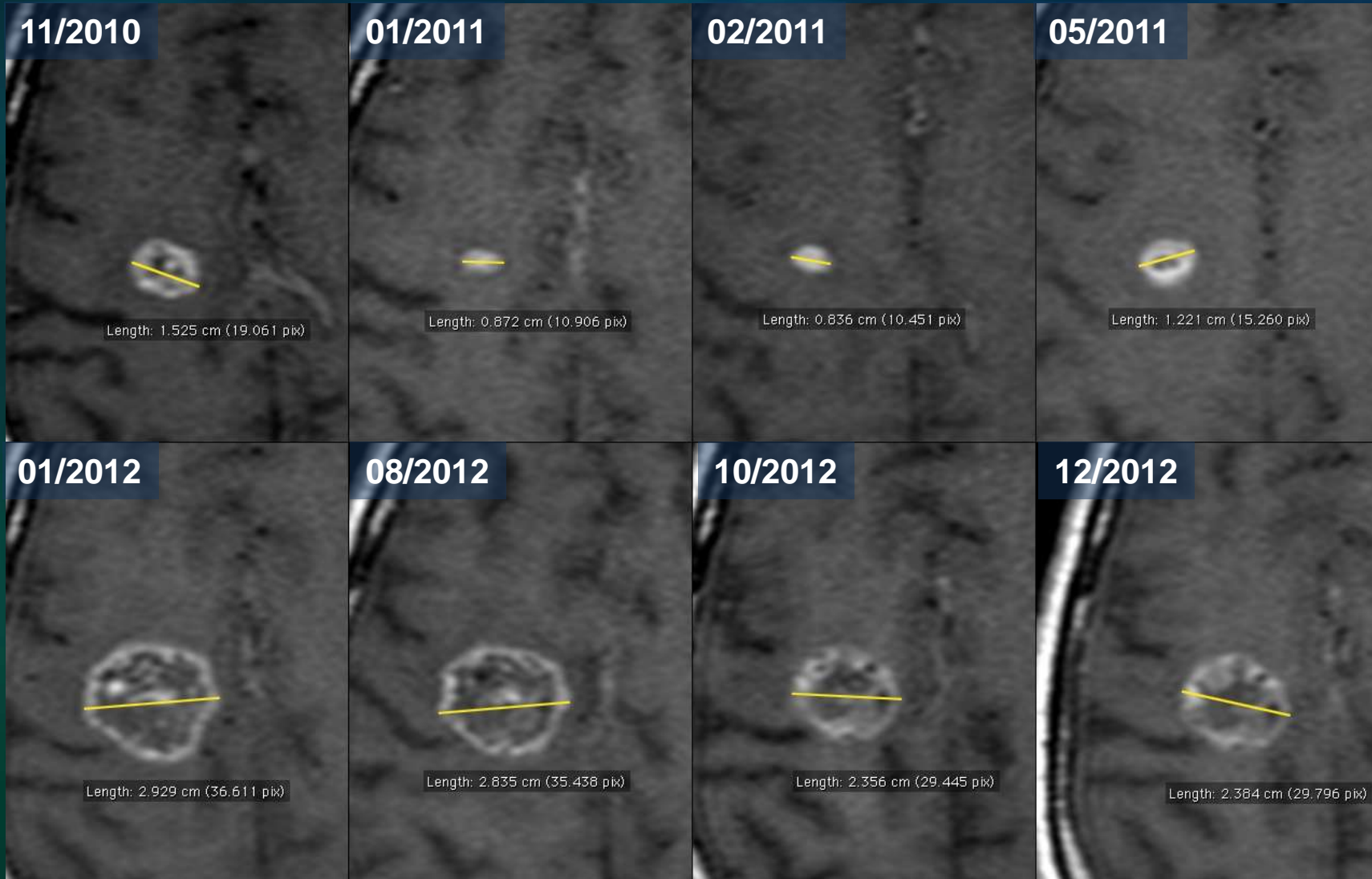


J. Savatovsky
Perfusion suivi tumeurs



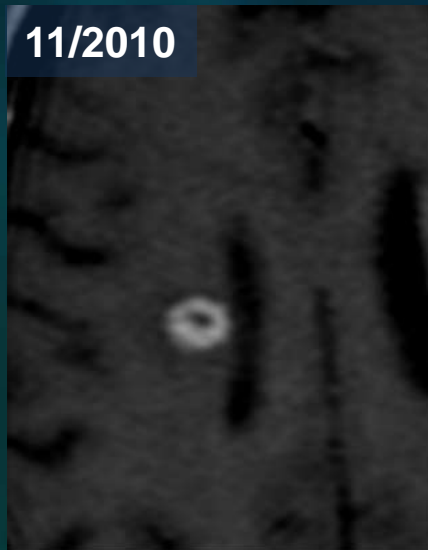
Biopsie (protocole médecine nuc.) Radionécrose



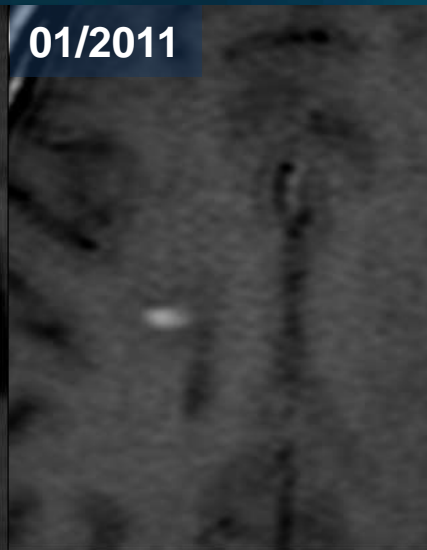




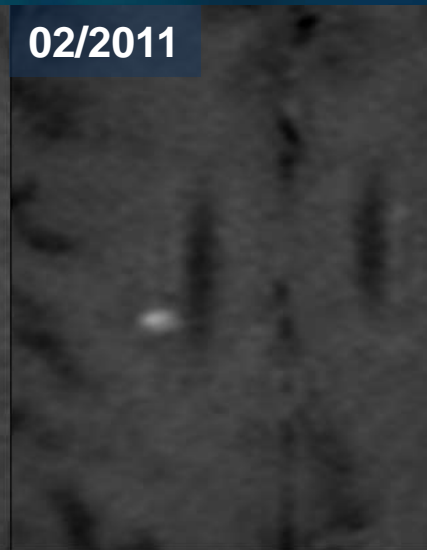
11/2010



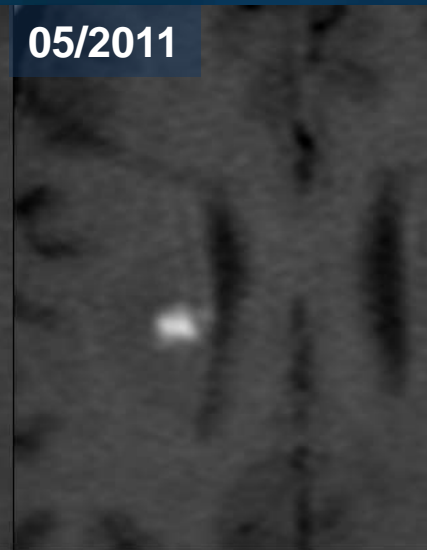
01/2011



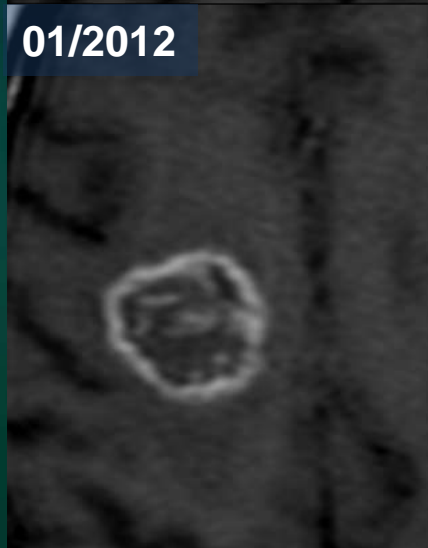
02/2011



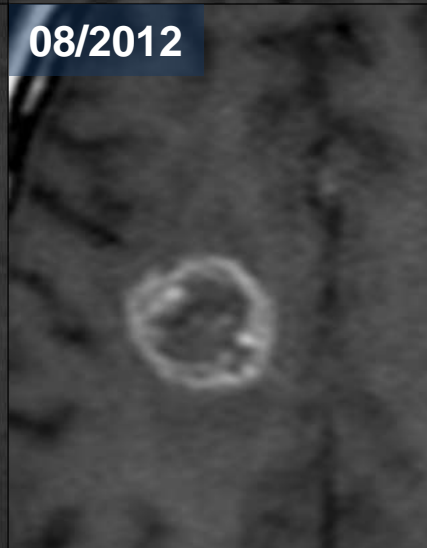
05/2011



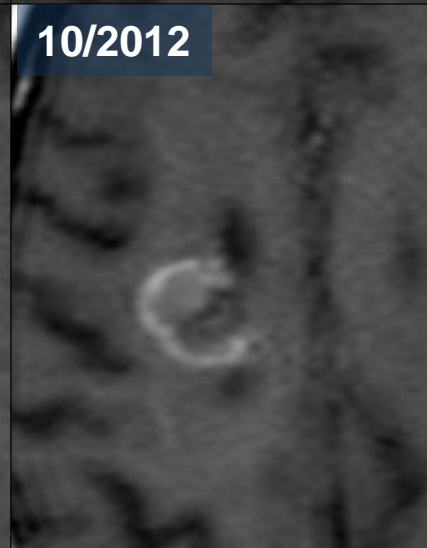
01/2012



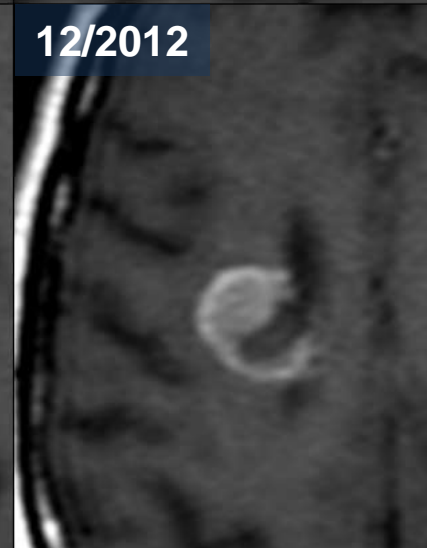
08/2012



10/2012



12/2012

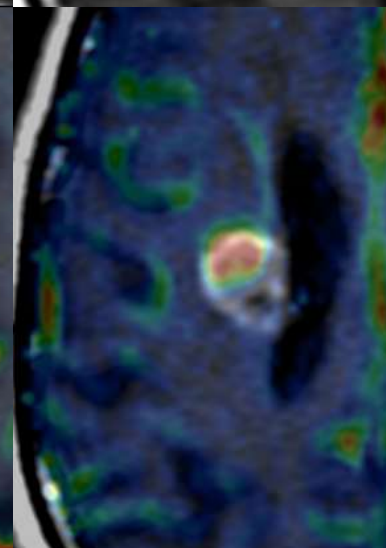
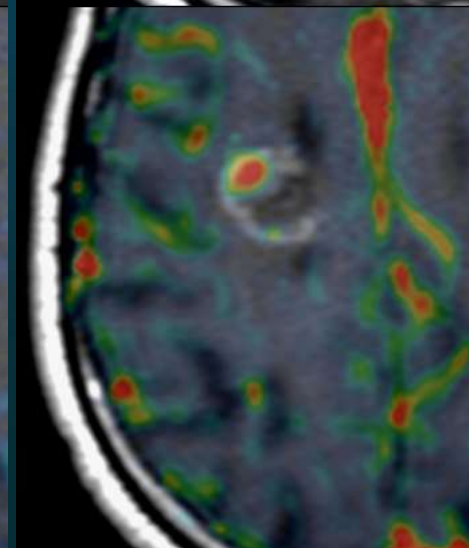
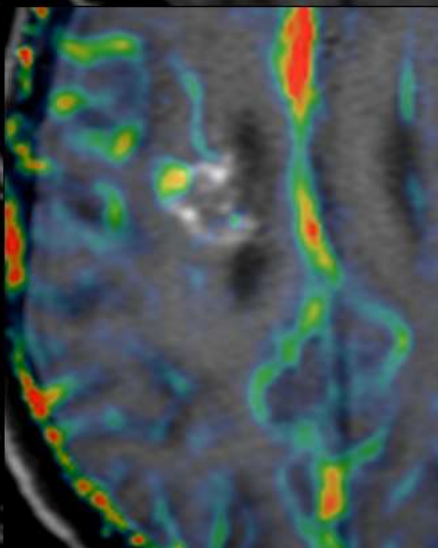
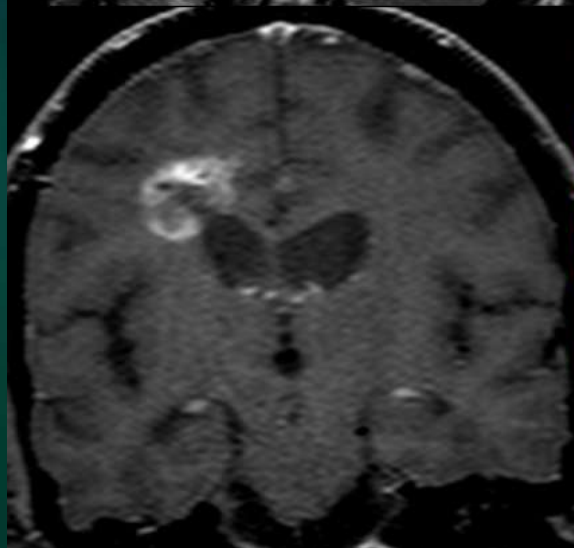
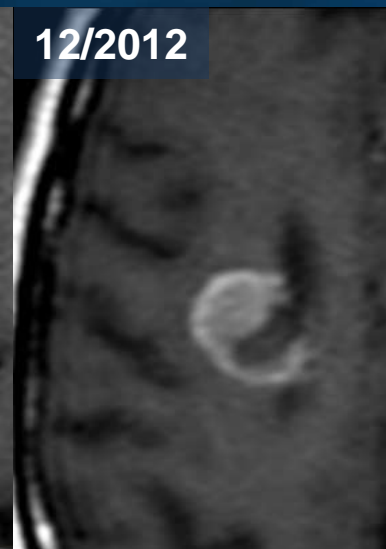
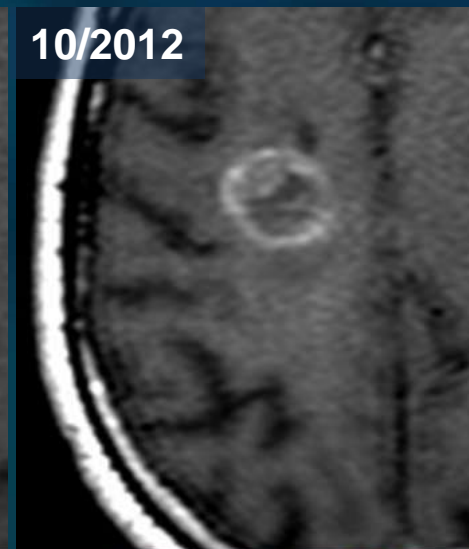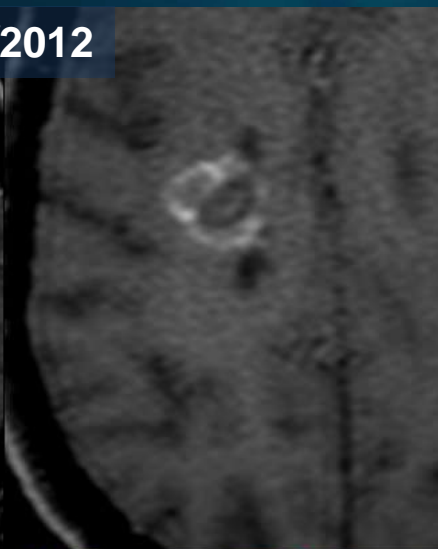
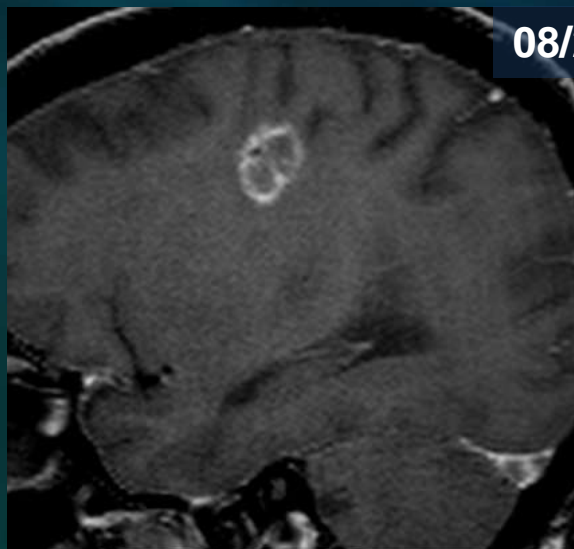


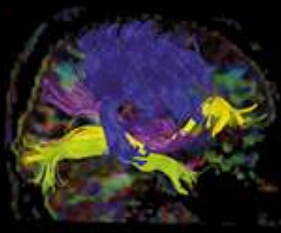


08/2012

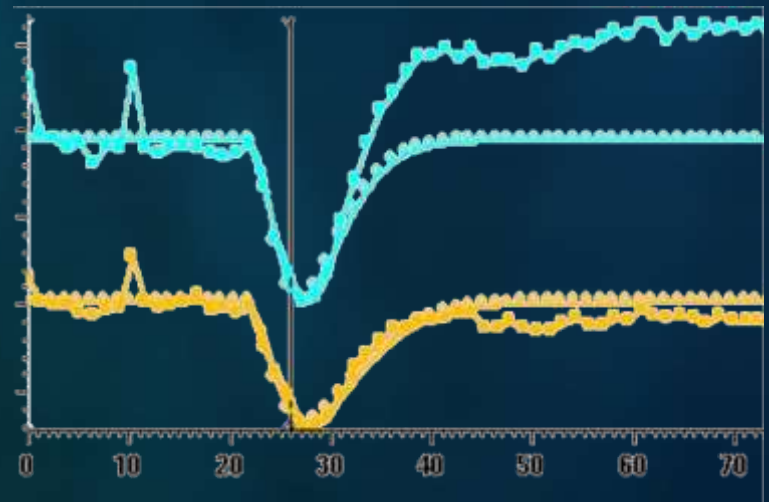
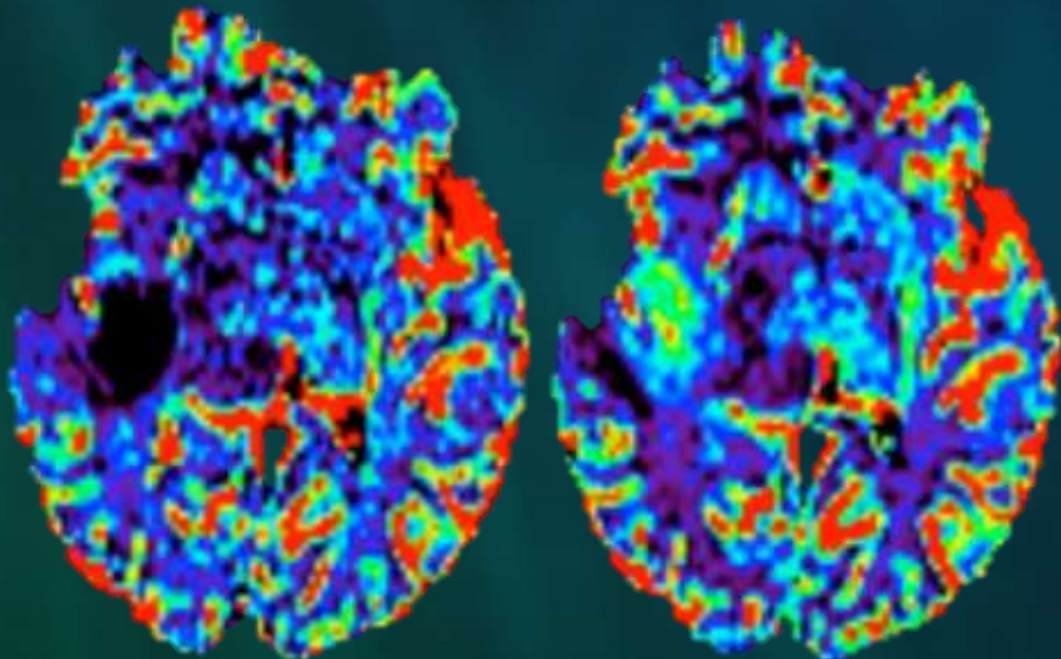
10/2012

12/2012



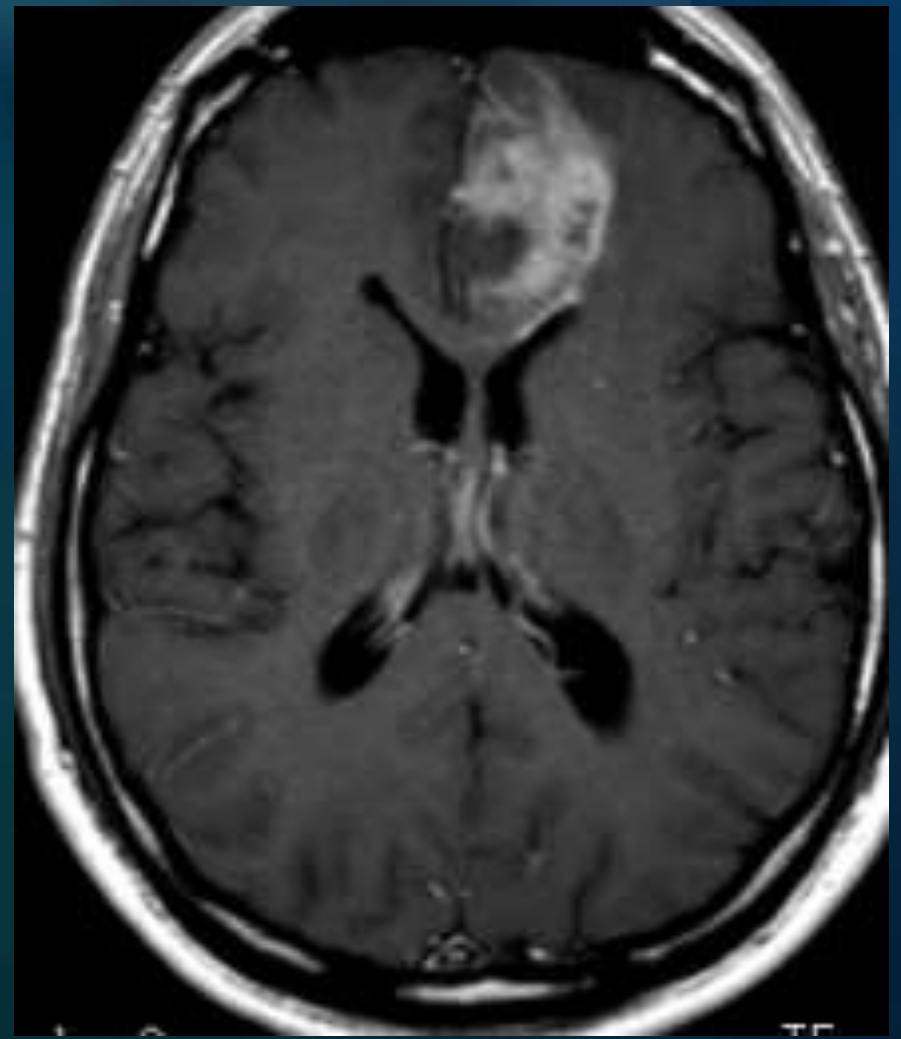
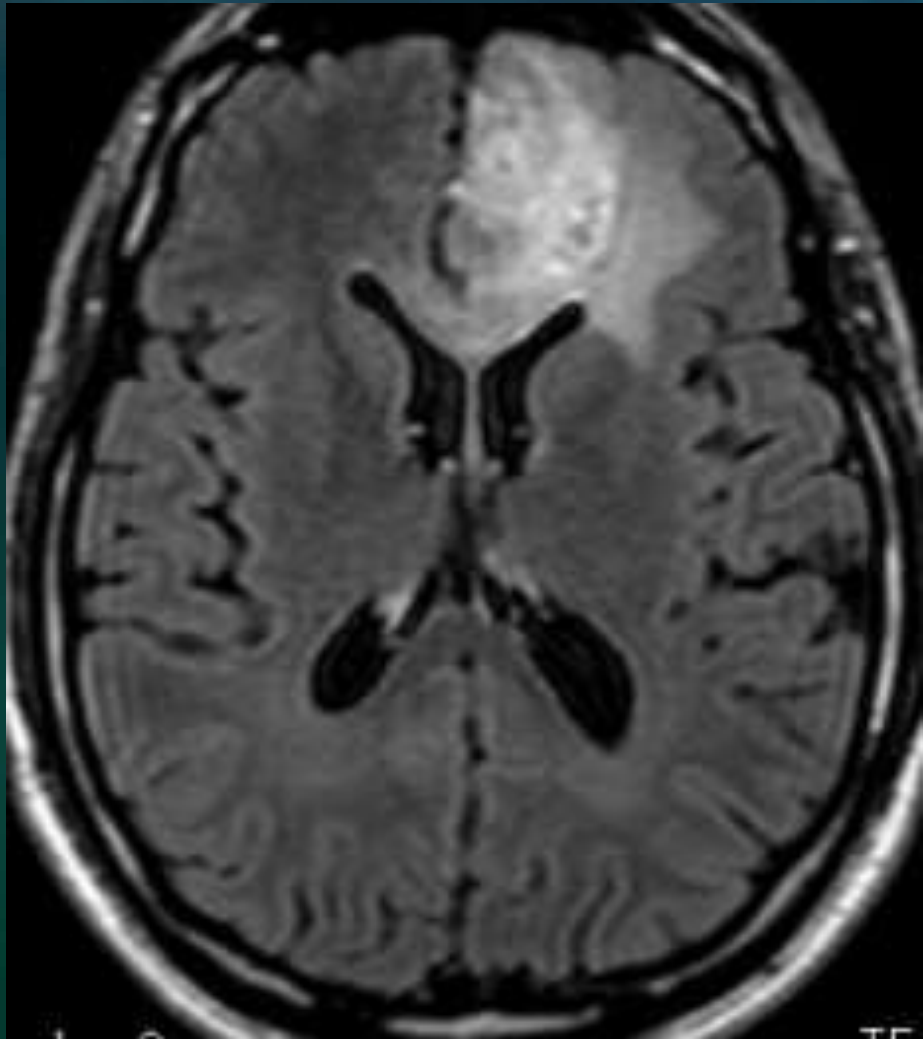


Difficultés d'évaluation et erreurs de mesure potentielles du rCBV

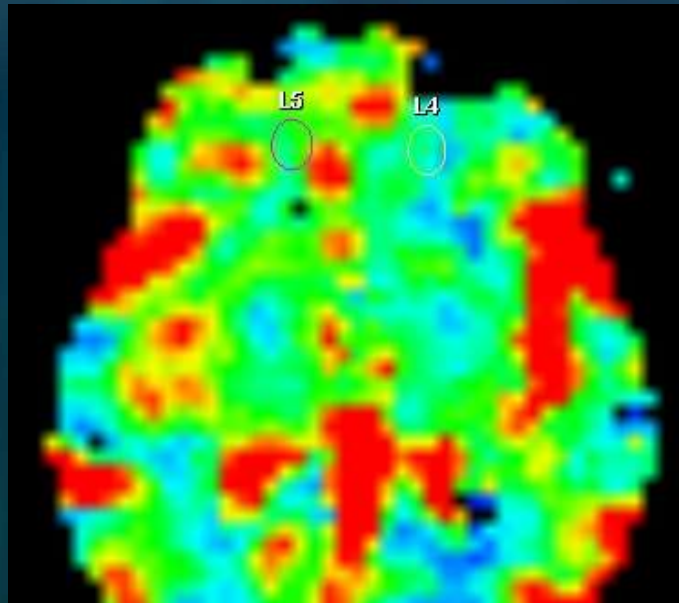
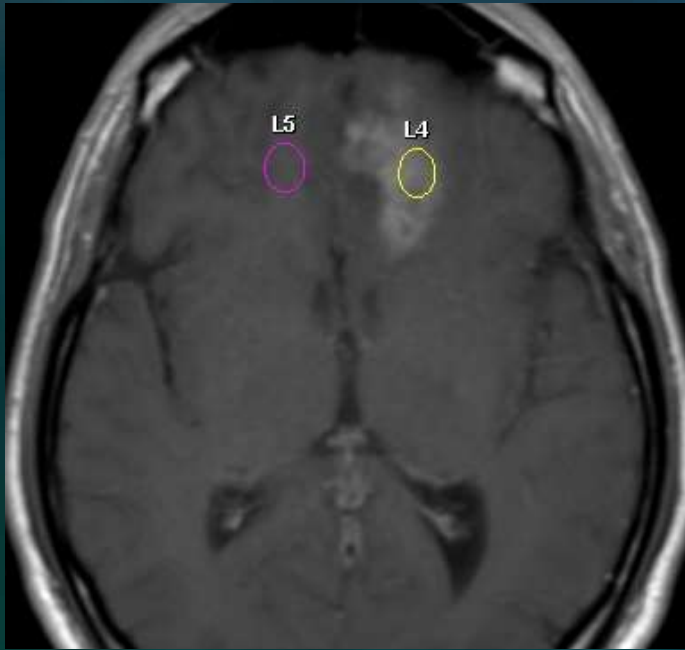


Lésion gliale de haut grade

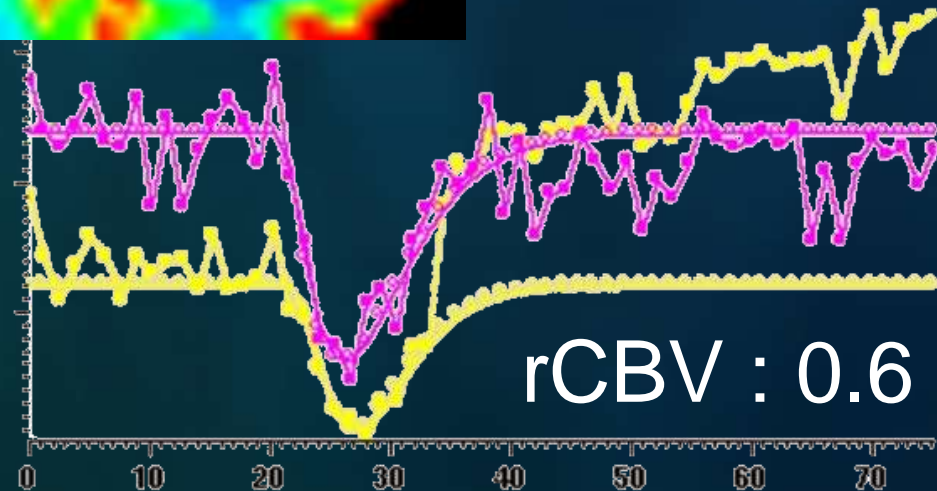
M2 Radiothérapie + TMZ

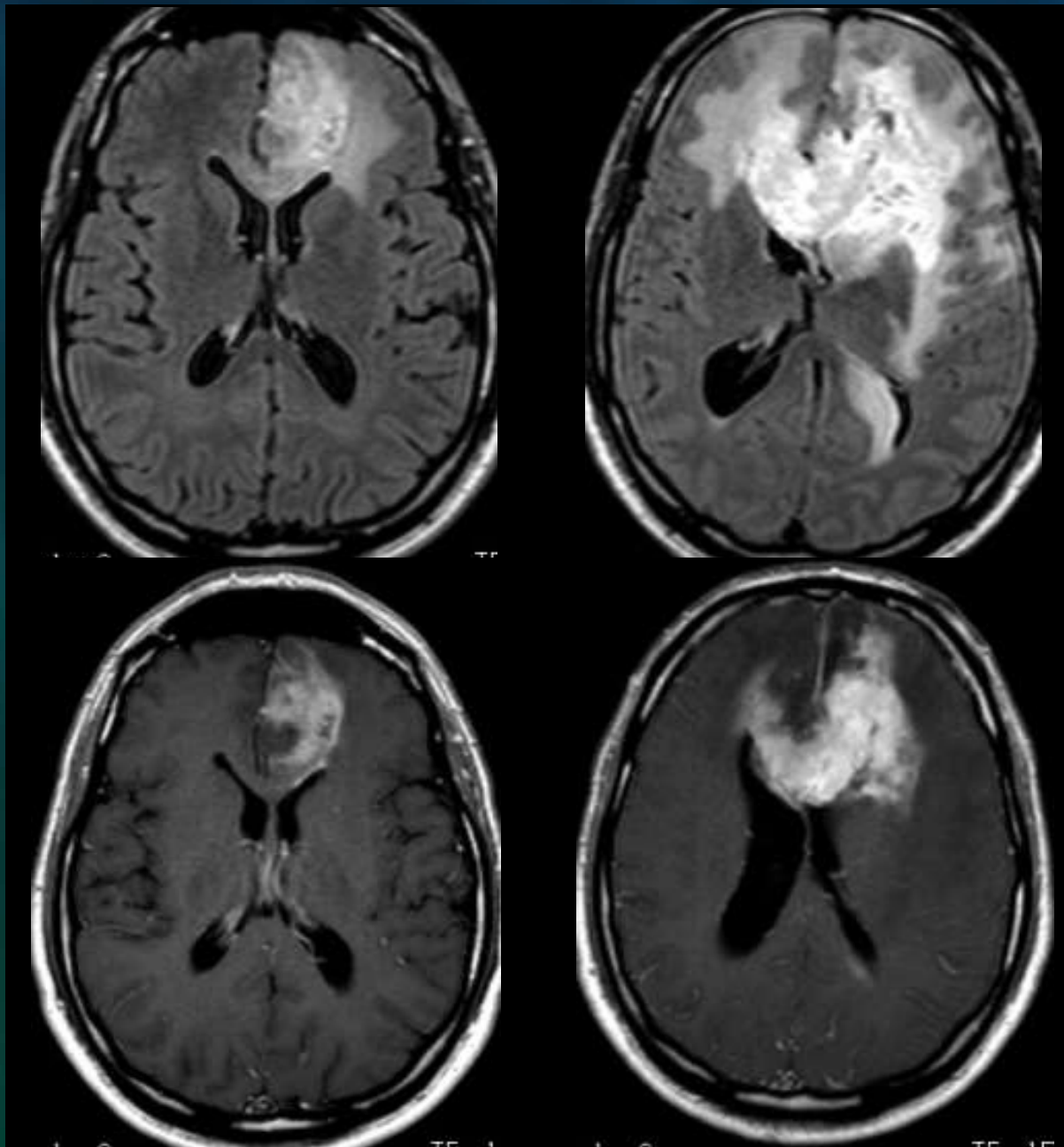


Lésion gliale de haut grade M2 Radiothérapie + TMZ




Examen antérieur non fourni
D'après CR : Taille PDC + 30%



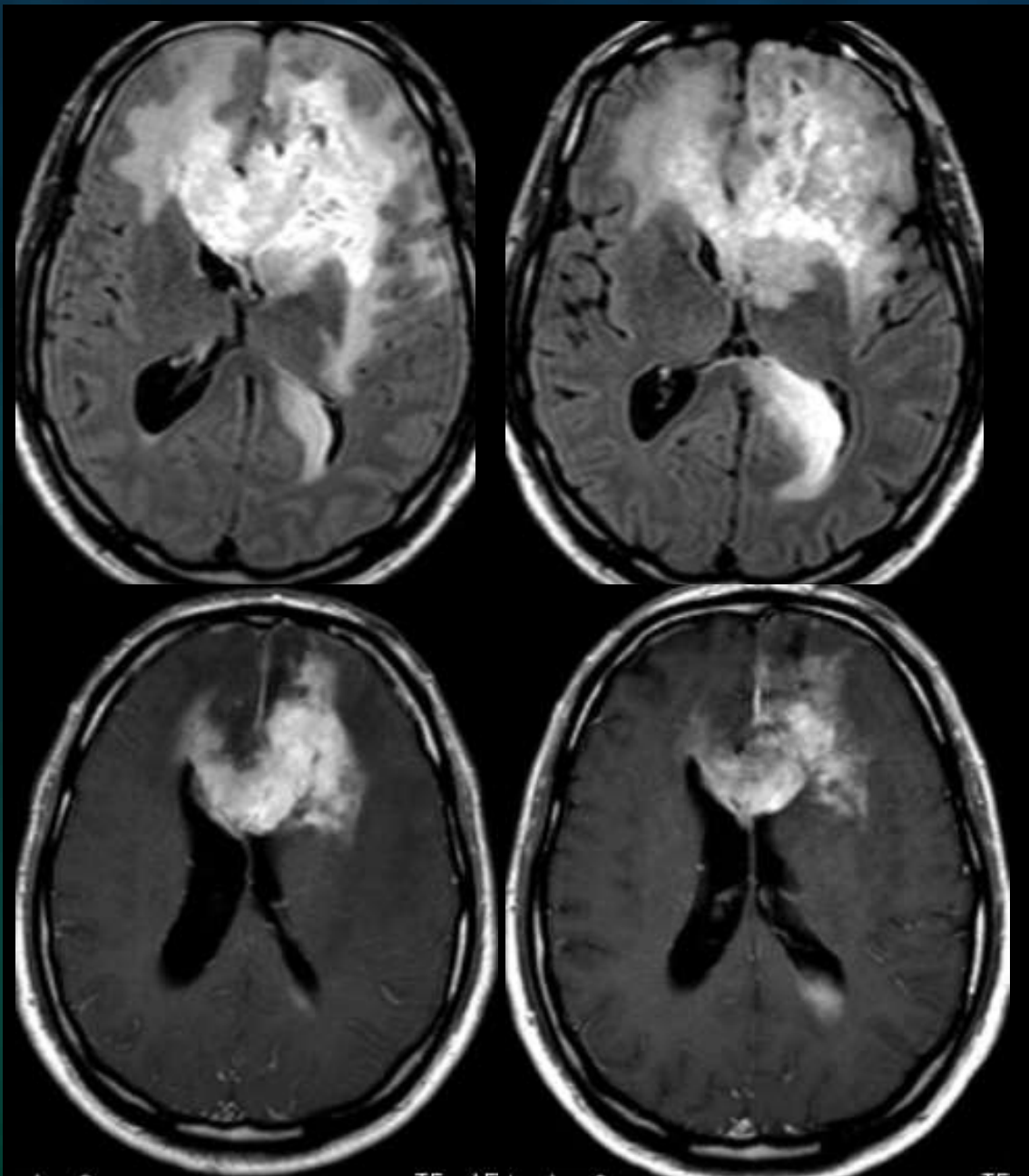


M2

M4

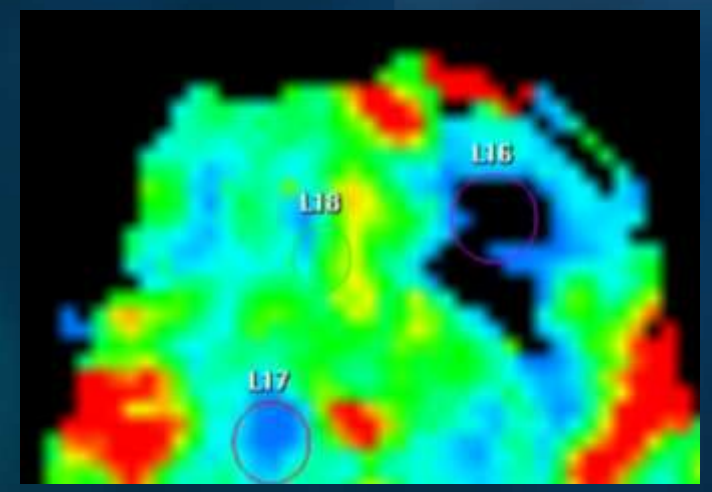


J. Savatovsky - Neuro Ingenia 3T

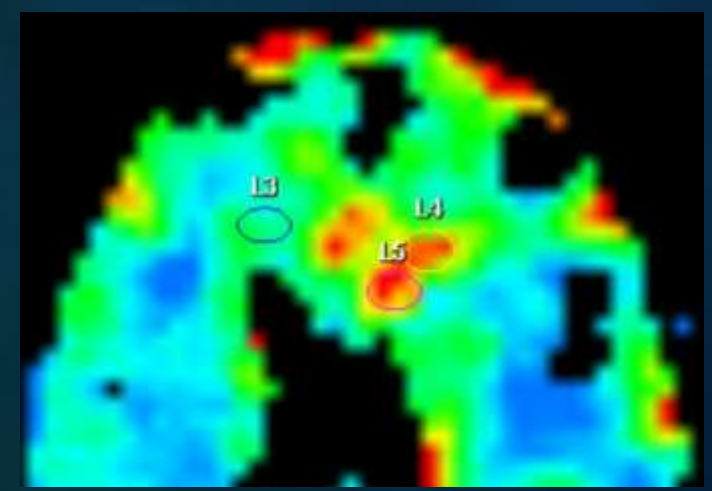


M4

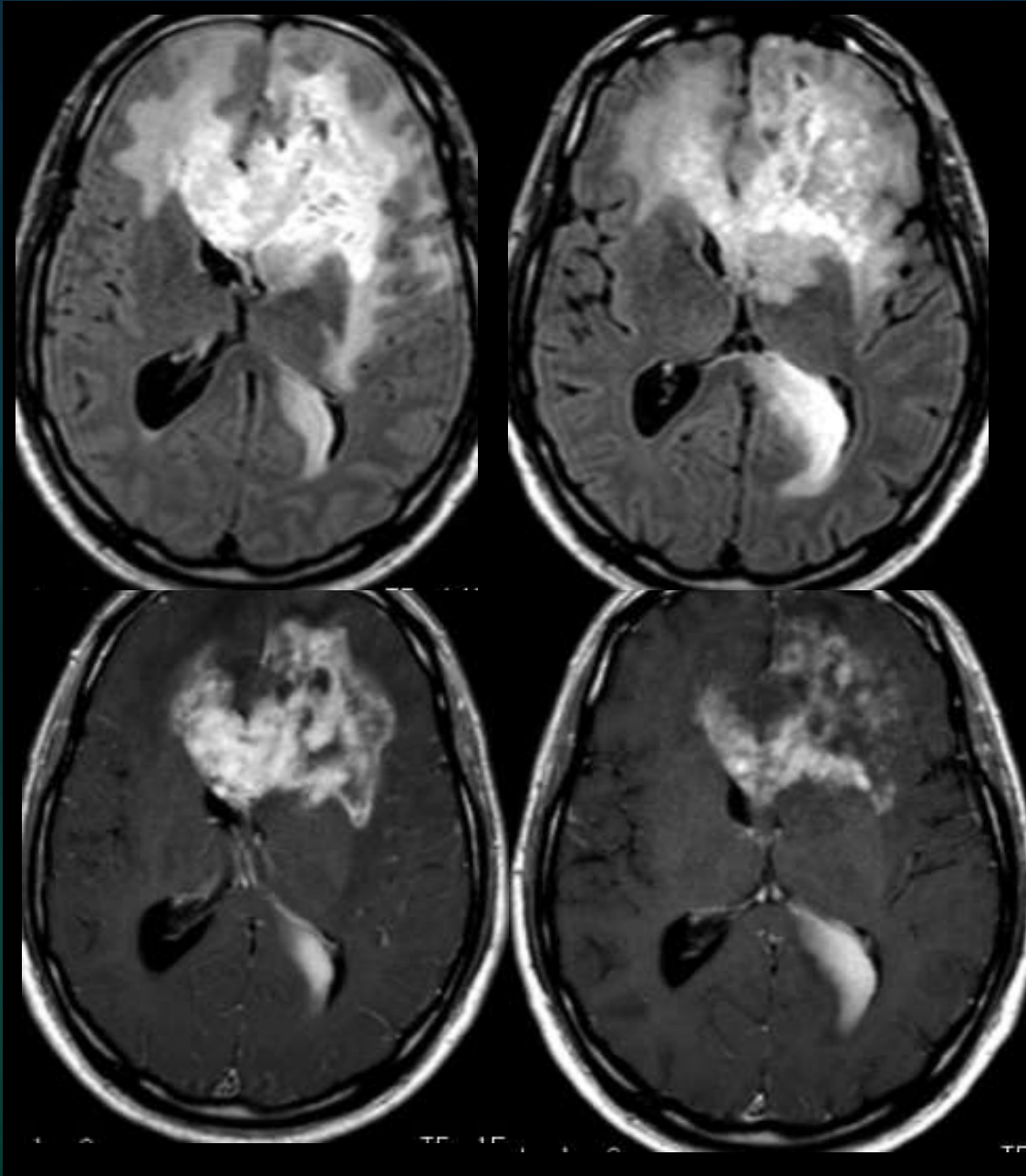
M5



rCBV < 0.5

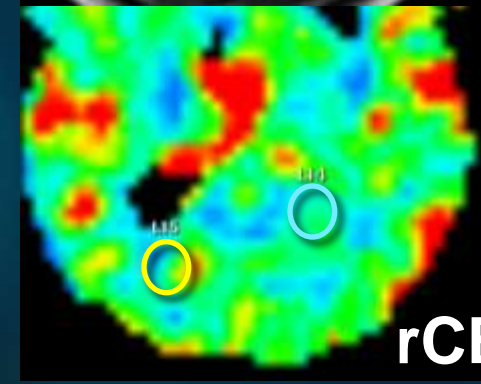
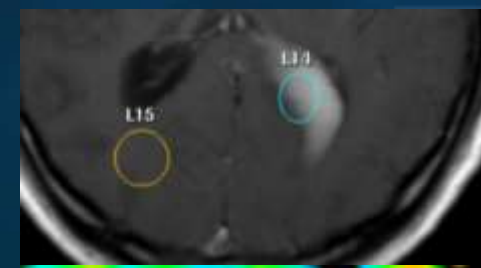


rCBV = 2.7

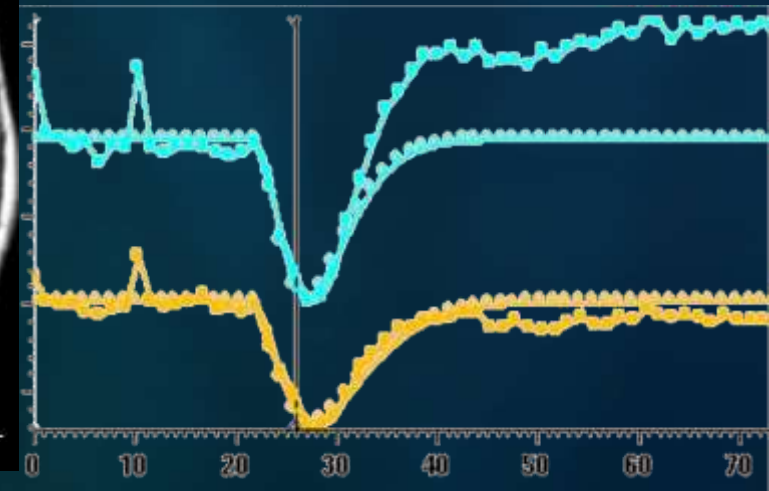


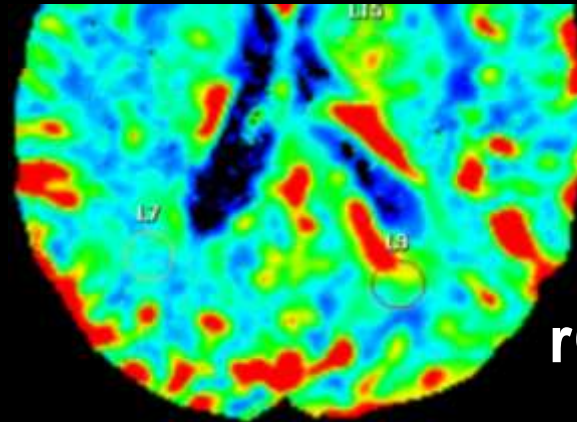
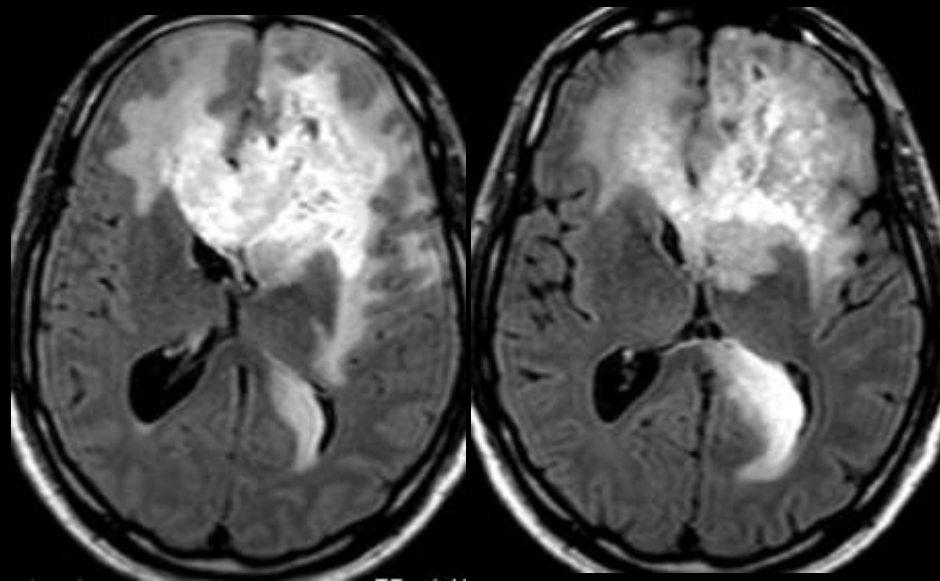
M4

M5



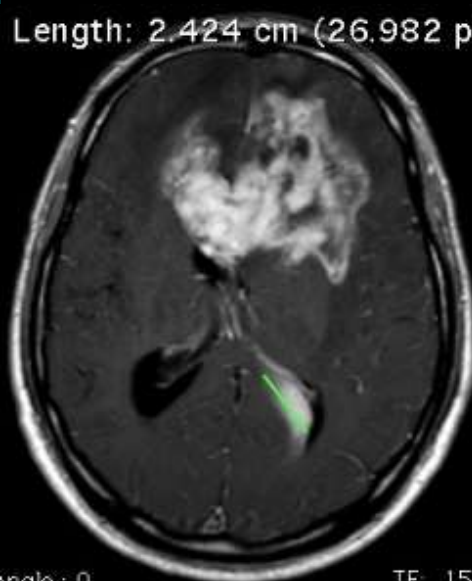
rCBV = 0.8



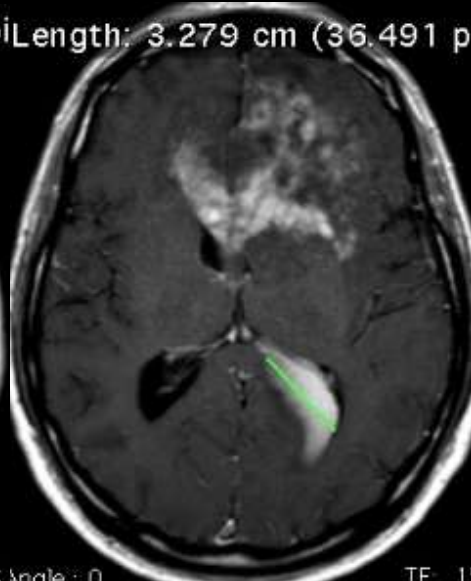


rCBV = 3.1

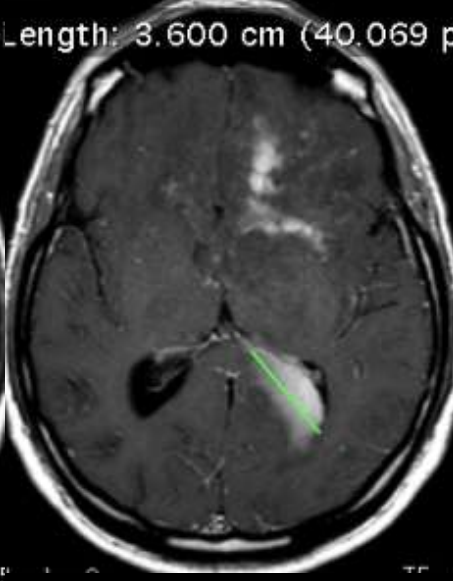
Length: 2.424 cm (26.982 pixels) Length: 3.279 cm (36.491 pixels) Length: 3.600 cm (40.069 pixels) Length: 4.022 cm (44.761 pixels)



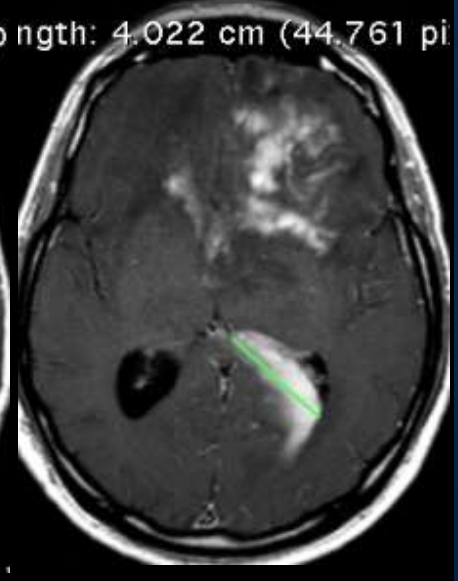
M4



M5



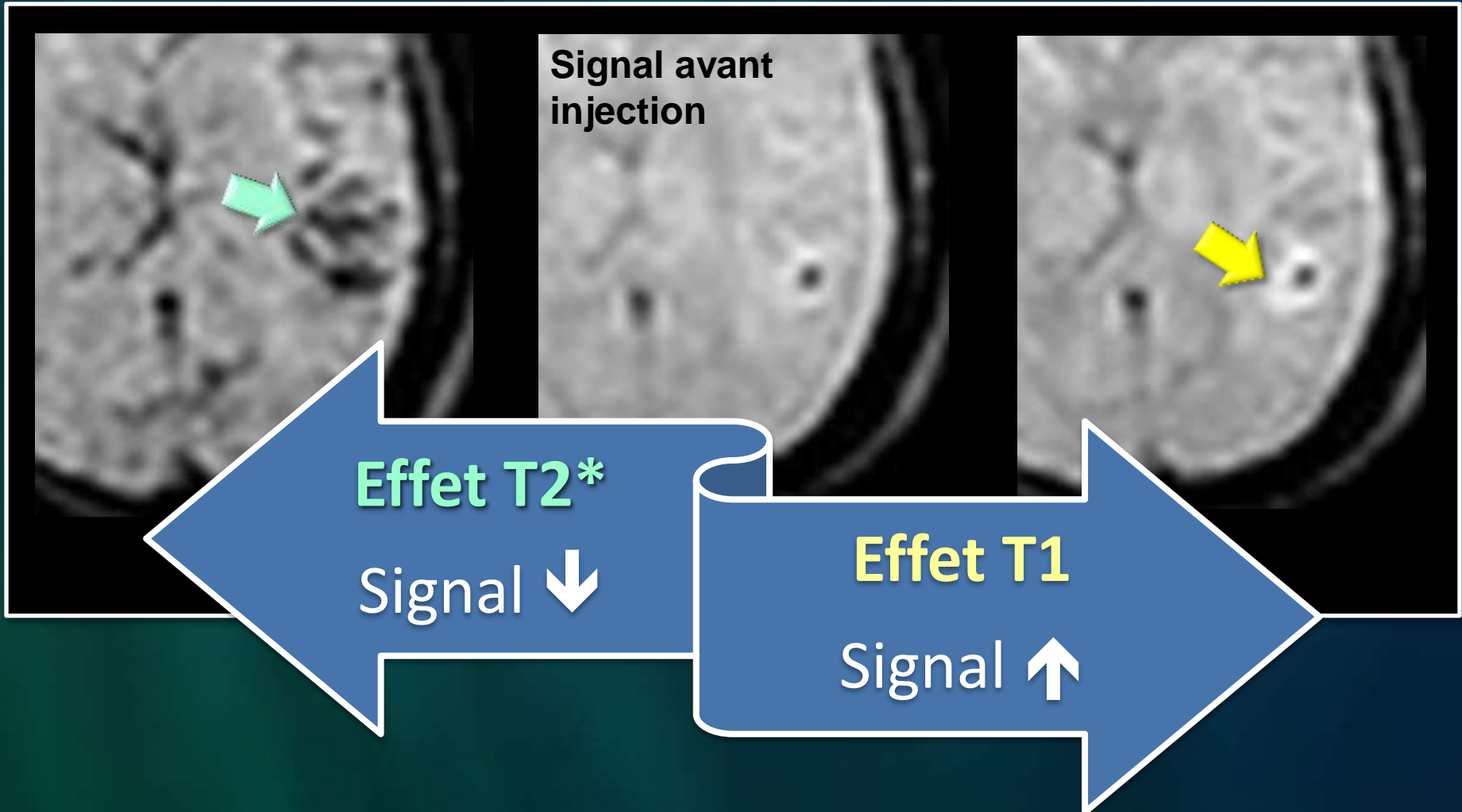
M6




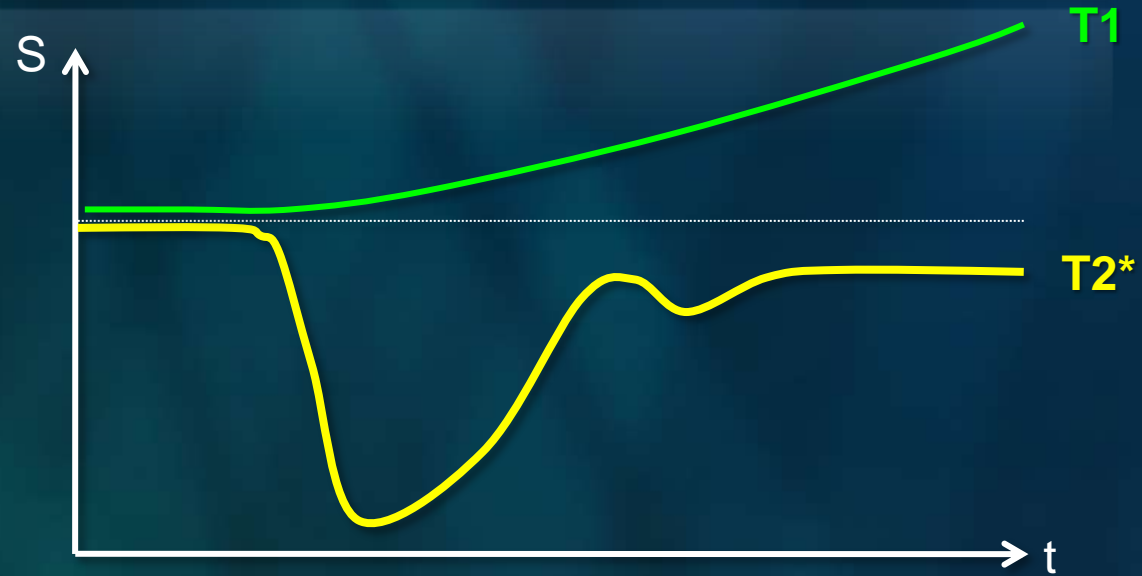
M8

Séquence DSC


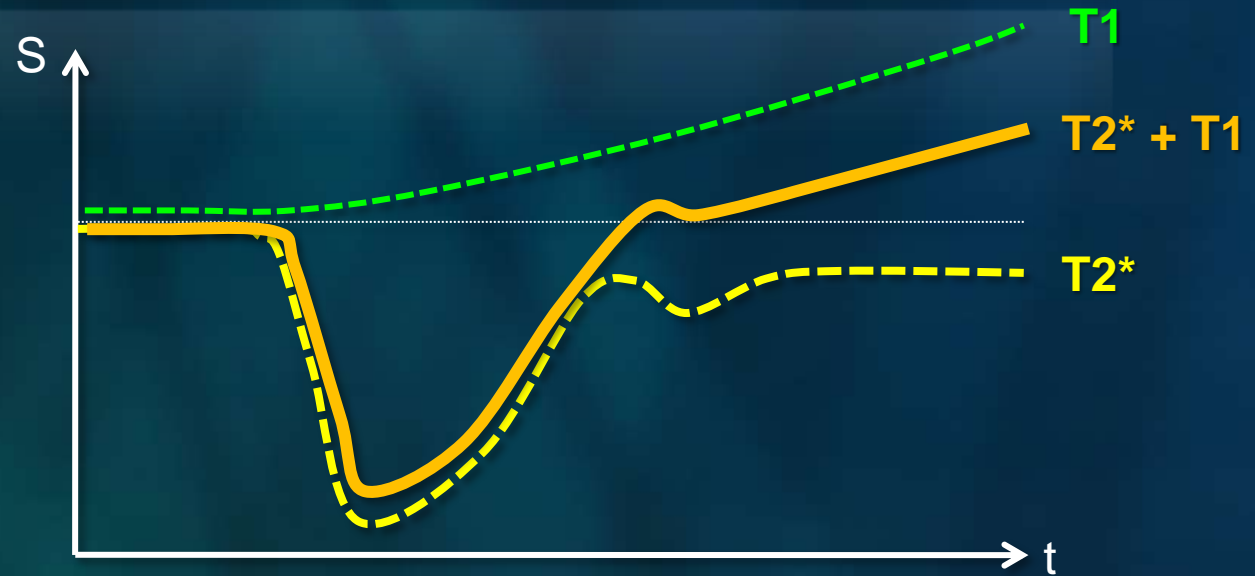
Même niveau de coupe



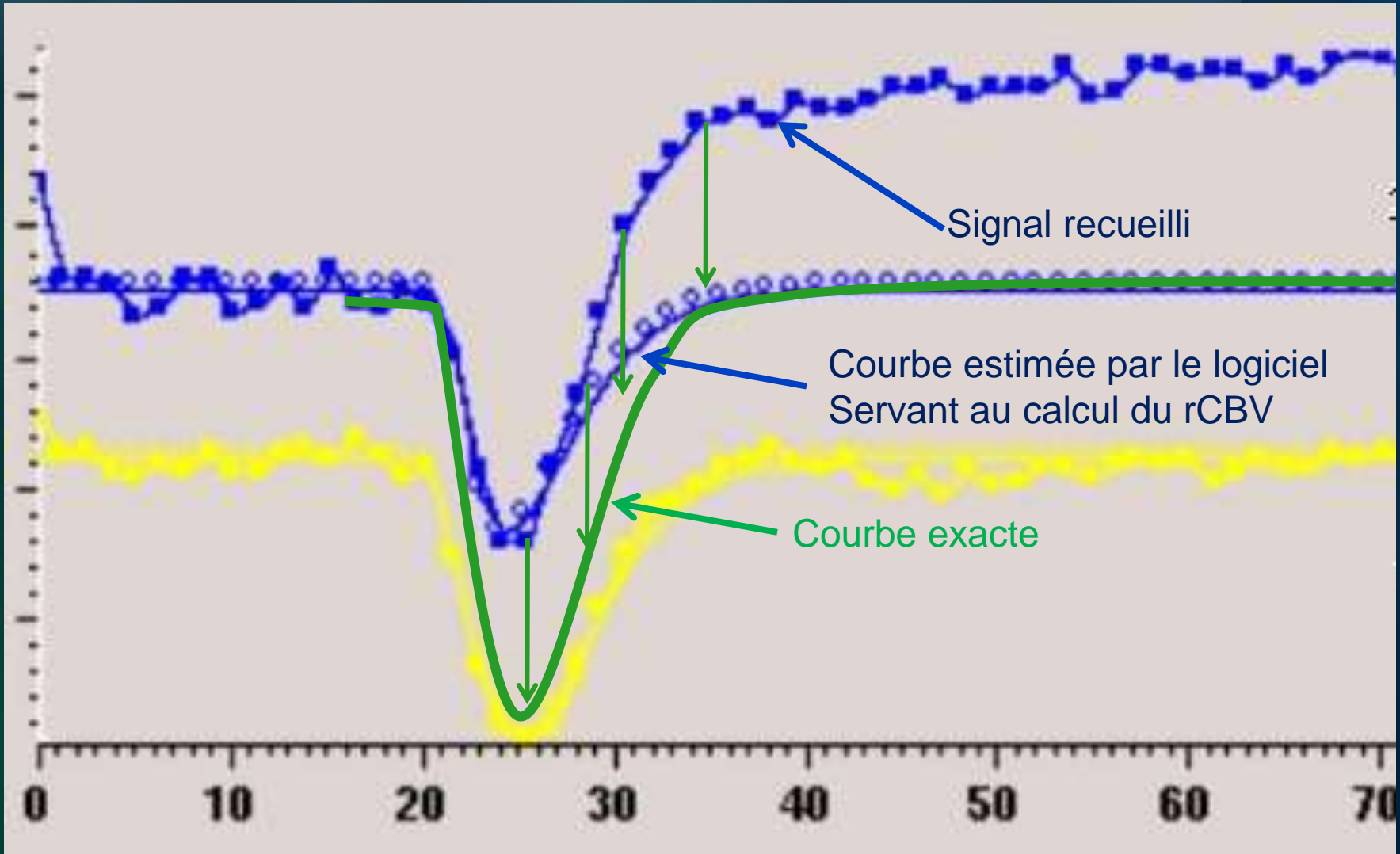
Séquence DSC



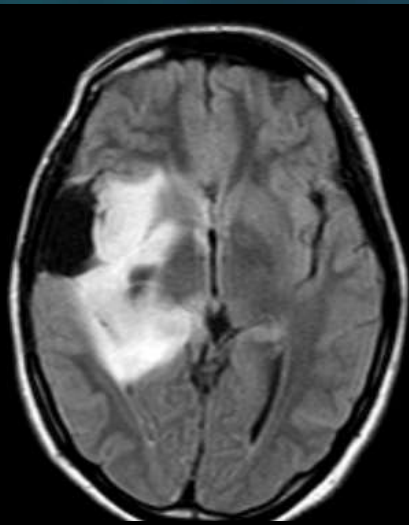
Séquence DSC



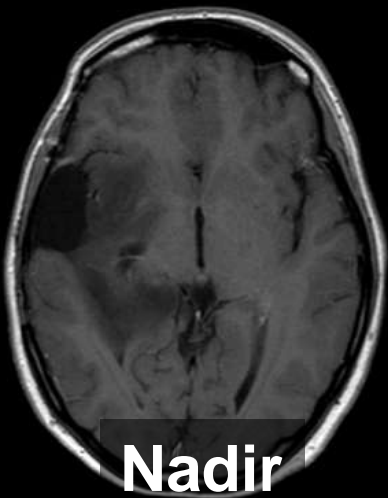
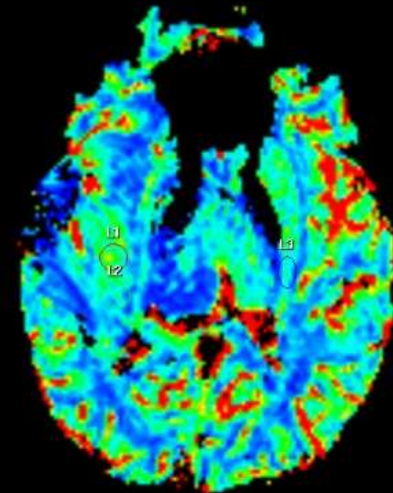
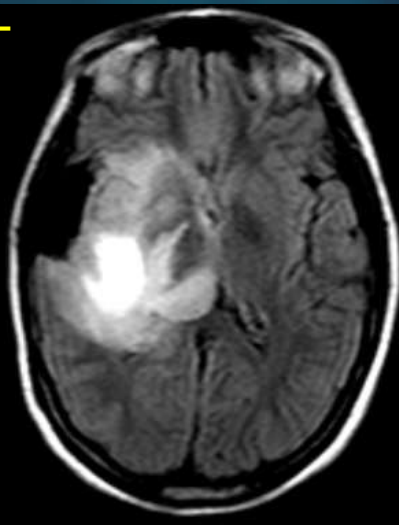
Quelle serait la « vraie » courbe sans l'effet T1 ?



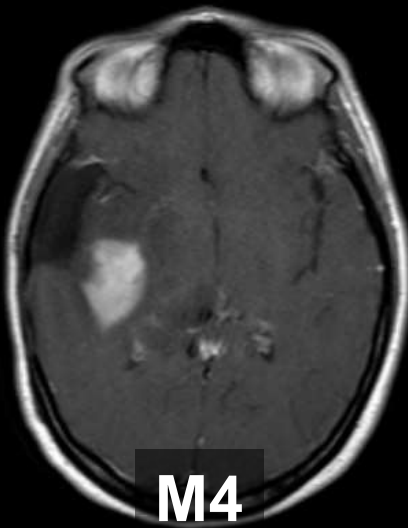
F, 37 ans, Astro III Stupp, 18 mois après RT



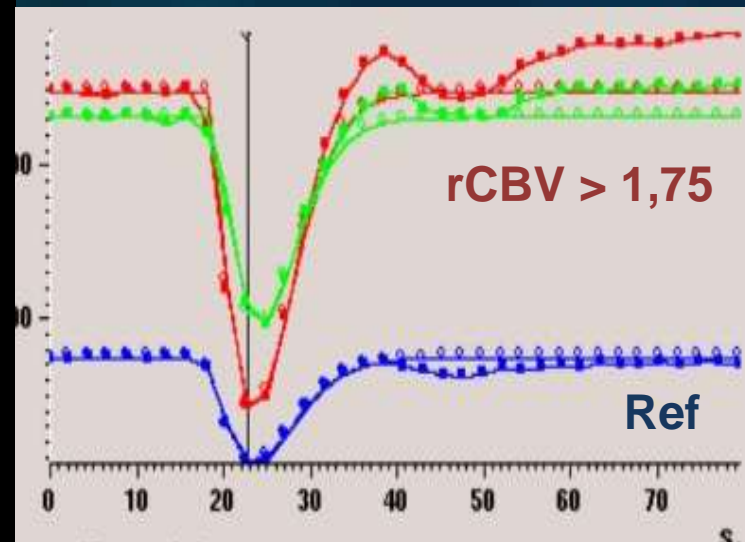
3T



Nadir



M4

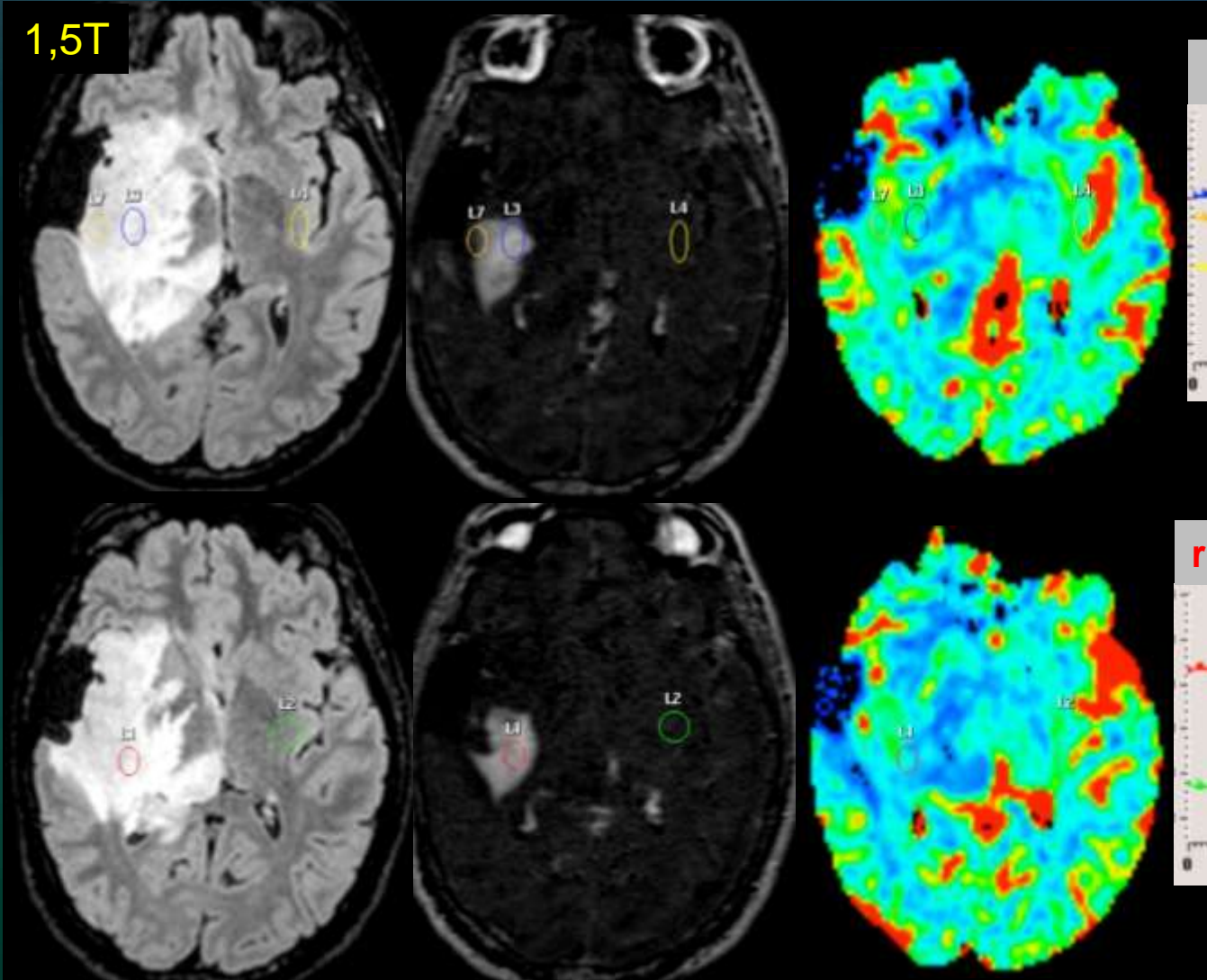


M4 – 2 jours...

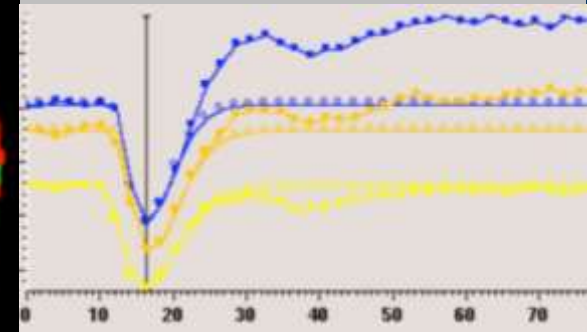


J. Savatovsky
Perfusion suivi tumeurs

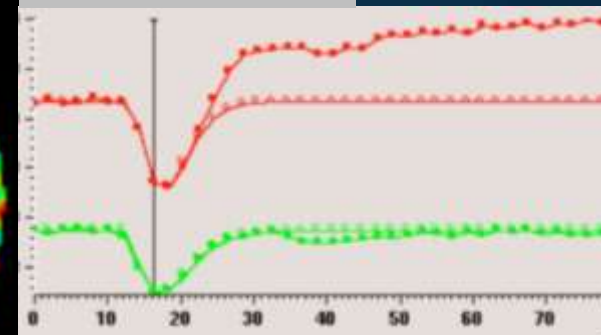
1,5T



rCBV=0,7 / rCBV=0,8 / Ref

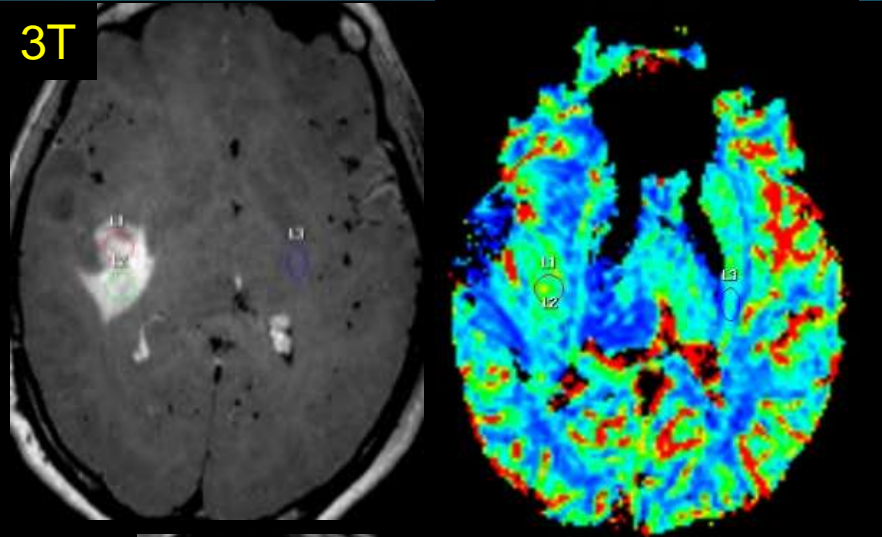


rCBV=0,7 / Ref

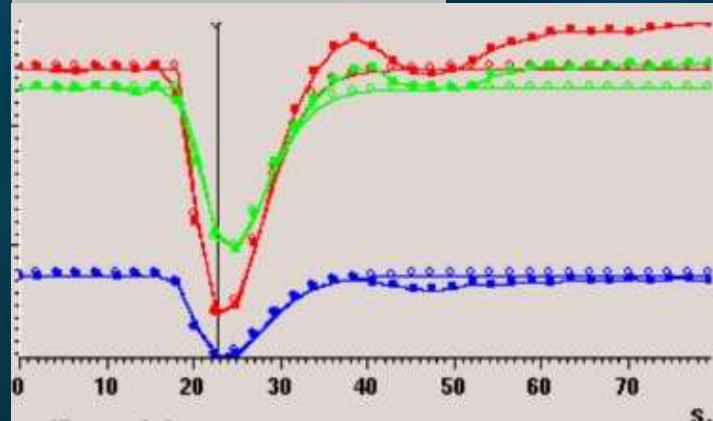


1,5T VS 3T

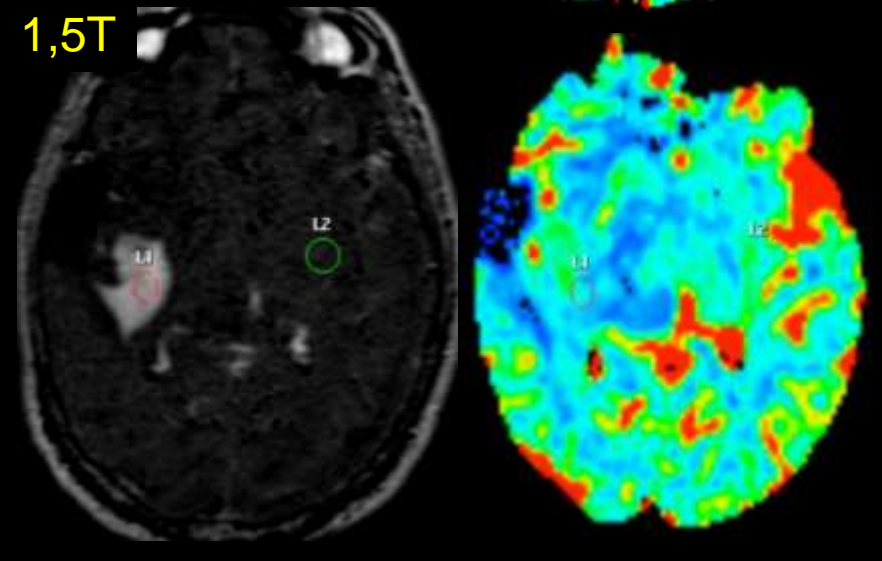
3T



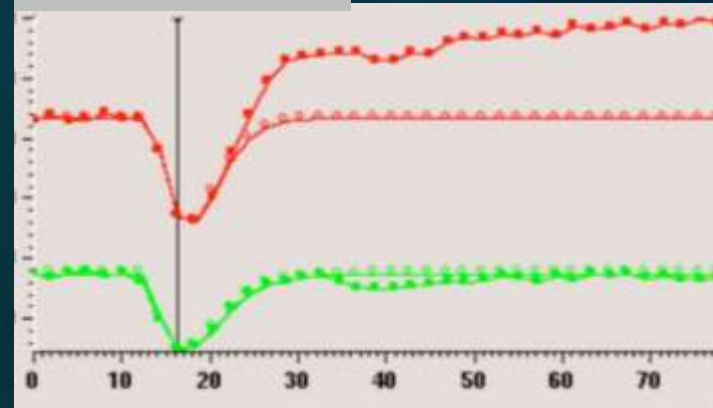
rCBV=1,6 / 1,3 / Ref



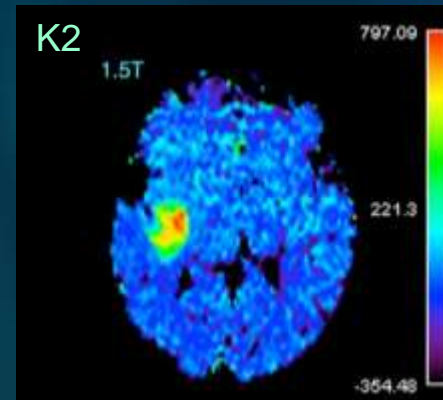
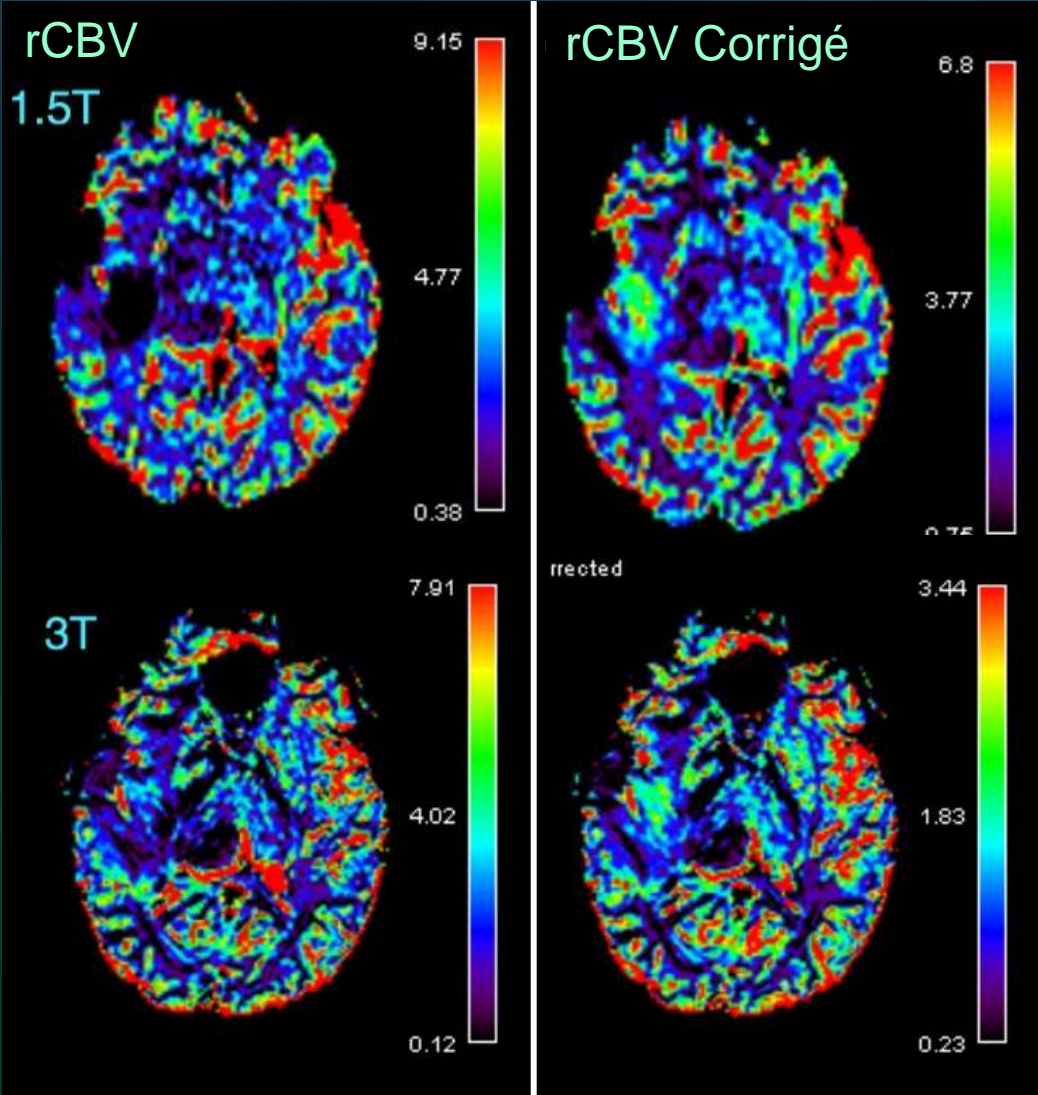
1,5T



rCBV=0,7 / Ref



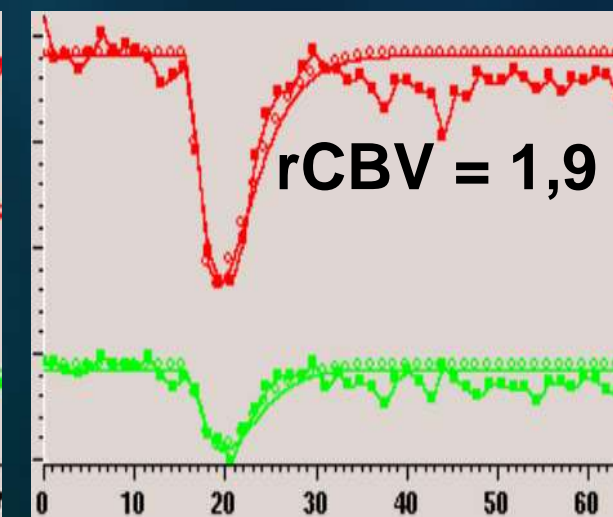
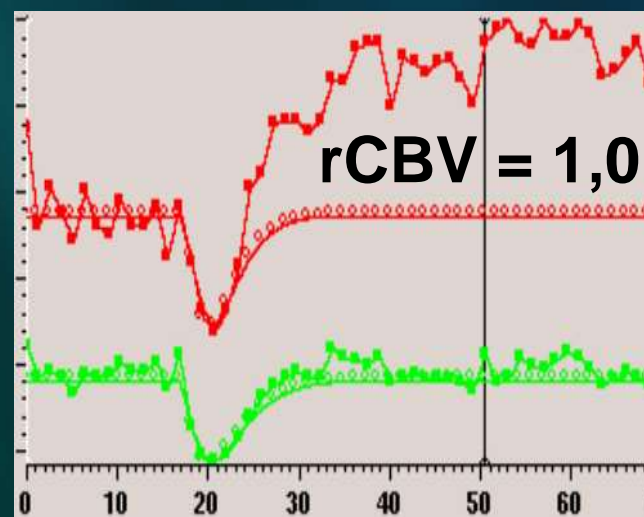
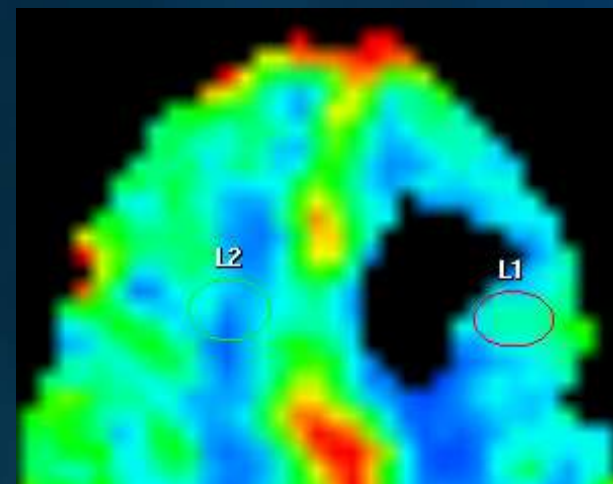
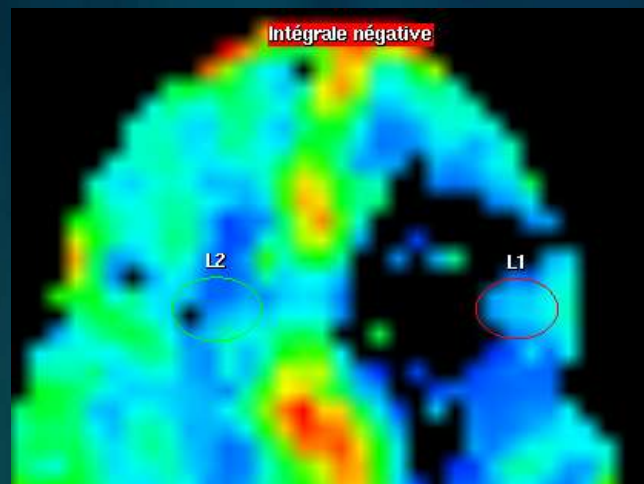
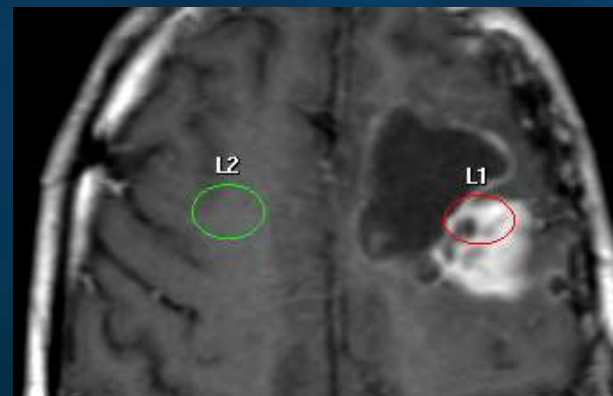
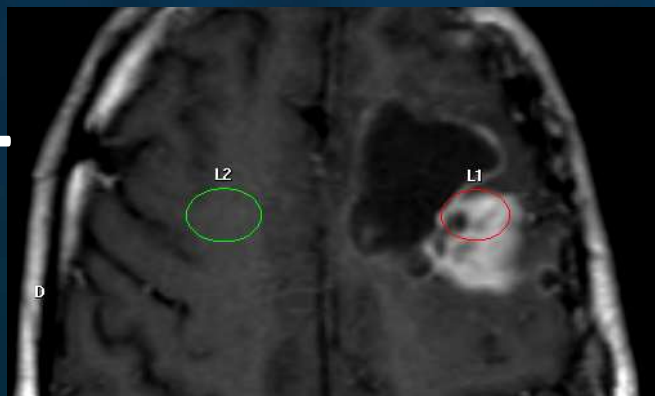
Correction logicielles (K2)



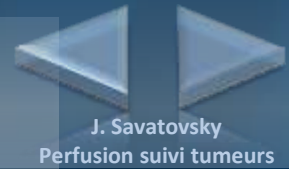
rCBV tumeur	1,5T	3T
Log. Constructeur	0,7	1,6
Log. Spé. Non corrigé	0,1	1,7
Log. Spé. Corrigé	1,4	1,9

Perfusion pré-impregnée

injecter 2x
0,1 mmol/kg
à 5 min intervalle

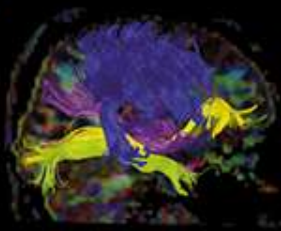


Perfusion faussement rassurante



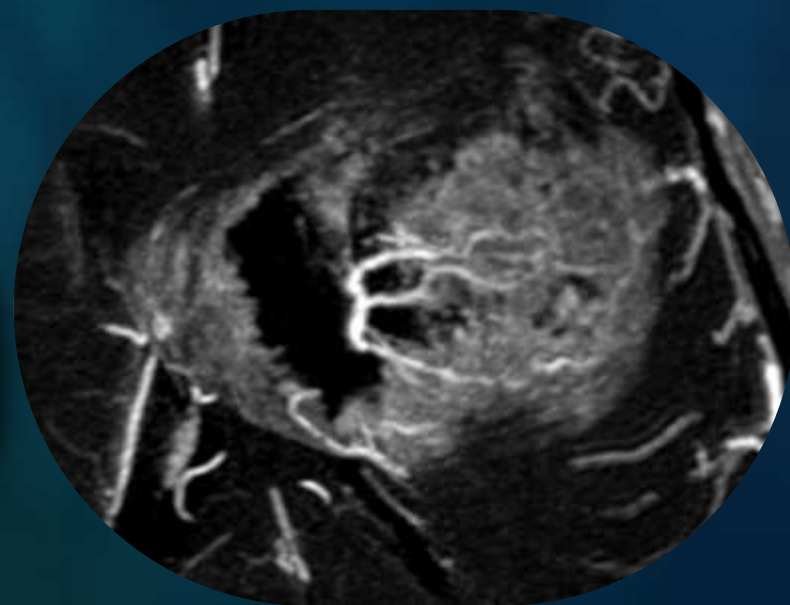
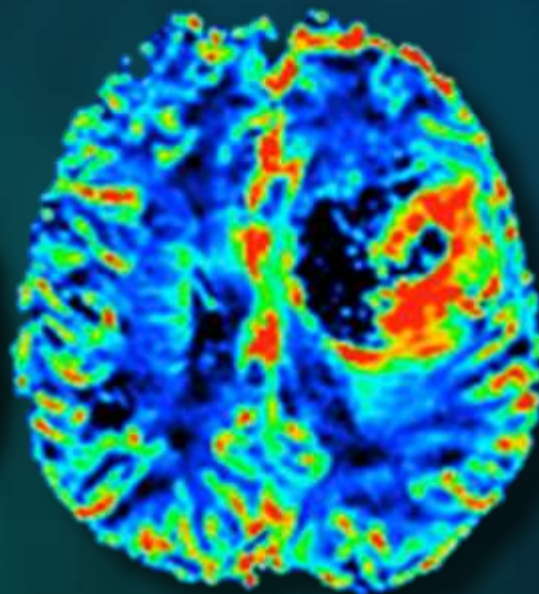
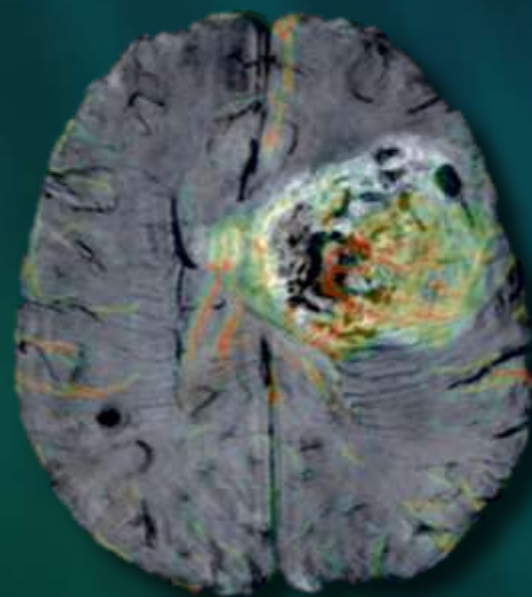
- Erreur dans le placement du voxel +++
 - Basé seulement sur la PDC
 - Basé sur l'analyse d'une cartographie rCBV mal fenêtrée
- Sous-estimation du rCBV par rupture BHE (effet T1)
 - Logiciels incluant un algorithme de correction
 - Pré-impregnation
 - 3T

Boxerman, AJNR 2006
Hu, AJNR 2010



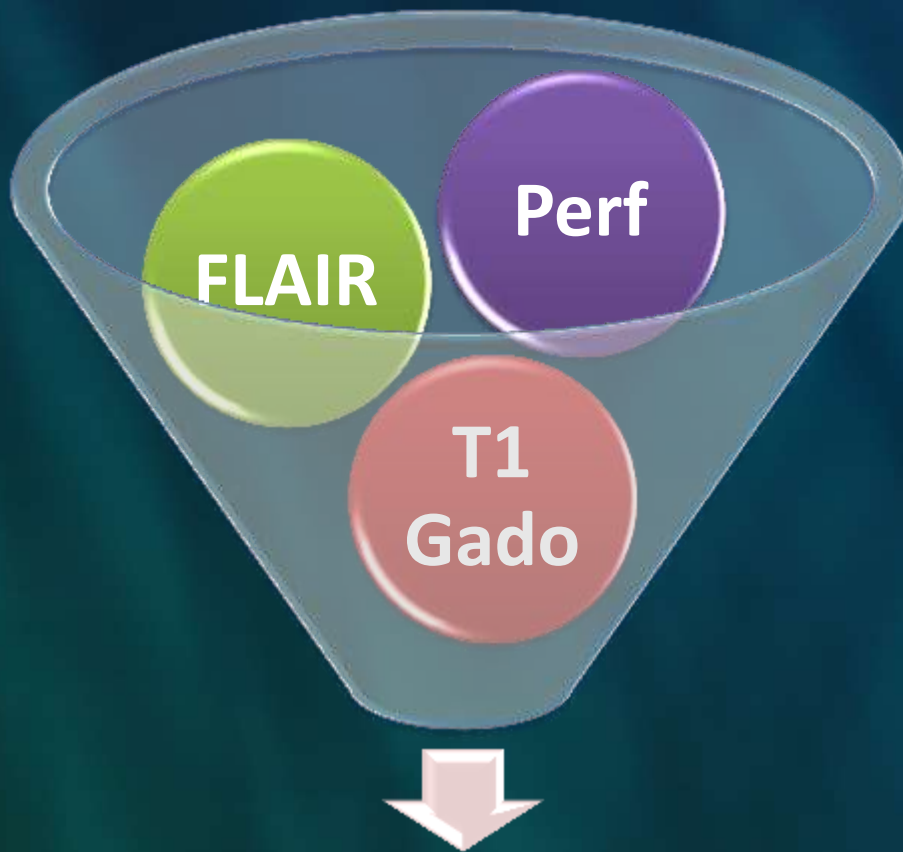
IRM de perfusion dans le suivi des tumeurs

Conclusion





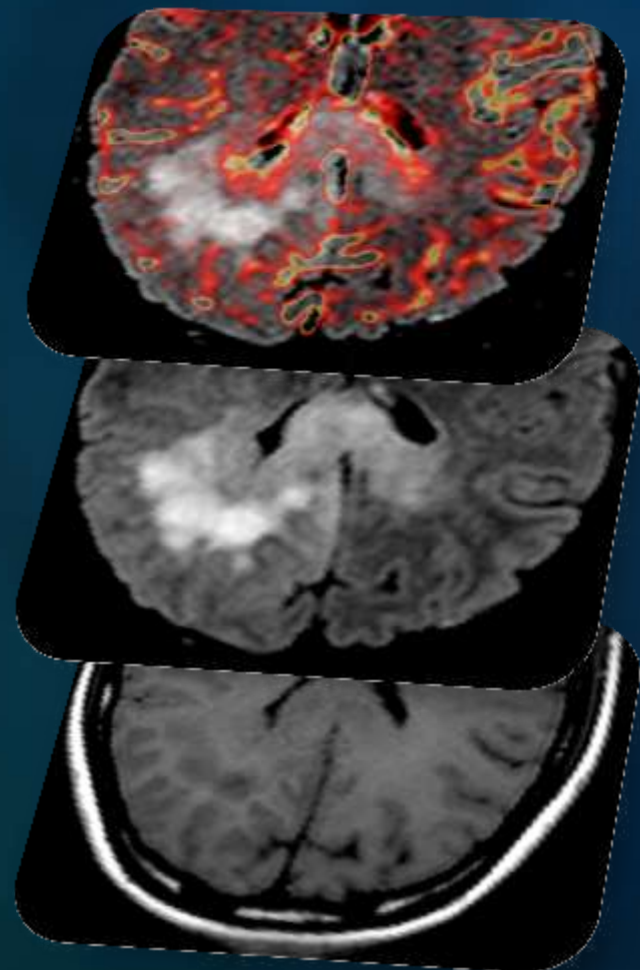
Le contexte et les nouveaux critères morphologiques (RANO) restent importants



Diagnostic d'évolutivité

Le protocole est adapté

L'interprétation intègre d'autres données que les mesures



La réalisation d'une perfusion dans le suivi
des tumeurs augmente la sensibilité et la
spécificité de l'examen.
Ne sortez pas sans elle !

