



RHYTHM 2017

Arrhythmias & Heart Failure

New Insights & Technological Advances

March 2-3

9th Congress Edition

Novotel PARIS Tour Eiffel




QUIZZ

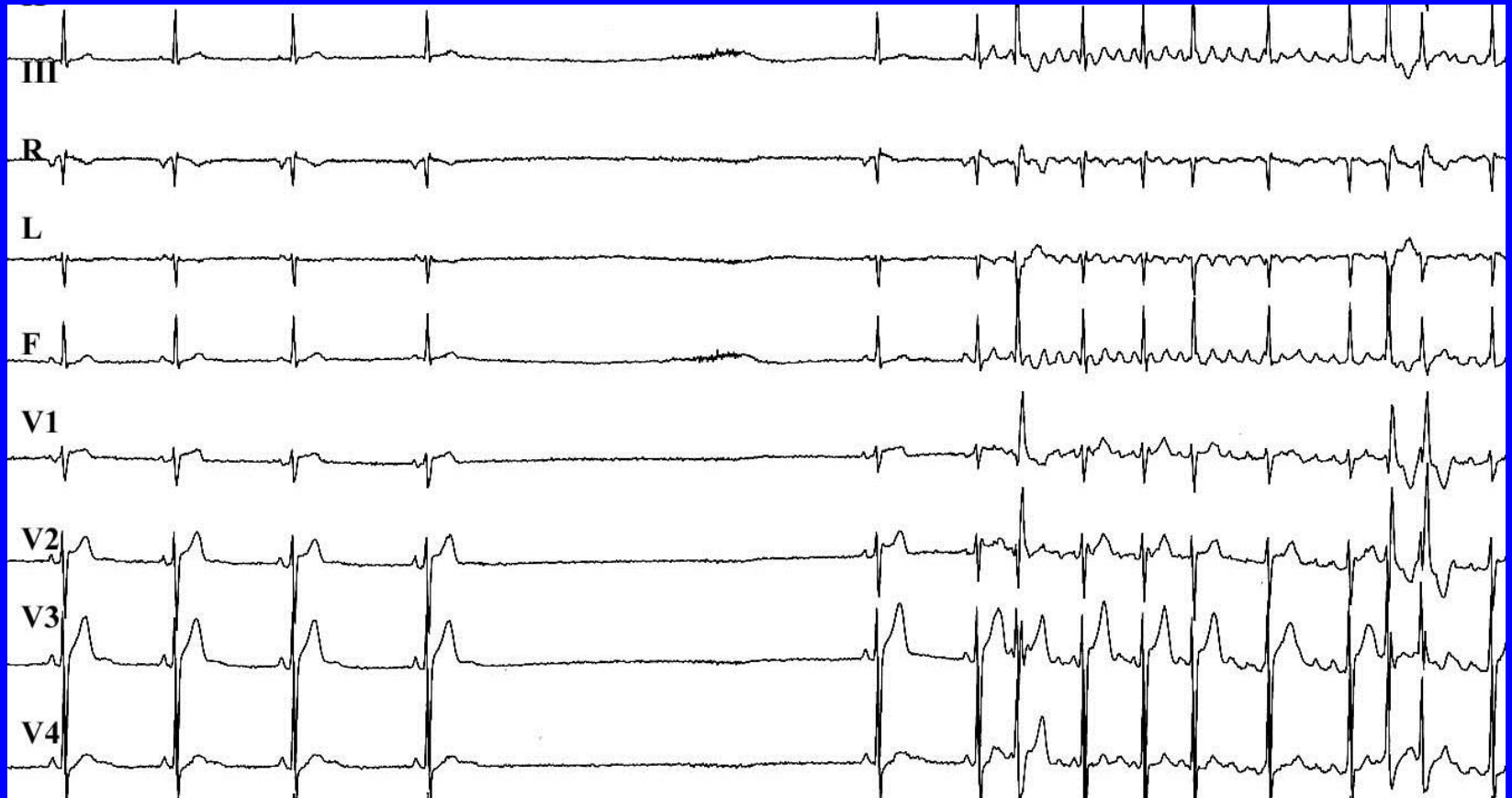Session paramédicale

www.rhythmcongress.com

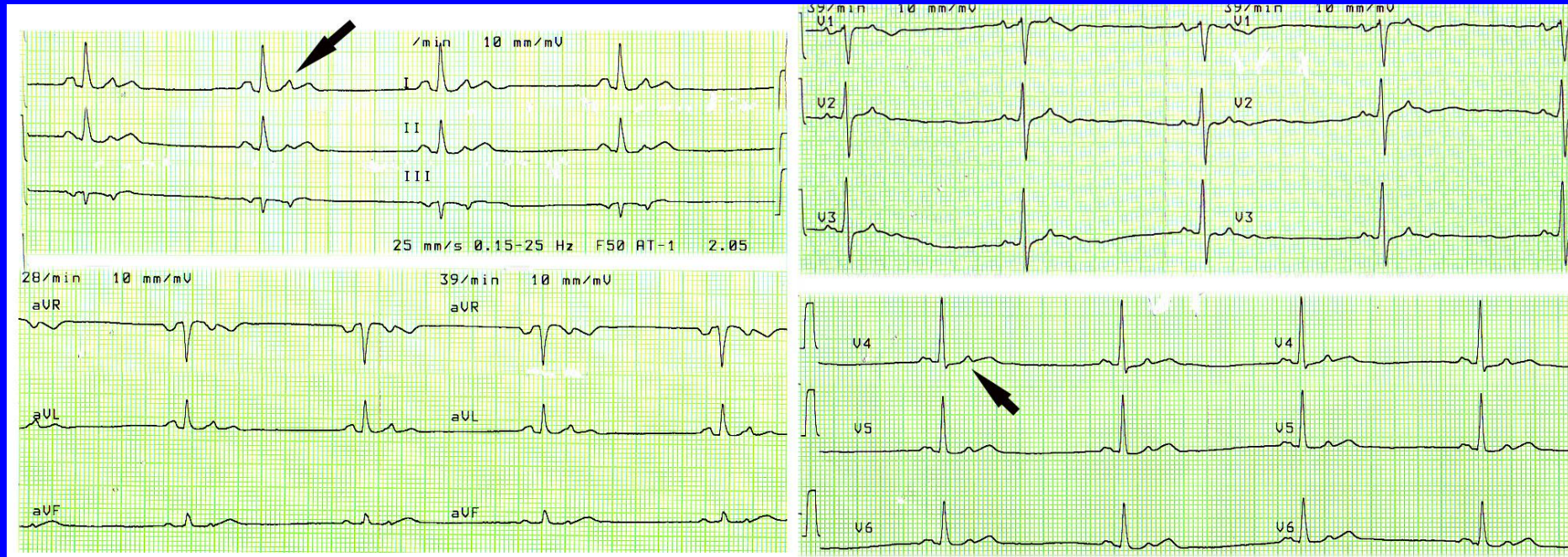
Patient consultant pour syncope



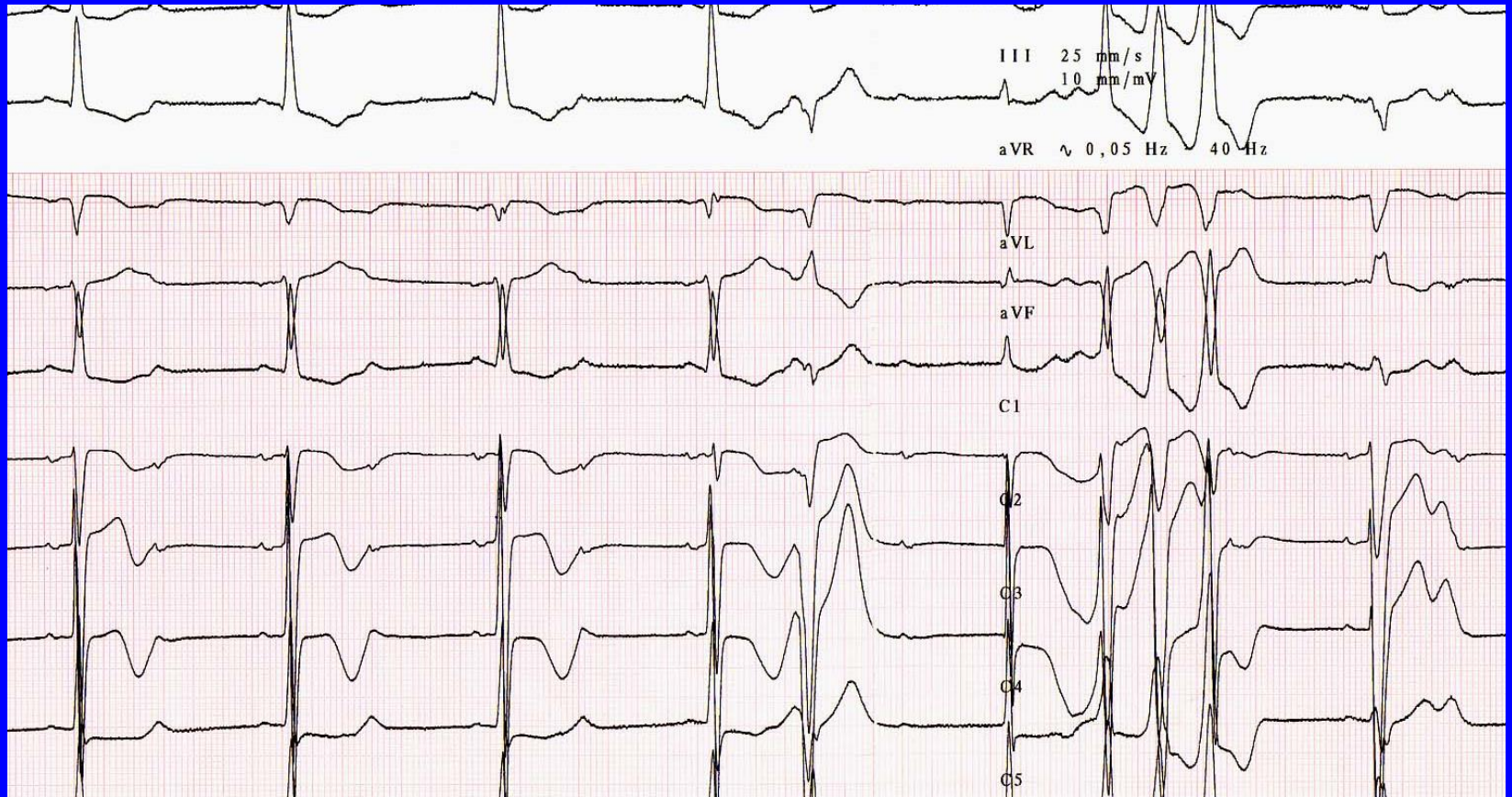
Montée de sonde endocavitaire par voie veineuse fémorale



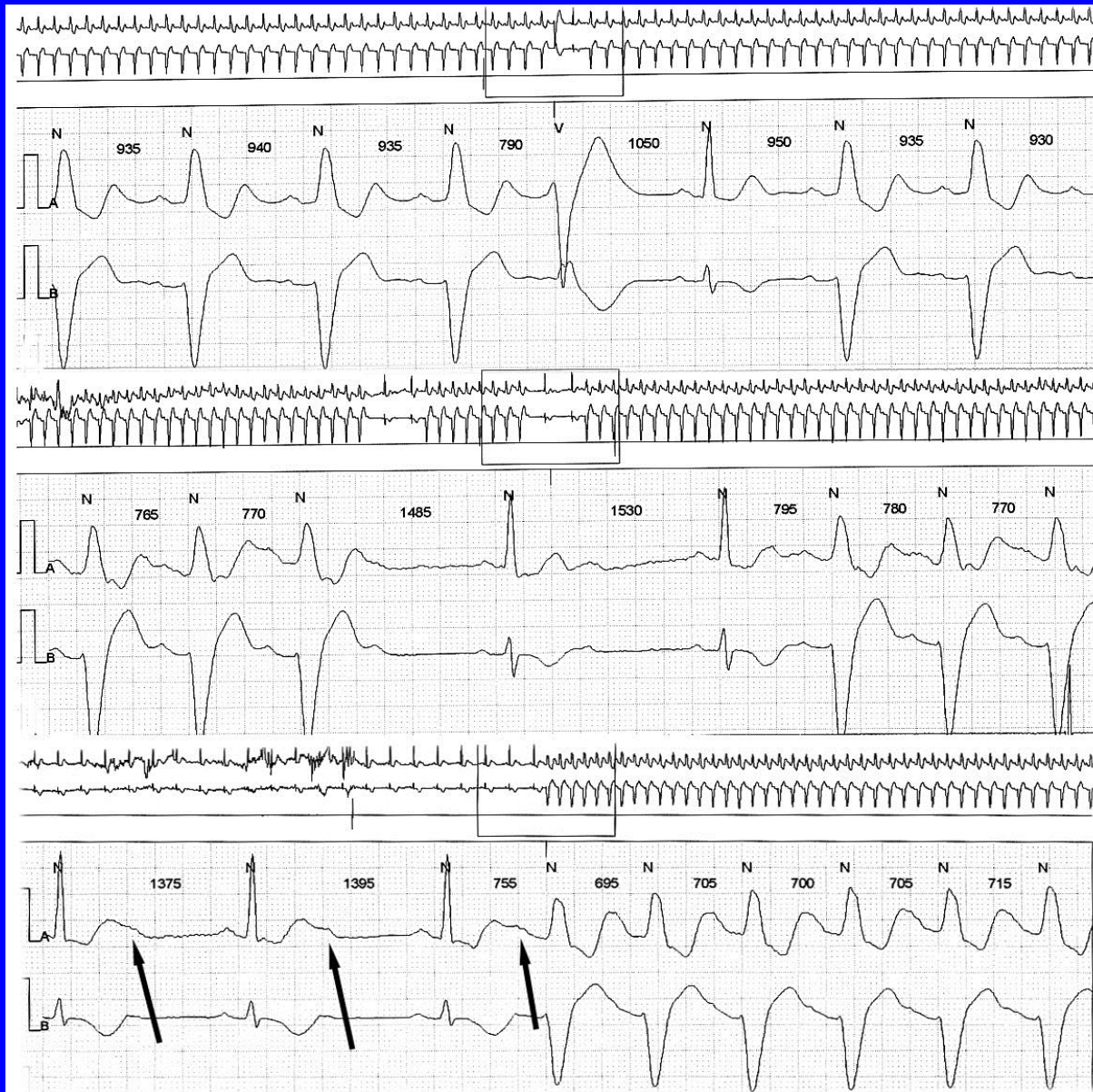ECG d'un patient venant pour Ablation de FA



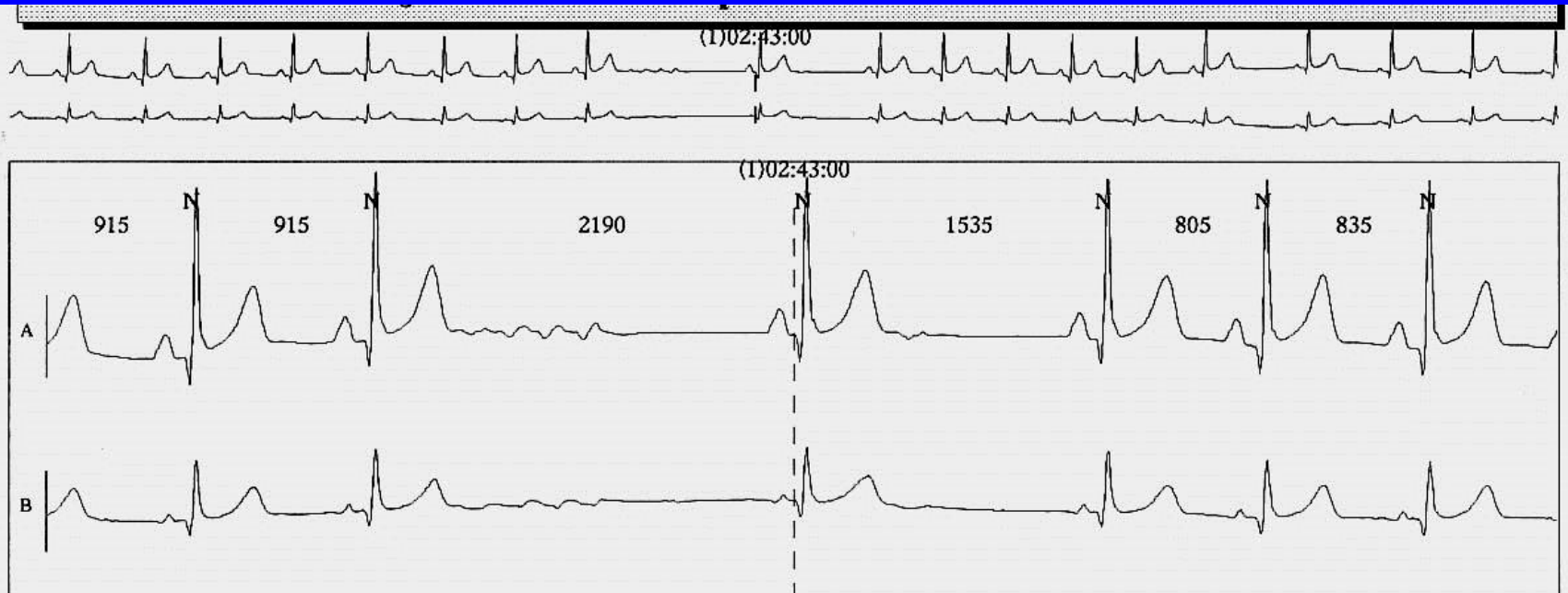
78 ans, sous diurétiques pour HTA, consulte pour syncopes



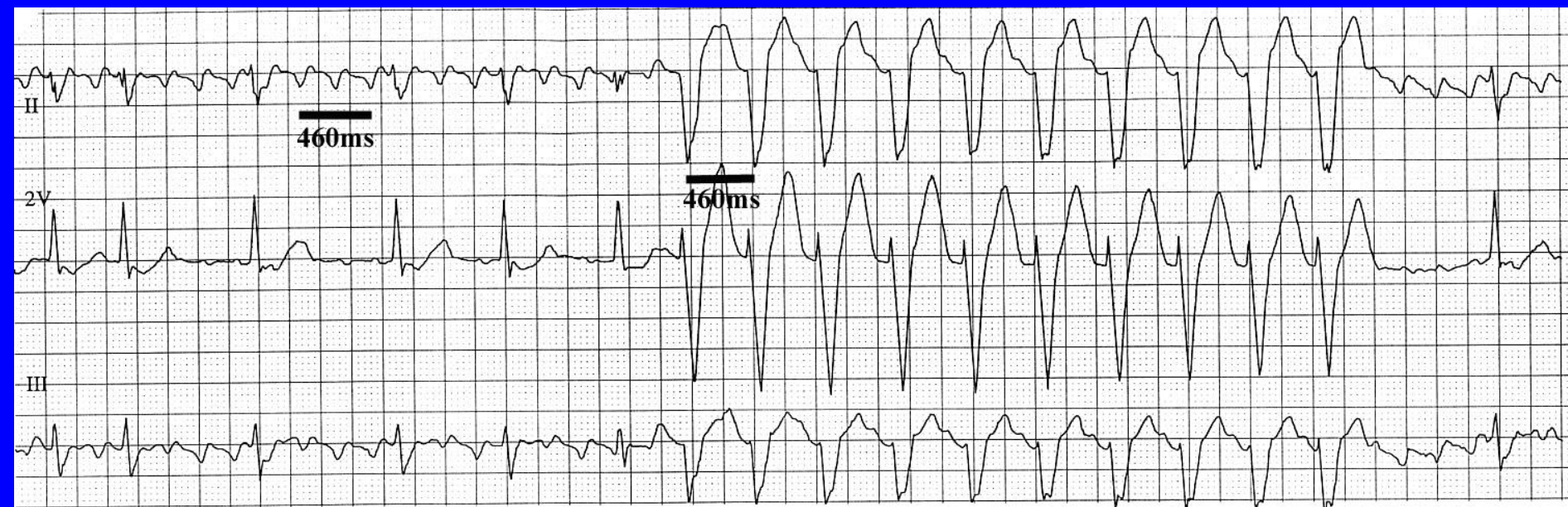
68 ans, dyspnée d'effort. Holter



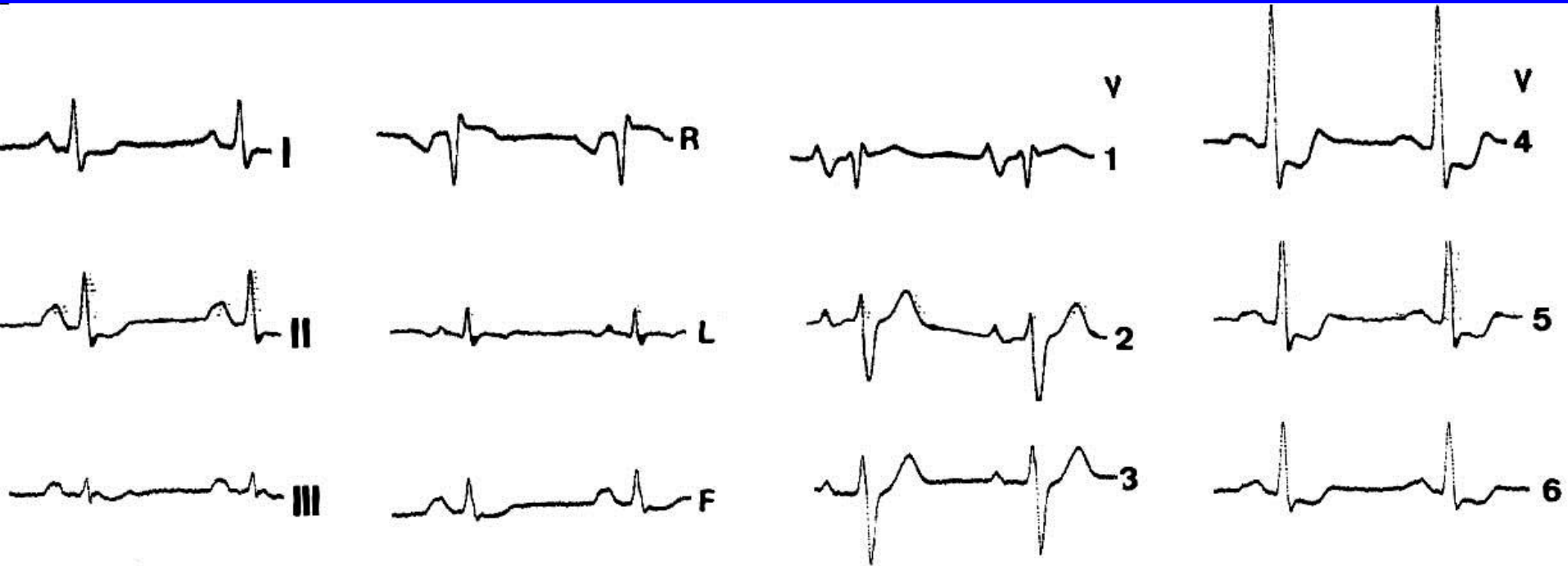
Holter de patient consultant pour palpitations



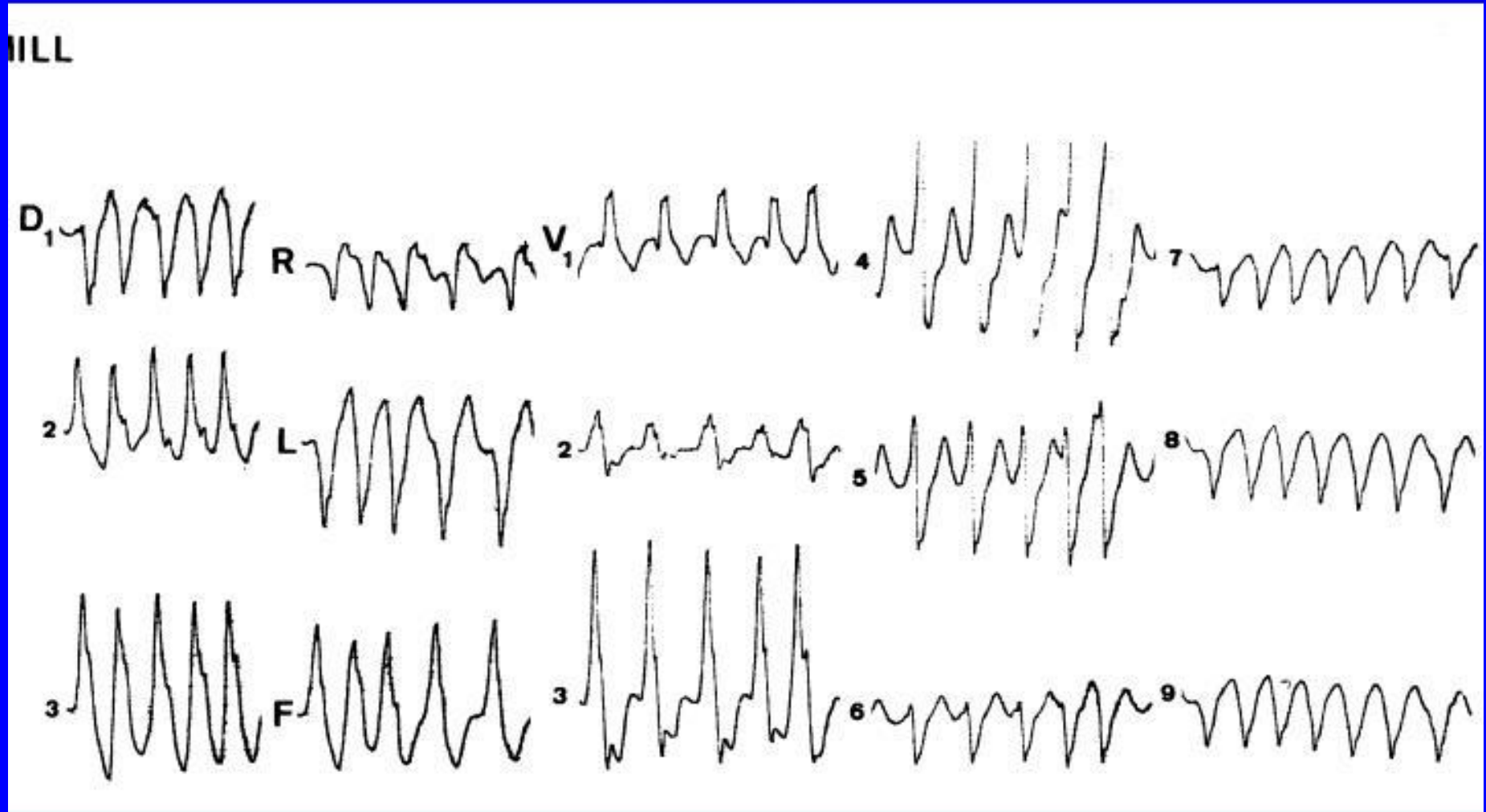54 ans, cœur sain, TdR auriculaires récidivants, sous Flécaine



Patient de 75 ans, palpitations sévères

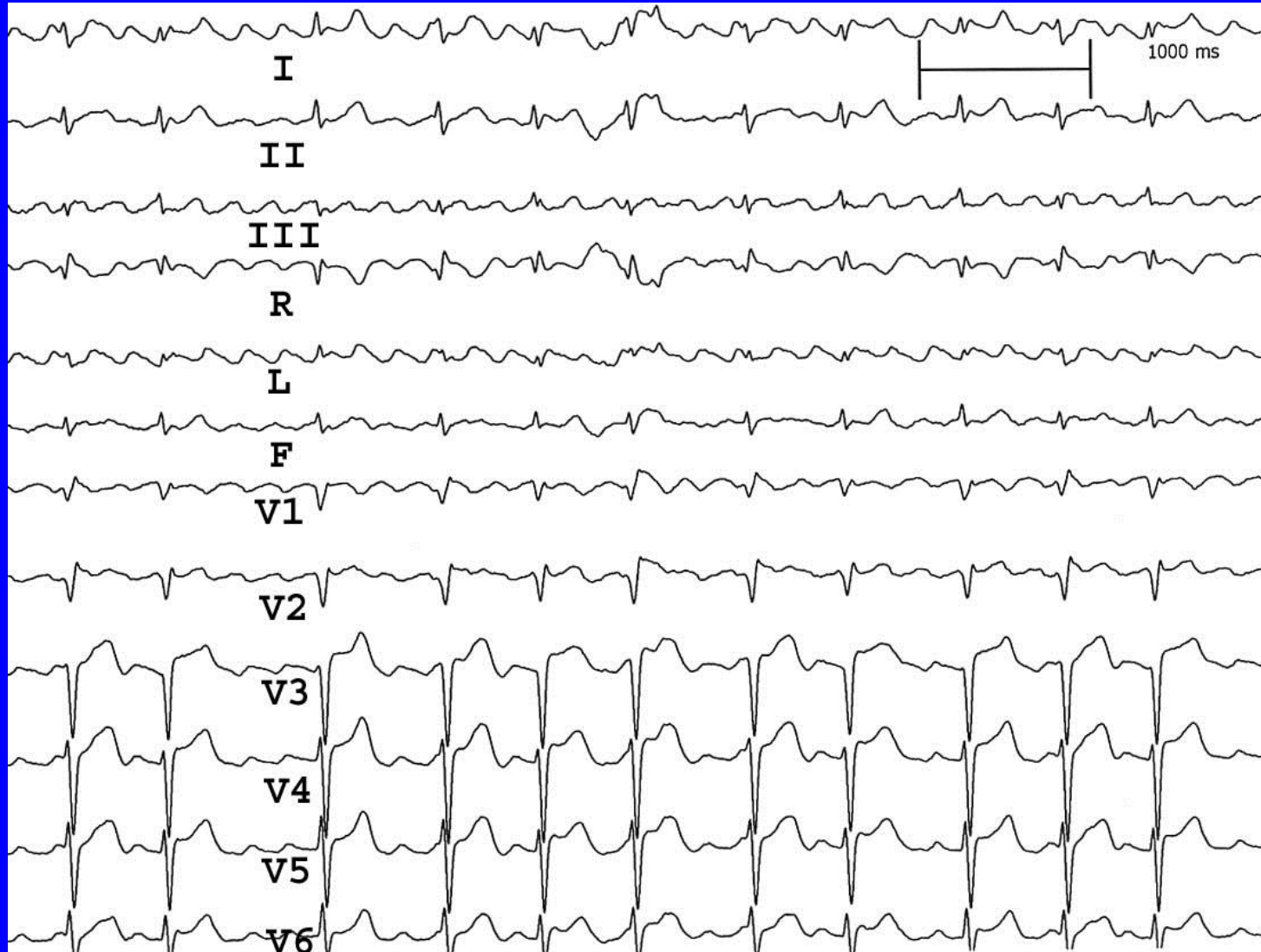


K LG

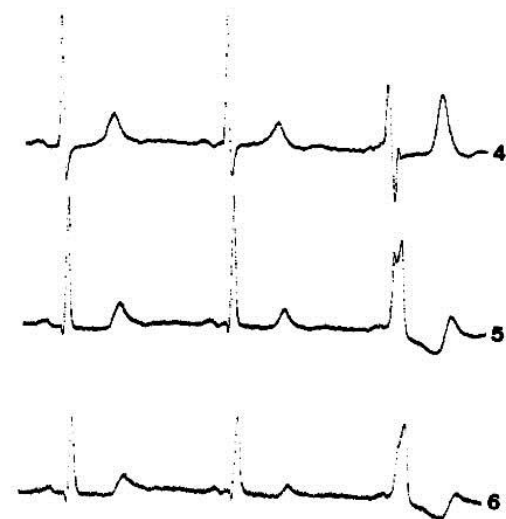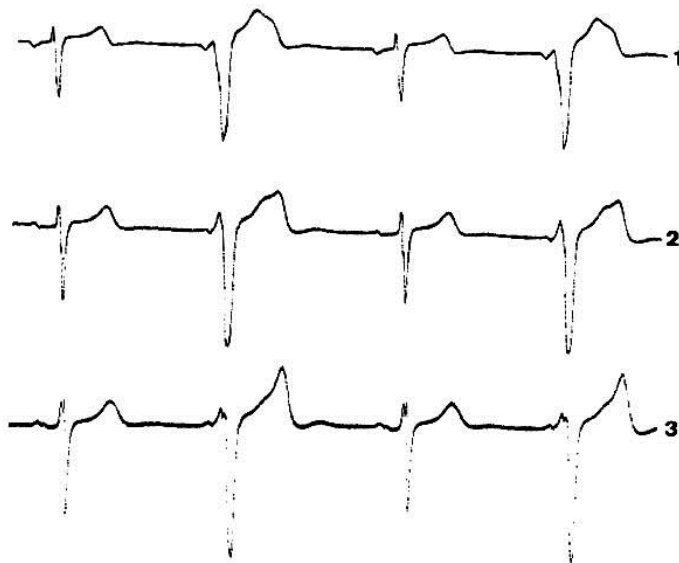
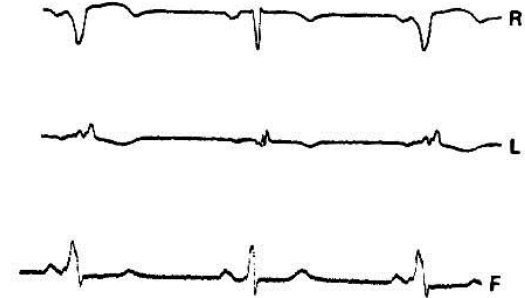
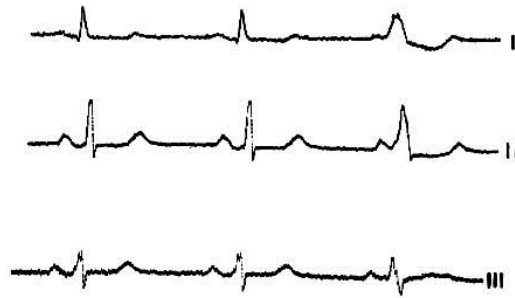


Le même, pendant la palpitation

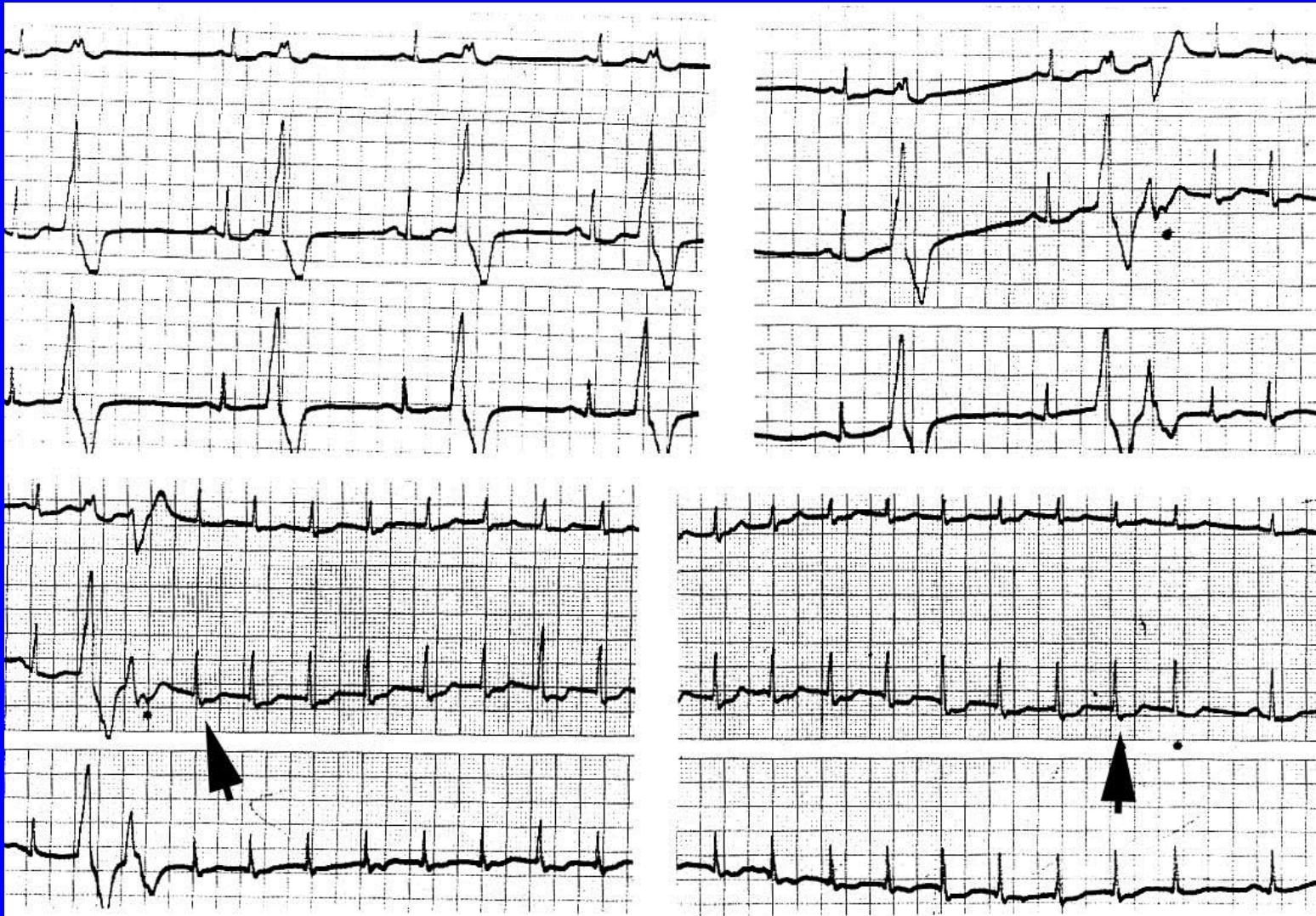
52 ans, ablation de flutter commun il y a 3 ans.



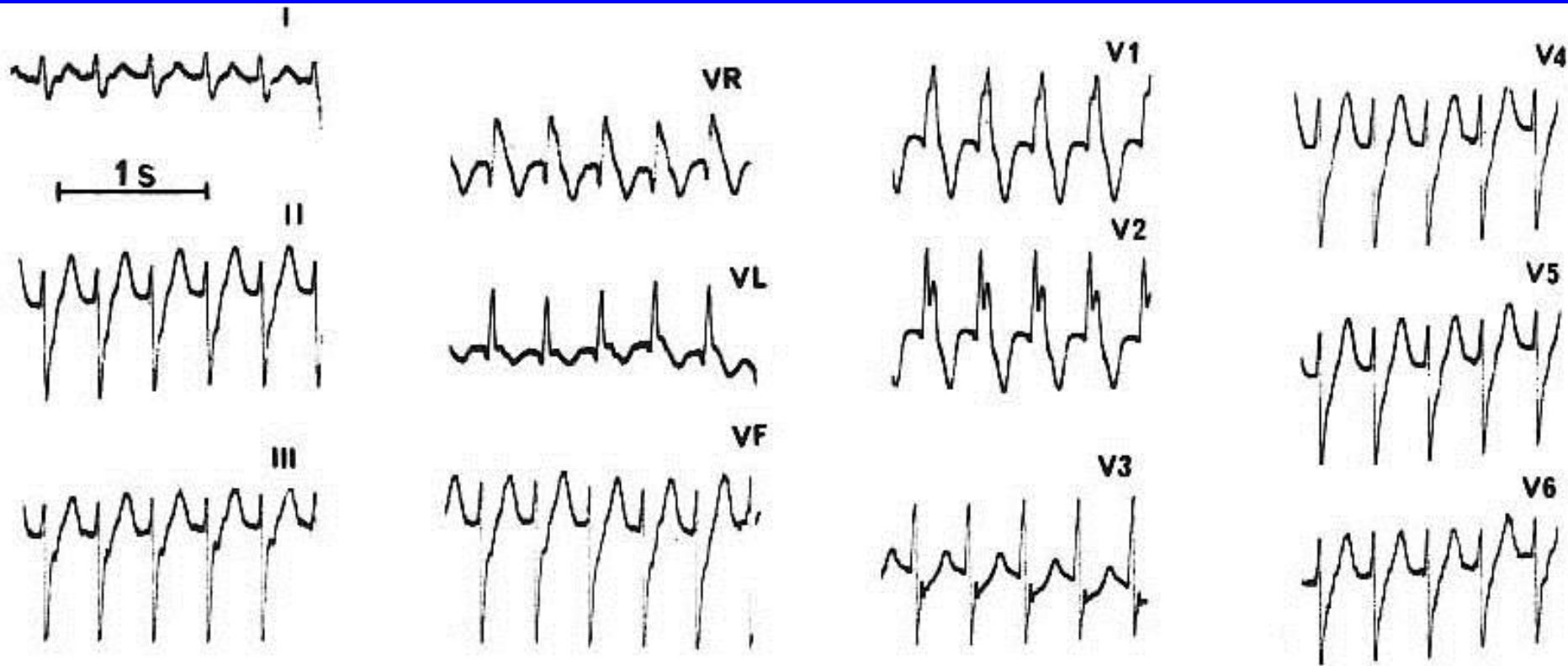
33 ans, asymptomatique



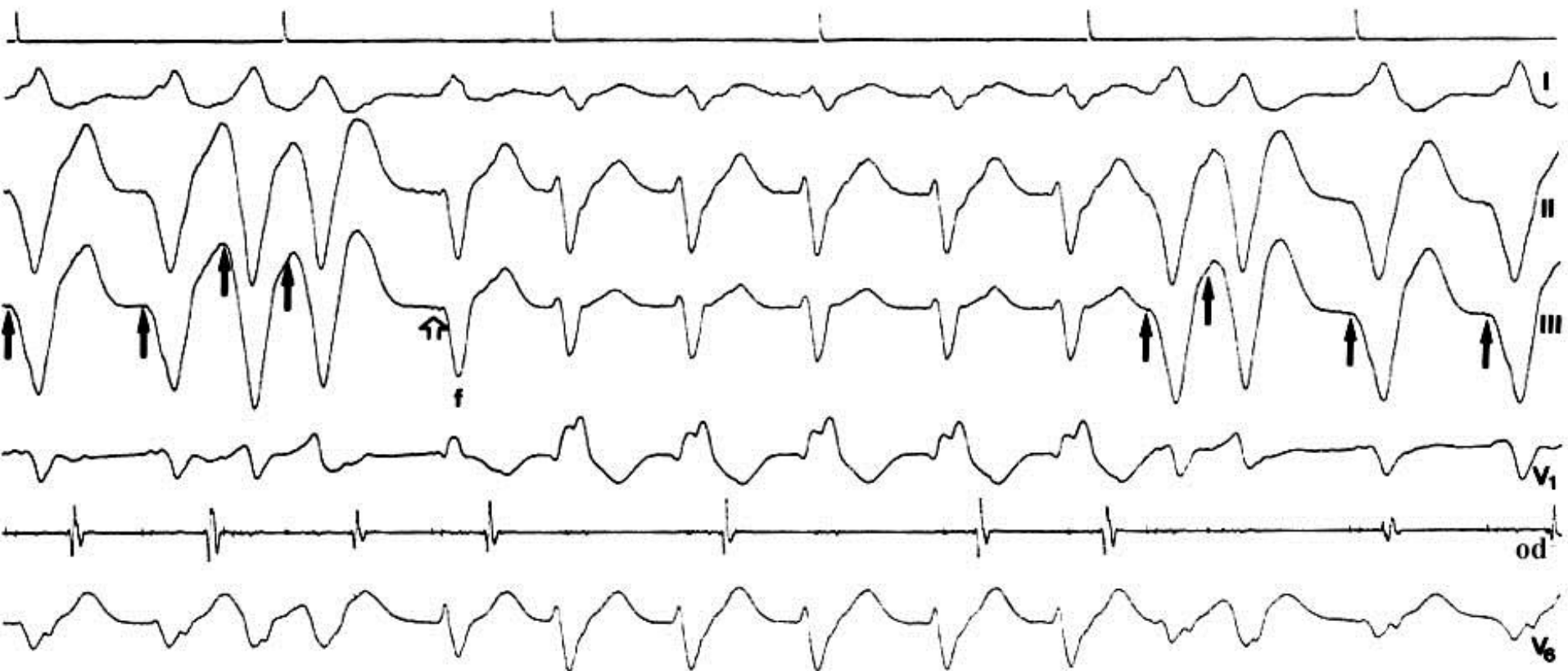Idm ancien, palpitations



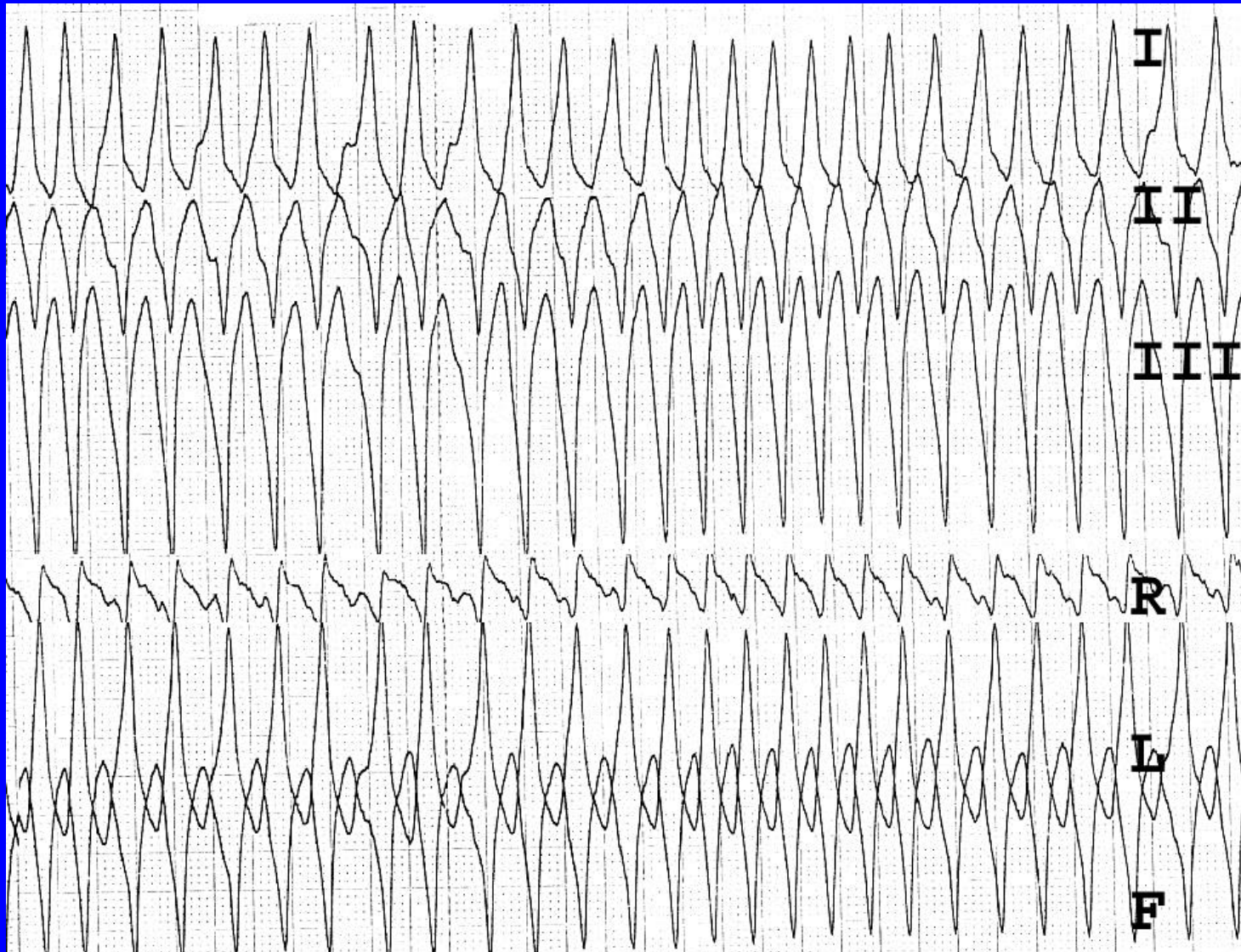
23 ans, Bouveret typique



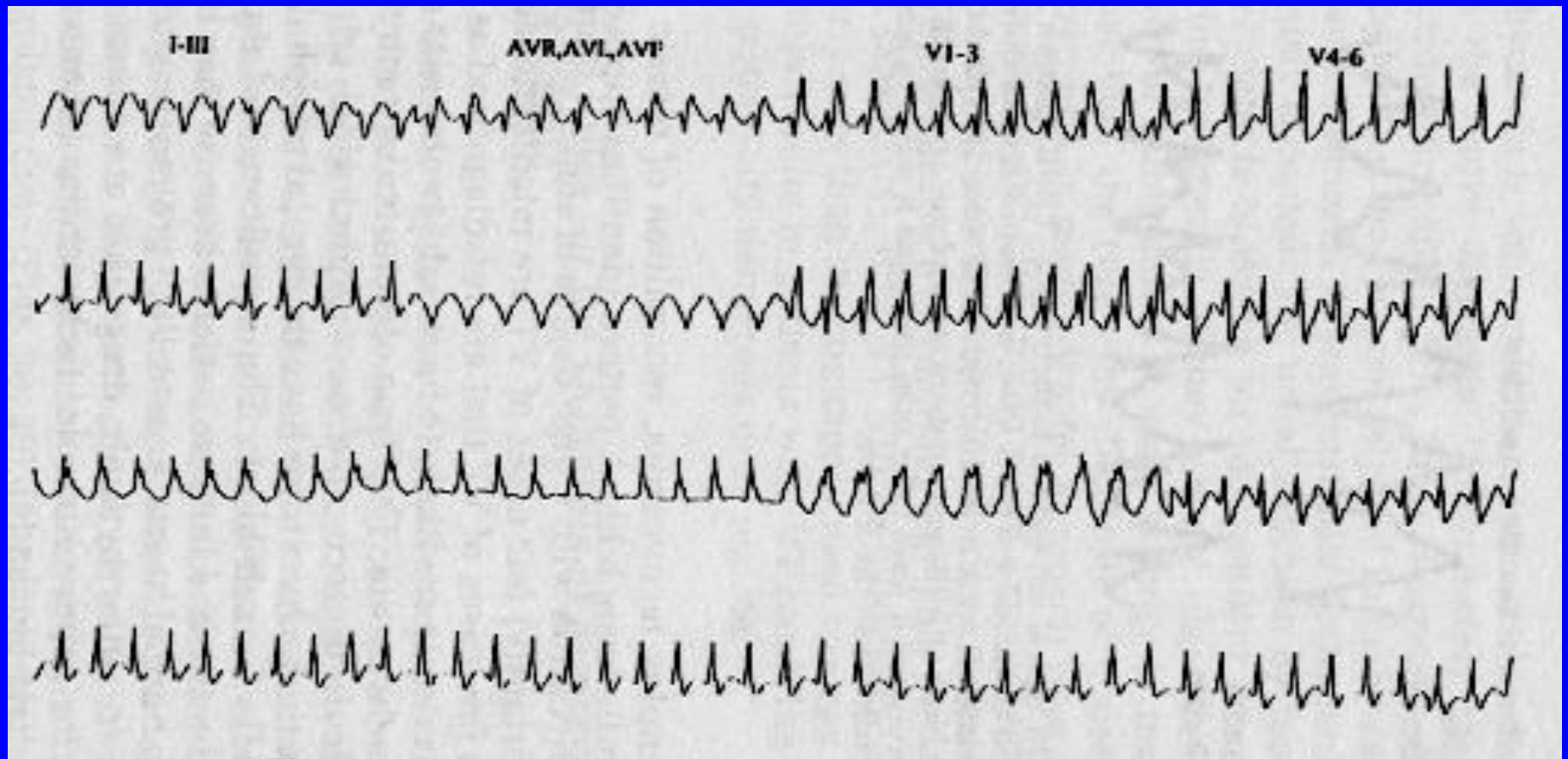
La même, exploration EP



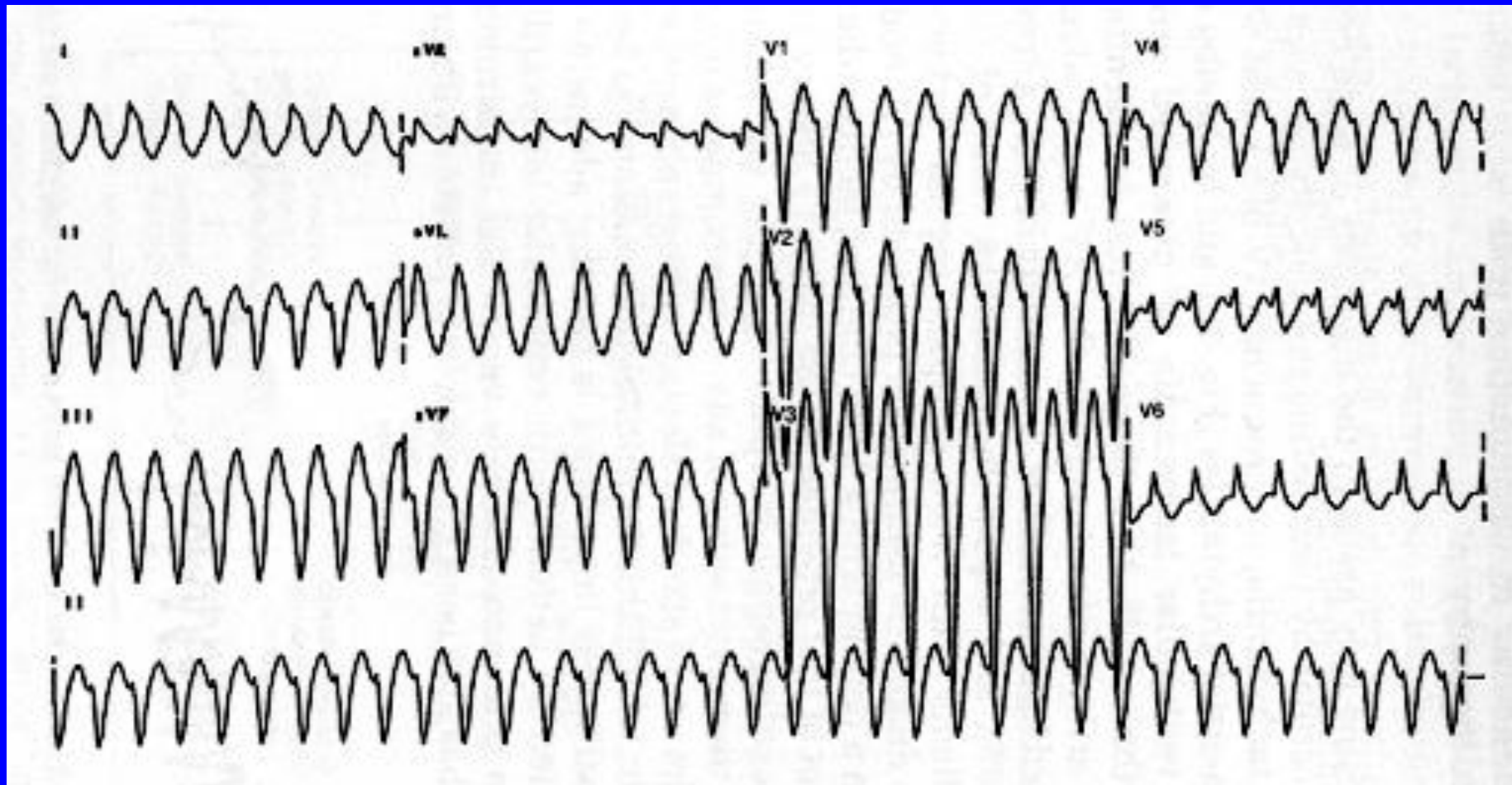
Palpitations



Palpitations



Palpitations



Palpitations

