




RHYTHM 2017

Arrhythmias & Heart Failure
New Insights & Technological Advances

March 2-3

9th Congress Edition
Novotel PARIS Tour Eiffel



Bases anatomiques et électrophysiologie

Dr Clément BARS

Hôpital St Joseph-Marseille

03-03-2017

www.rhythmcongress.com

Electrophysiologie

De la cellule à l'organe

2 populations de cellules



**Commande
Electrique**

Genèse de l'influx = Nœud sinusal

Transmission de l'influx =

- Nœud auriculo-ventriculaire
- Faisceau de His et ses branches



Contraction

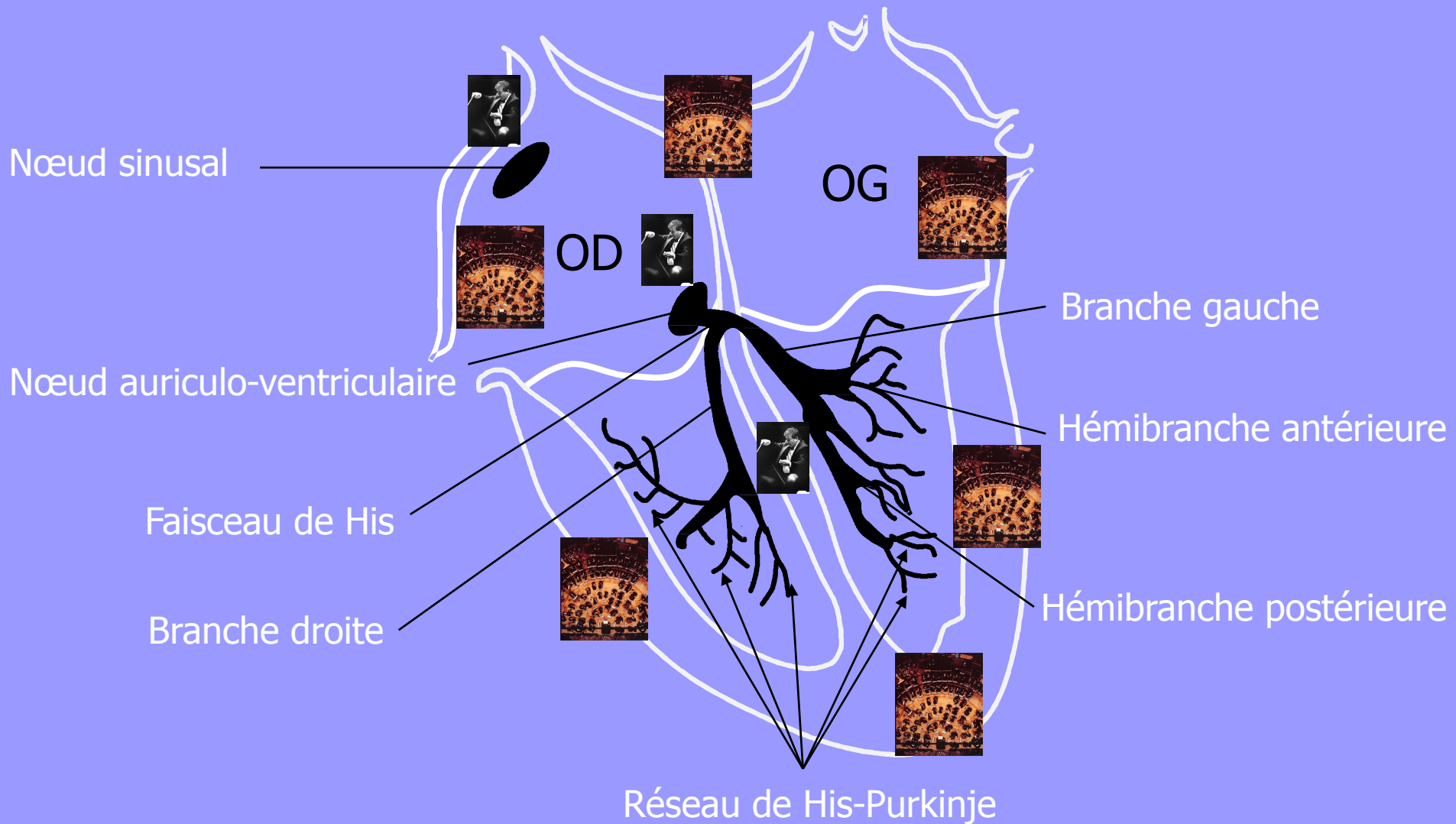
=

Cardiomyocytes

Myocarde atrial et ventriculaire

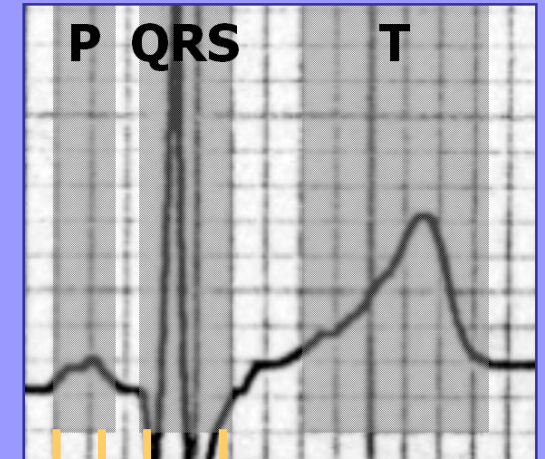
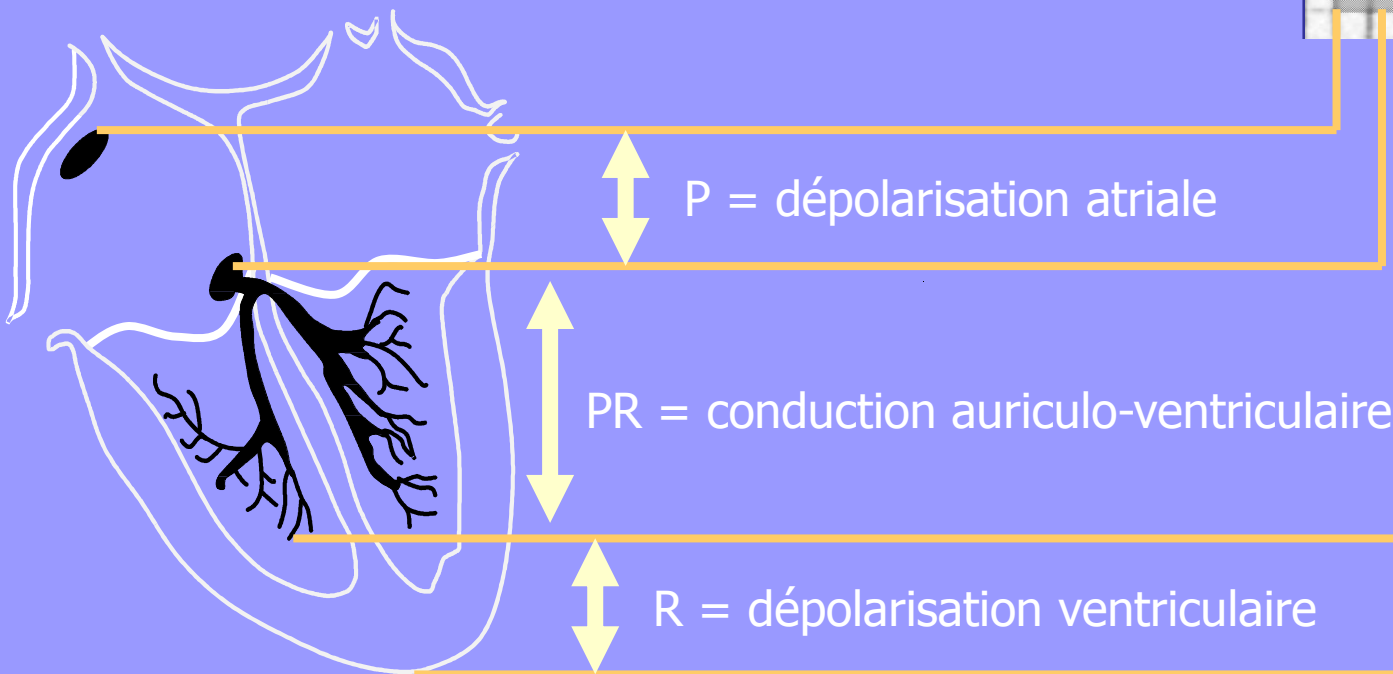
Electrophysiologie

Les voies de conduction



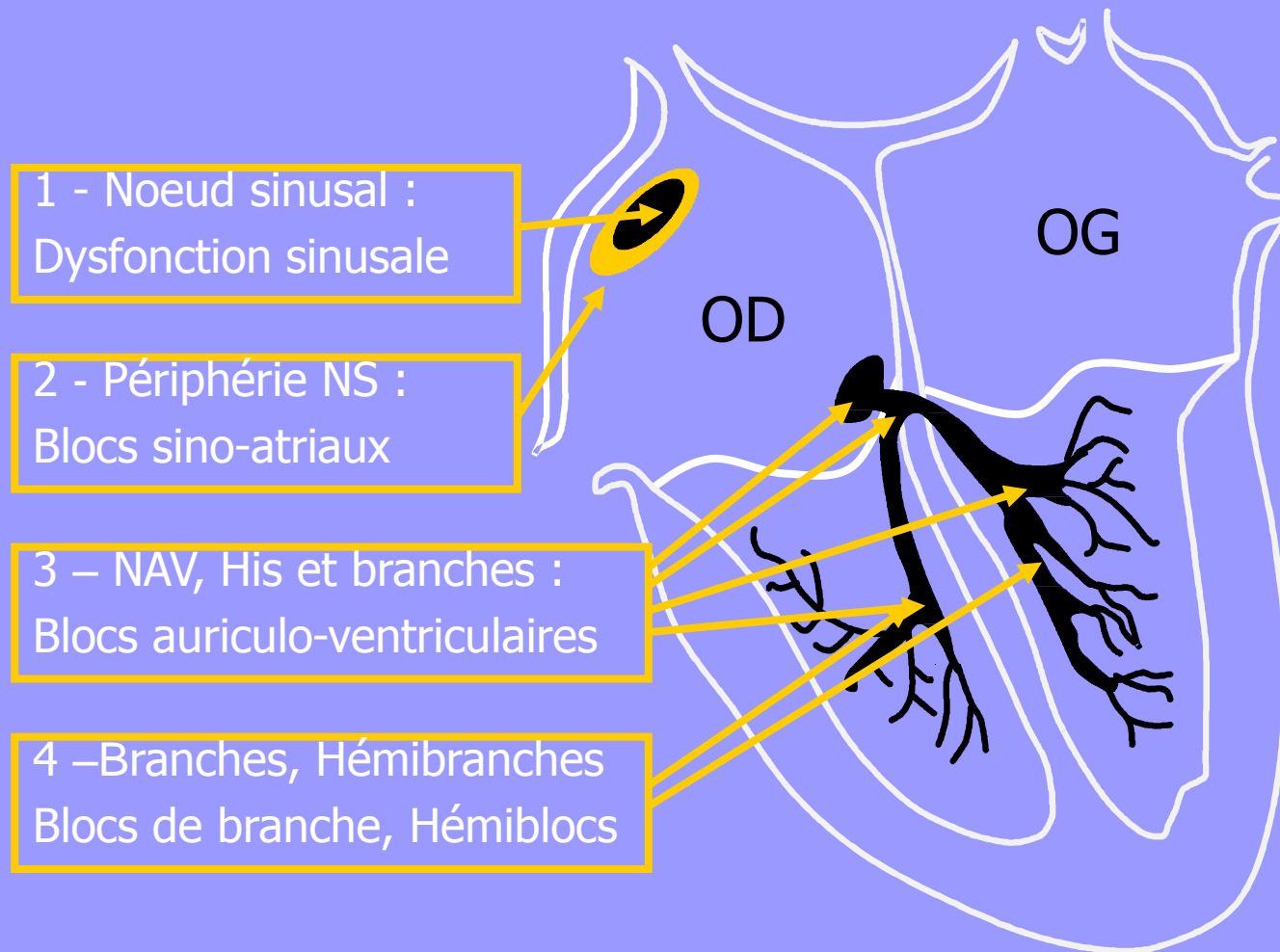
Electrophysiologie

Les voies de conduction



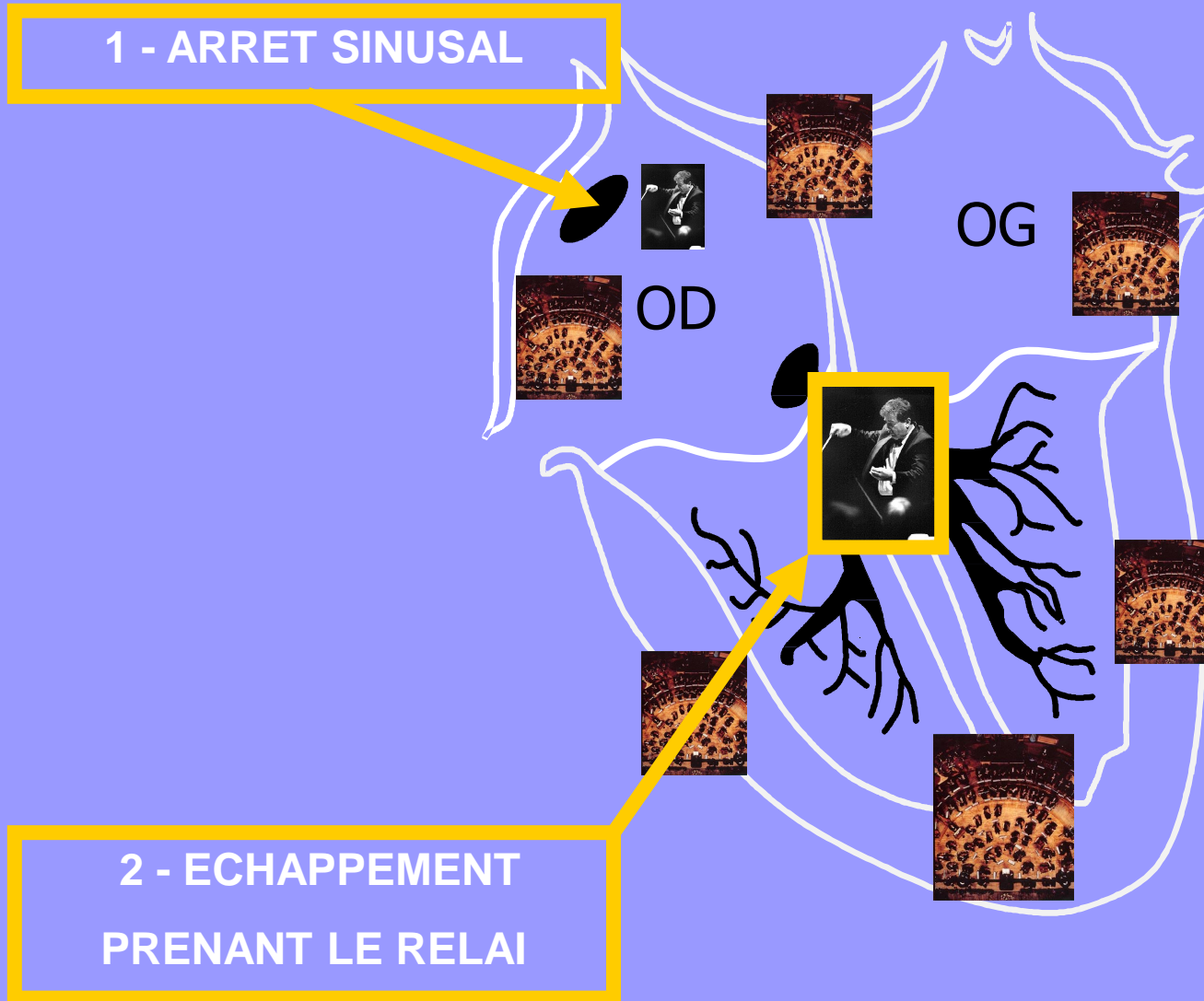
Electrophysiologie

Les voies de conduction : anomalies



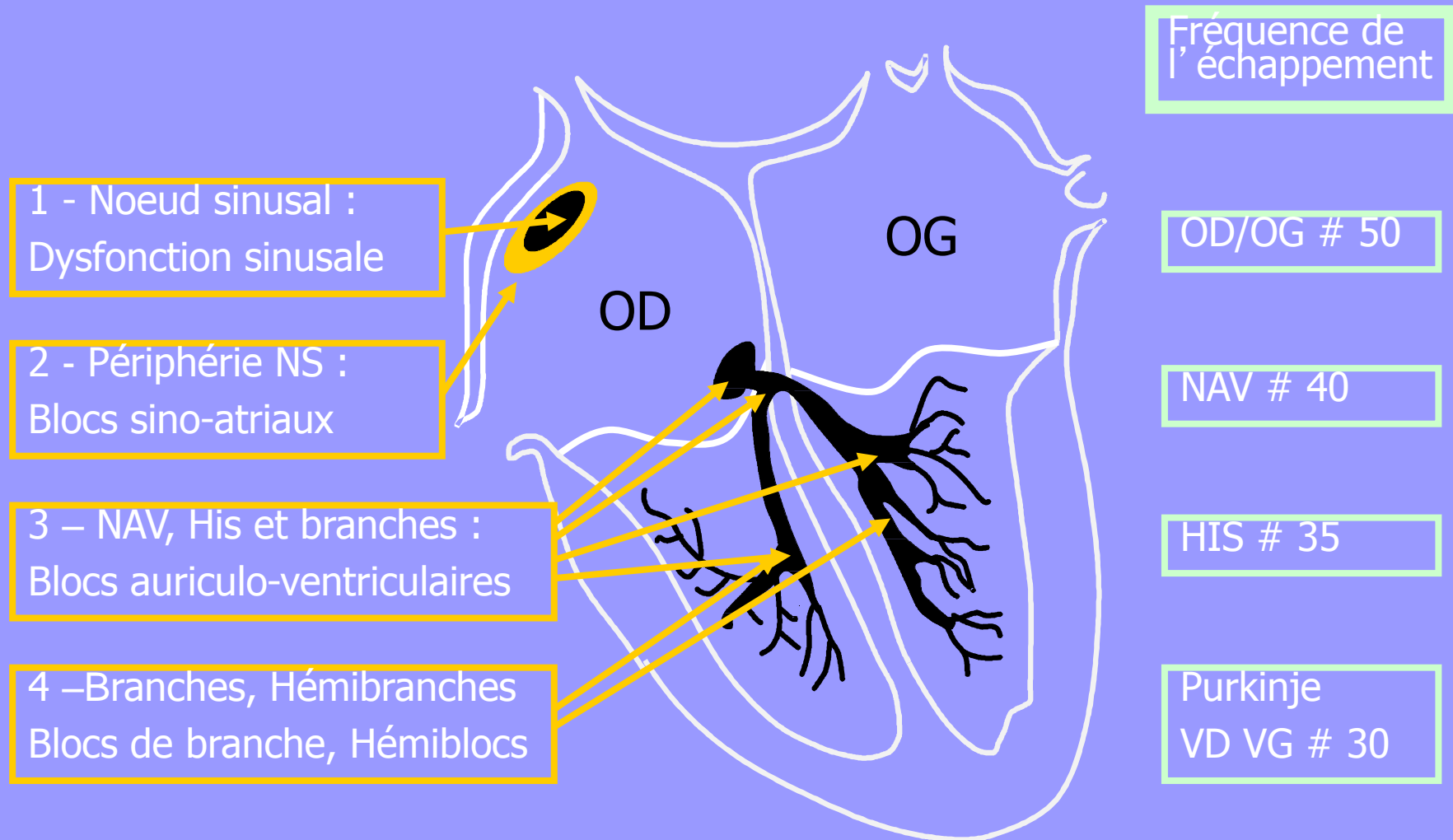
Electrophysiologie

Les voies de conduction : notion d'échappement

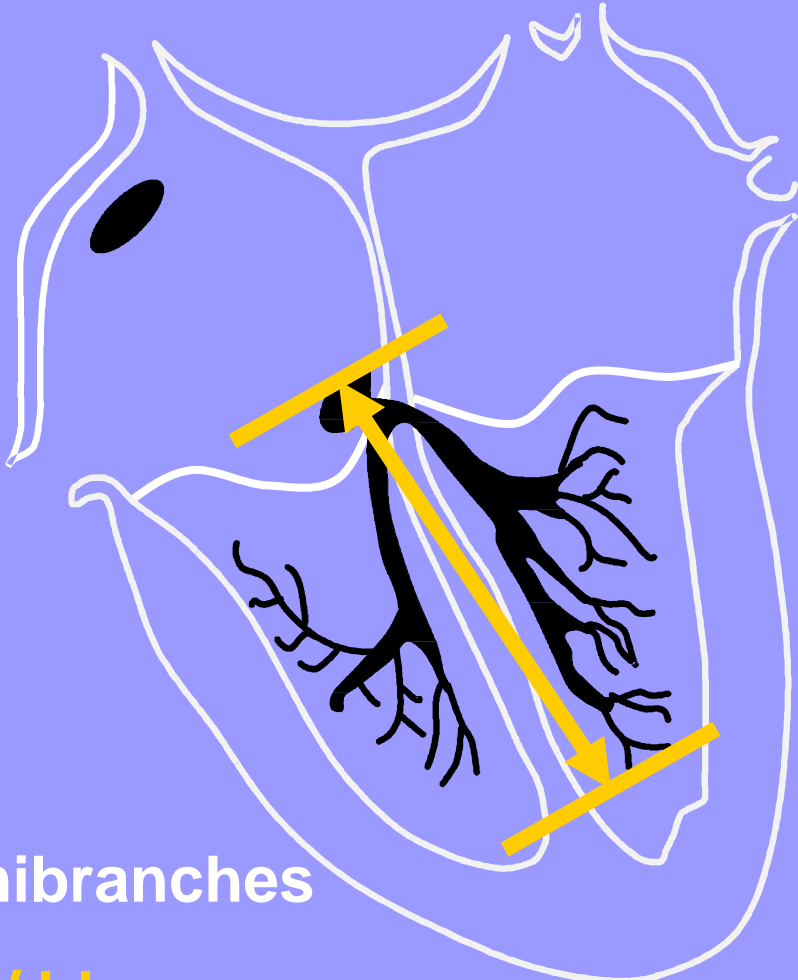
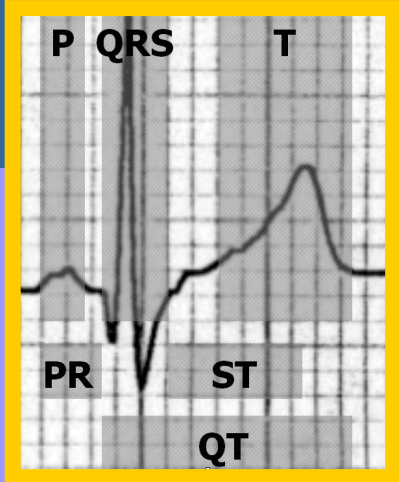


Electrophysiologie

Les voies de conduction : rythme d'échappement



Blocs auriculo-ventriculaires



NAV

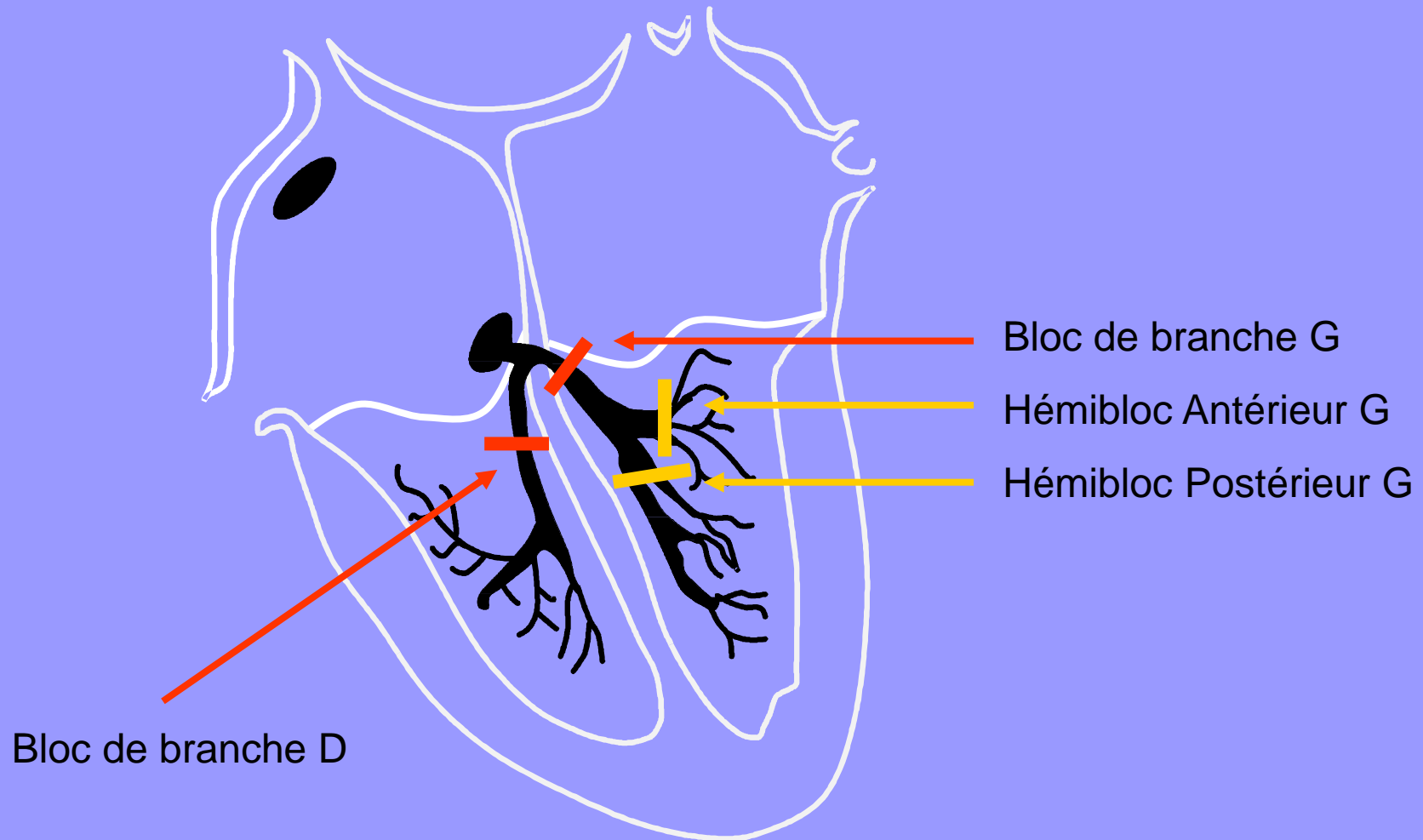
His

Branches – Hémibranches

Ralentissement / blocage
Permanent / Intermittent

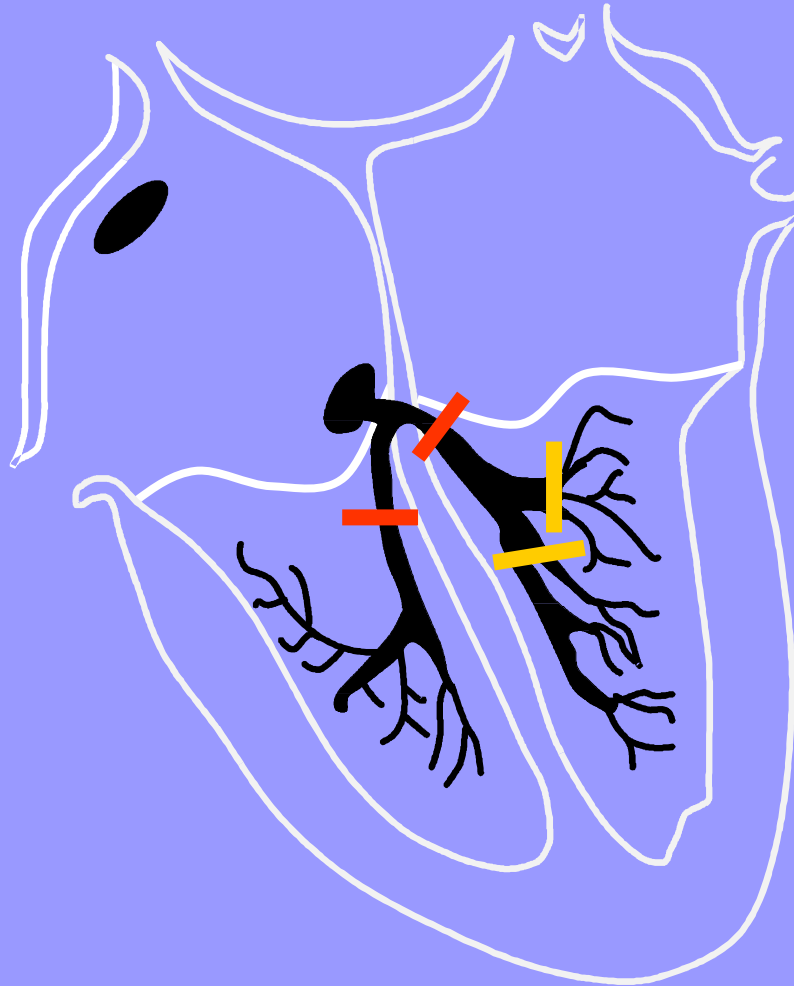
Interprétation

Blocs de branche



Interprétation

Blocs de branche



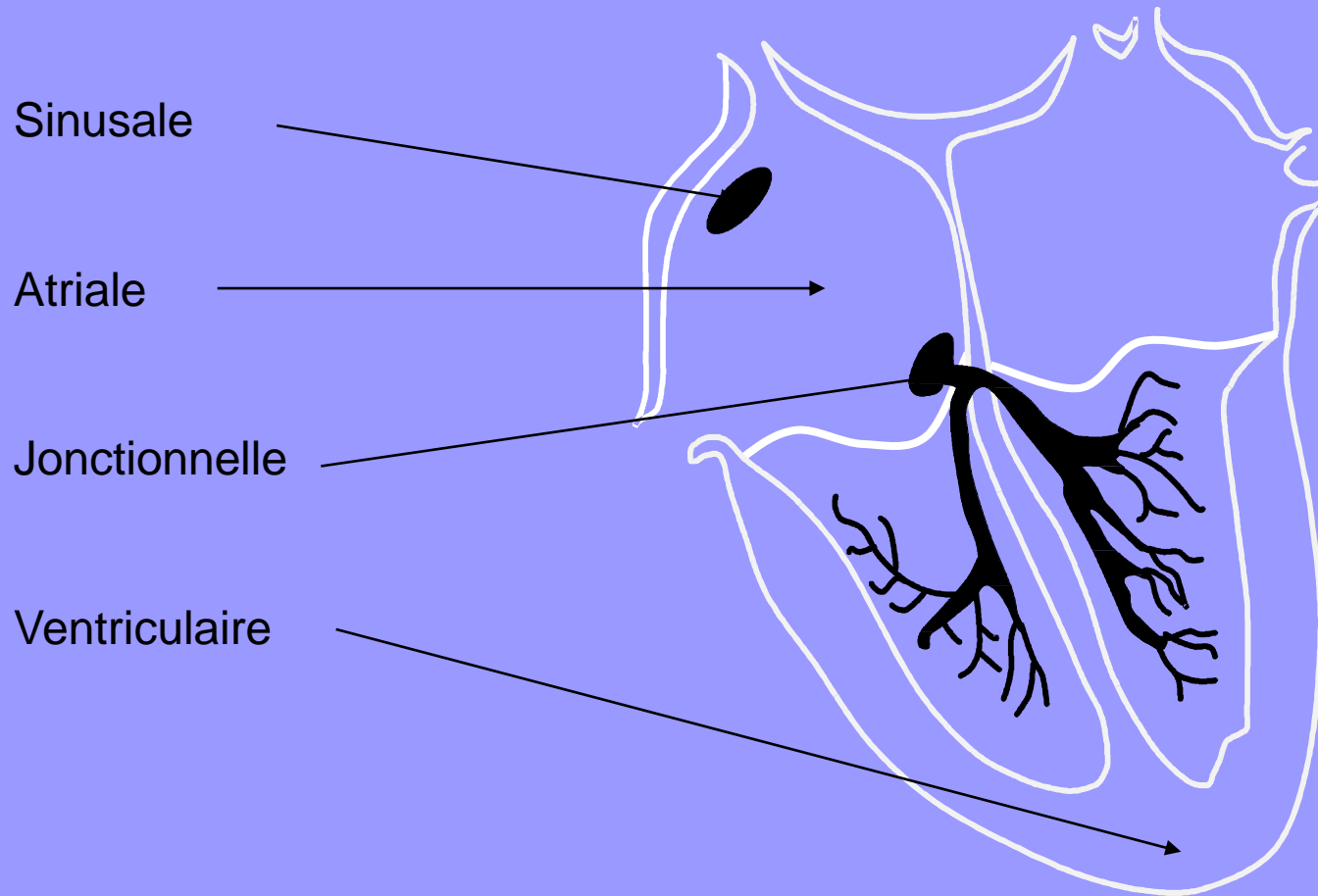
Combinaisons :

BBD + HBAG

BBD + HBPG

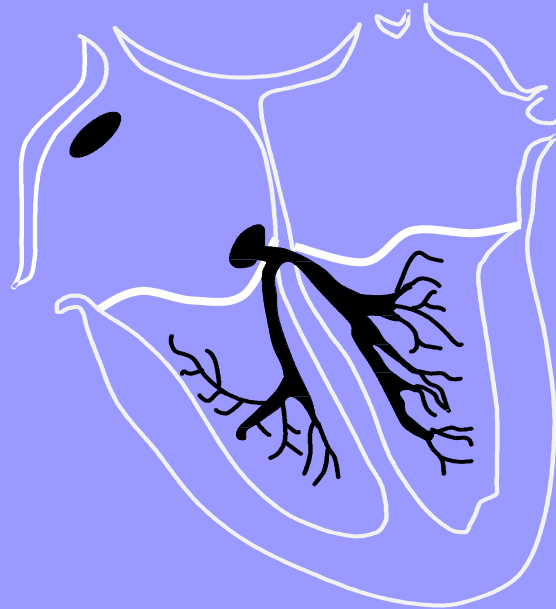BBG + BBD = BAV III !!!

Tachycardies

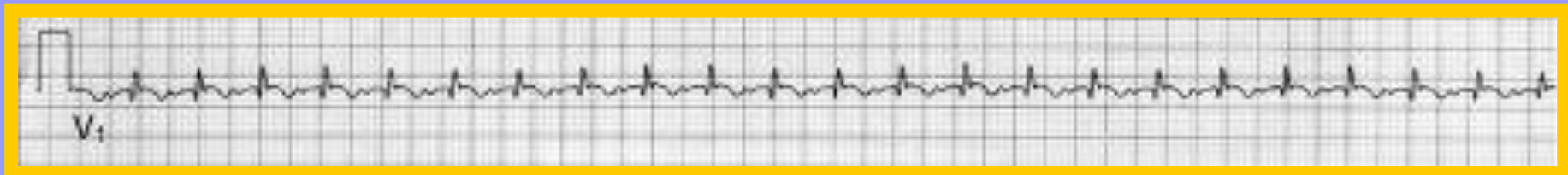


Tachycardies

Tachycardie Sinusale

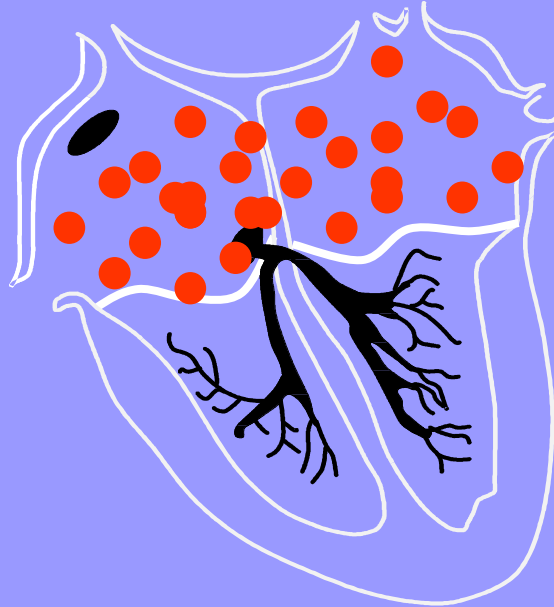


Rythme sinusal accéléré (fièvre, effort, émotion, anémie...)




Tachycardies

Fibrillation atriale

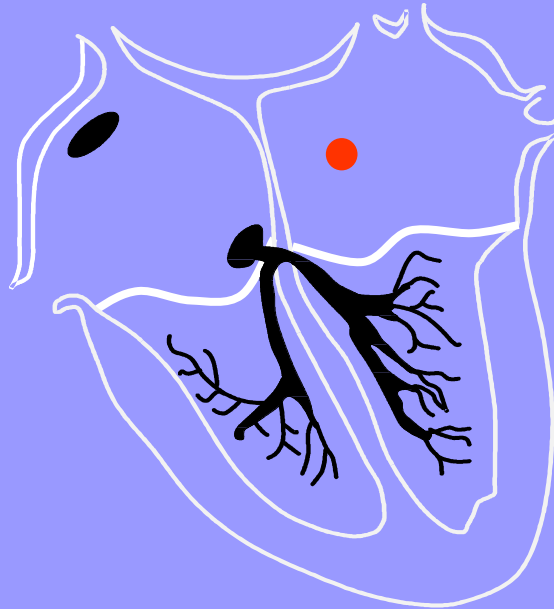

Rythme atrial anarchique, toutes les cellules atriales se dépolarisant de façon désorganisée, très rapide : tachycardie irrégulière




Tachycardies

Extrasystole atriale

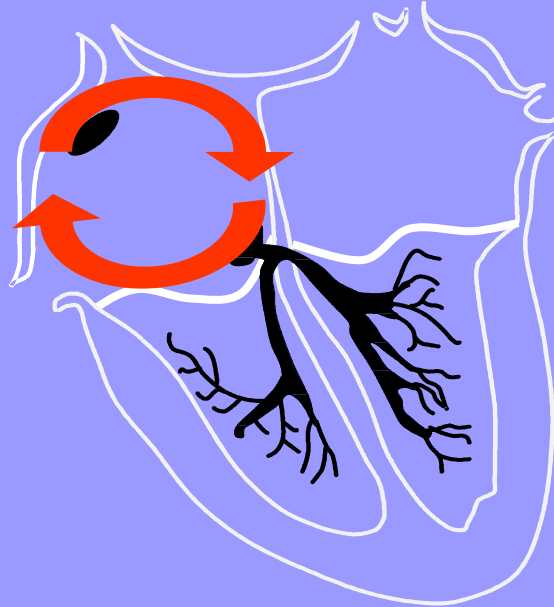

Contraction atriale prématurée (extrasystole) liée à un foyer d'activation anormal (différent du nœud sinusal)



Tachycardies

Flutter atrial



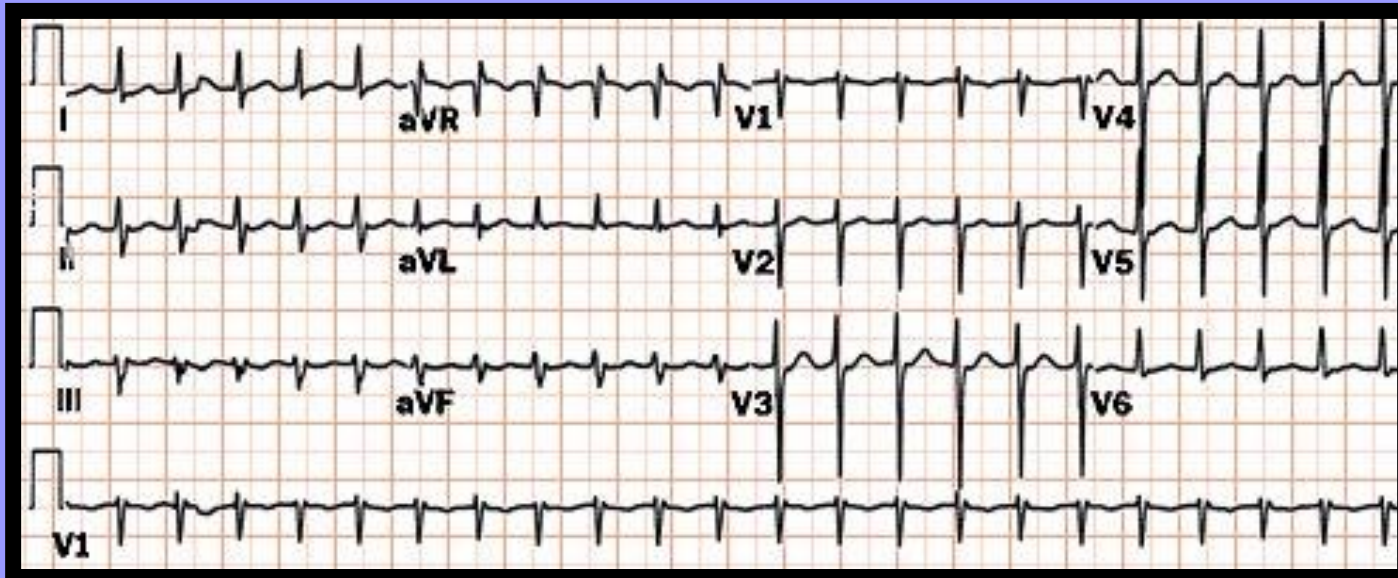
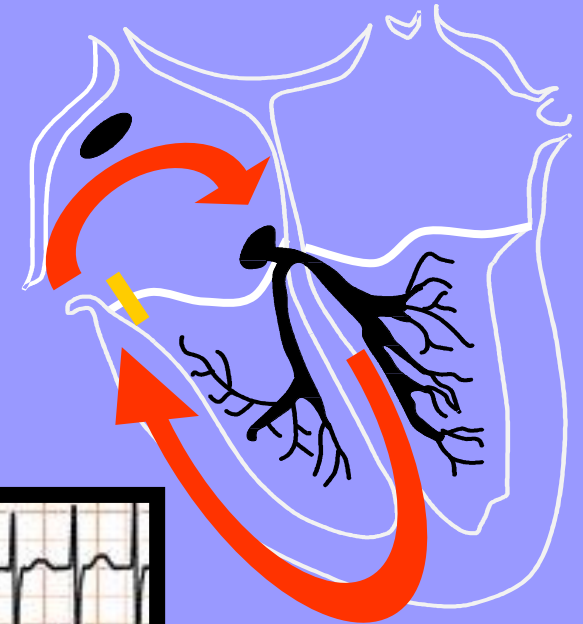
Tachycardie liée à un circuit dans l'oreillette droite tournant à 300/mn



Tachycardies

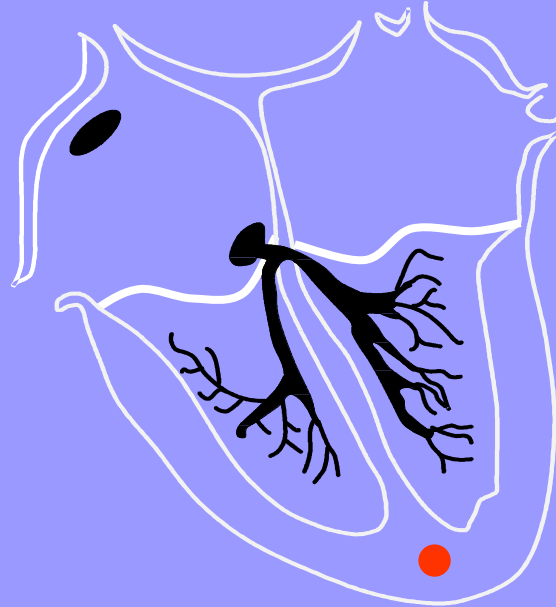
Jonctionnelle

Tachycardie liée à un circuit tournant dans le nœud auriculo-ventriculaire, descendant par le His au ventricule et remontant à l'oreillette par un Kent



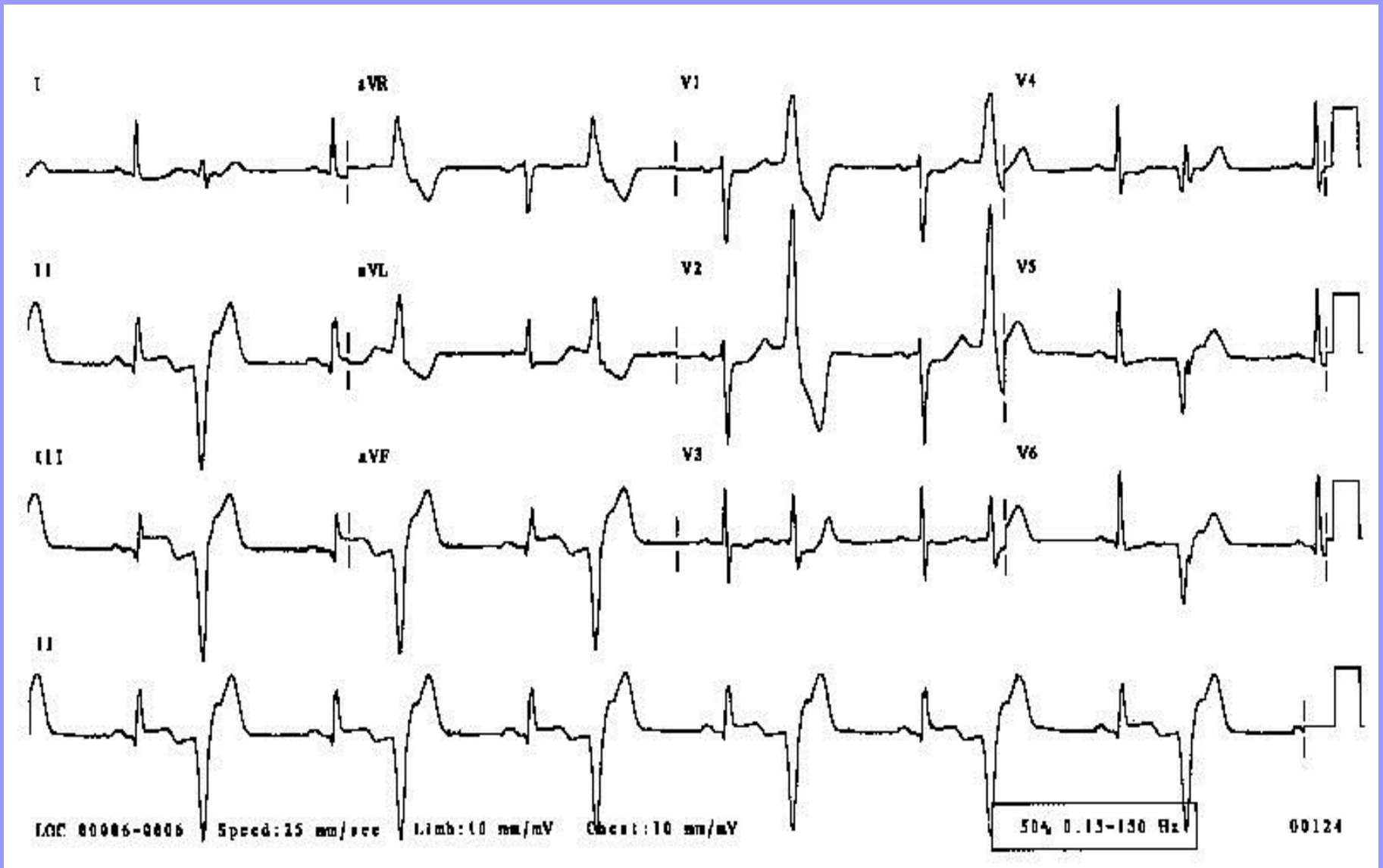
Tachycardies

Extrasystole ventriculaire



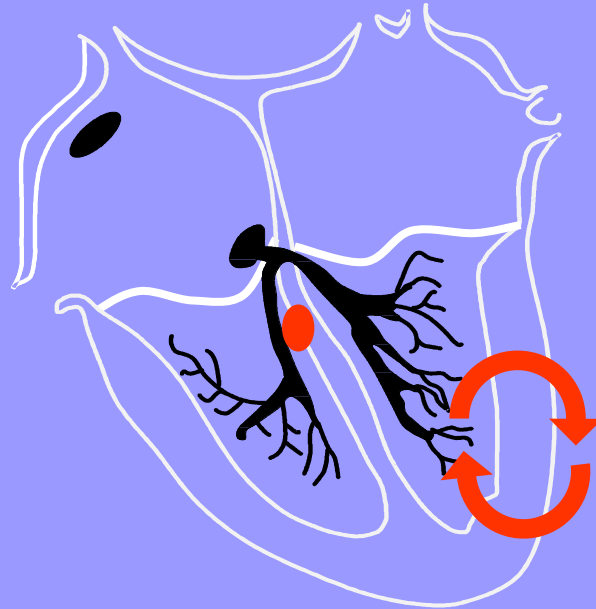
Contraction V prématurée (extrasystole) liée à un foyer d'activation anormal

Extrasystoles ventriculaires



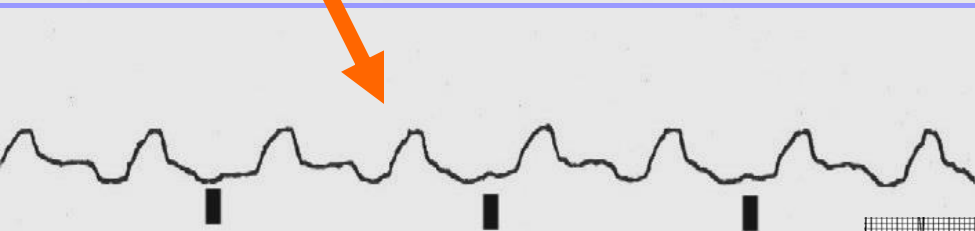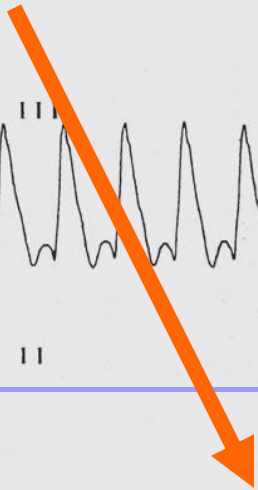
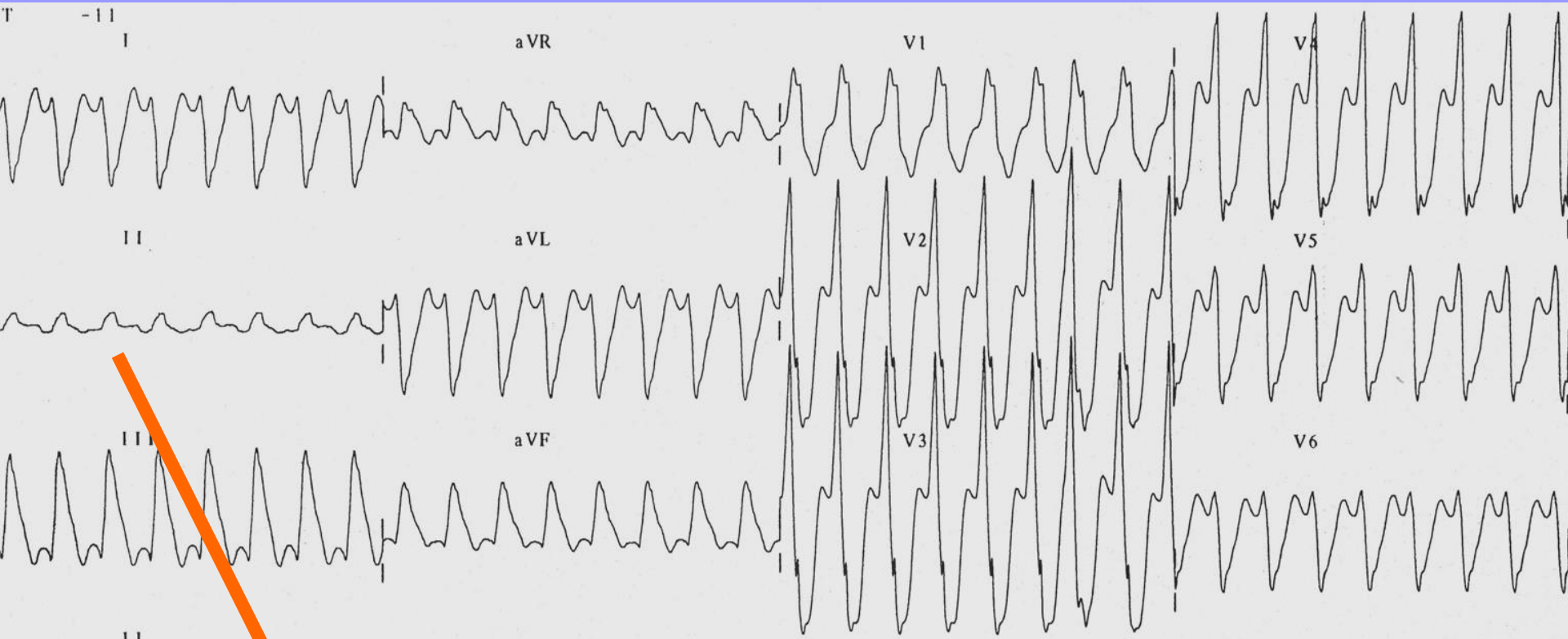
Tachycardies

tachycardie ventriculaire



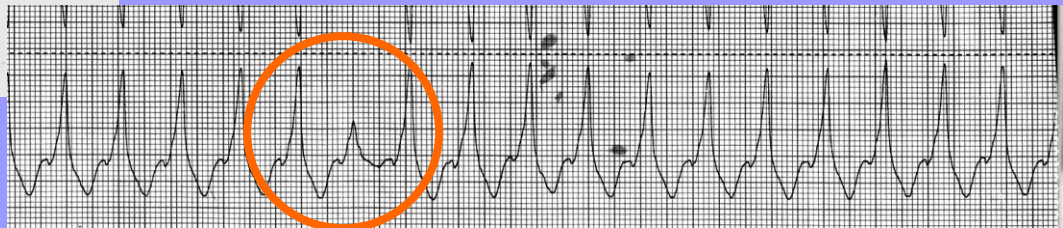
Circuit ou foyer d'activation anormal

Tachycardie Ventriculaire



Dissociation AV

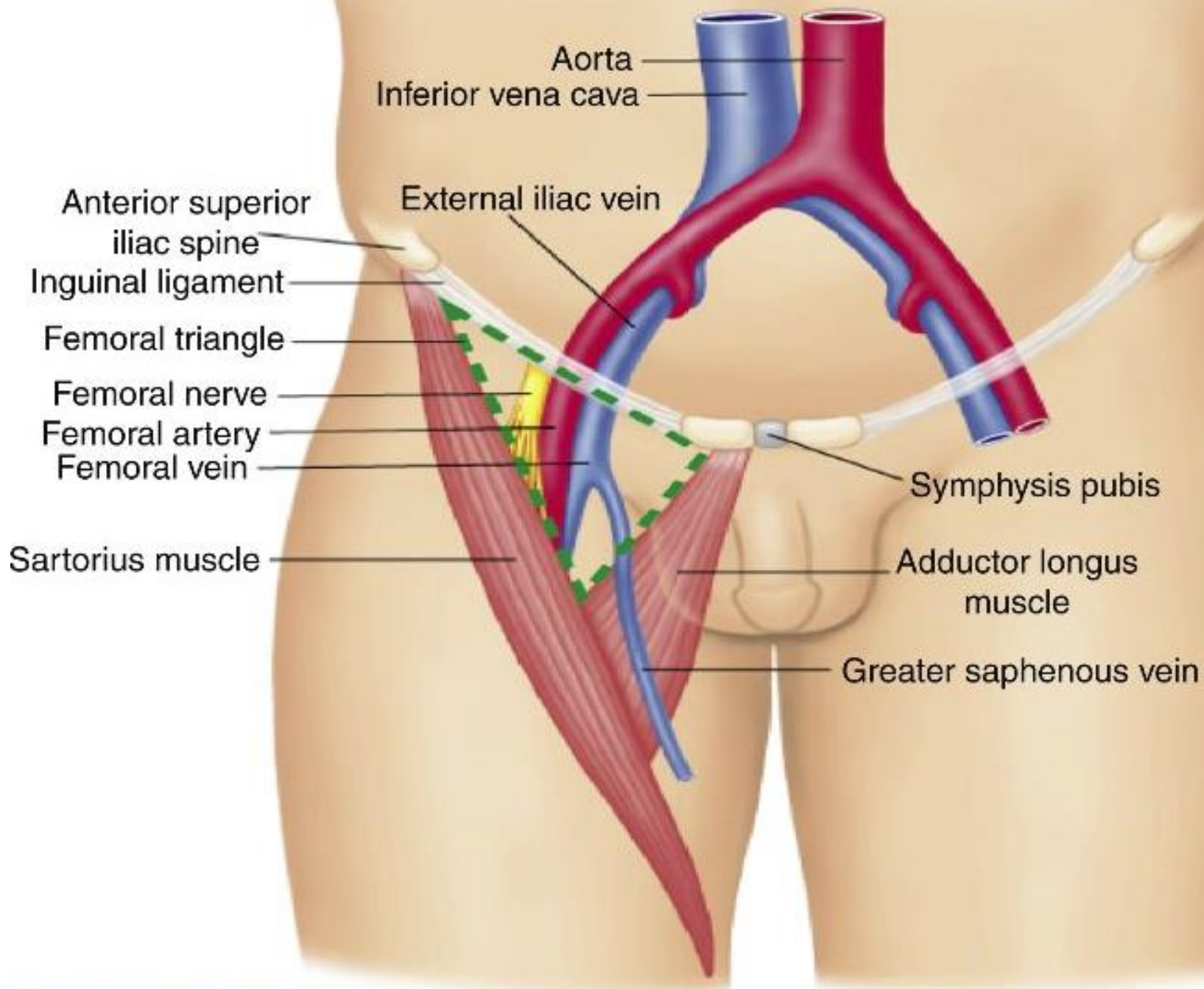
Captures & Fusions



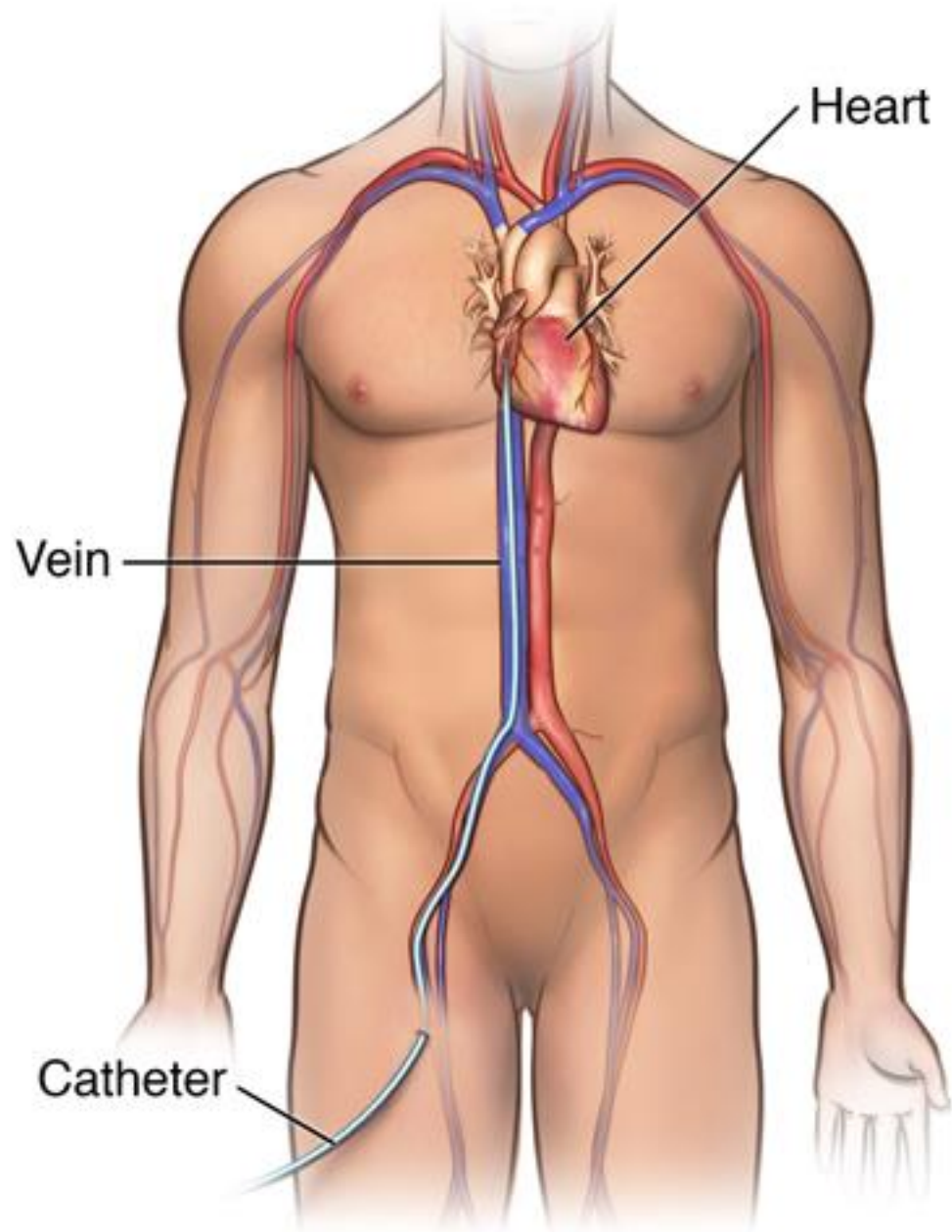
Procédure endocavitaire

Ponction veineuse

- Veine fémorale.
- En dedans de l'artère fémorale, en dedans du nerf fémoral
- Reçoit la grande veine saphène
- Se poursuit en veine illiaque puis VCI

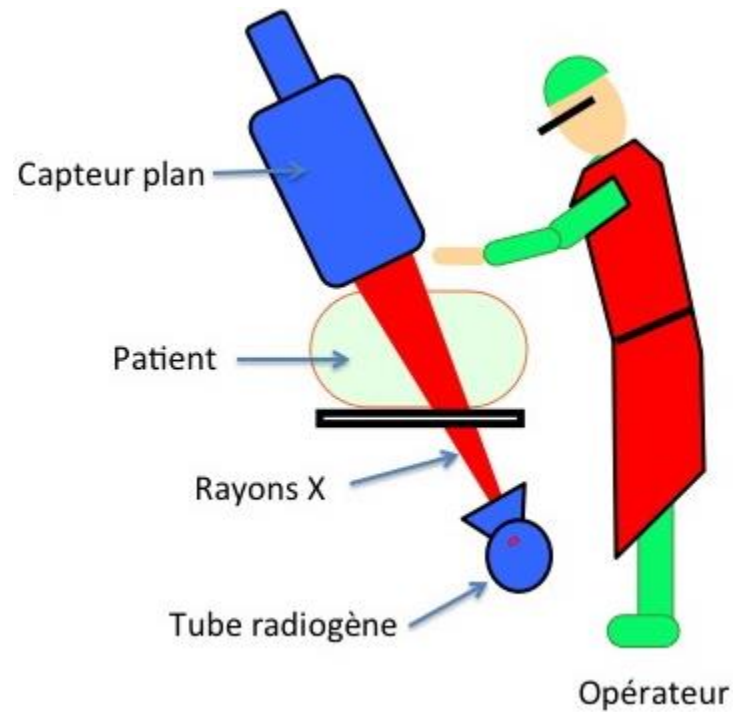
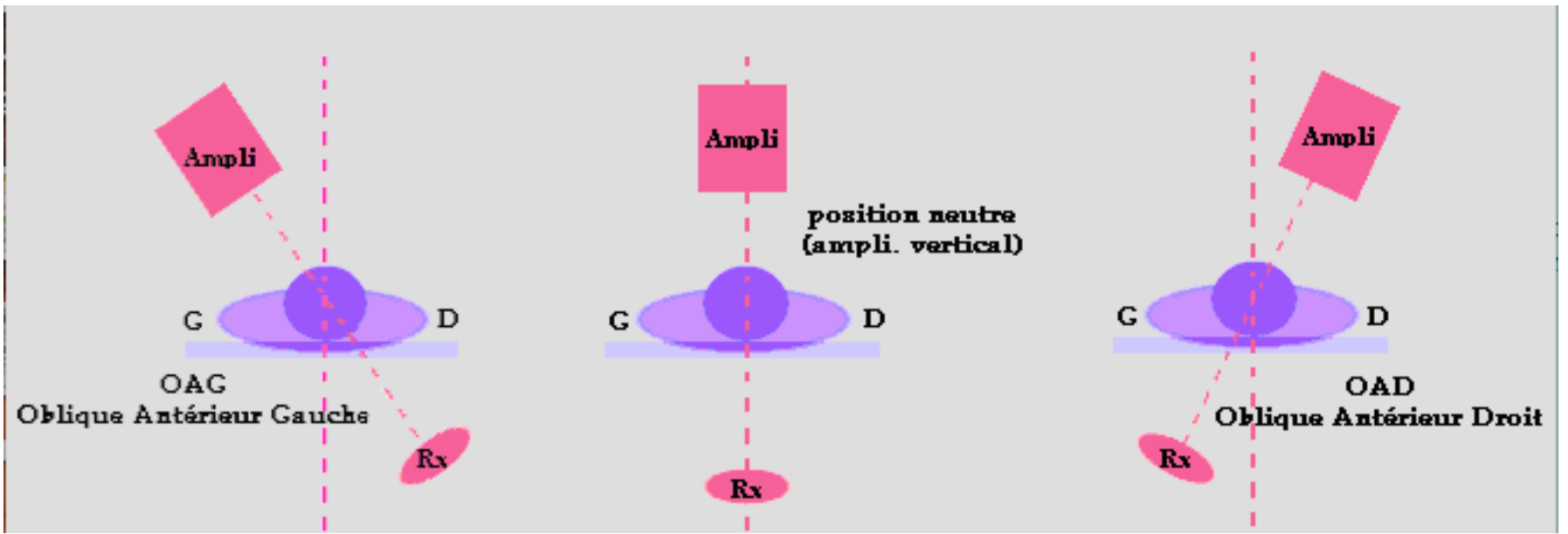


Catheter placement



La scopie

- Premier mode de repérage
- Vue 2D
- Plusieurs « angle de vue »



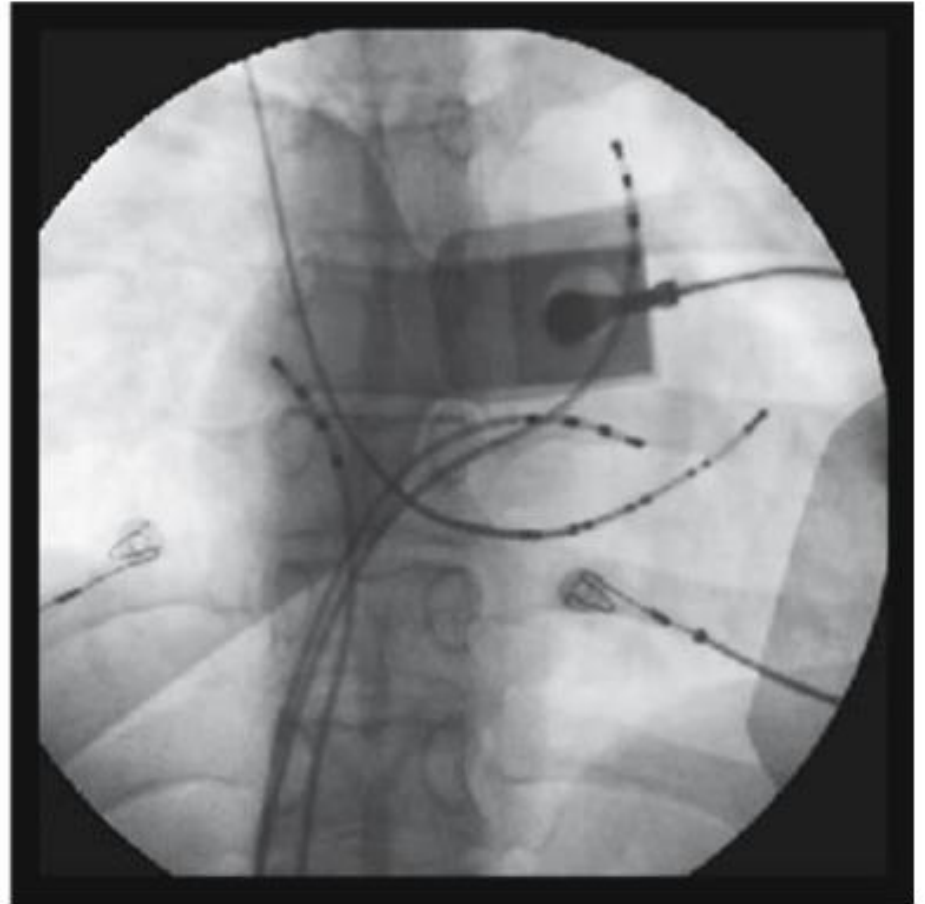
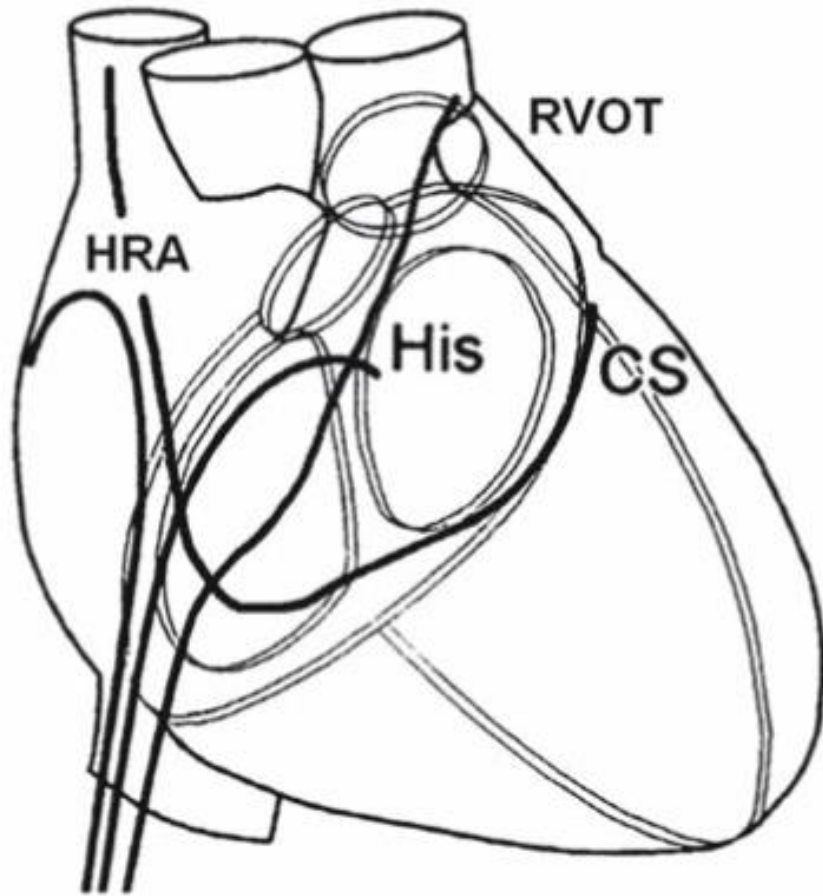


Figure 3.25 The posteroanterior (*PA*) view. In the diagram, one can see three diagnostic catheters inserted via the inferior vena cava. The high right atrium (*HRA*) is the catheter placed into the right atrium, *His* is the catheter in the His region (*His*), the right ventricular outflow tract (*RVOT*) is placed in the *RVOT*. The coronary sinus (*CS*) is the catheter placed into the *CS*, inserted via a superior approach. In the fluoroscopic image the four catheters are shown in their respective positions

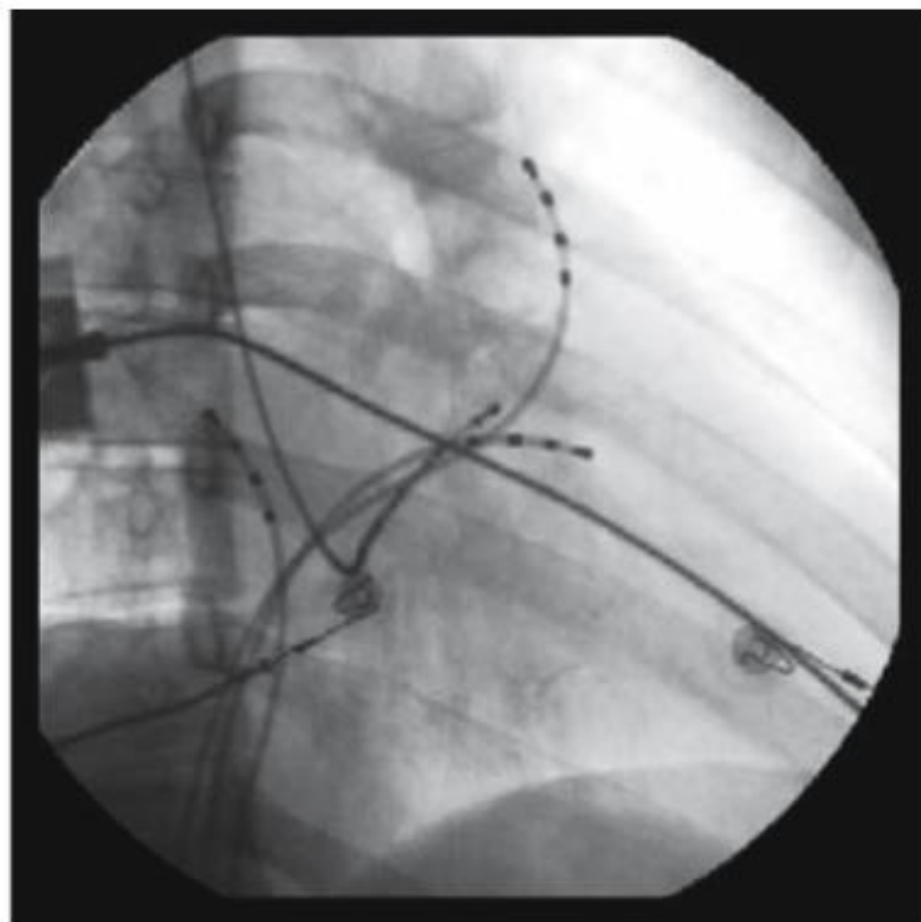
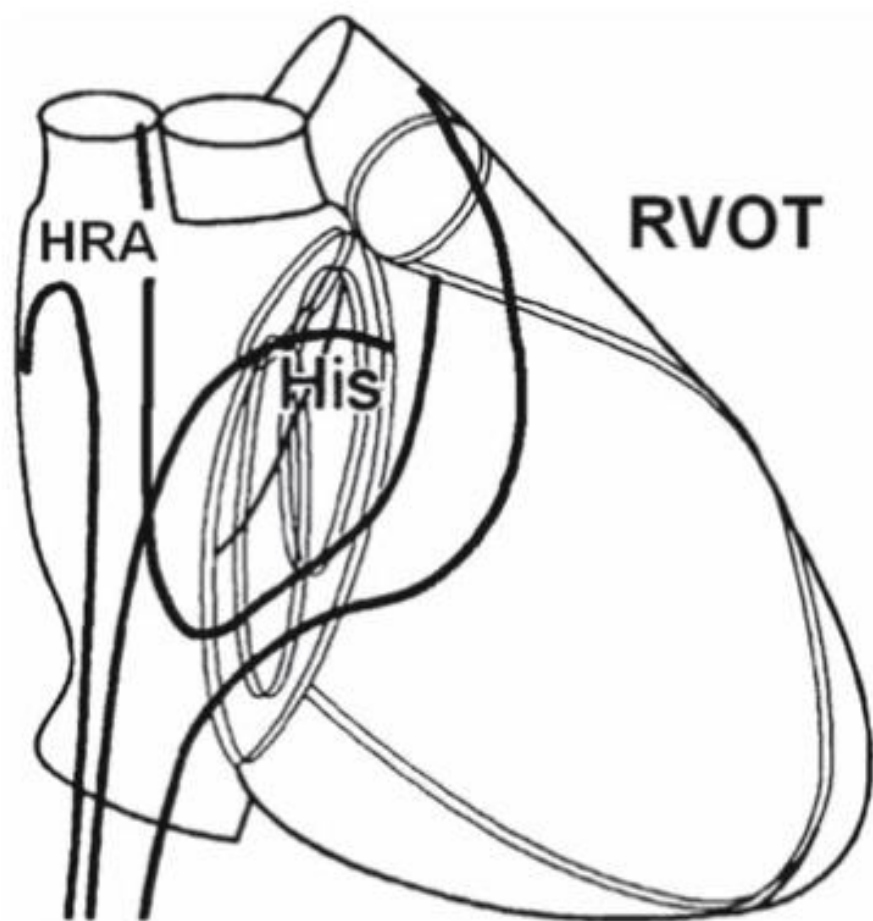


Figure 3.26 The right anterior oblique (RAO) view. In the diagram as well as in the fluoroscopic image, the four catheters are in their respective positions

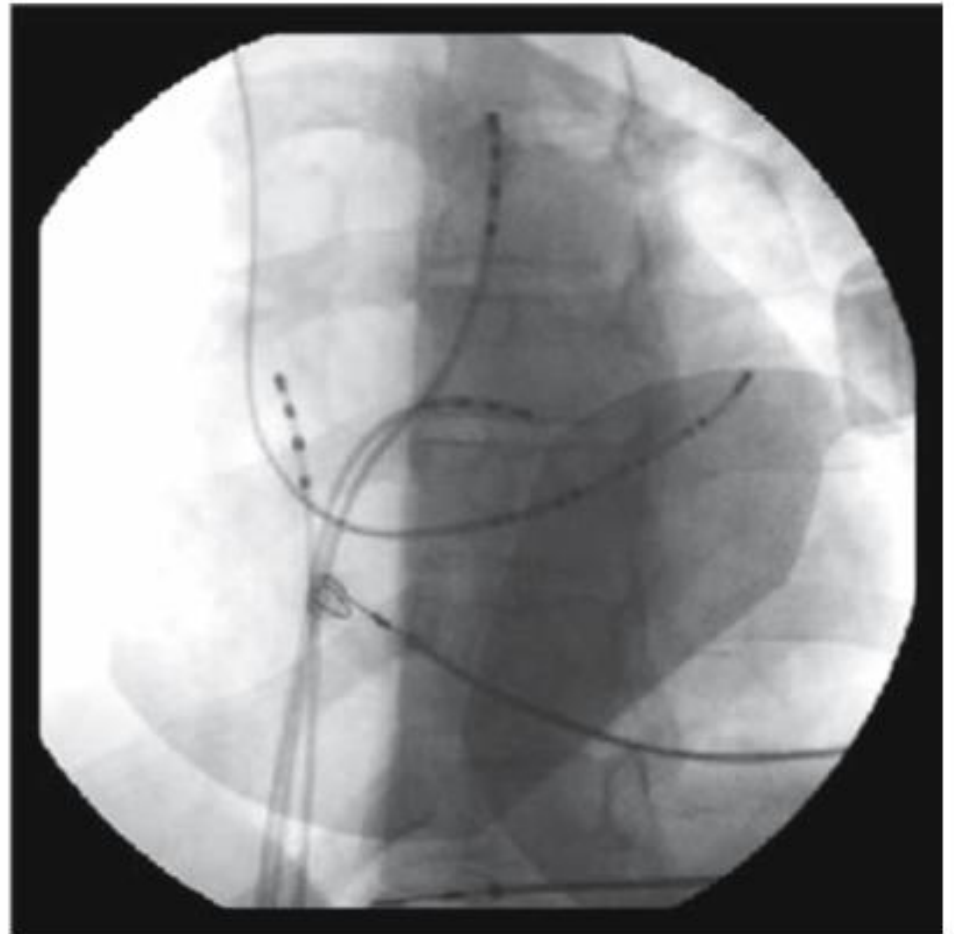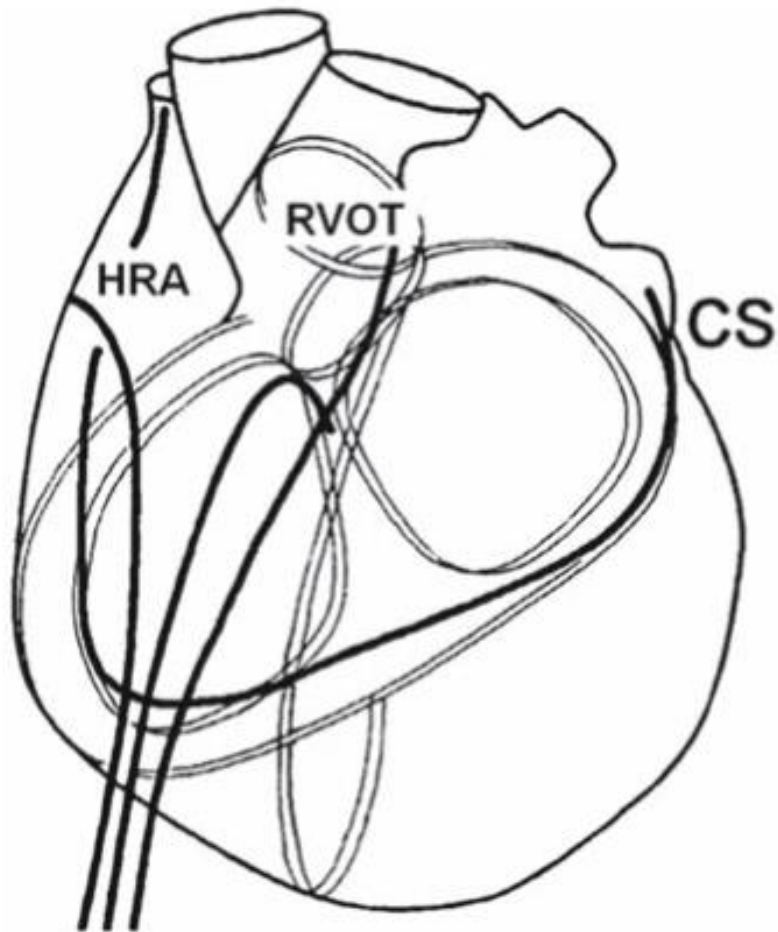
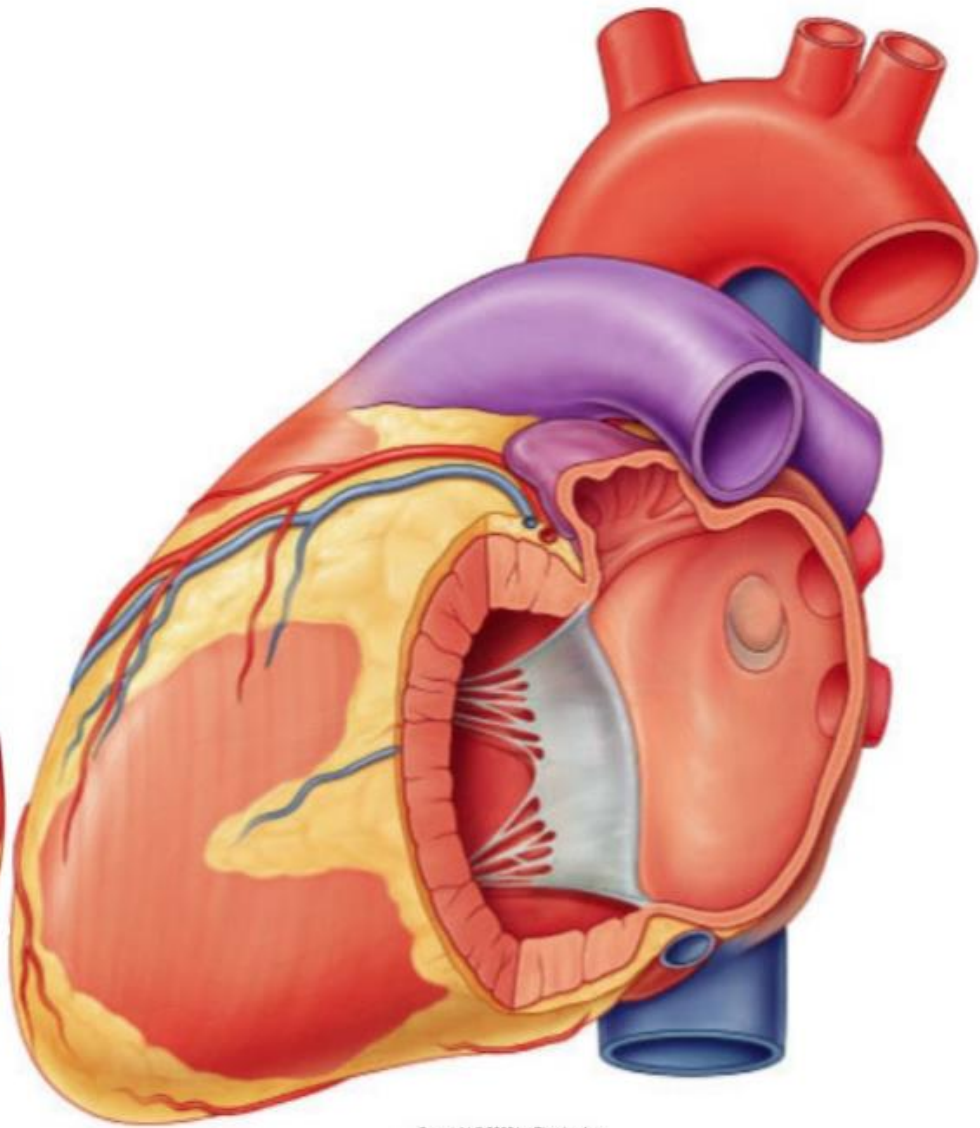
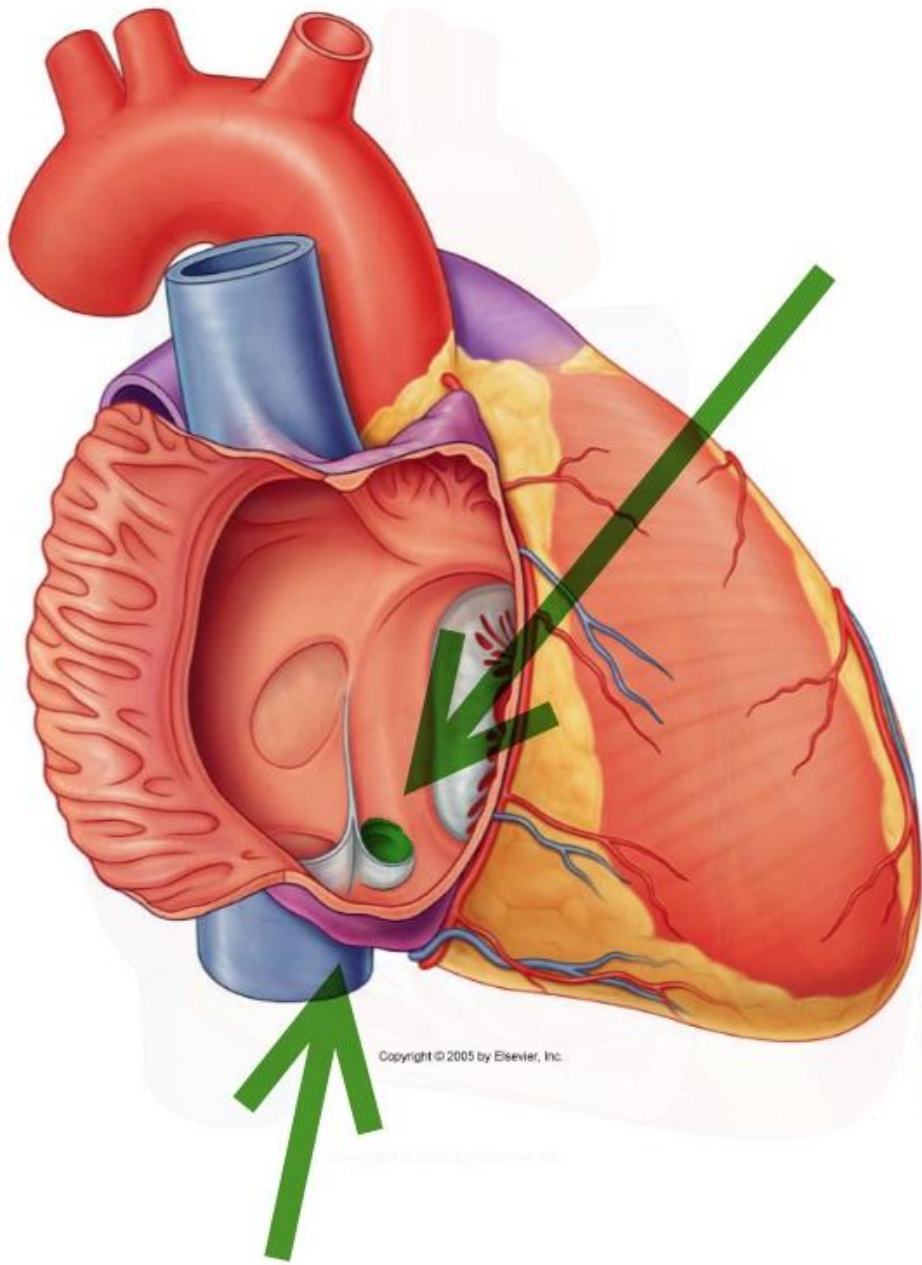


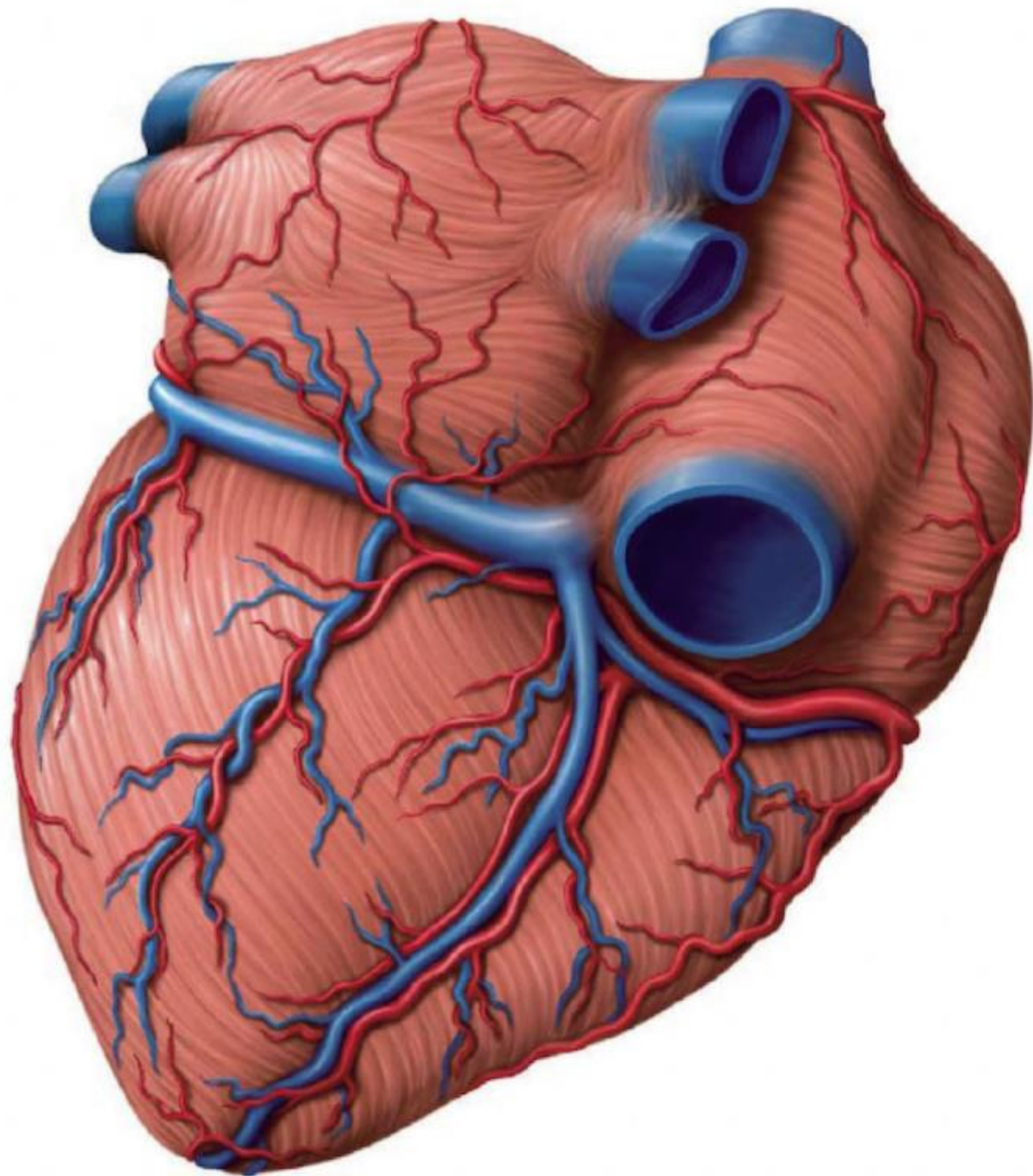
Figure 3.27 The left anterior oblique (LAO) view. In the diagram as well as in the fluoroscopic image, the four catheters are seen in their respective positions

Le sinus coronaire

- Tronc veineux
- Sillon atrio-ventriculaire gauche
- S'abouche dans l'oreillette droite D+/- 1 cm
- Reçoit la grande veine cardiaque
- Valve de thébesius

- Repère 1
- Resynchronisation





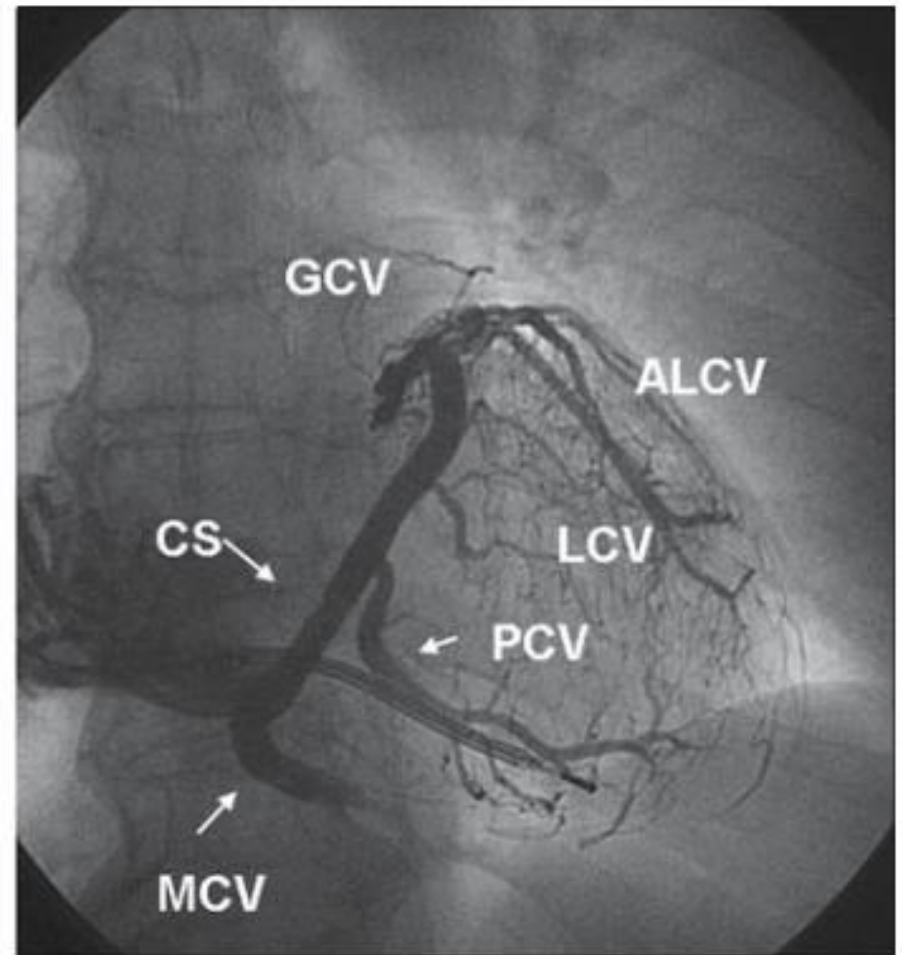
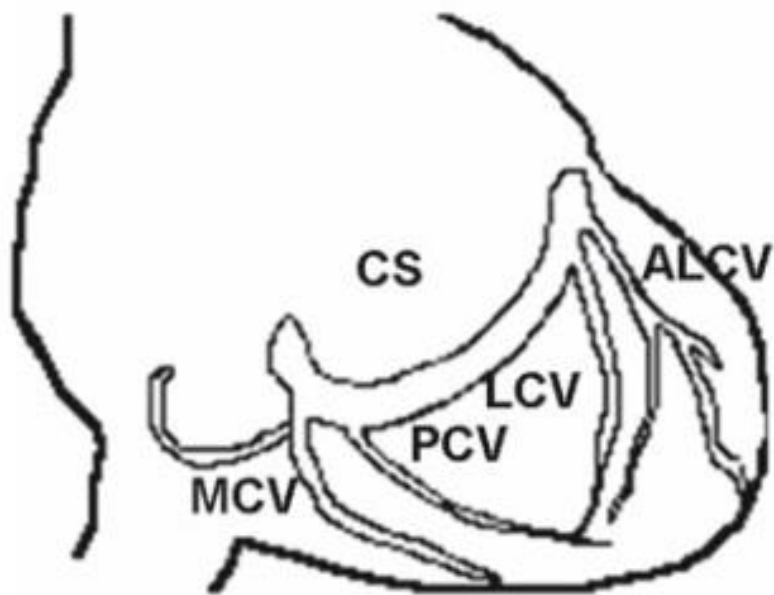


Figure 10.1 The posteroanterior (PA) view of the venous system of the heart. The coronary sinus (CS) and its branches are represented. *MCV*: middle cardiac vein. *PCV* posterior cardiac vein, *LCV* lateral cardiac vein, *GCV* great cardiac vein, *ALCV* anterolateral cardiac vein

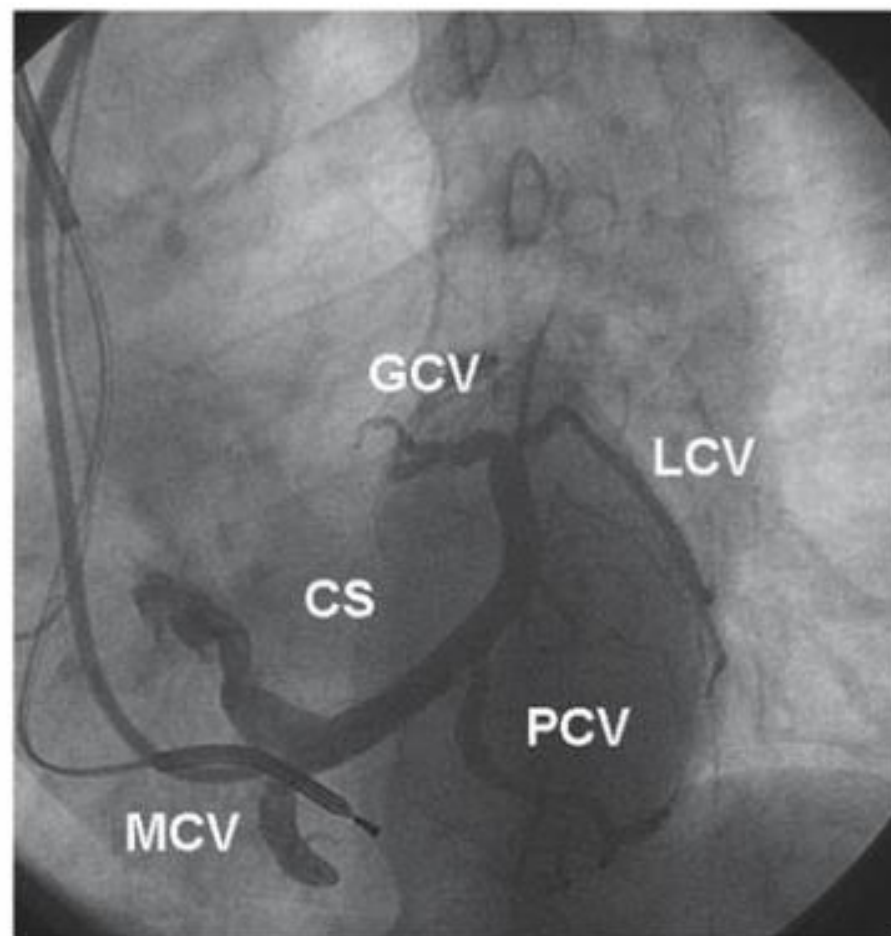
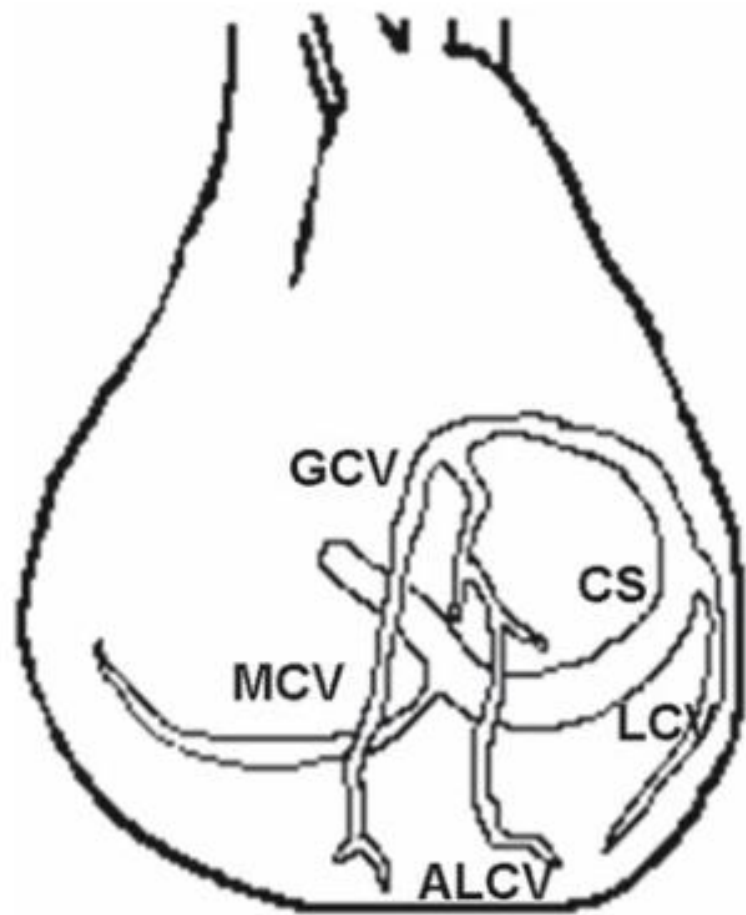


Figure 10.2 The left anterior oblique (LAO) view of the coronary sinus (CS) and its branches. This projection helps a better view of the posterior and lateral veins

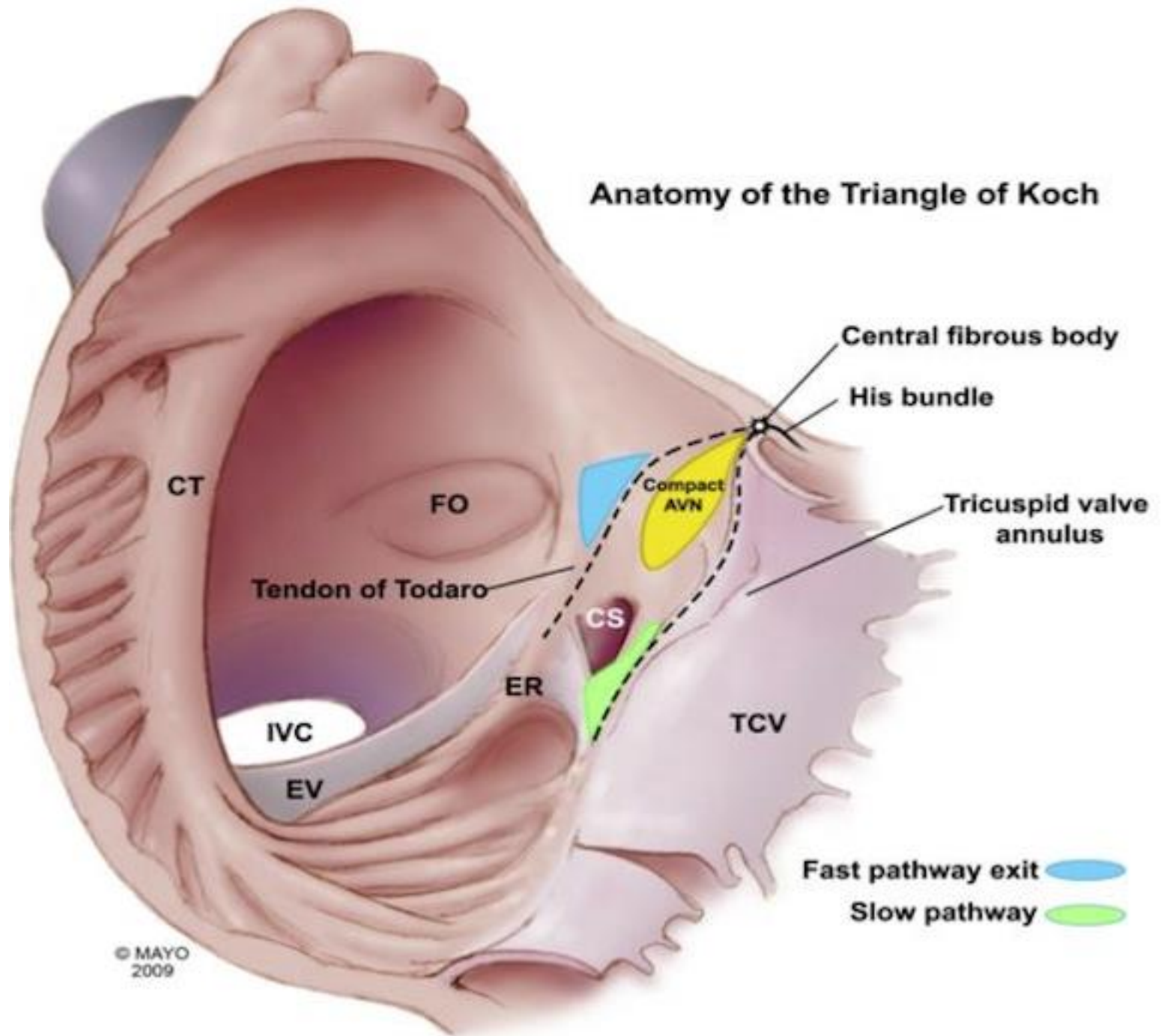
Le triangle de Koch

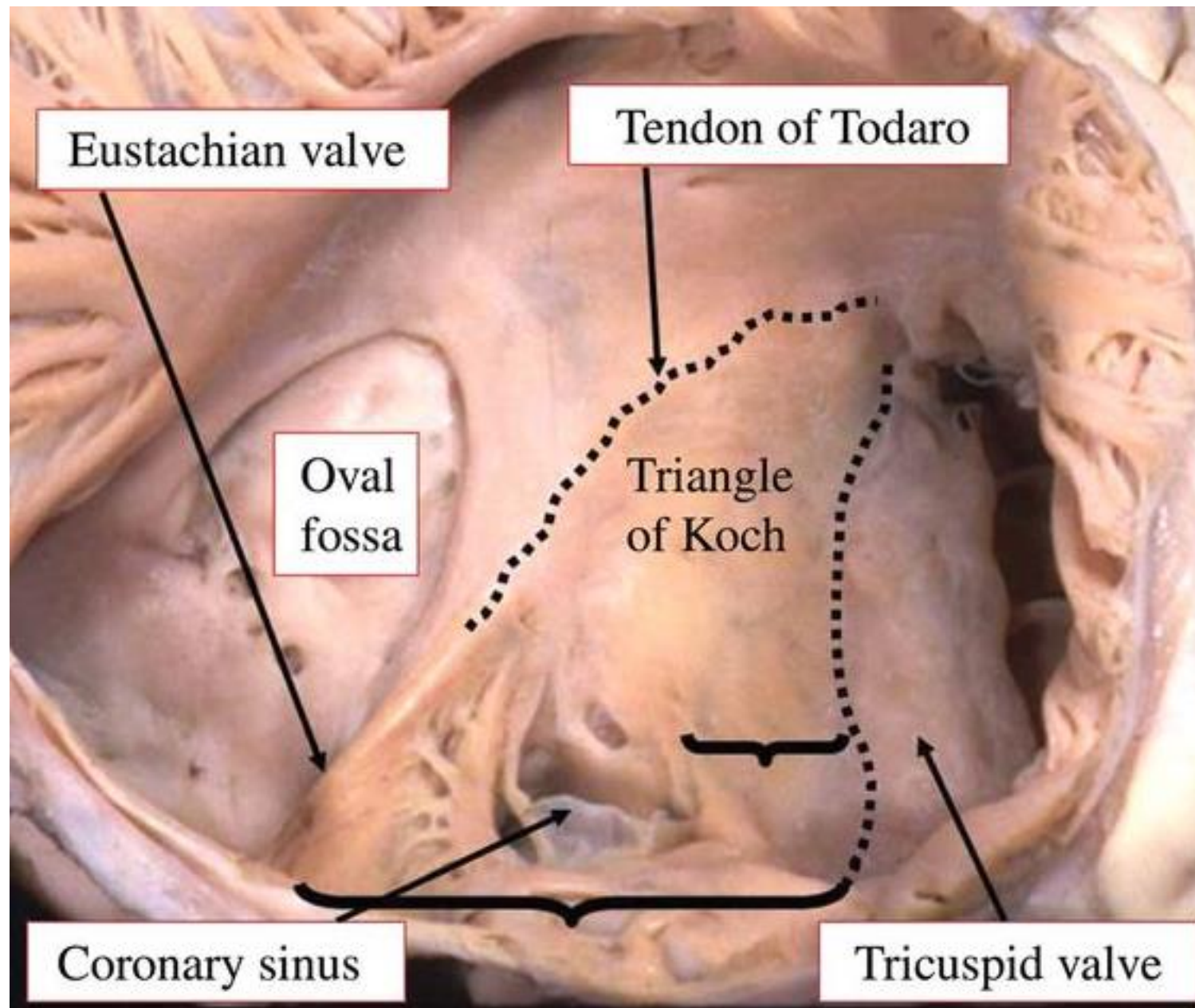
- Feuillet septal de la tricuspide en avant
- Tendon de Todaro en arrière (valve eustachi)
- Sinus coronaire en bas

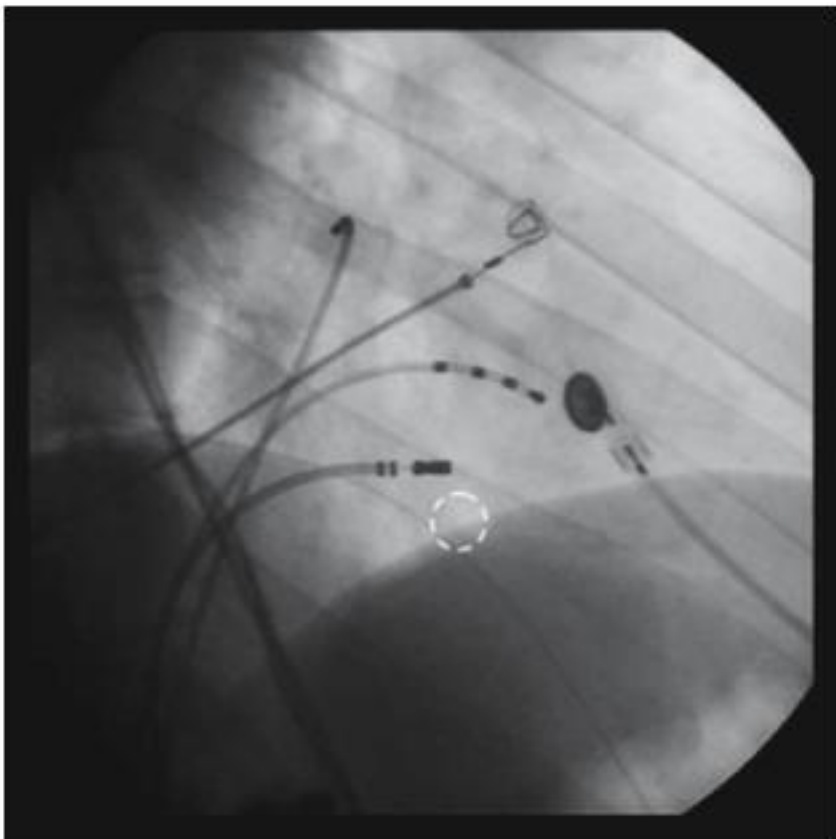
- His au sommet

- Ablation réentrée intranodale

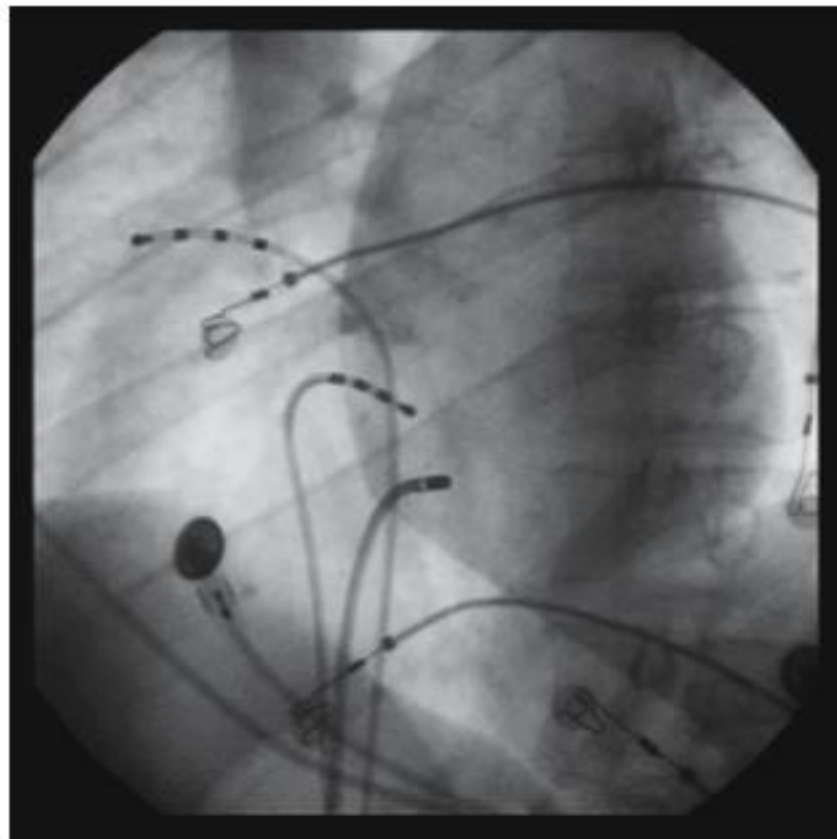
Anatomy of the Triangle of Koch







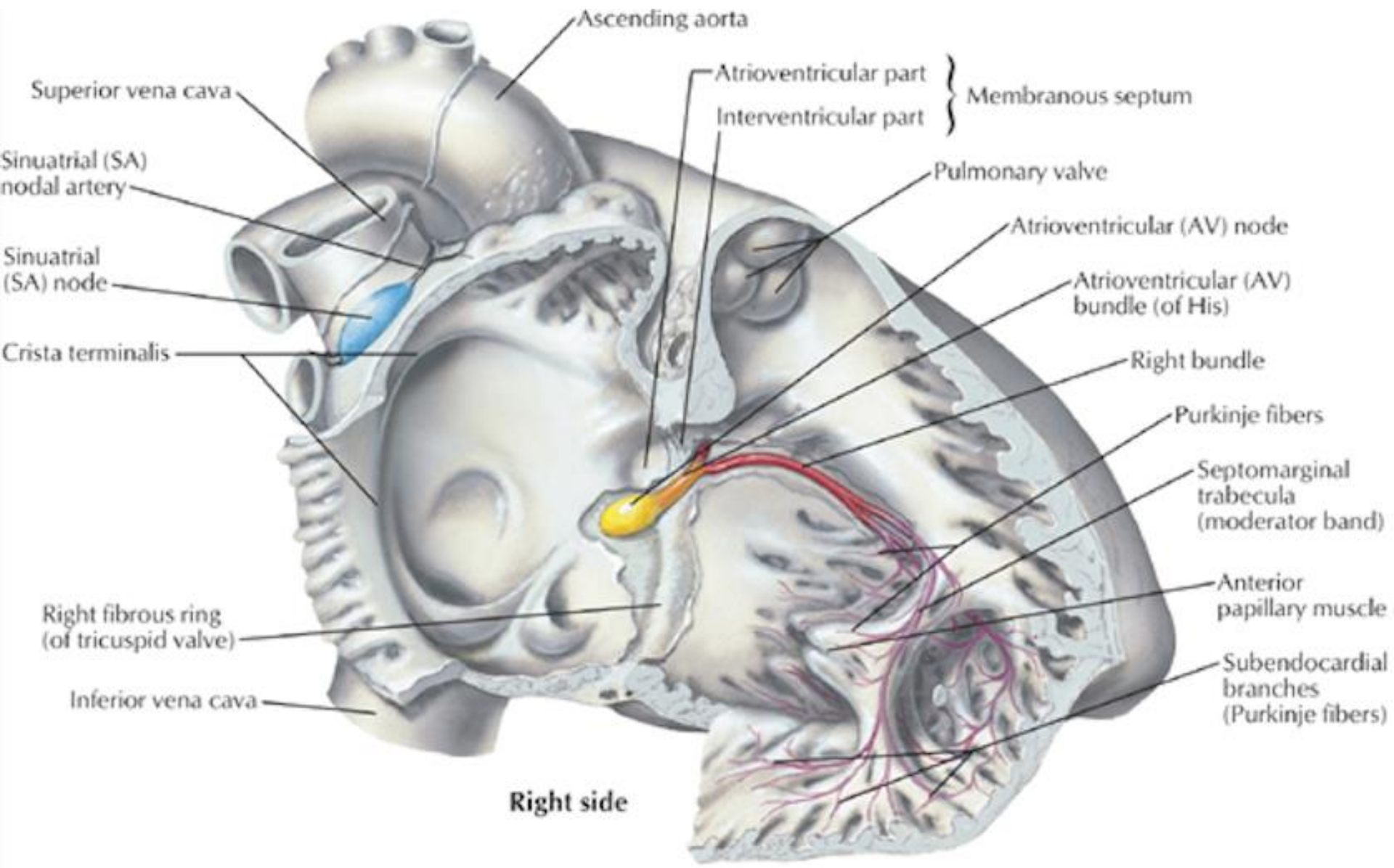
OAD

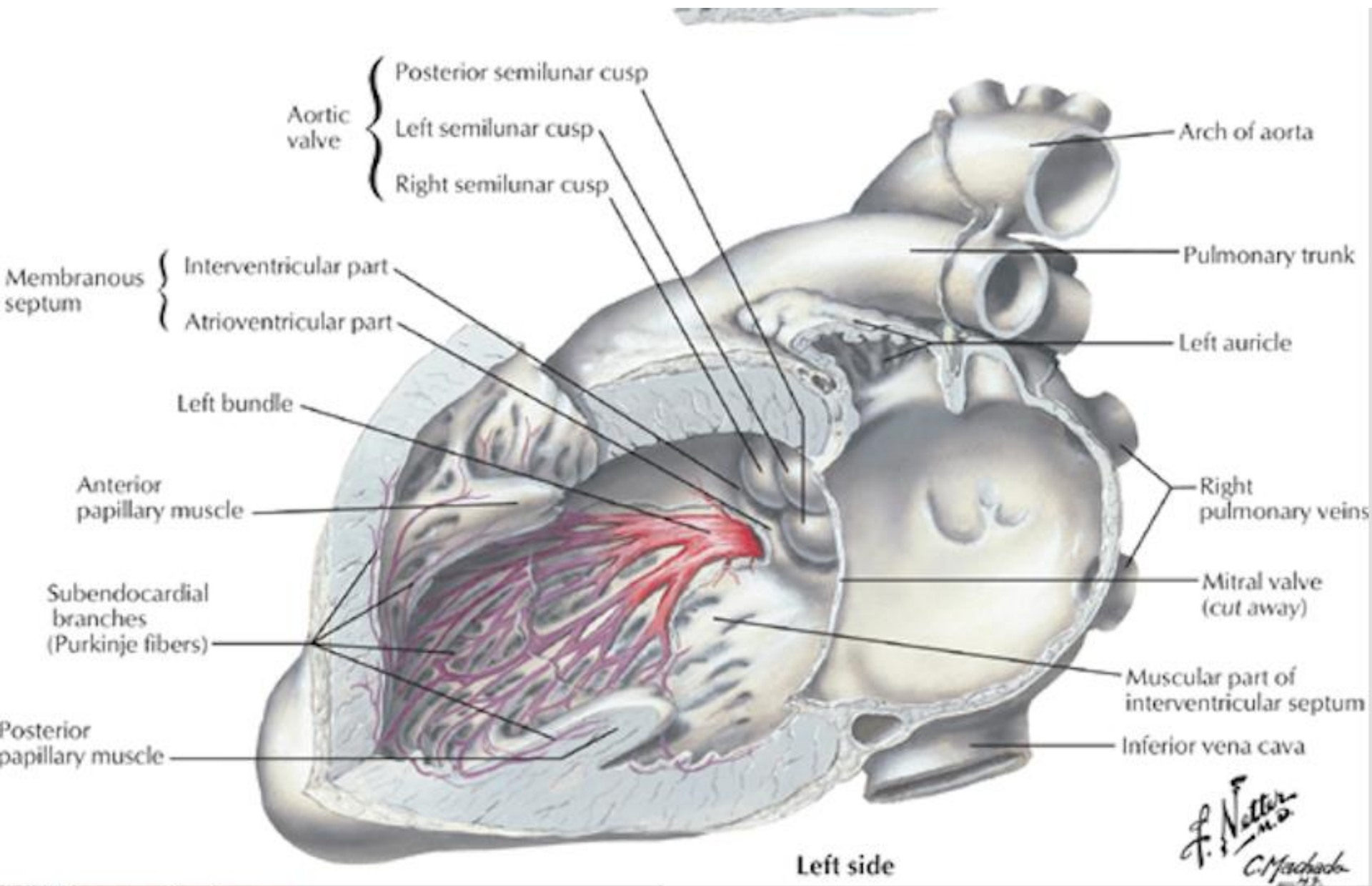


OAG

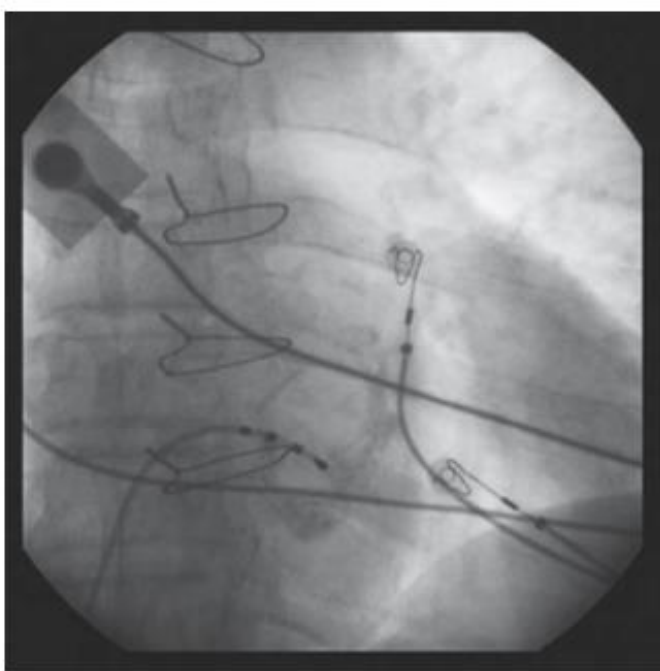
NAV, His, Branches et Purkinje

- NAV : Partie postéro inférieure du septum inter atrial
- Nœud compact 3 mm. Centre du triangle de Koch
- His : dans le septum interventriculaire, donc profond. Tronc séparé en 2 branches puis réseau de Purkinje, endocardique. Pas de différence visuelle

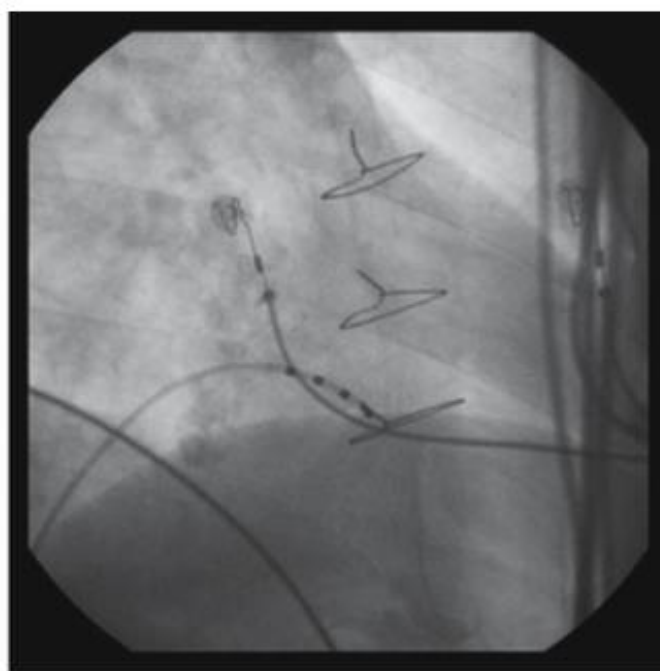




PA



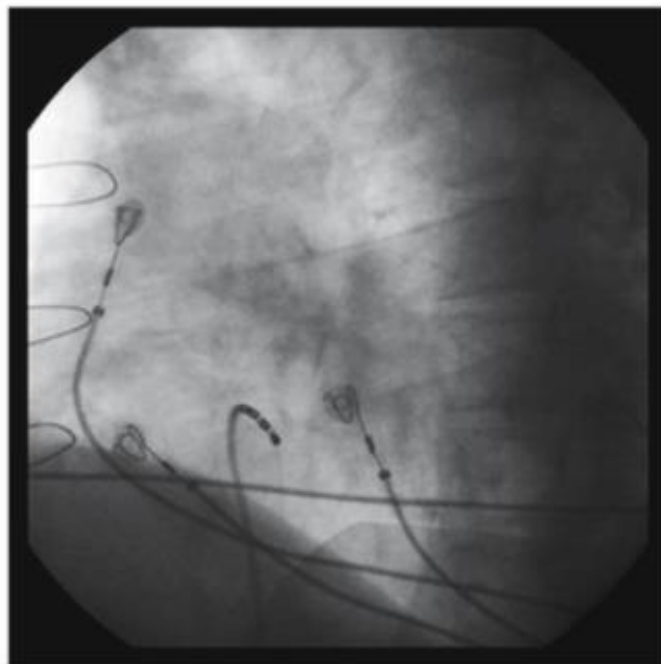
a



b

OAD

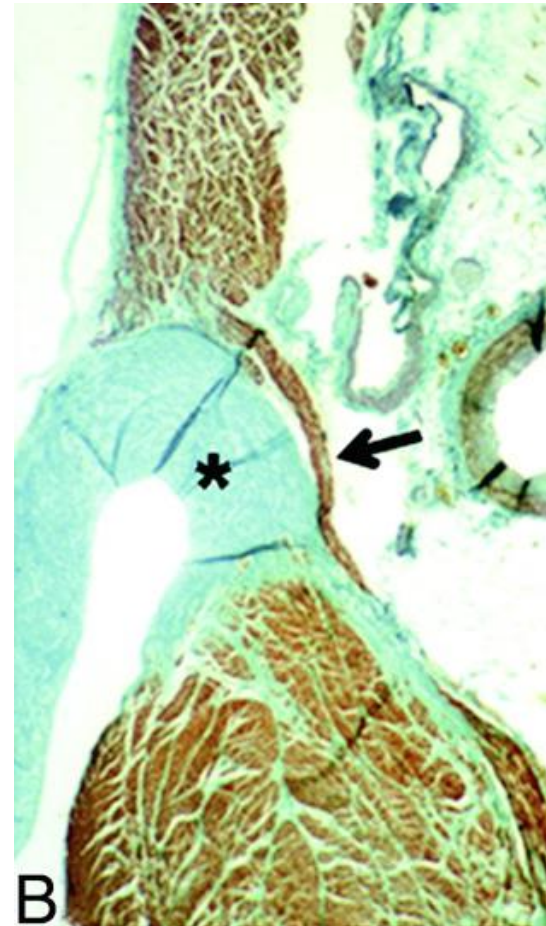
OAG



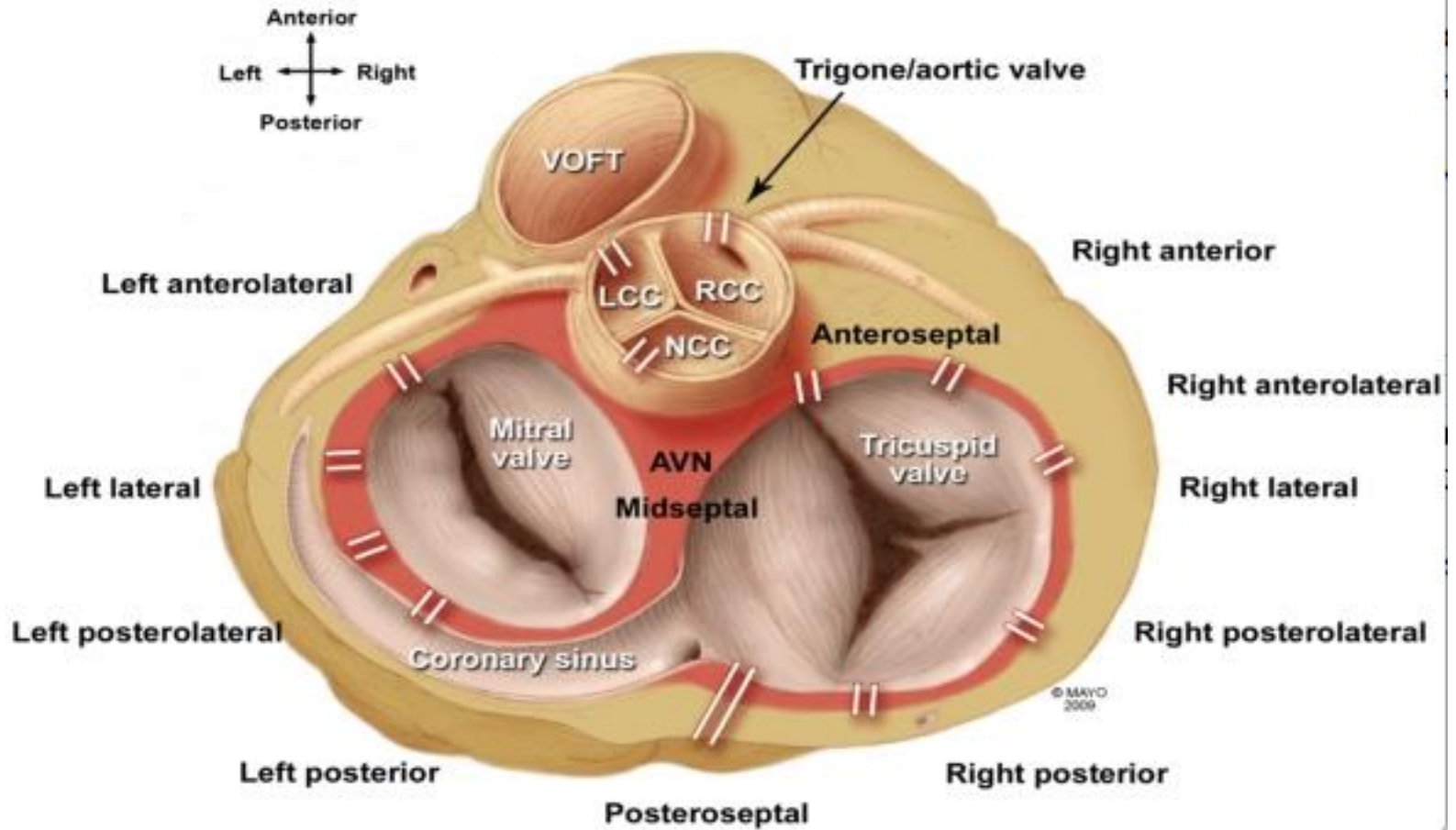
c

Voie accessoire atrioventriculaire

- Voie de conduction accessoire entre oreillette et ventricule
- Rupture de « l'isolation » créée par l'anneau



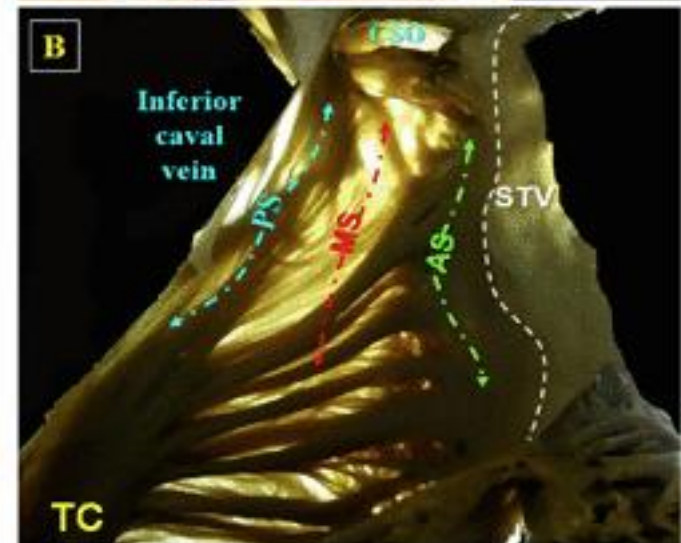
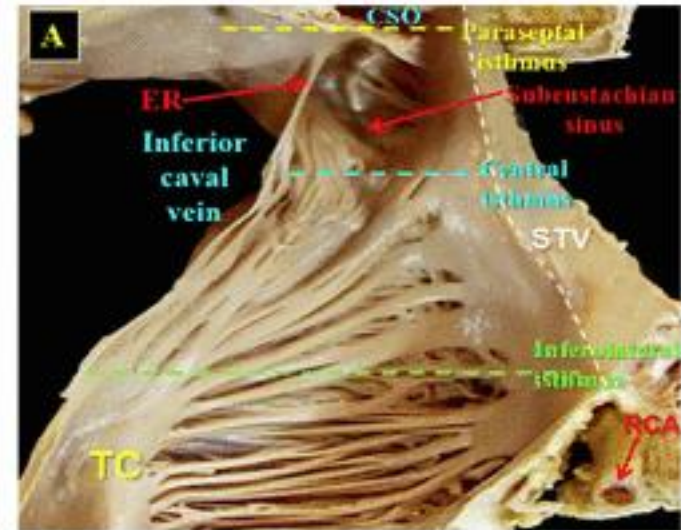
Accessory Pathway Locations



L'isthme cavotricuspidien ICT

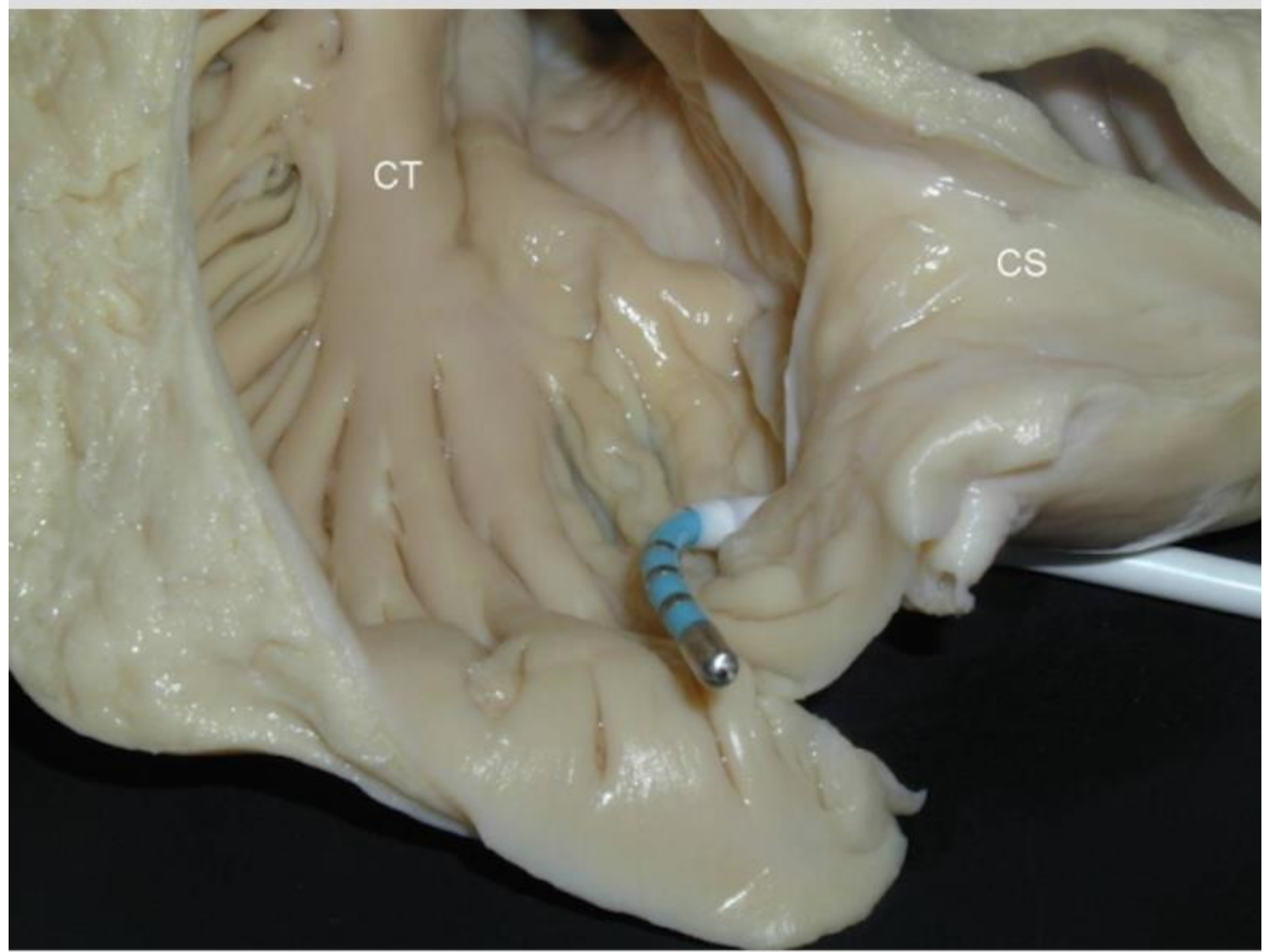
Entre :

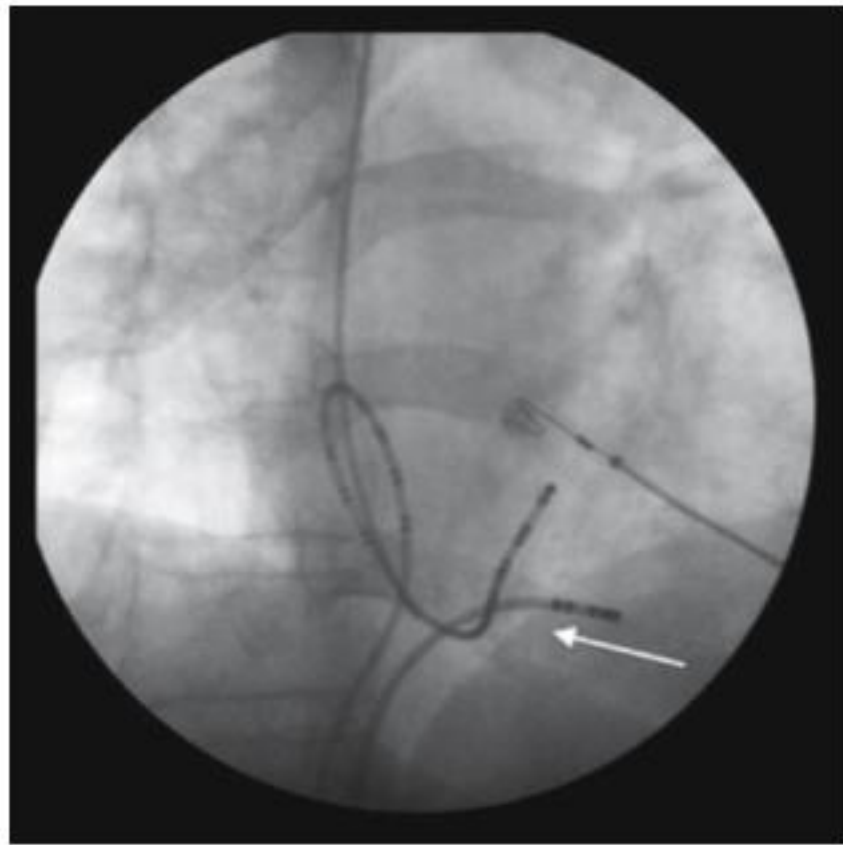
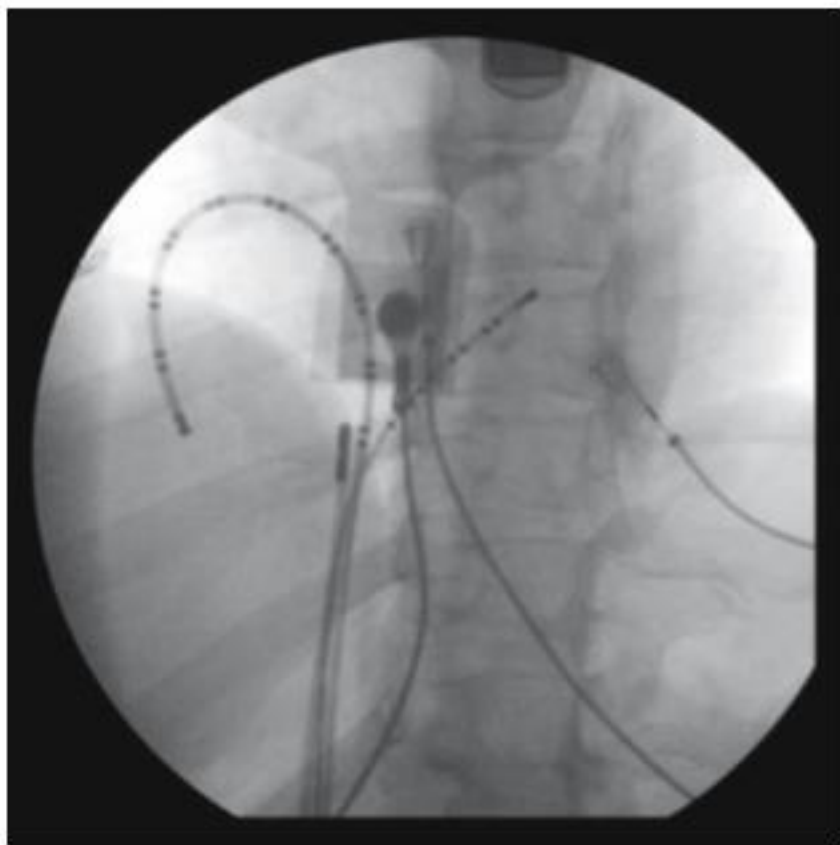
- la veine cave inférieure (en arrière)
- La valve tricuspide, son feuillet septal en avant



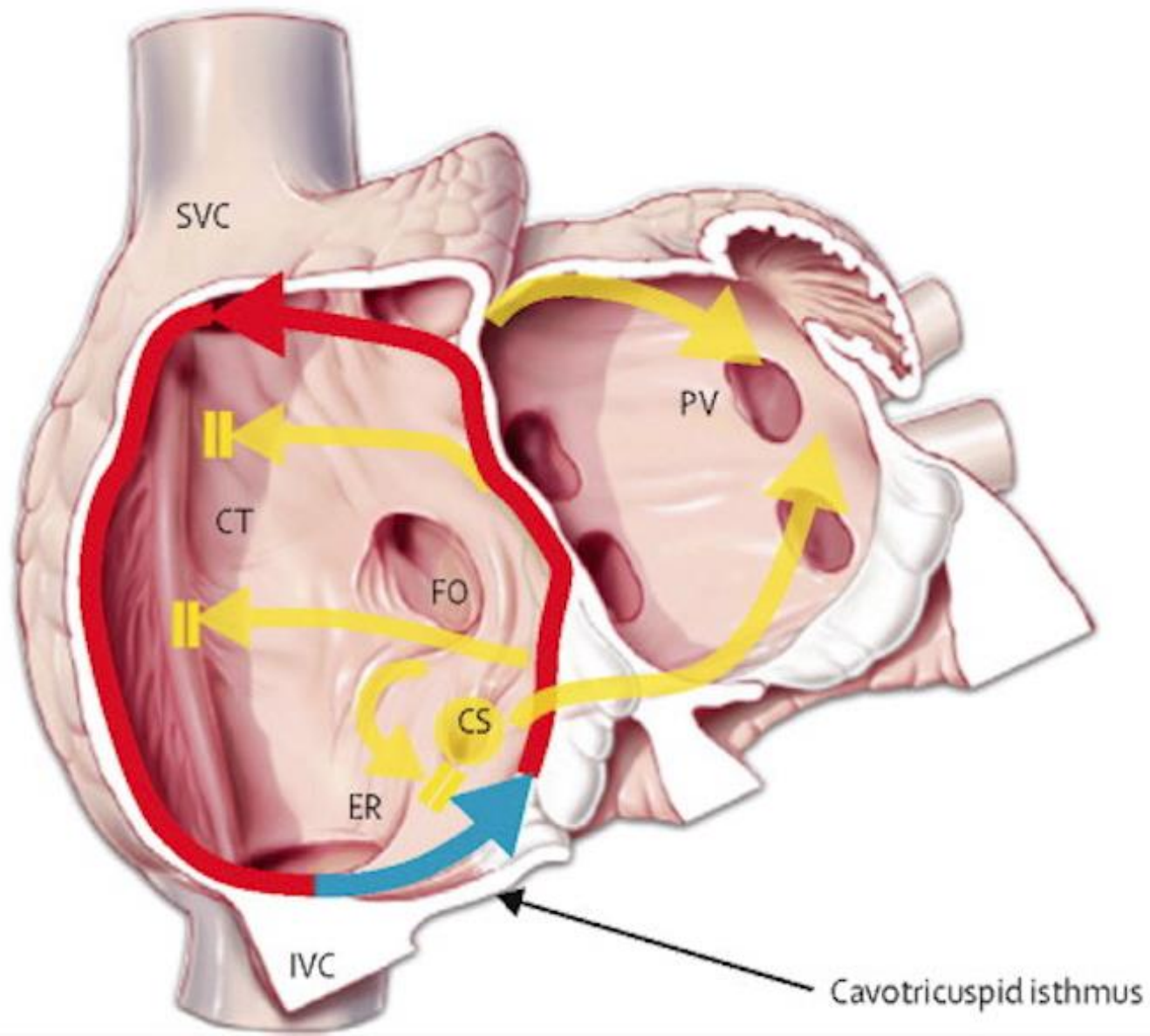
CT

CS

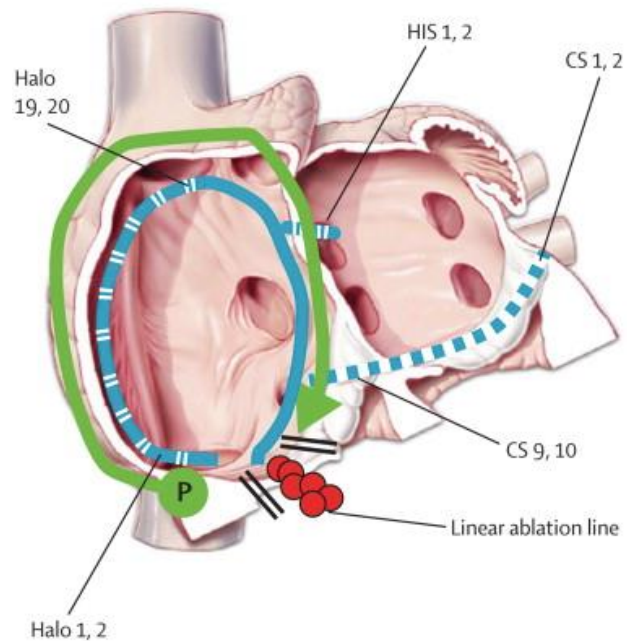




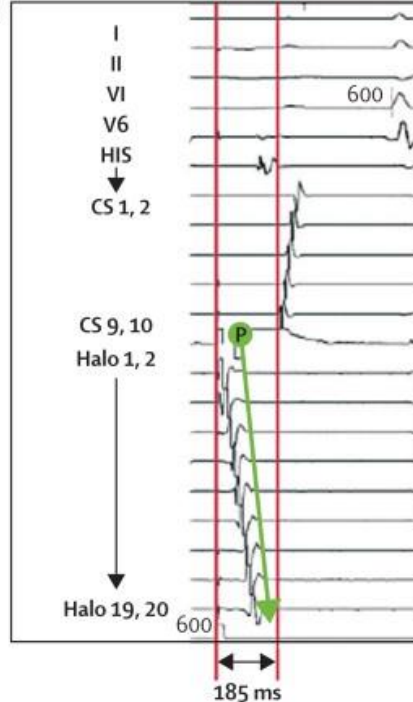
A Typical right atrial flutter



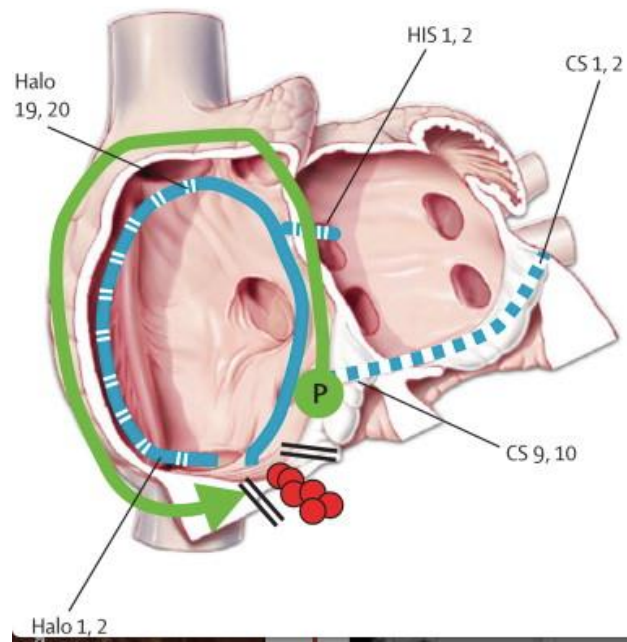
A Pacing lateral to ablation line



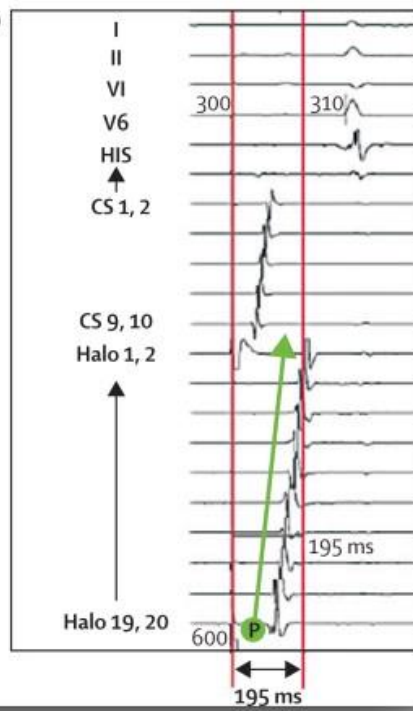
B



C Pacing septal to ablation line

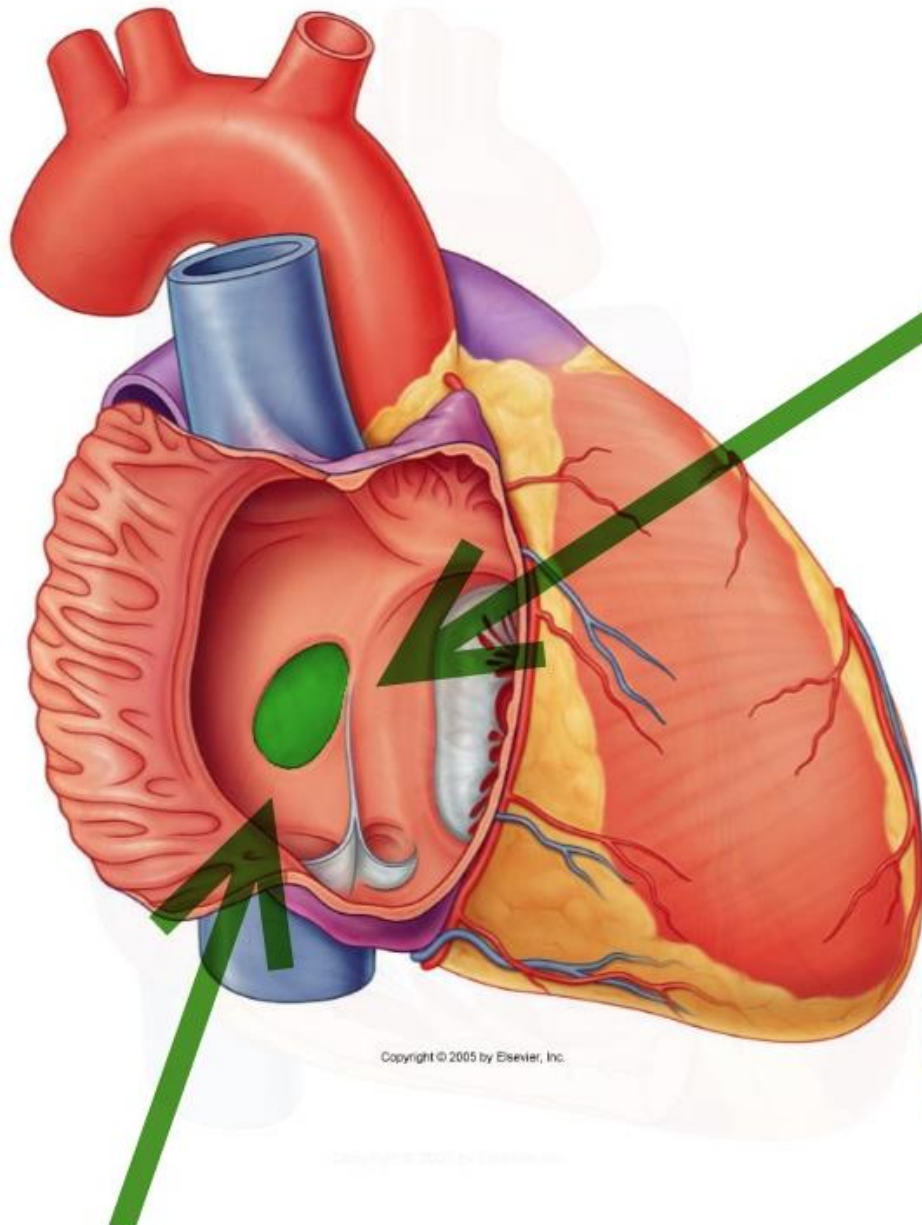


D

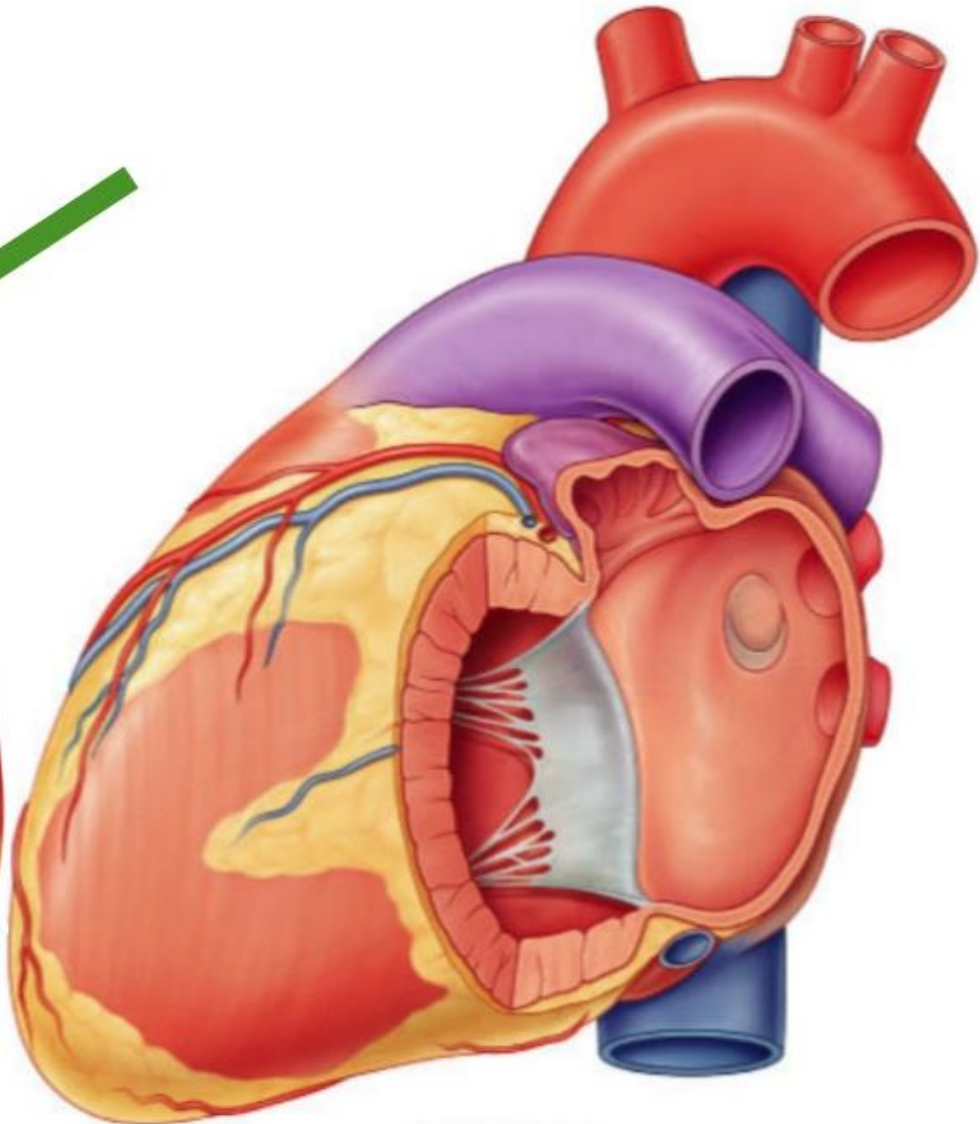


La fosse ovale

- Vestige du Foramen Ovale (reste perméable chez 20% des gens)
- Septum interatrial
- Lieu de passage pour l'abord transeptal de l'OG



Copyright © 2005 by Elsevier, Inc.



Copyright © 2005 by Elsevier, Inc.

Le péricarde

- « Saccoche » entourant le cœur
- 2 feuillet, l'un pariétal, l'autre viscéral

Heart

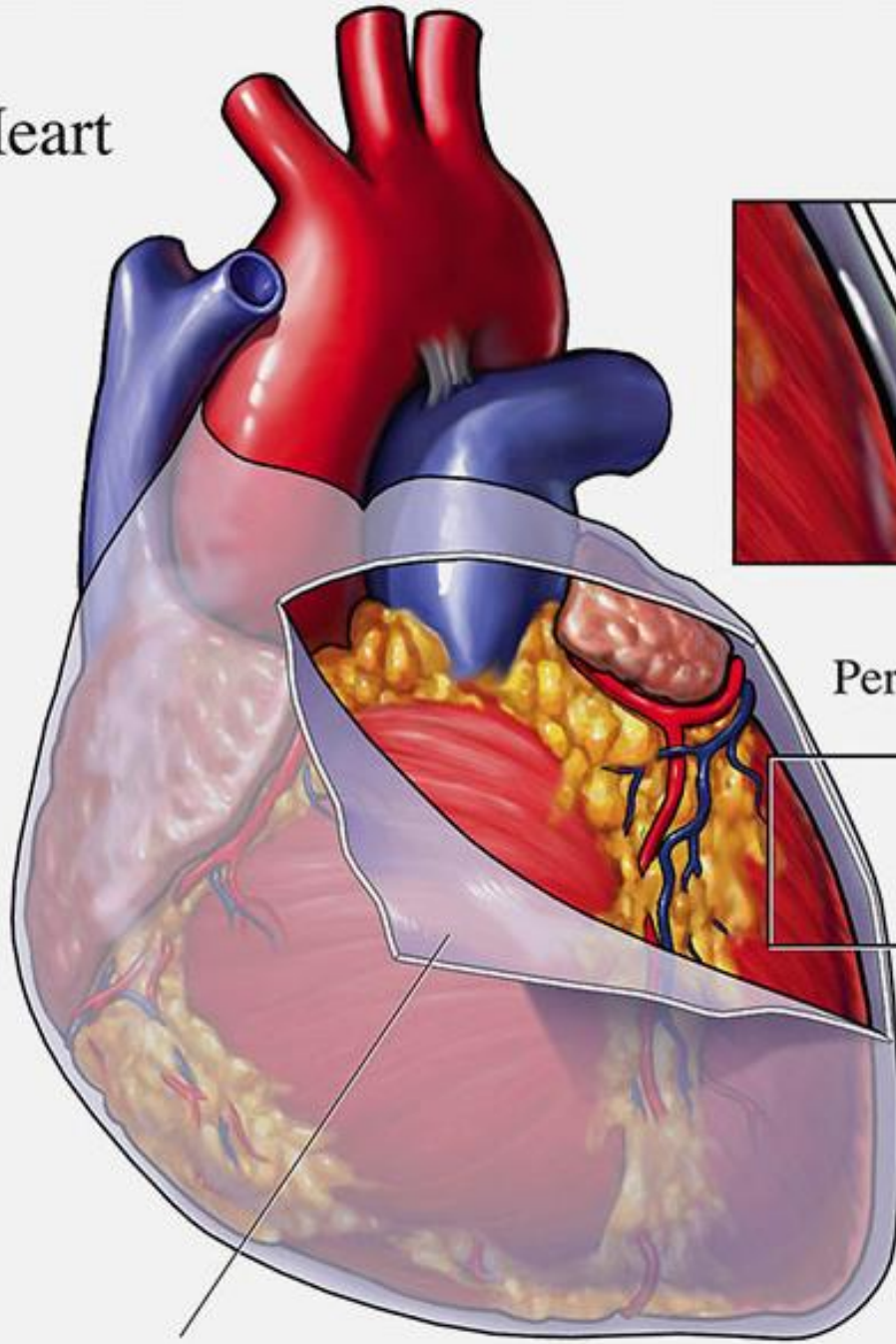
Pericardium



Pericardial fluid

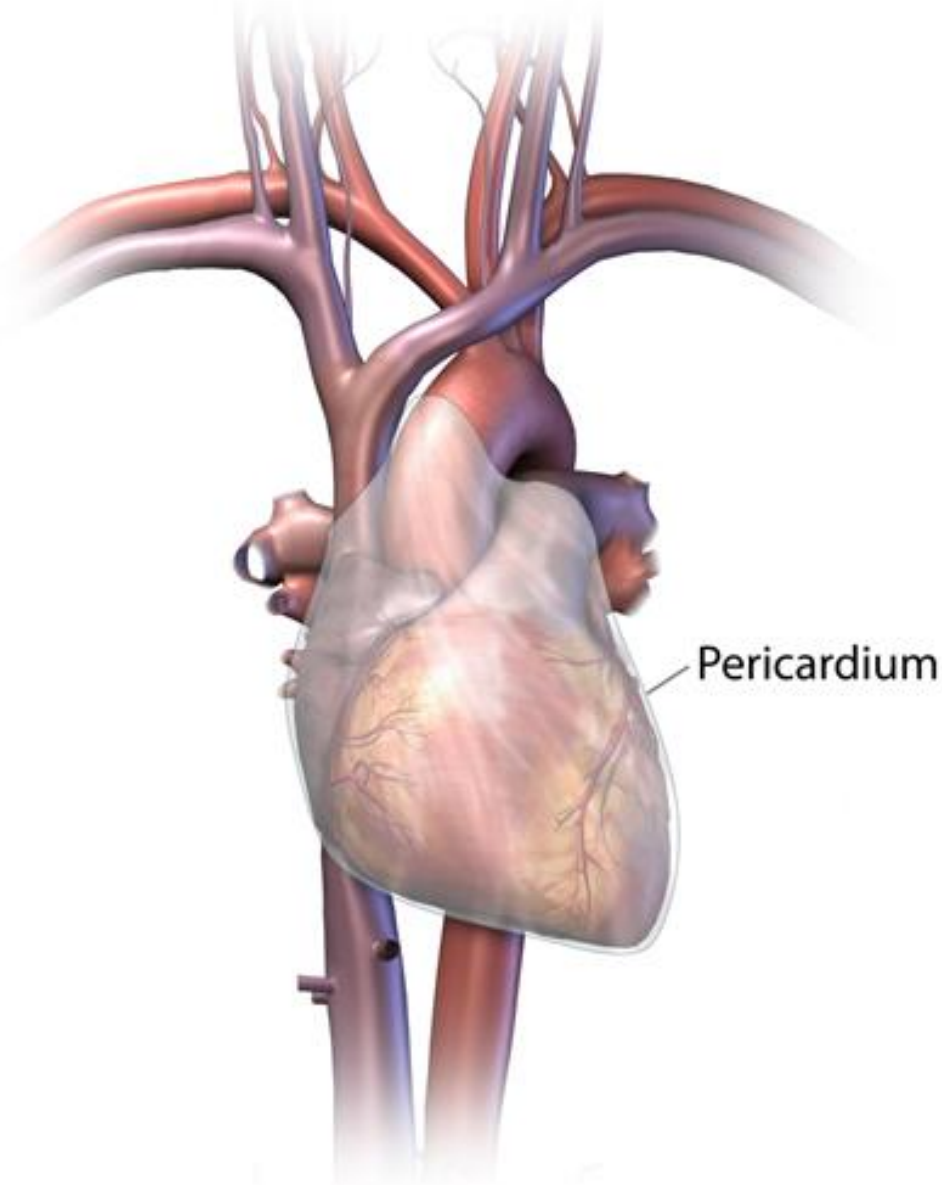


Pericardium



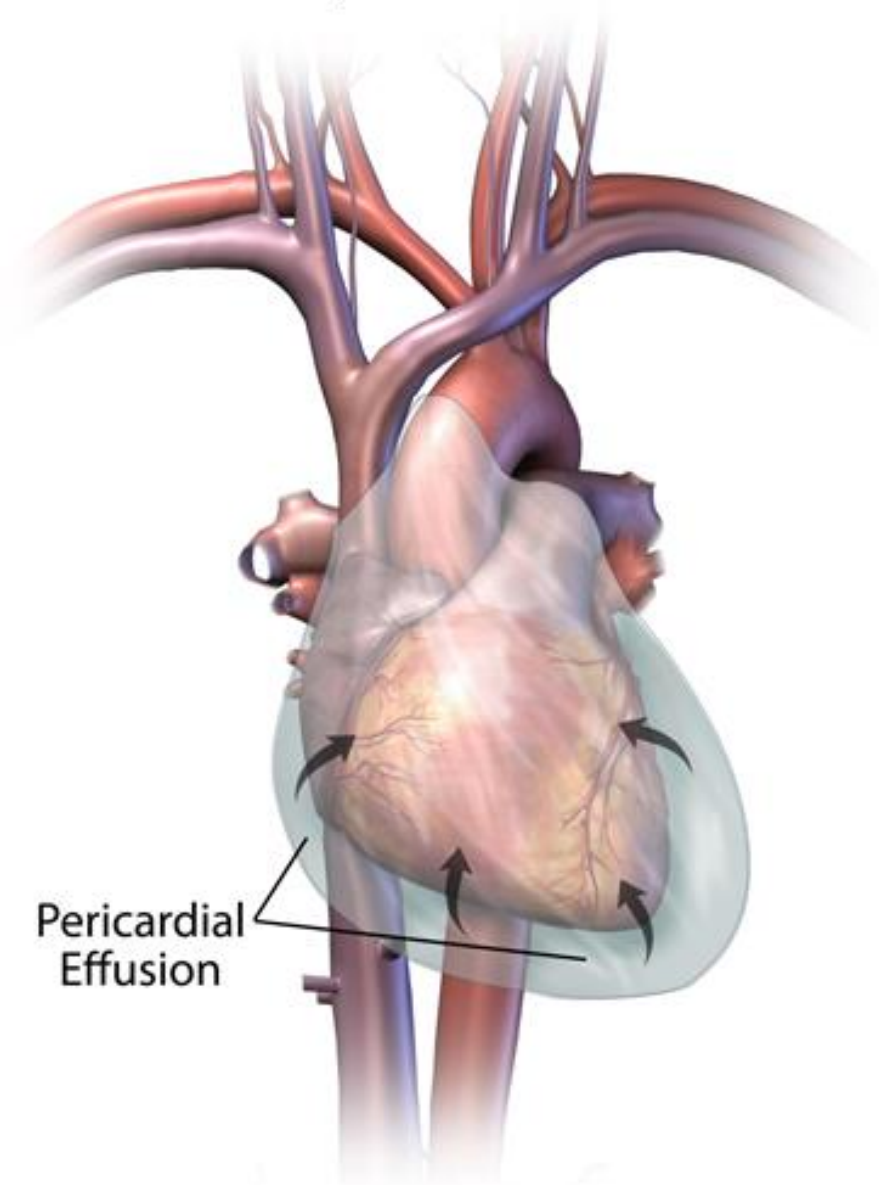
Normal Heart and Pericardium

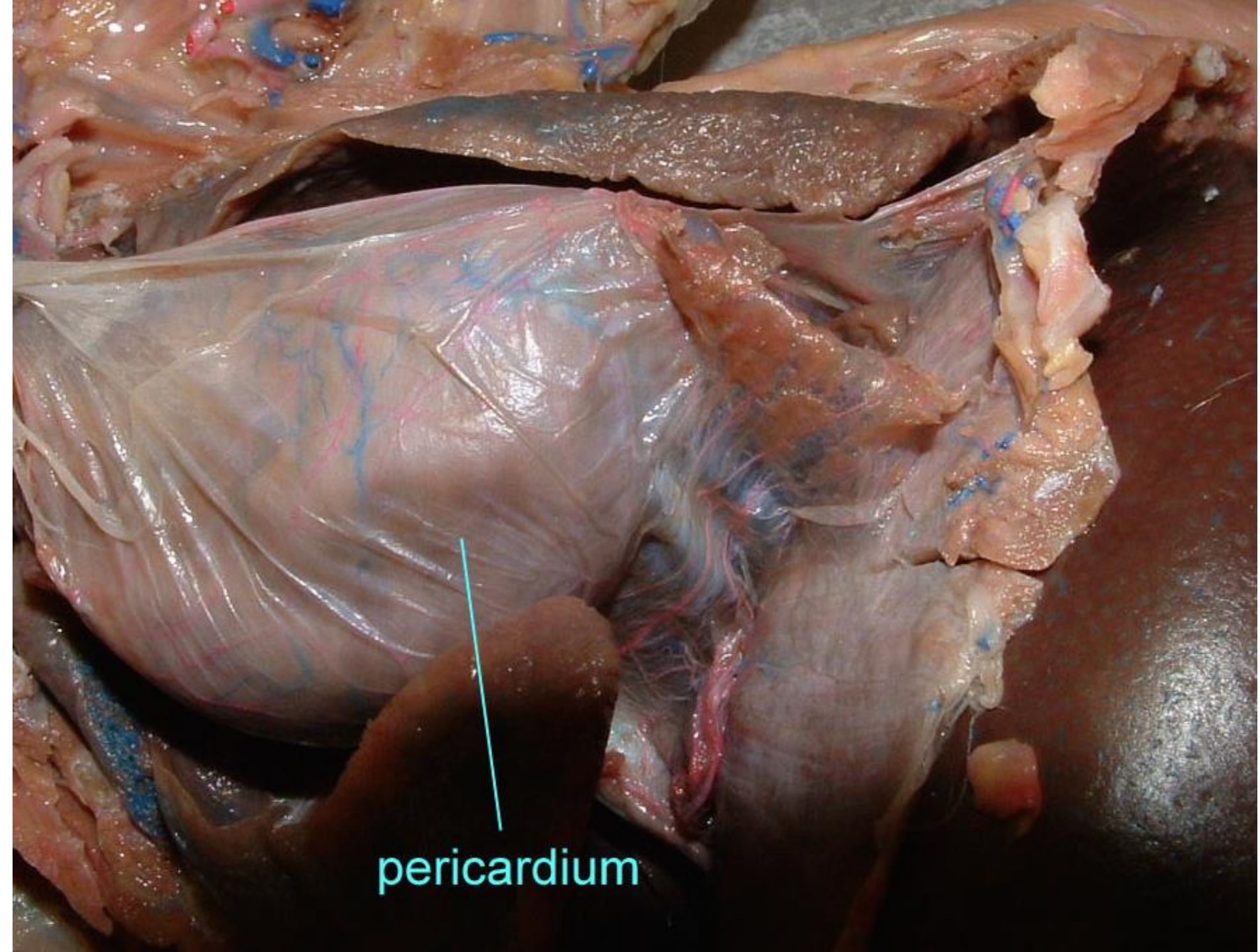
The pericardium is a thin membrane that covers the heart.



Pericardial Effusion

The pericardium fills with abnormal fluid and compresses the heart.

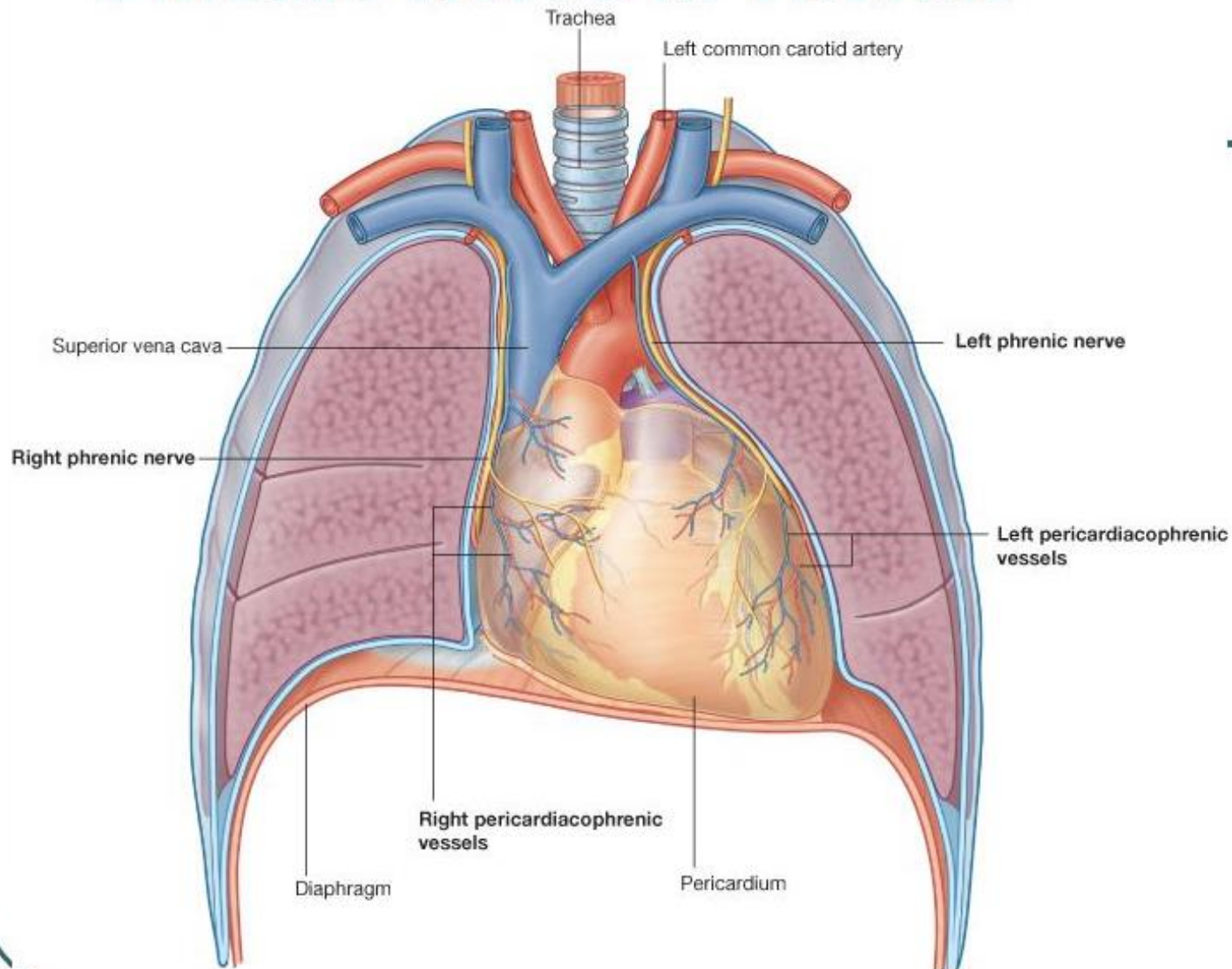


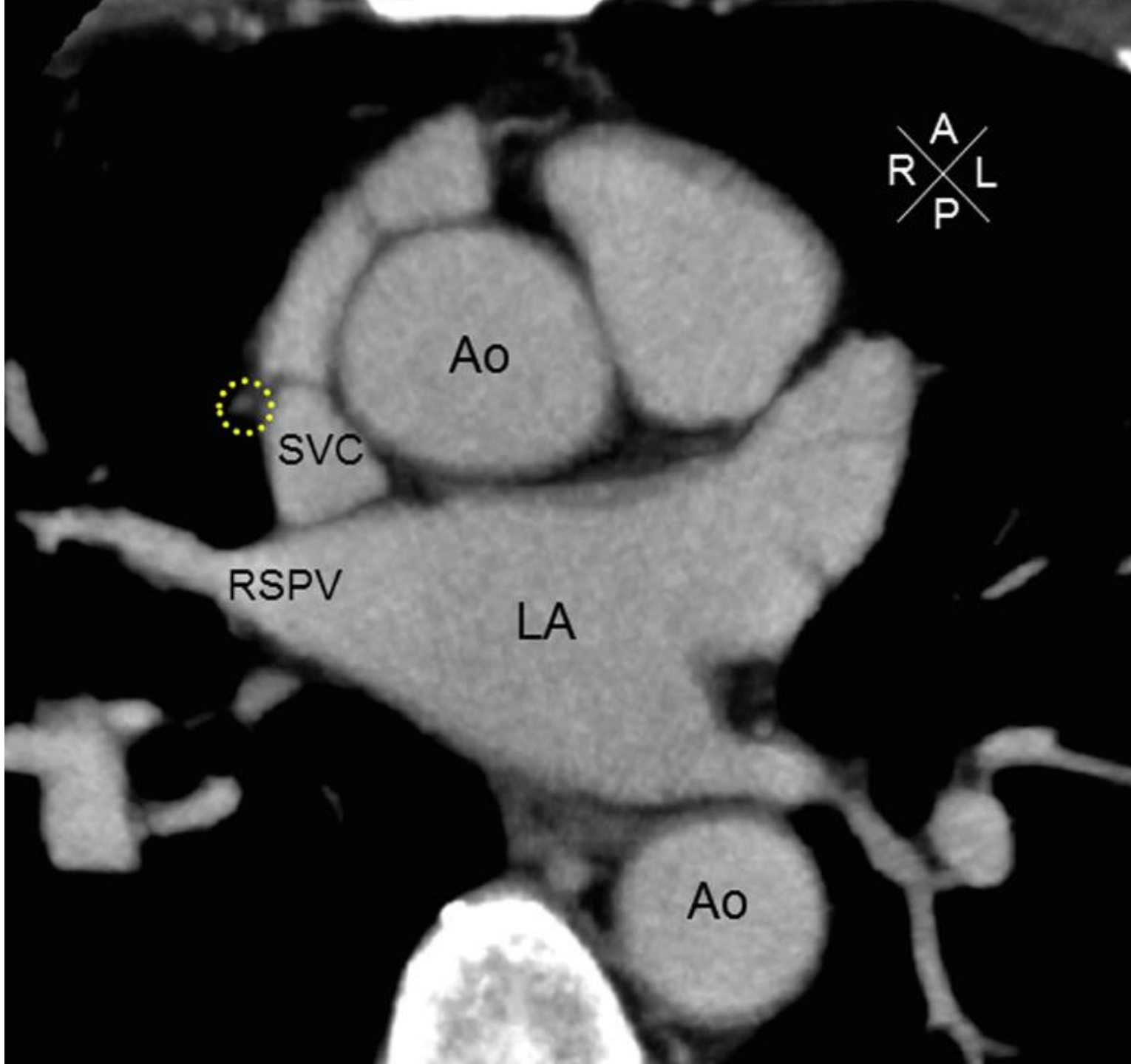


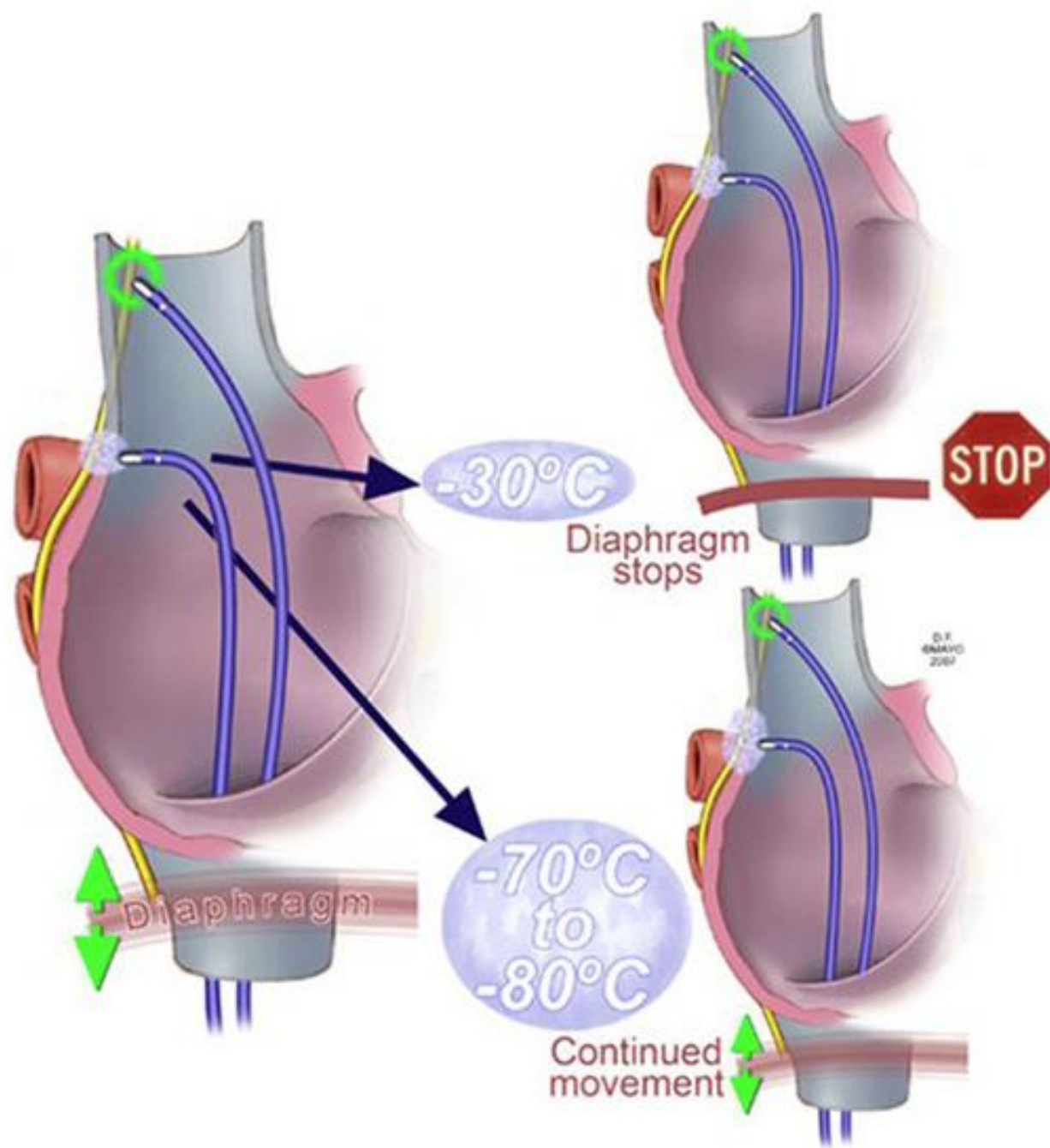
pericardium

Le nerf Phrénique

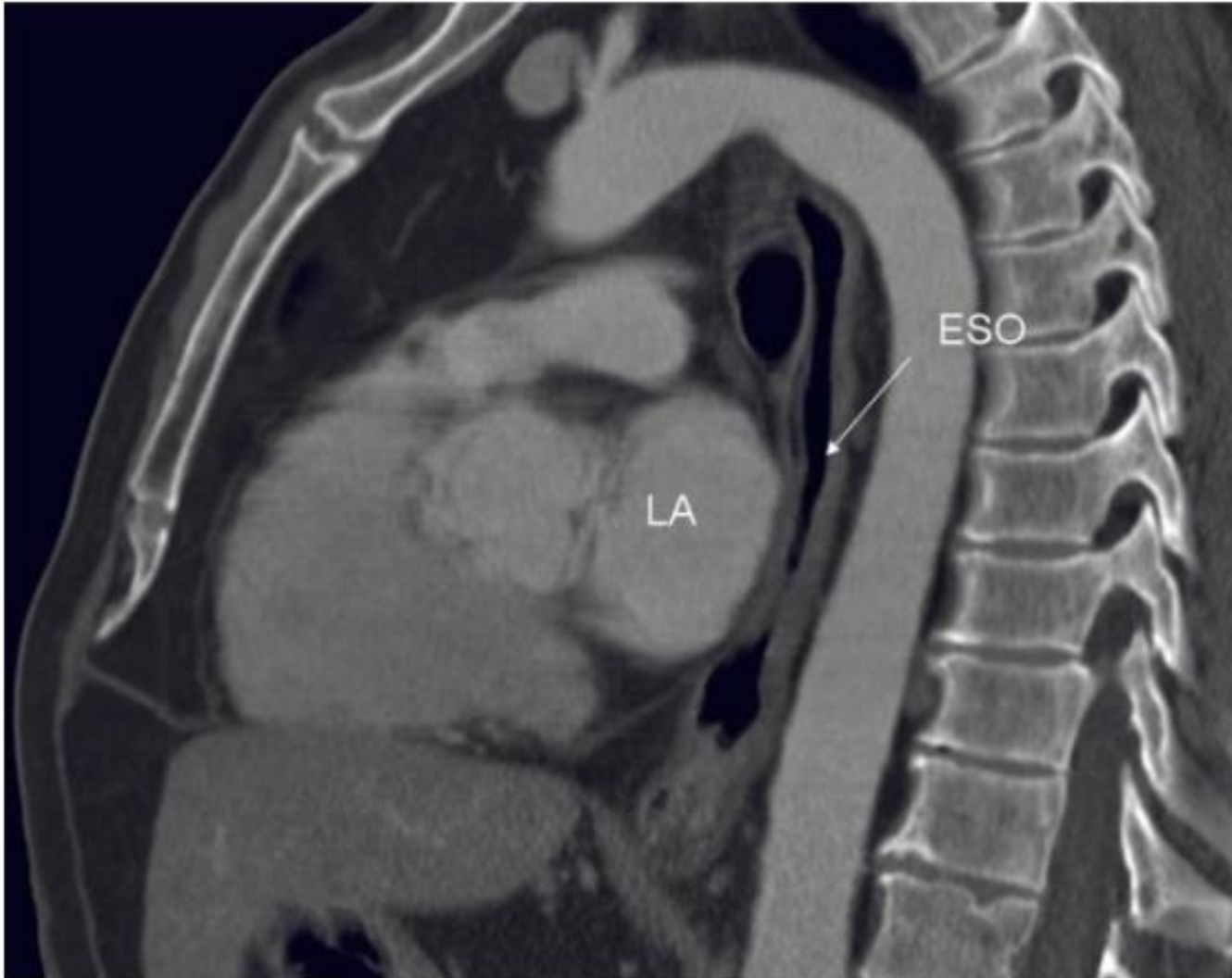
Phrenic Nerve in Thorax



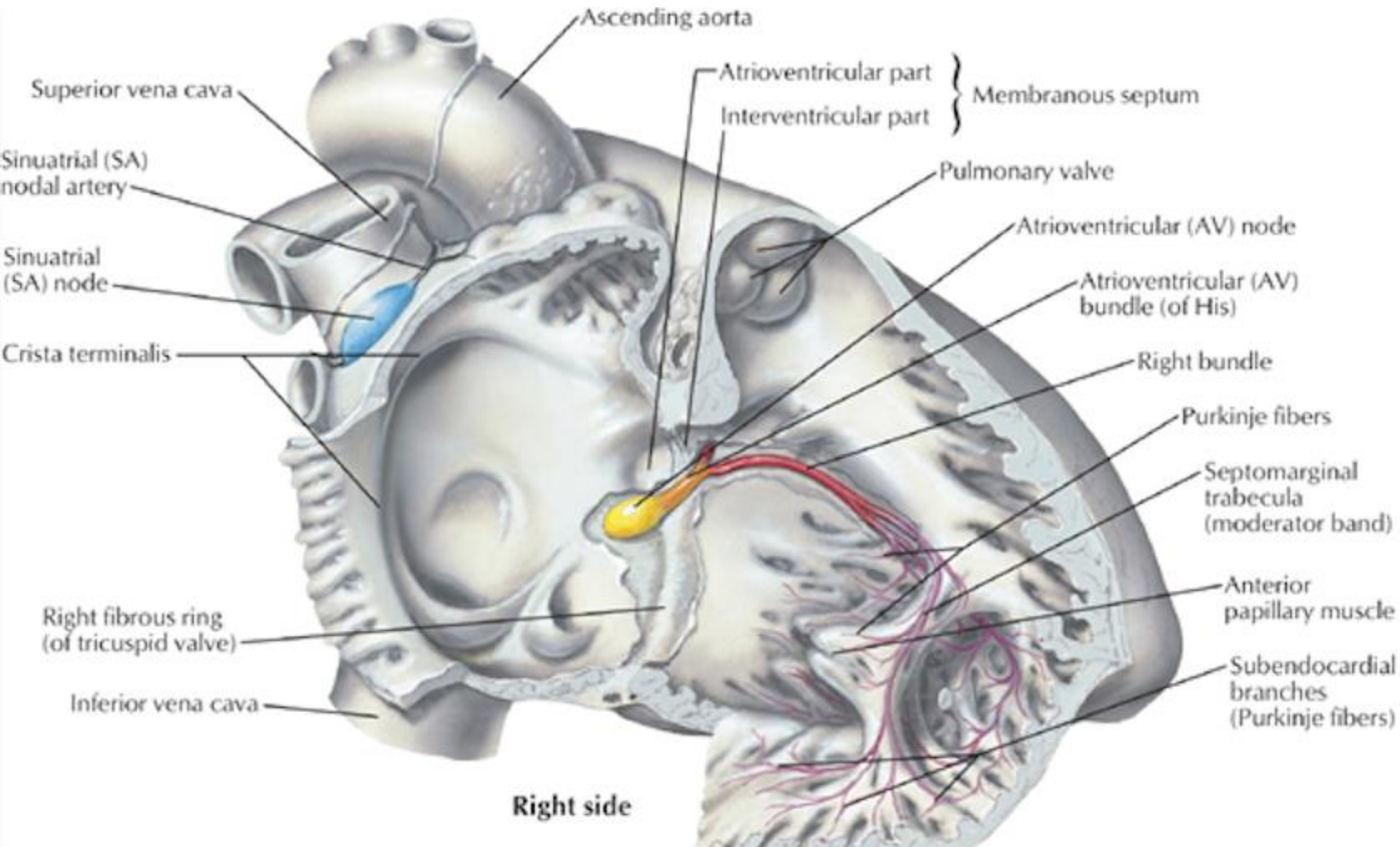




L'oesophage



MERCI DE VOTRE ATTENTION!



- Bonnes connaissances anatomiques essentielles

