



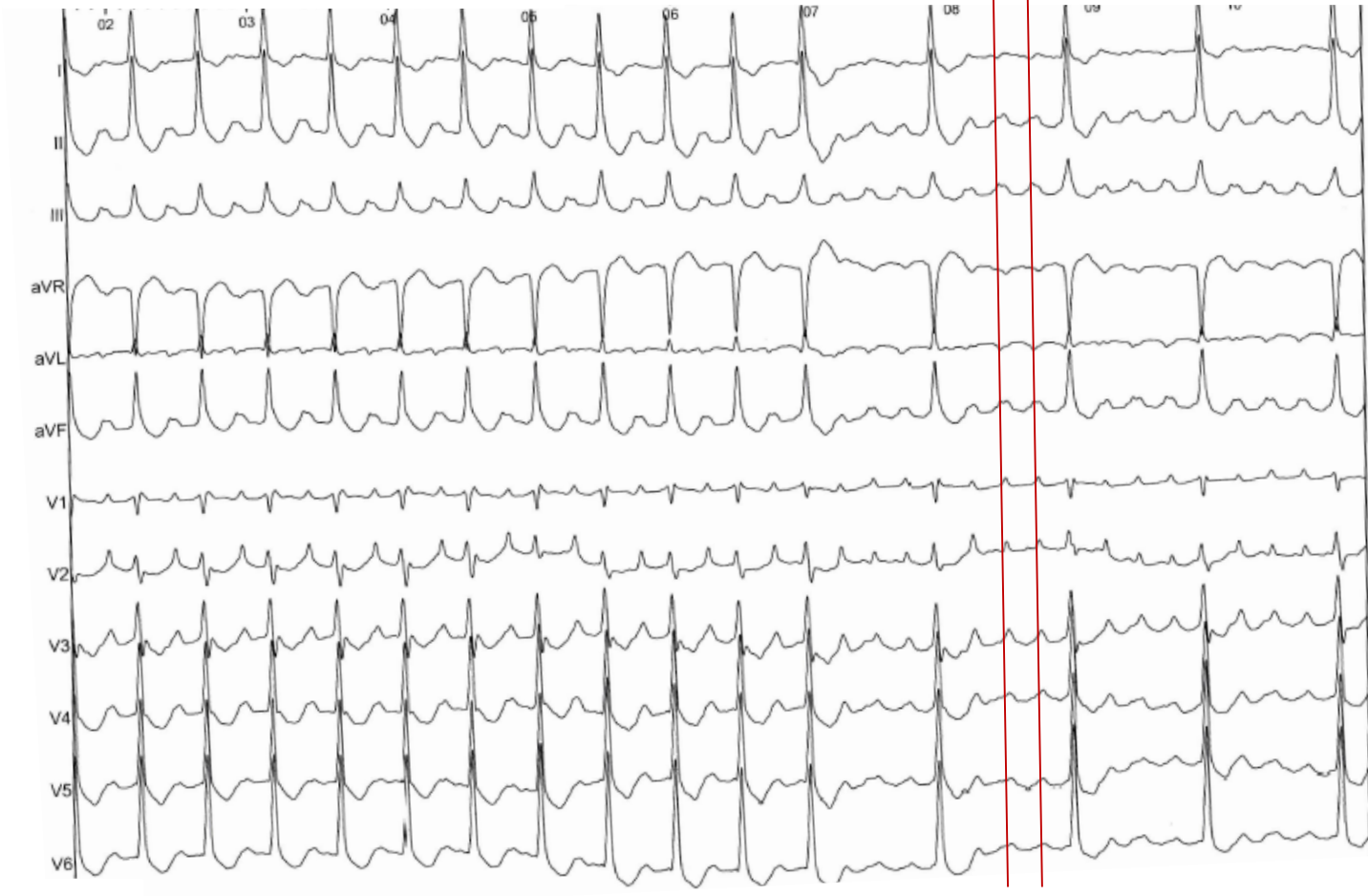
« David Against Goliath »

Mars 2017

Stéphane Combes, *Département de rythmologie et de stimulation cardiaque*
scombes@clinique-pasteur.com

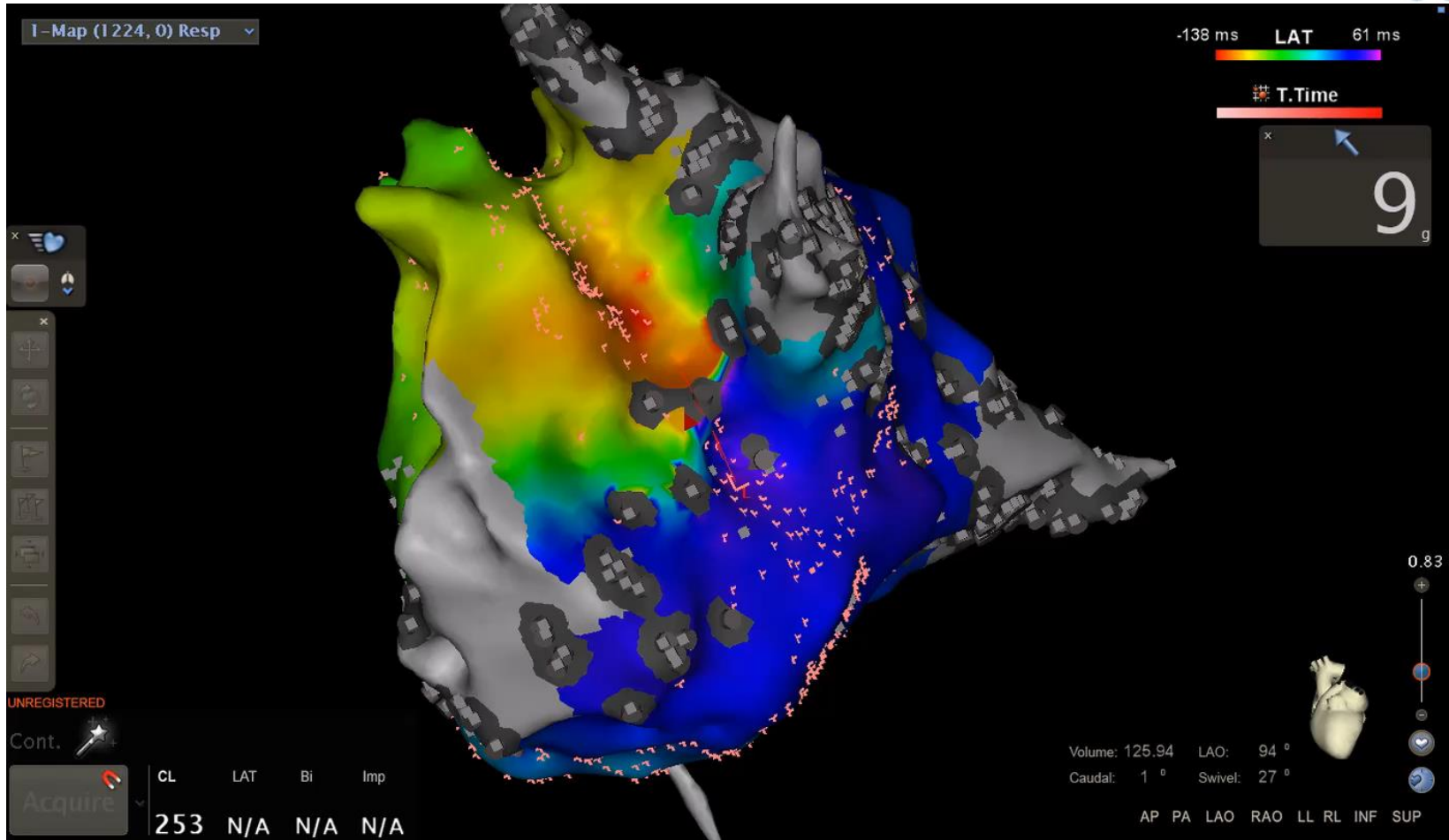
Patient aged 70 years old

- 2011: paroxysmal AF Ablation (cryo ablation with 28 mm balloon)
- 2014: Palpitations. ECG Left Atrial Flutter
- A new ablation was performed: PV was disconnected and EP study confirmed a peri mitral flutter.
- At the beginning of 2017, patient presents new symptoms



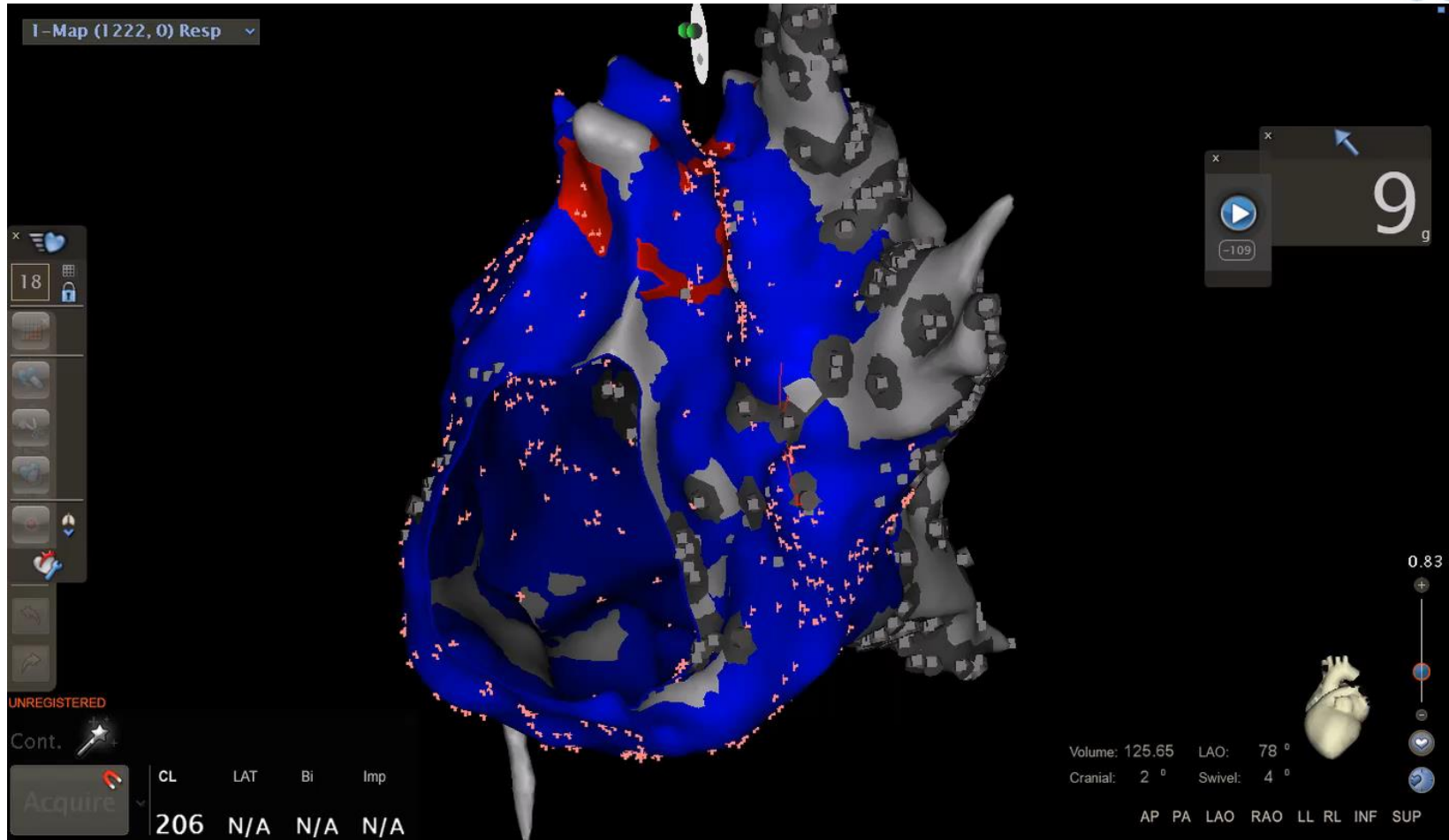
CL: 240 ms

Activation map

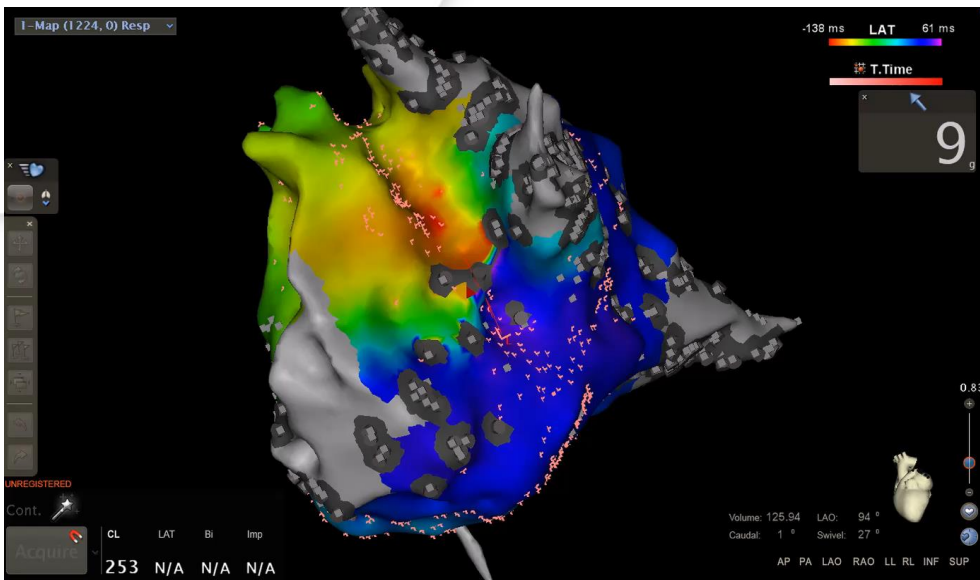


CLT: 240 ms

propagation map



question



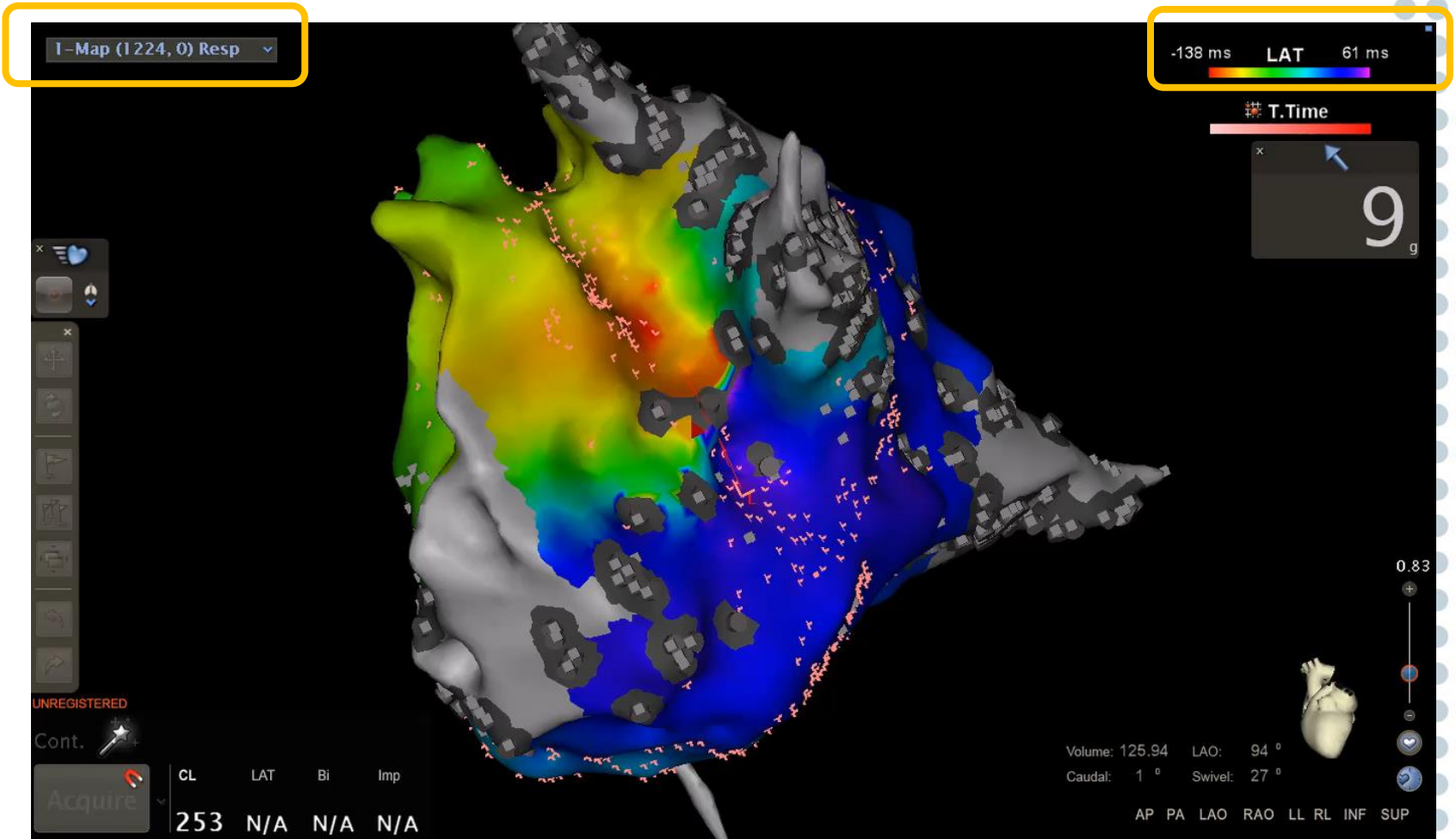
1- left focal atrial tachycardia

2- peri mitral flutter

3- complet block at the mitral isthmus

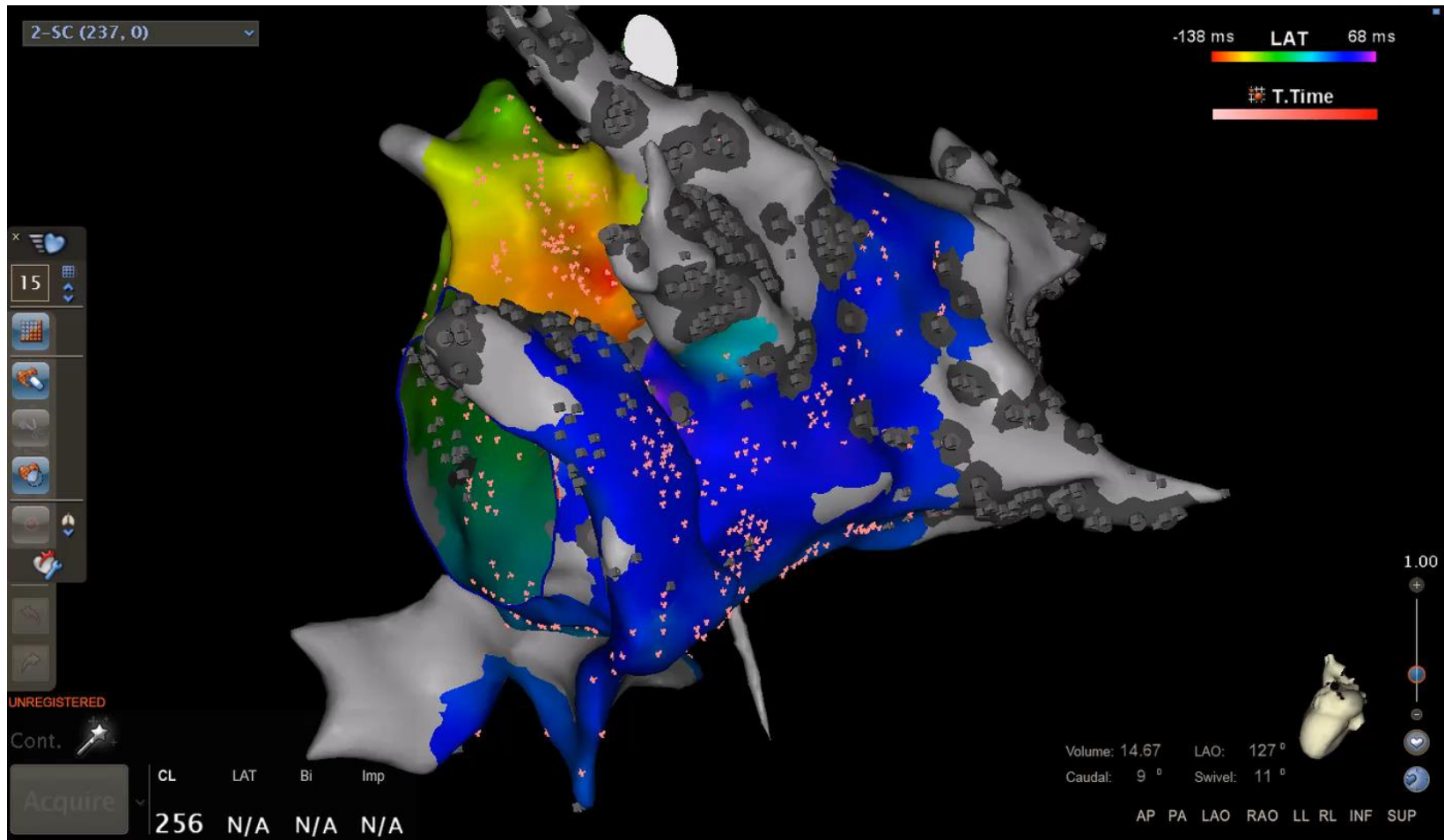
4- right atrial tachycardia

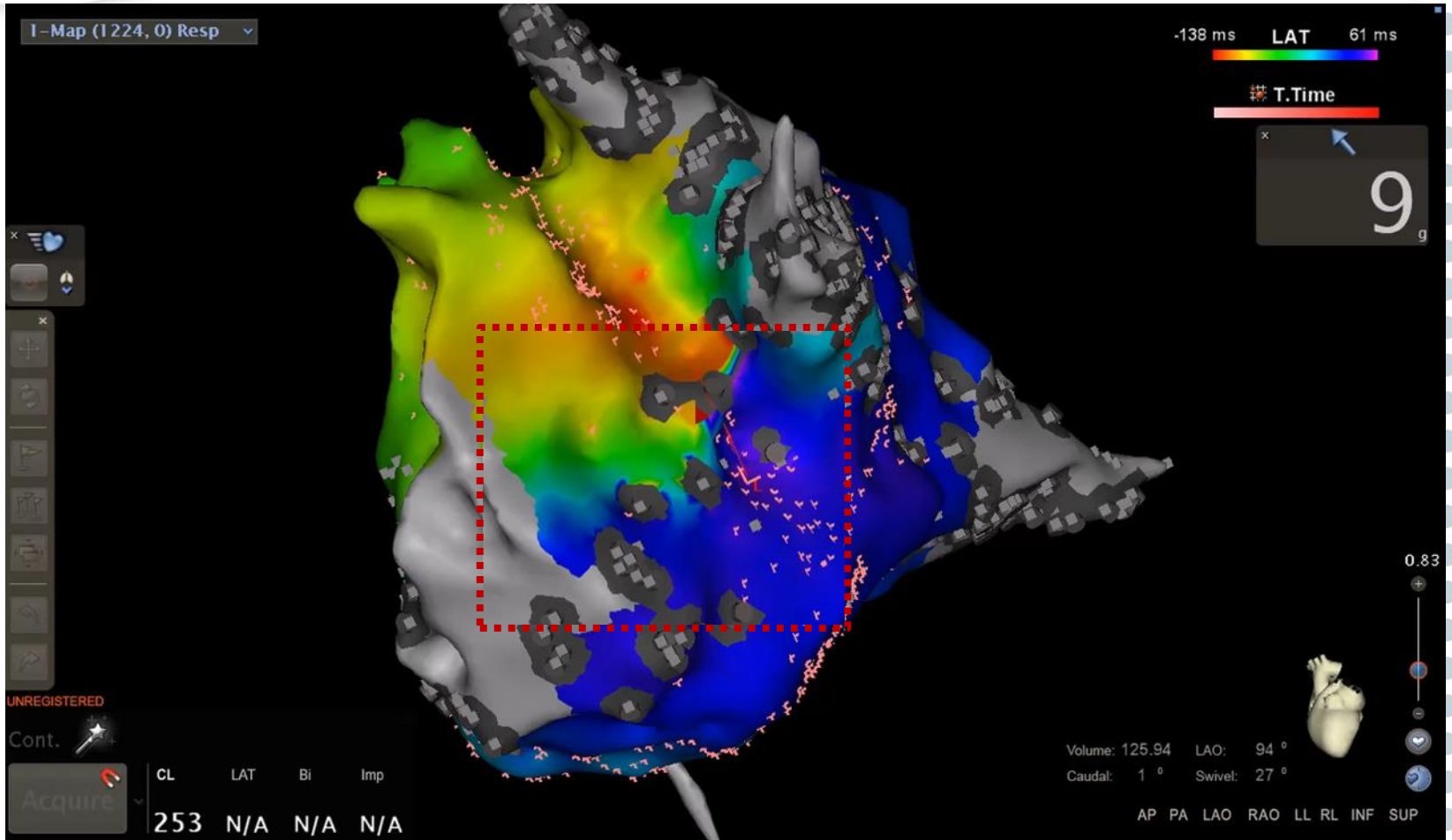
Activation map

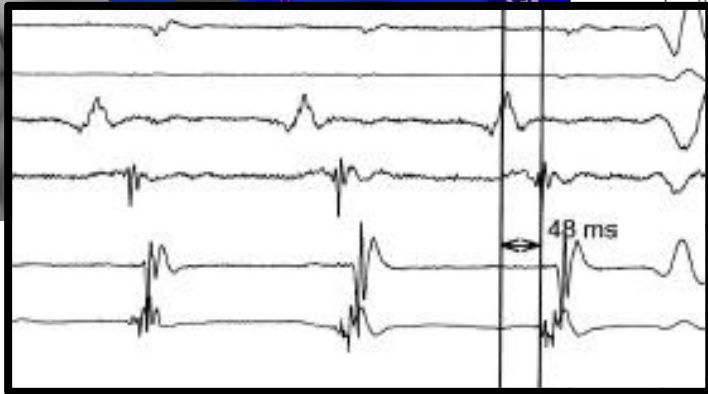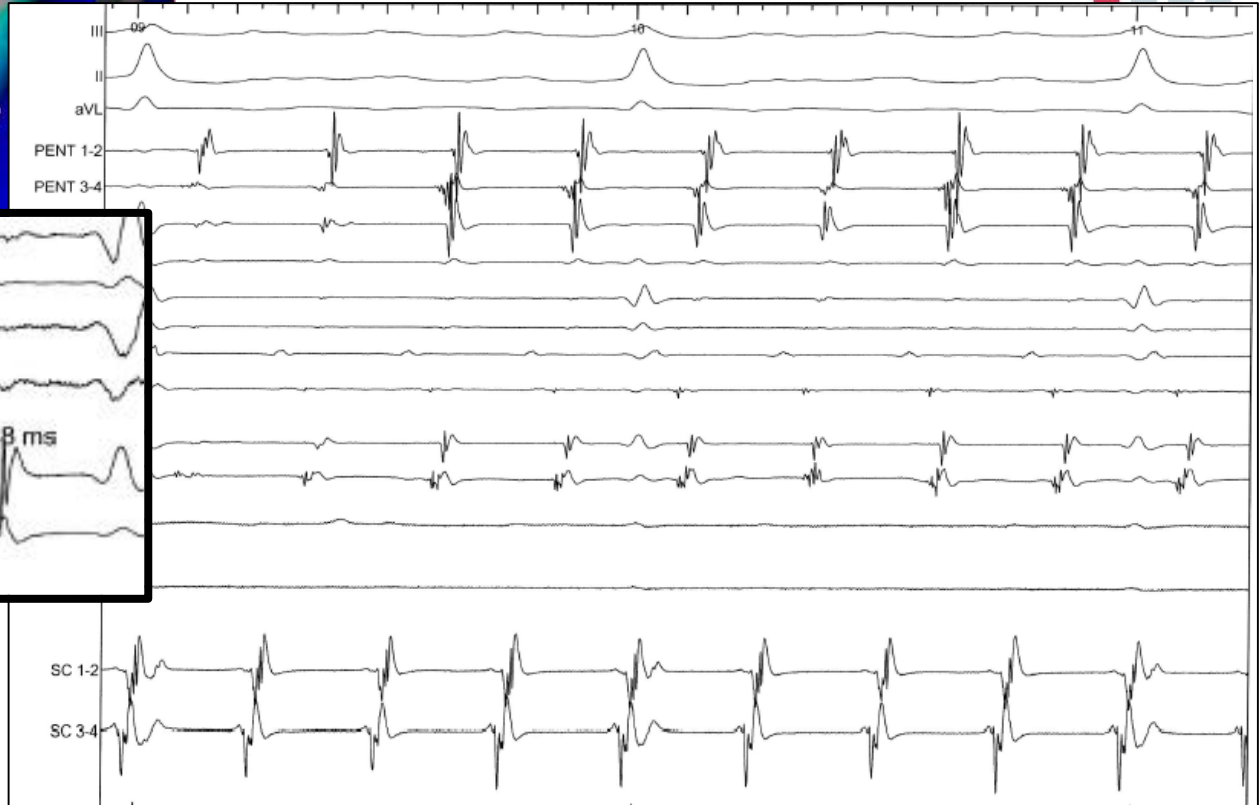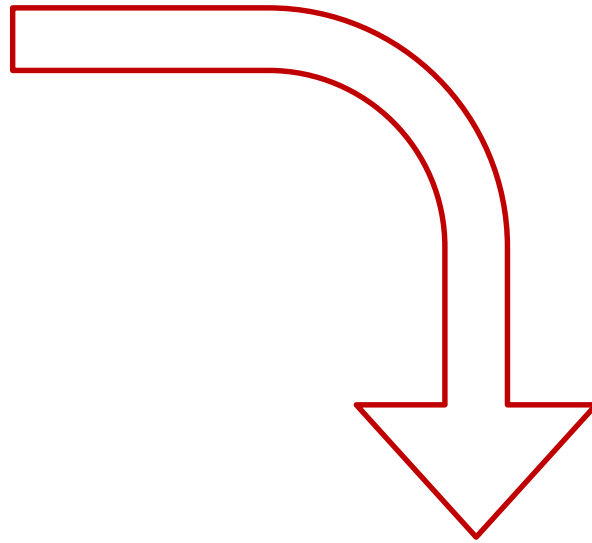
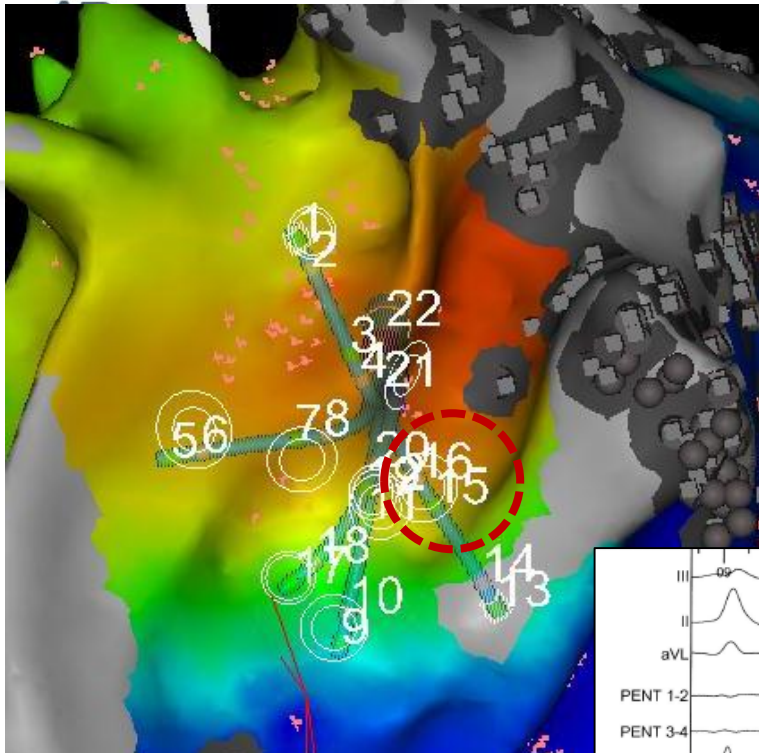


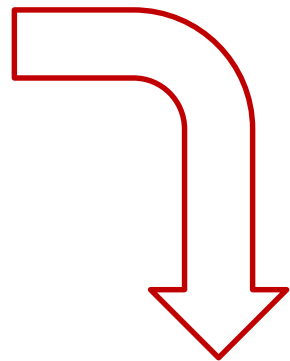
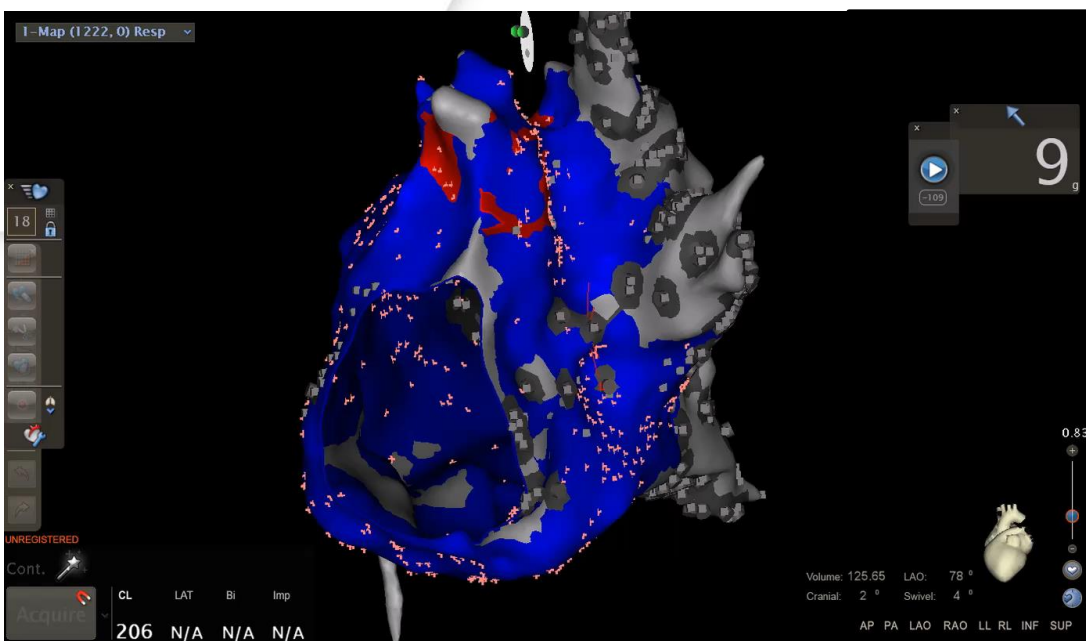
CLT: 240 ms

Activation map

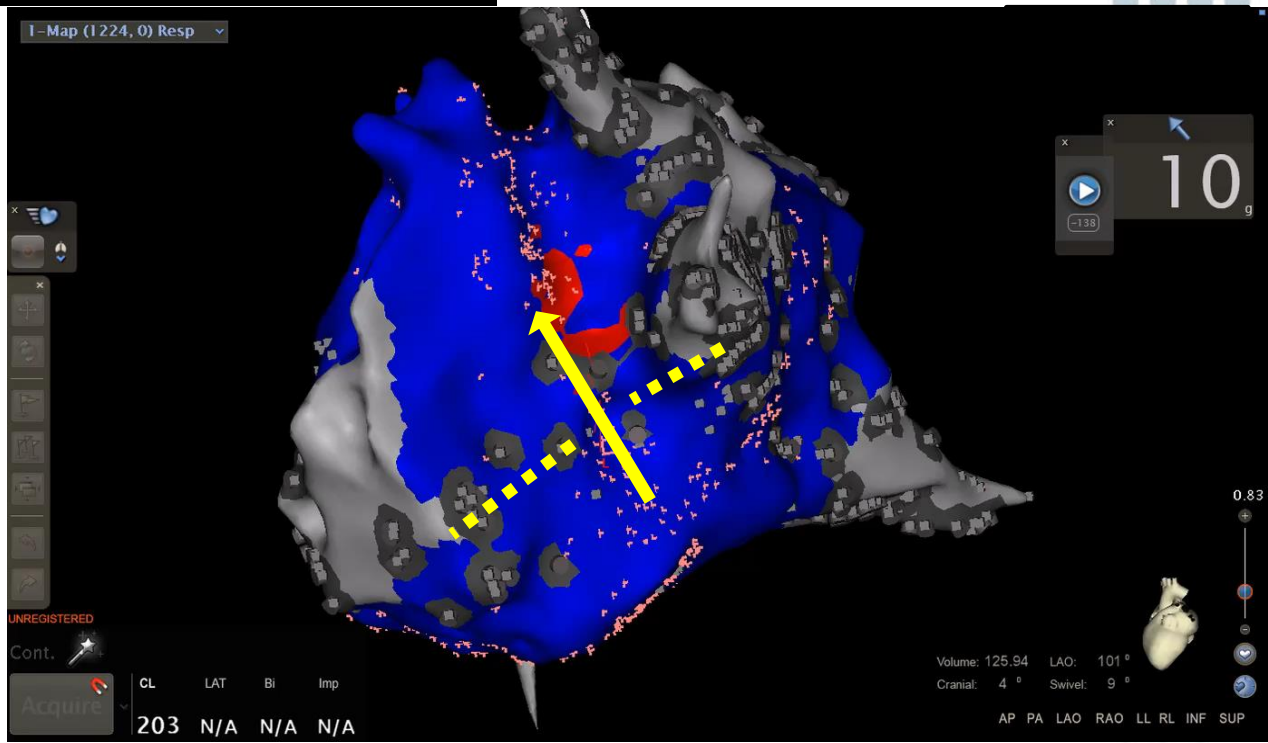


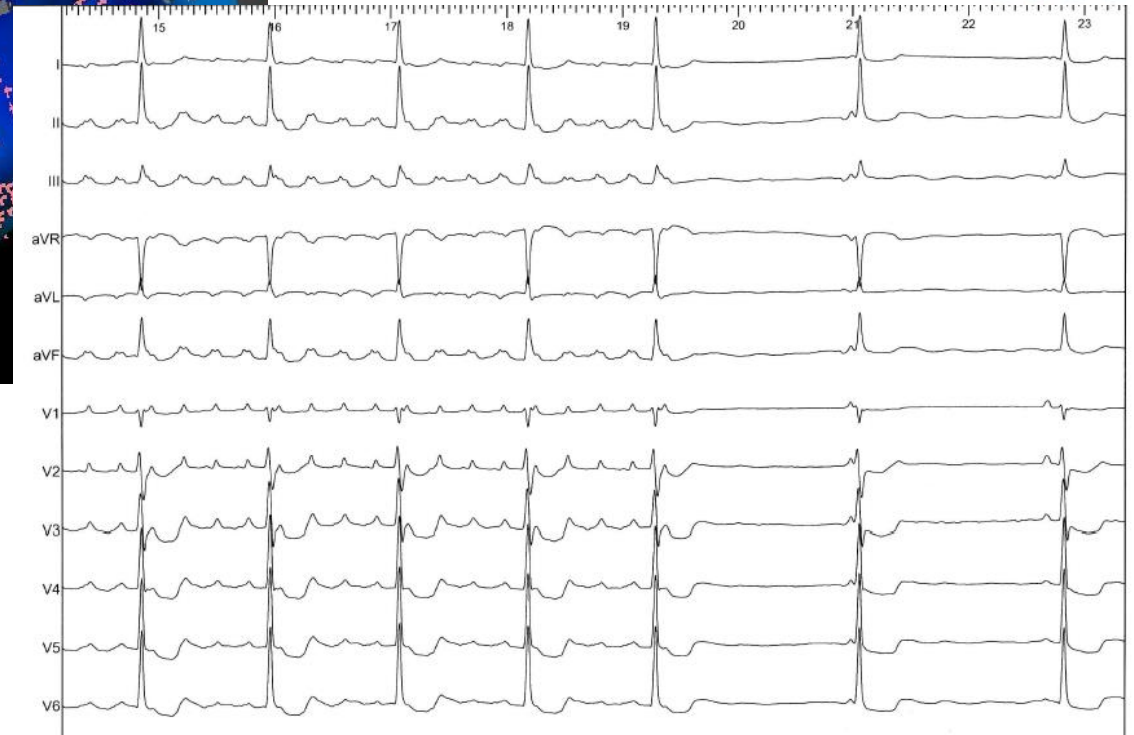
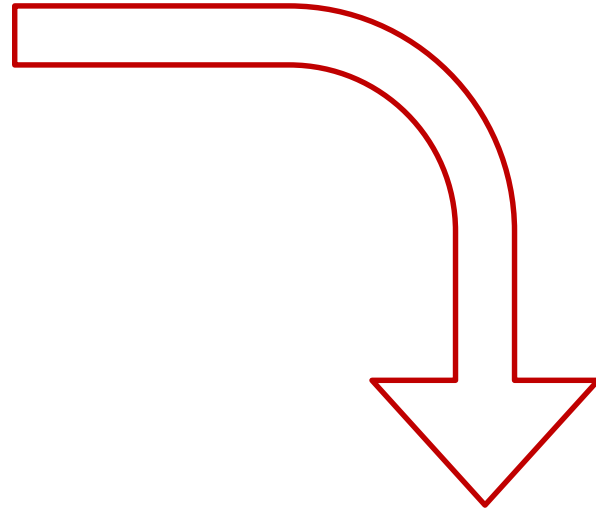
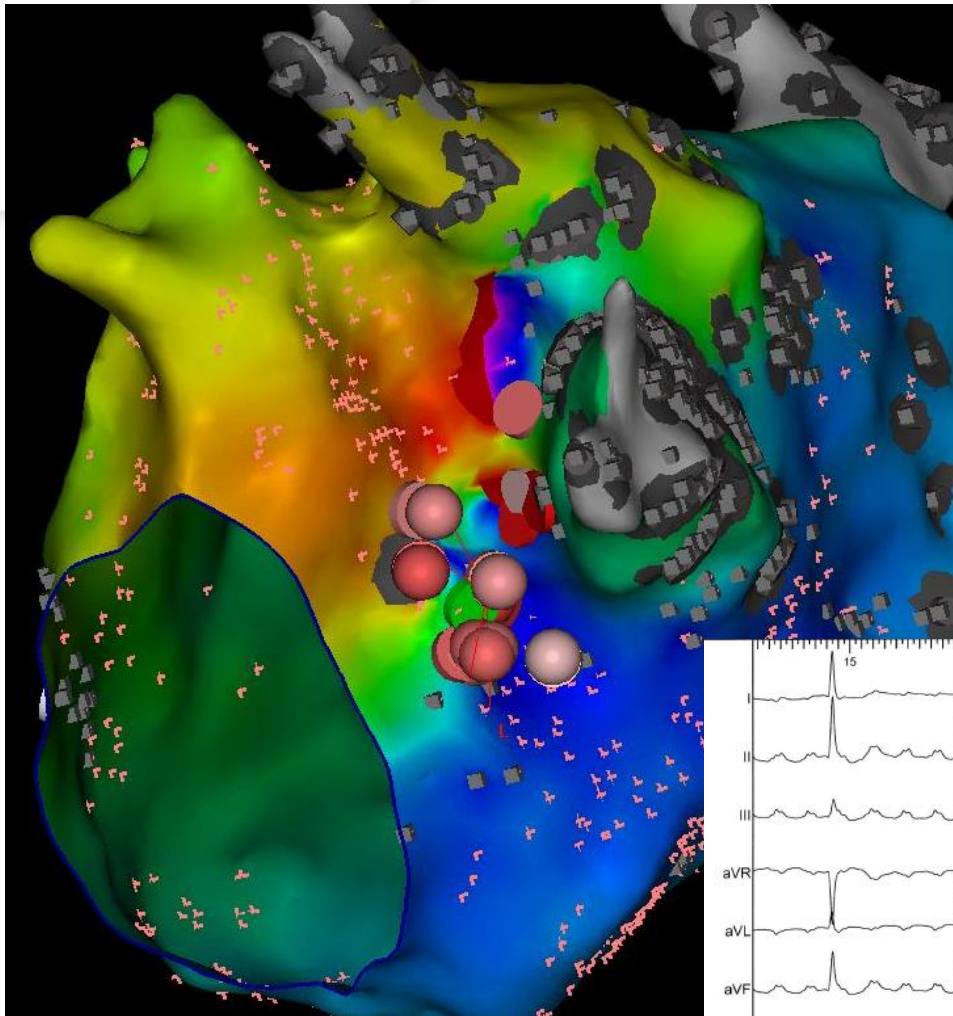


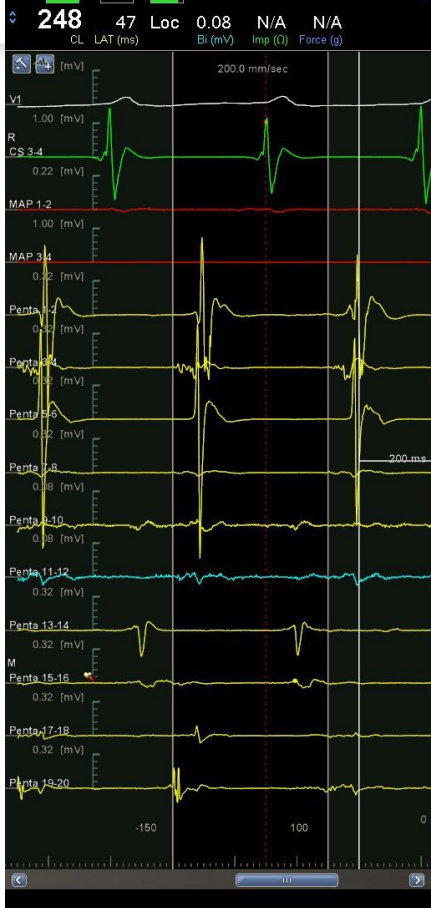



Manual change



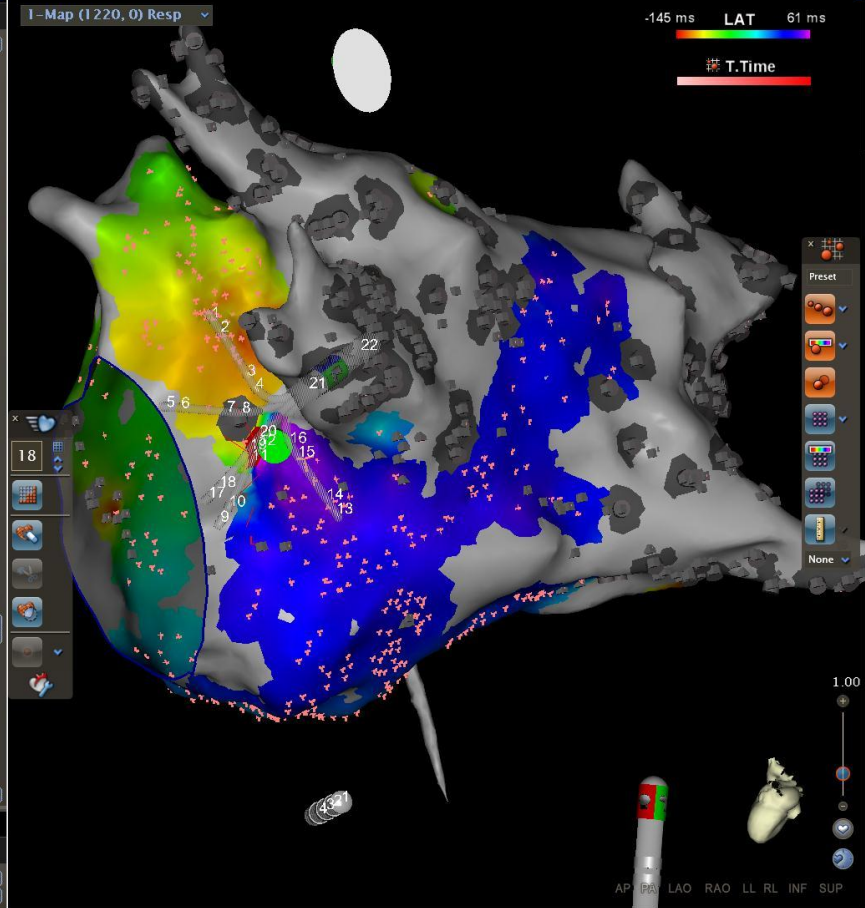




#	LAT	Elect.	CL	F
1074	-119	Penta ...	248	↑
1075	37	Penta ...	248	↑
1076	-116	Penta ...	250	↑
1077	-119	Penta ...	248	↑
1078	37	Penta ...	248	↑
1079	-120	Penta ...	250	↑
1080	-119	Penta ...	249	↑
1081	37	Penta ...	249	↑
1082	-121	Penta ...	251	↑
1083	41	Penta ...	247	↑
1084	-113	Penta ...	250	↑
1085	44	Penta ...	250	↑
1086	-107	Penta ...	249	↑
1087	-108	Penta ...	248	↑
1088	41	Penta ...	248	↑
1089	-109	Penta ...	250	↑
1090	-108	Penta ...	248	↑
1091	41	Penta ...	248	↑
1092	-110	Penta ...	251	↑
1093	44	Penta ...	251	↑
1094	-112	Penta ...	250	↑
1095	-100	Penta ...	248	↑
1096	-117	Penta ...	248	↑
1097	-108	Penta ...	248	↑
1101	51	Penta ...	248	↑
1102	47	Penta ...	248	↑
1105	-109	Penta ...	250	↑
1113	51	Penta ...	250	↑
1115	-125	Penta ...	250	↑
1120	51	Penta ...	250	↑
1130	28	Penta ...	249	↑
1134	28	Penta ...	248	↑
1135	30	Penta ...	251	↑
1136	27	Penta ...	249	↑
1137		Penta ...	249	↑
1138	27	Penta ...	249	↑
1141		Penta ...	504	↑
1142		Penta ...	504	↑
1143	34	Penta ...	504	↑
1149	29	Penta ...	248	↑
1150	28	Penta ...	249	↑
1152	29	Penta ...	249	↑

#	LAT	Elect.	CL	F
0001		Penta ...	245	↑
0002		Penta ...	247	↑
0003		Penta ...	244	↑

Recycle Bin



Take home message

I wanted to show you that new systems of cartography “**Goliath**” and automatic mapping is a breakthrough.

but will never replace the signal with a new catheter and the eye of the electrophysiologist “**David**”





Thank you for your attention