




My worst/most didactic BTK case

JM PERNES



Le masochisme est une perversion absurde qui consiste à se faire du mal à soi-même, alors qu'il y a les autres pour cela.

Georges-Armand Masson.



Disclosure of Interest

Speaker name: ..JM PERNES.....

- I have the following potential conflicts of interest to report:
- Consulting
- Employment in industry
- Shareholder in a healthcare company
- Owner of a healthcare company
- Other(s)
- **I do not have any potential conflict of interest, even with...**



Roc-Eclerc
POMPES FUNÈBRES
CONTRATS OBSÈQUES - MARBRERIE

La disponibilité et la compétence au plus juste prix

- Prise en charge des obsèques
7 jours sur 7
- Transfert en chambre
funéraire
24 heures sur 24
- Etude personnalisée et
gratuite de votre contrat obsèques

**Promo
Toussaint**
-20% sur le monument
de votre choix*
Jusqu'au 15/11/2013

50 monuments
en exposition
sur notre site du Prélong

Deux adresses à **MONTCEAU** : Au centre-ville, rue Blanqui 03 85 57 55 54
Complexe du Prélong, rue des Chavannes (à 400 m de l'hôpital) 03 85 67 10 10



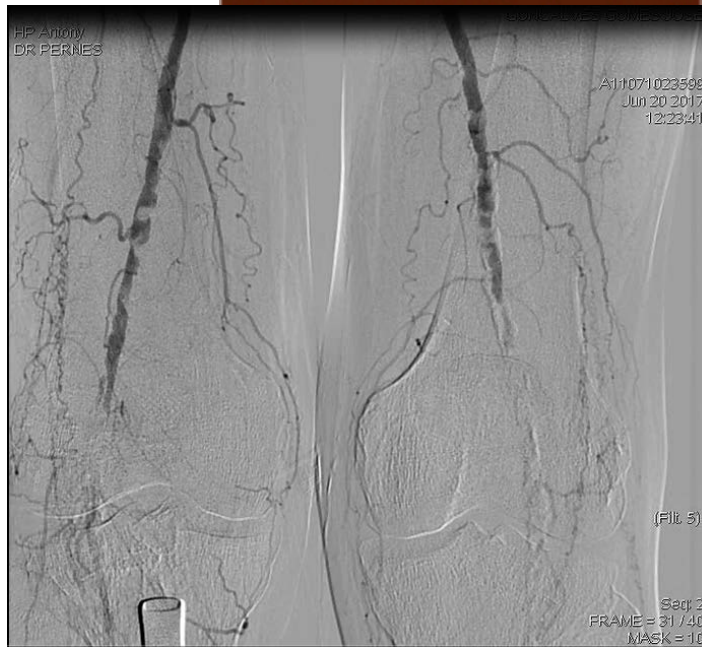
Mr G..., 62 Y

BILATERAL RUTHERFORD III (R>>L): PM 50 M

NO critical ischemia (excuse me, no CLTI...)

TASC D (excuse me, does not exist anymore..)

CHALLENGE : BOTH SIDE ENDO



ESC
European Society
of Cardiology
European Heart Journal (2017) 00, 1–60
doi:10.1093/eurheartj/ehx095

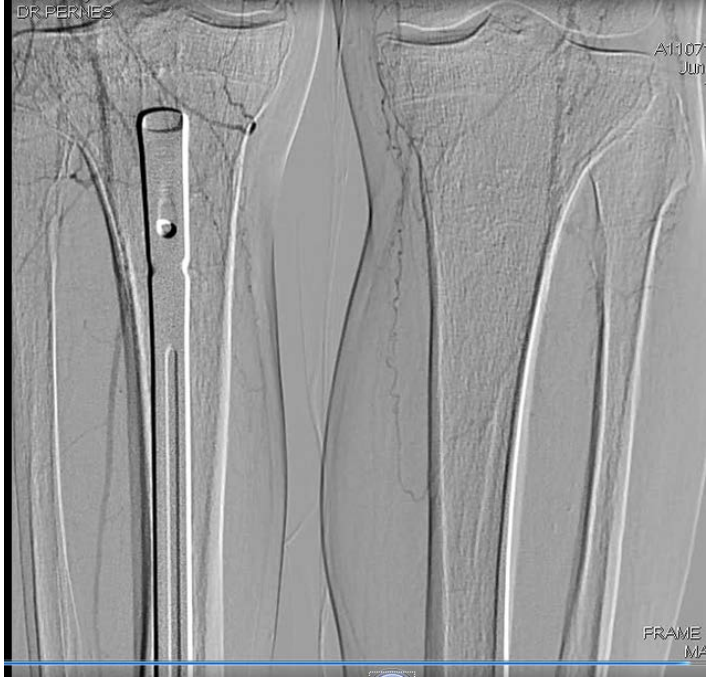ESC GUIDELINES

2017 ESC Guidelines on the Diagnosis and Treatment of Peripheral Arterial Diseases, in collaboration with the European Society for Vascular Surgery (ESVS)

Document covering atherosclerotic disease of extracranial carotid and vertebral, mesenteric, renal, upper and lower extremity arteries

Endorsed by: the European Stroke Organization (ESO)

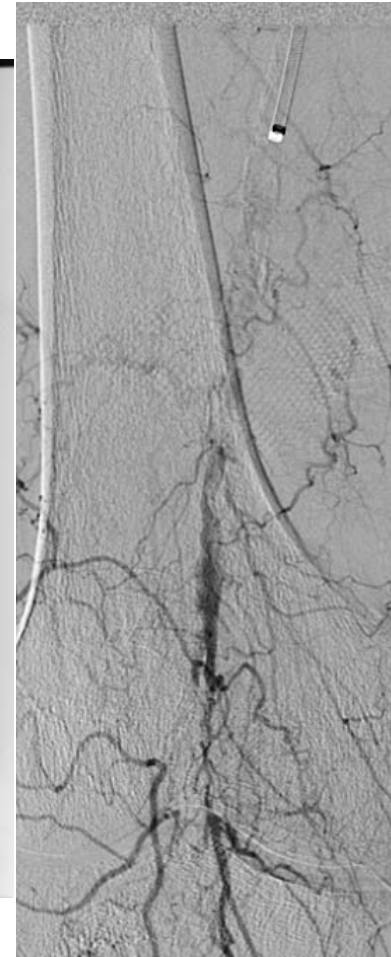
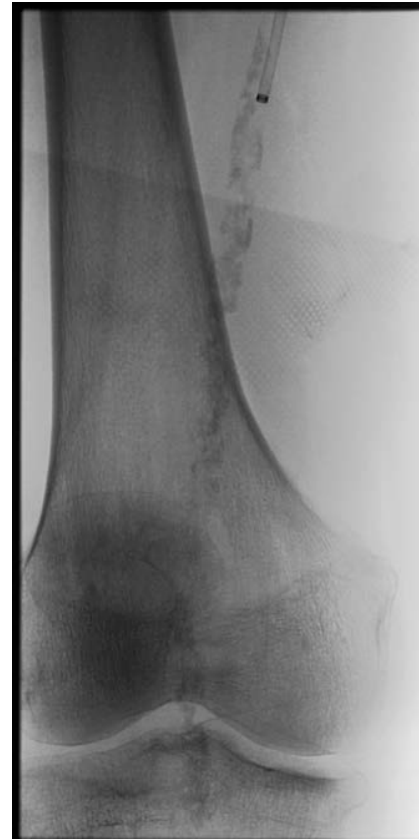The Task Force for the Diagnosis and Treatment of Peripheral Arterial Diseases of the European Society of Cardiology (ESC) and of the European Society for Vascular Surgery (ESVS)

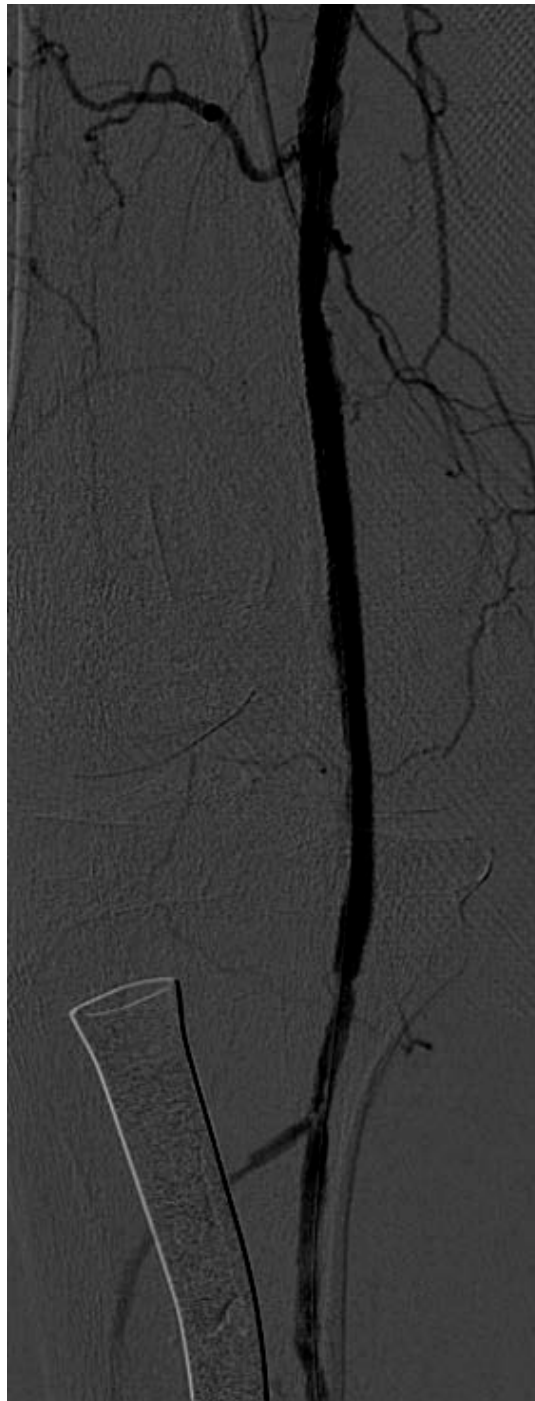
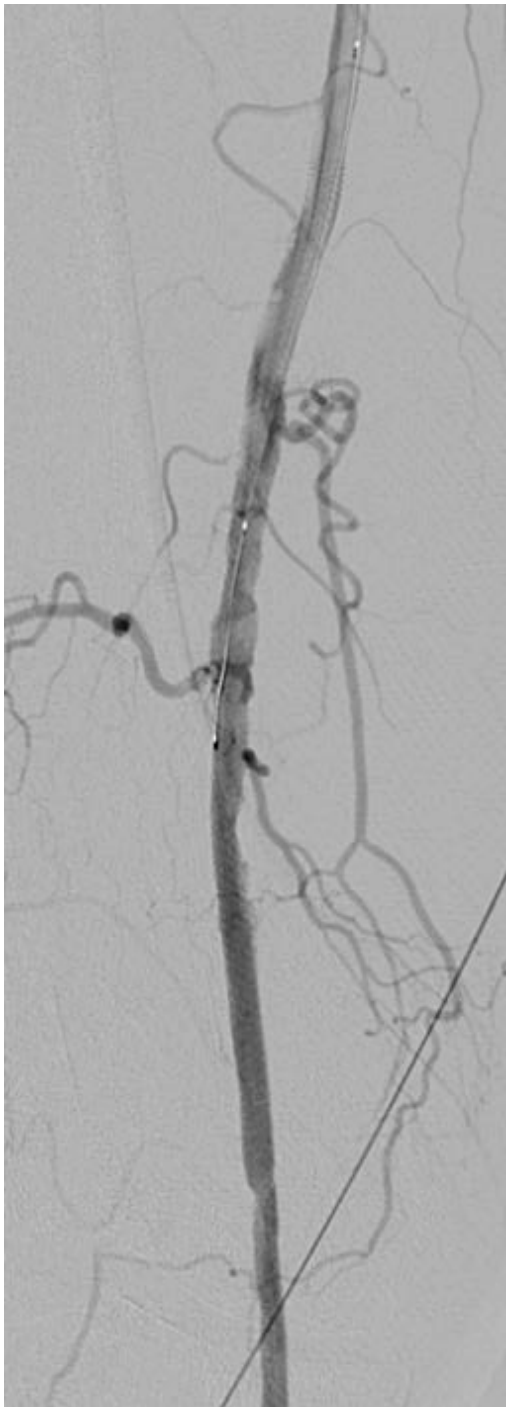


06/2017

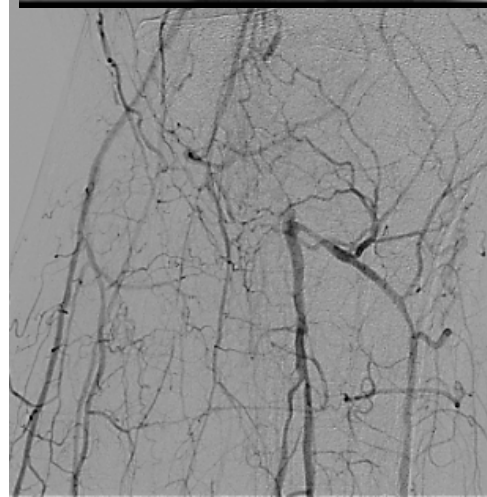
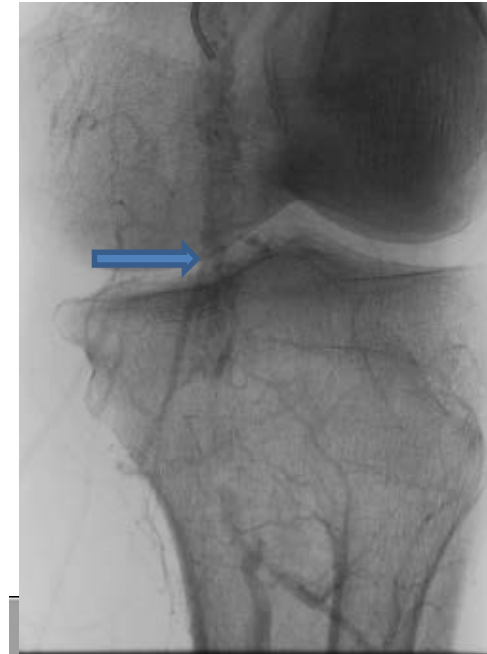
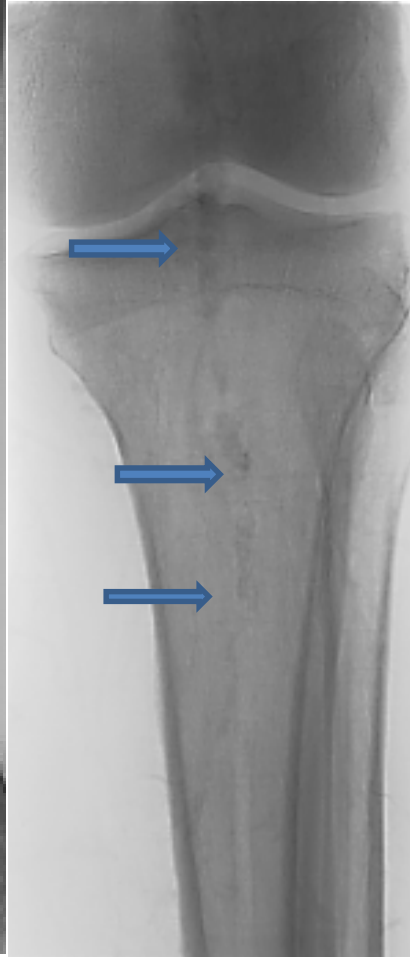
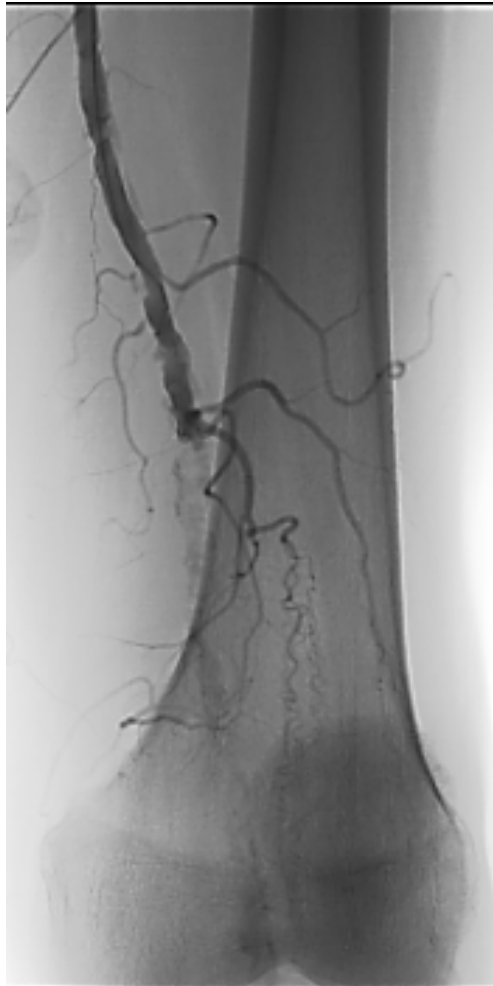
RIGHT SIDE:

- Succes of PIER after failure of intraluminal recanalisation ,in first intention
- Rather hard, but good clinical and hemodynamical result at 6months



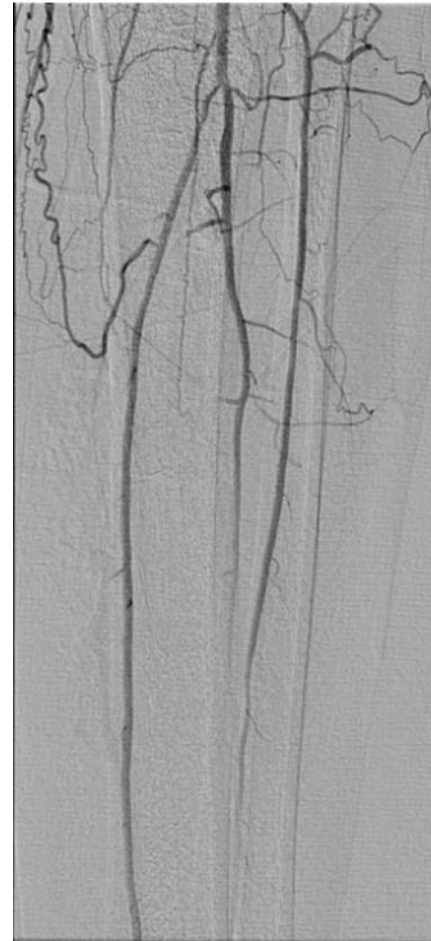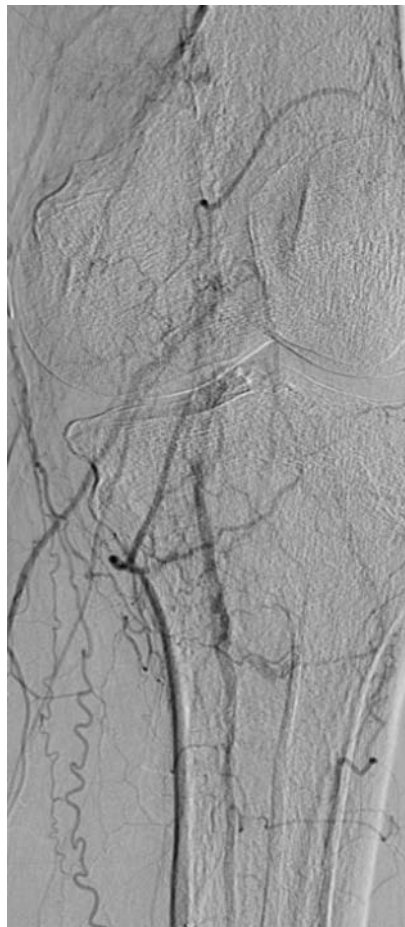
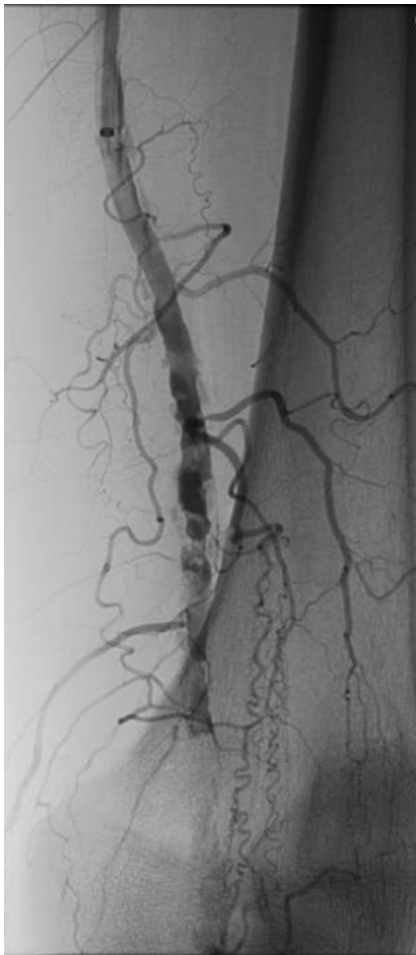


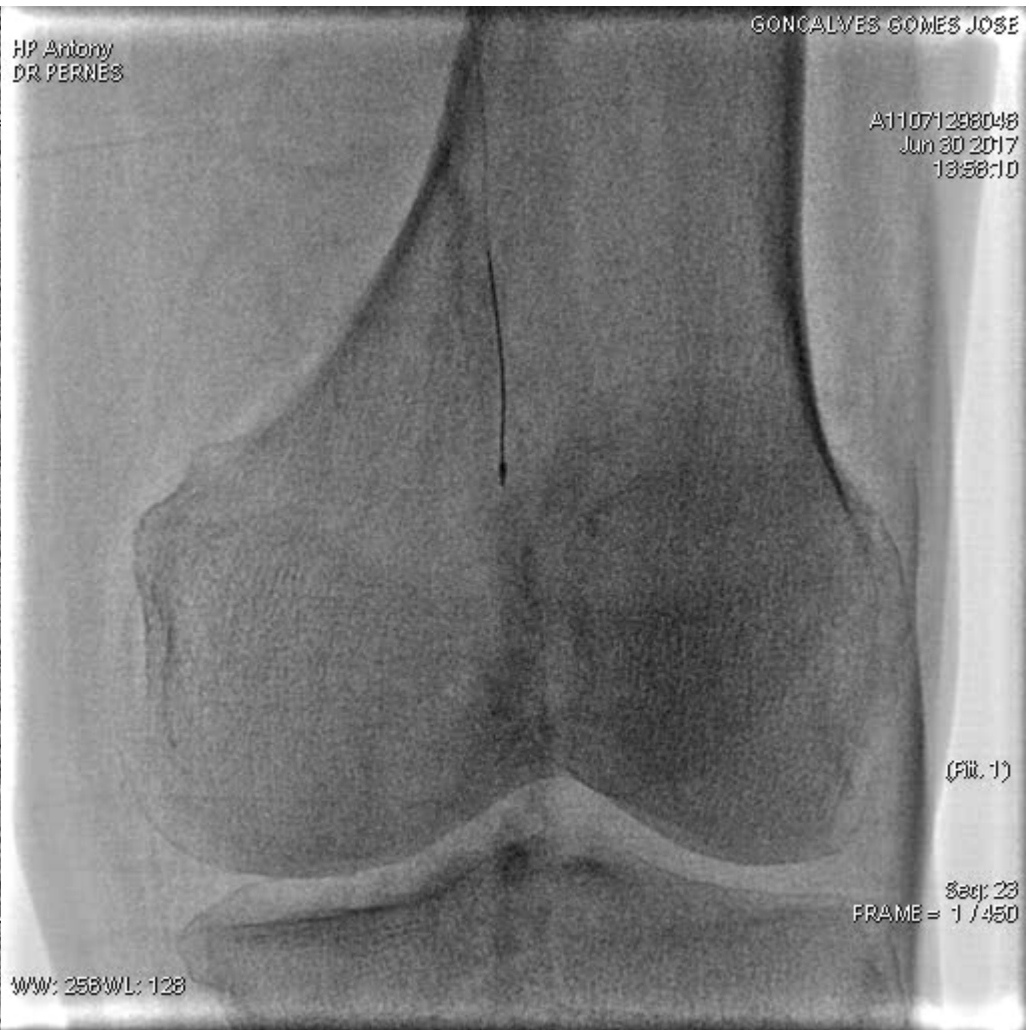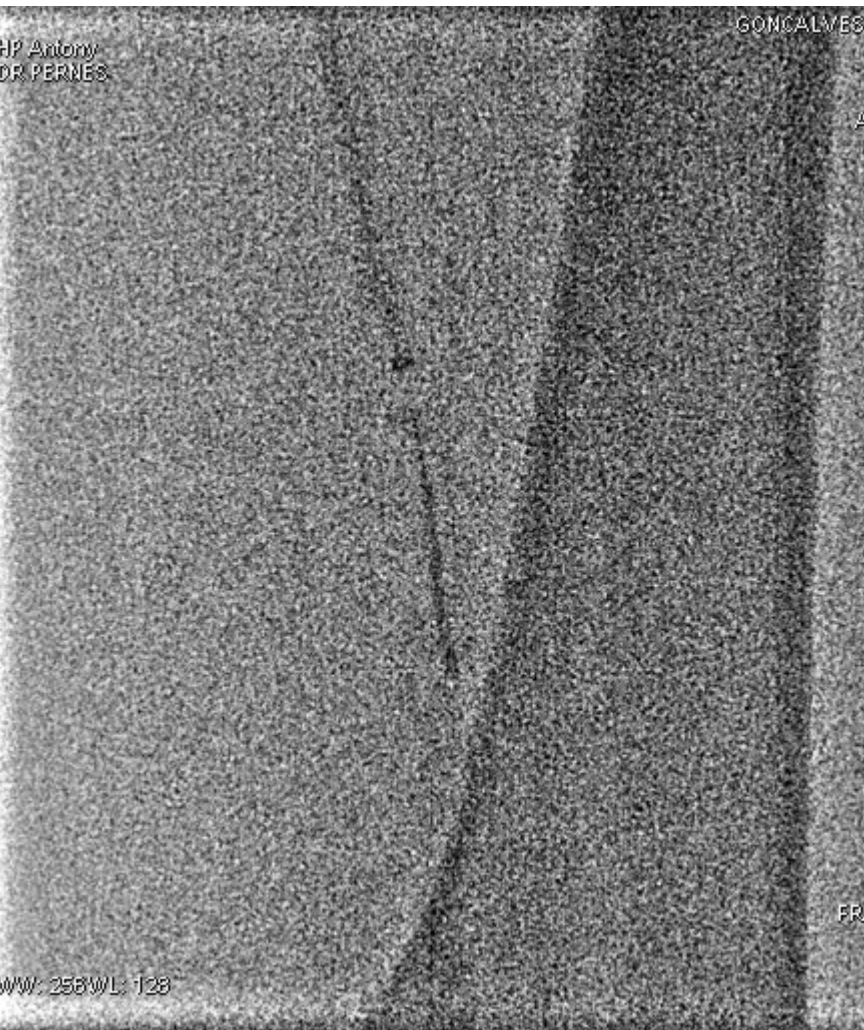
2 WEEKS LATER: LEFT SIDE

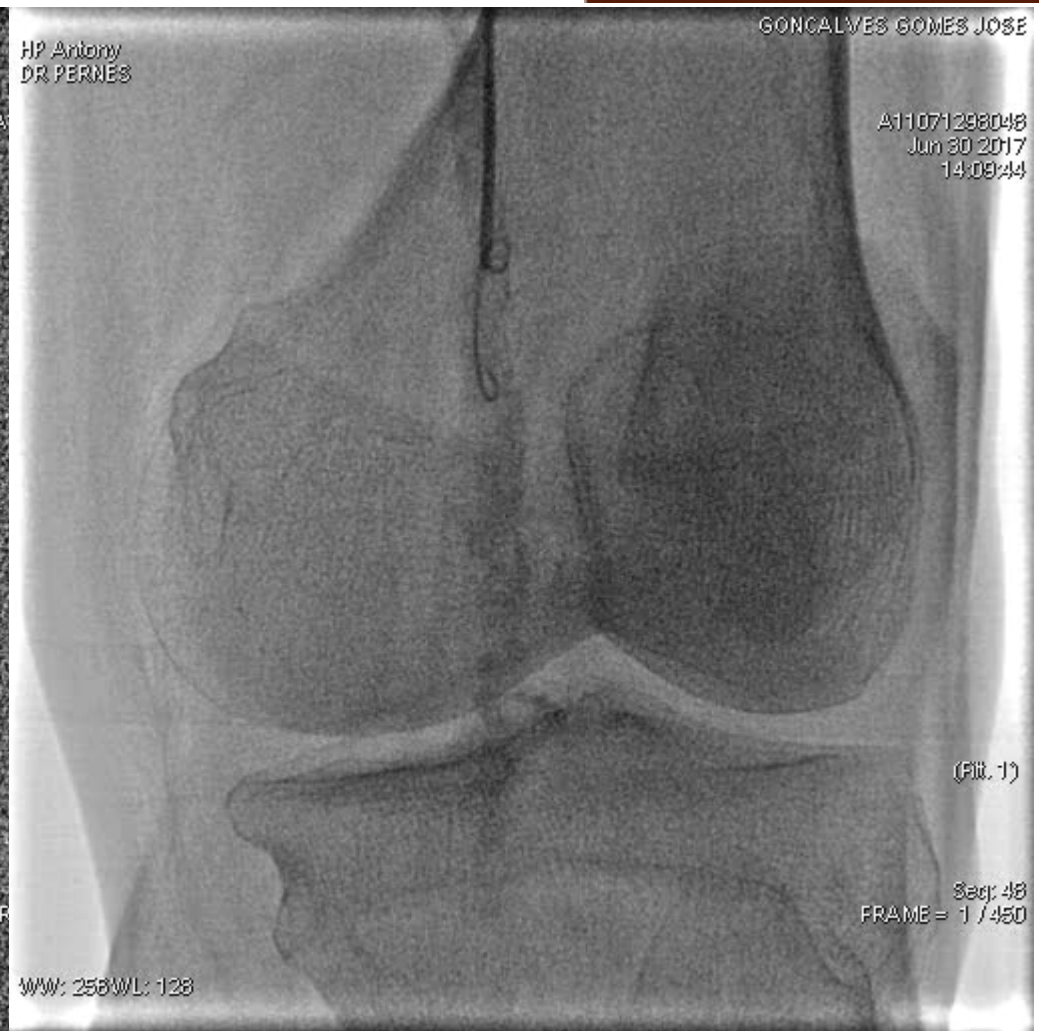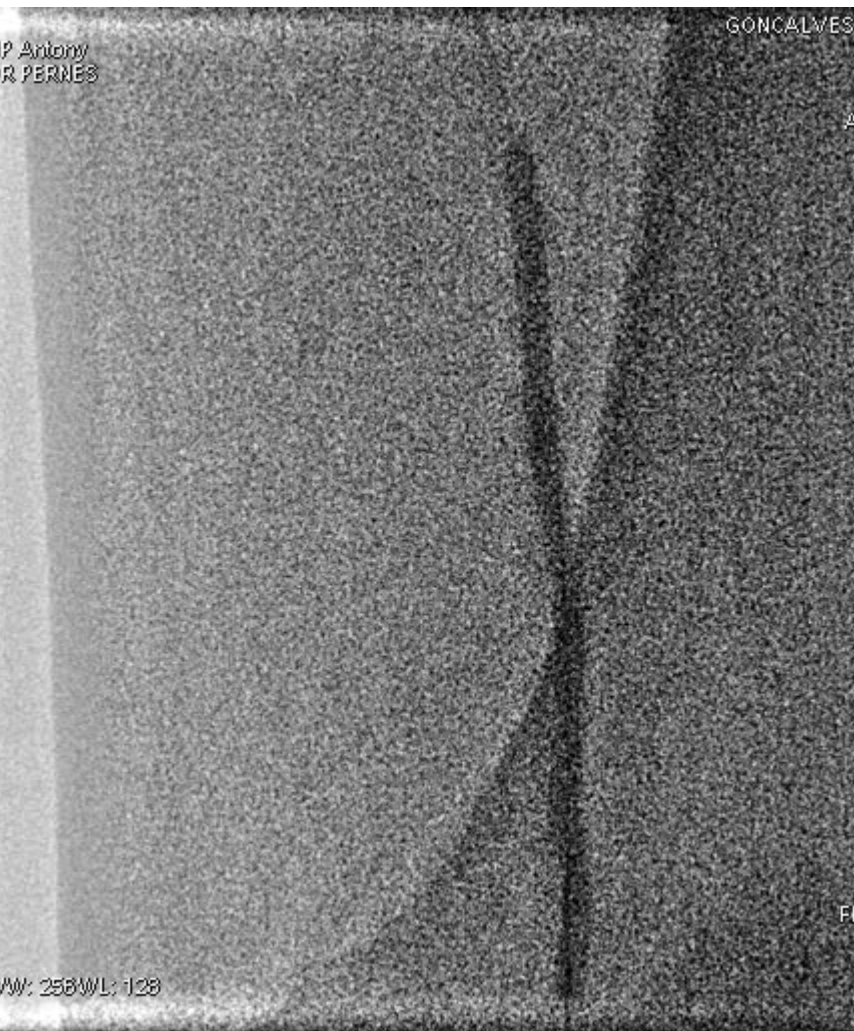


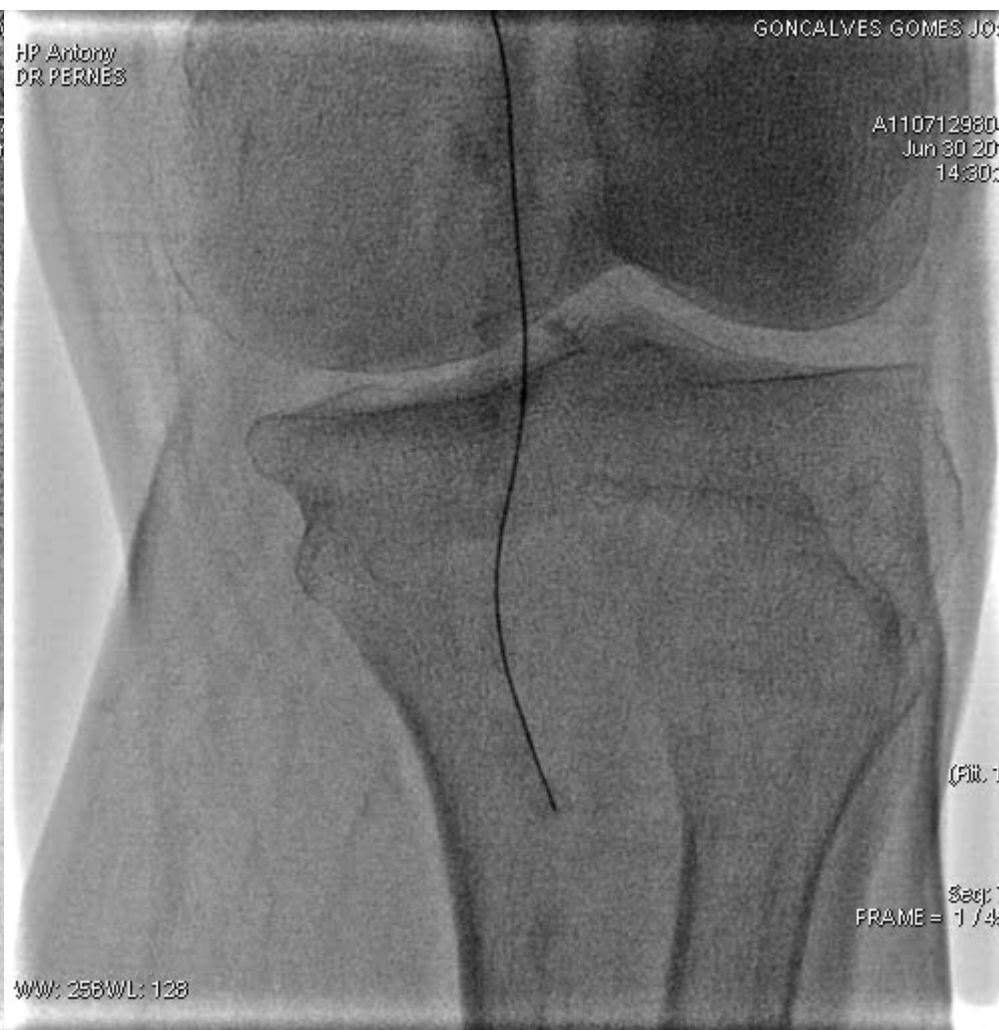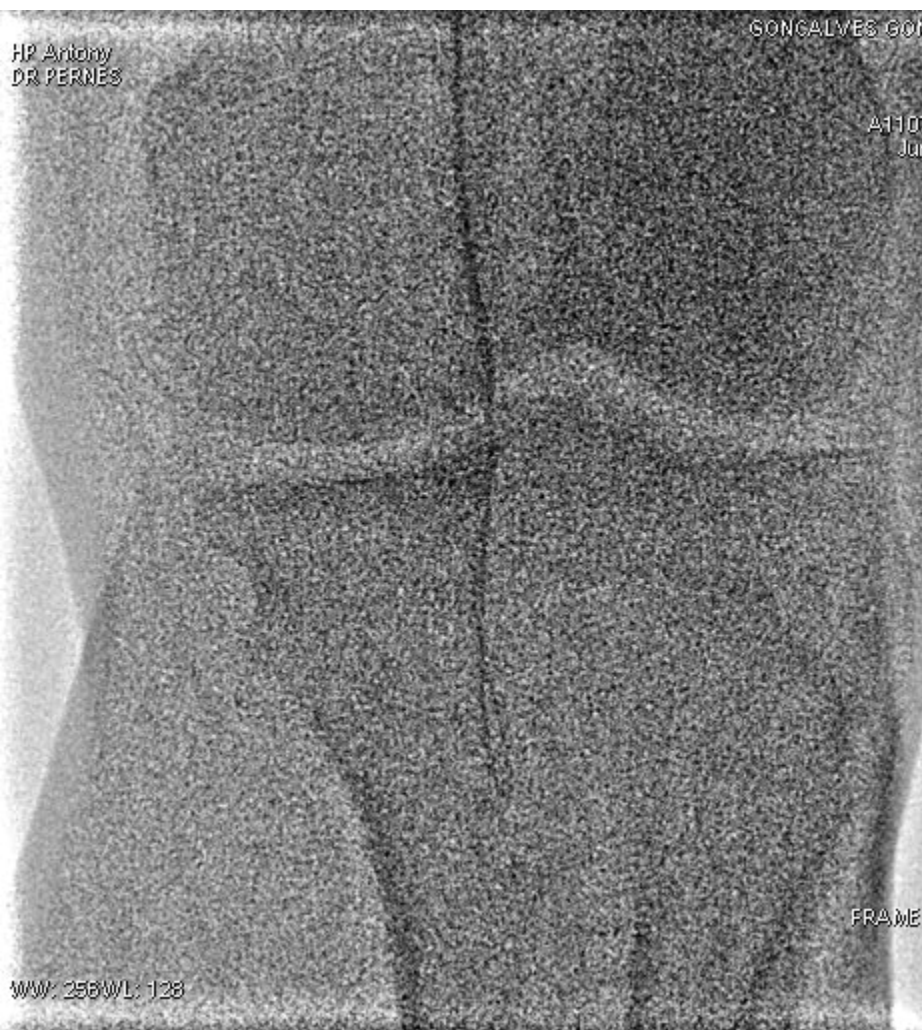ANTEGRADE APPROACH : 45 CM 6F SHEATH

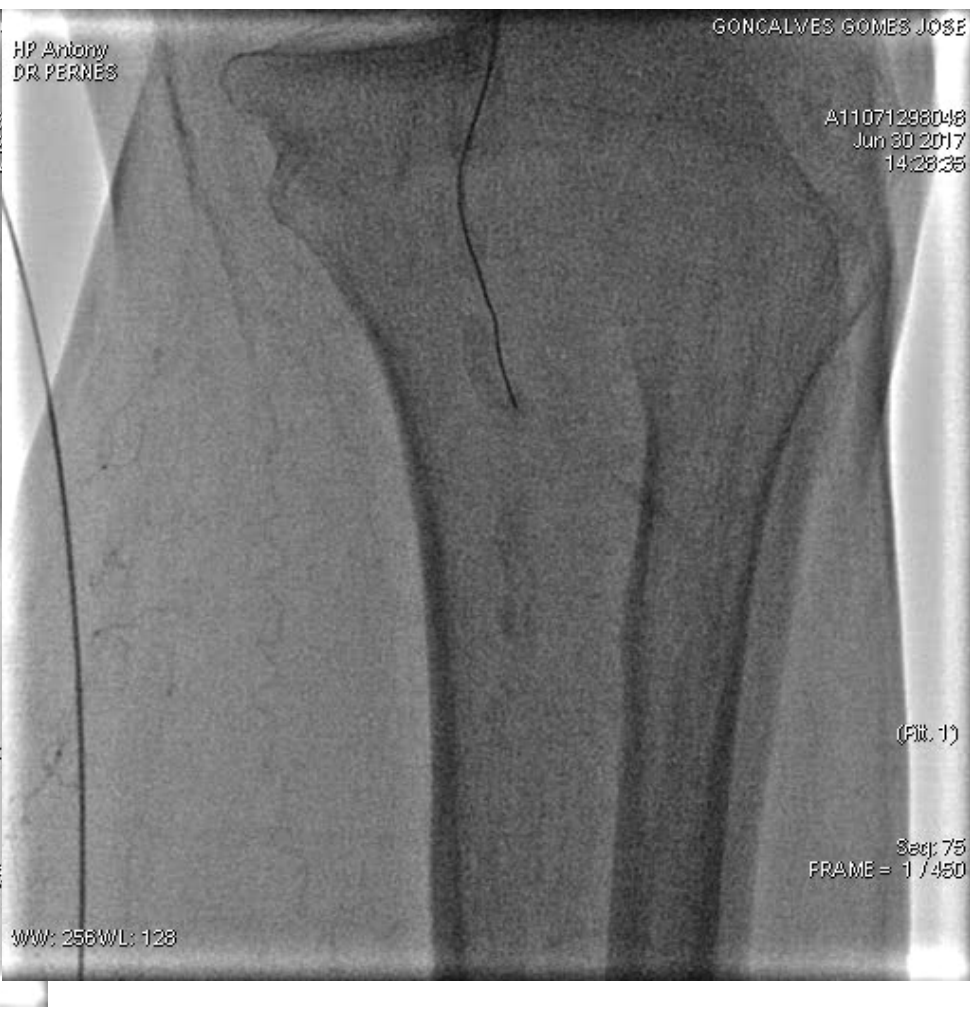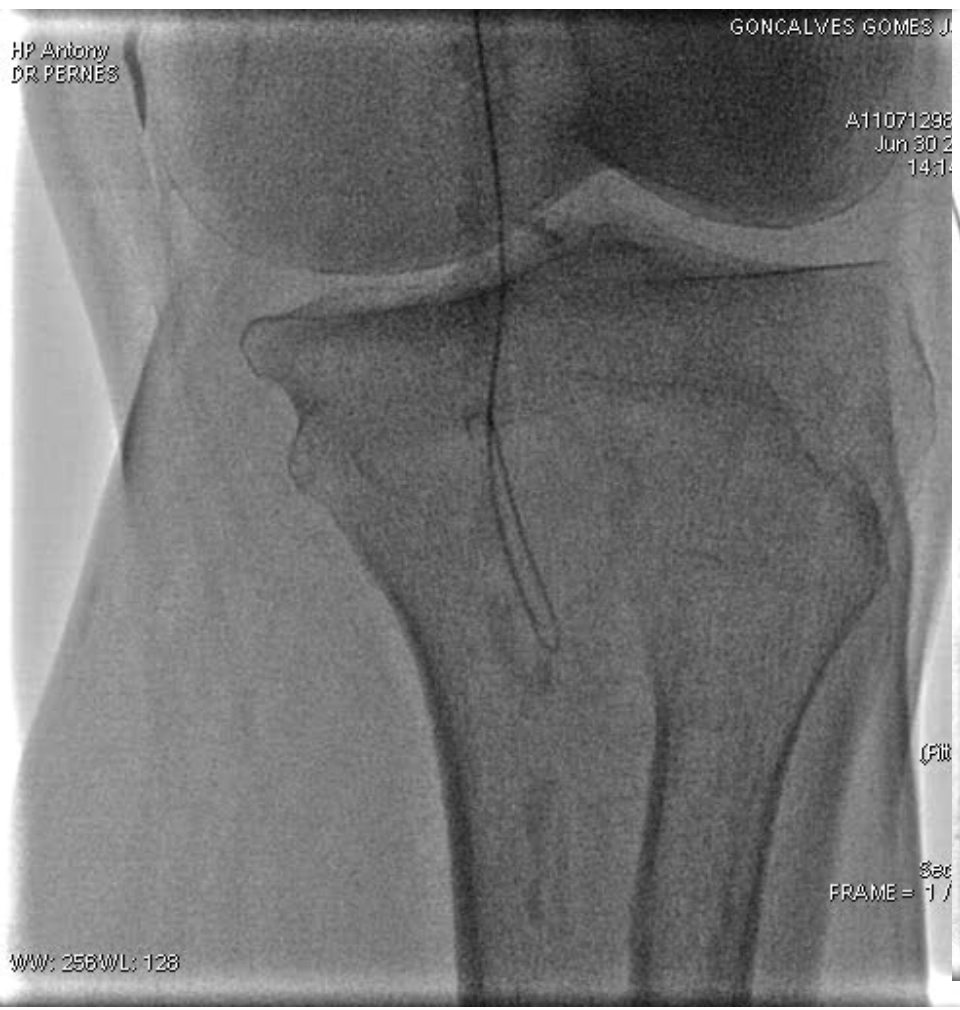- failure of INTRALUMINAL path despite dedicated 0.018 wires
- failure of EXTRALUMINAL intentionnal angioplastie with wires 0.018 et 0.035



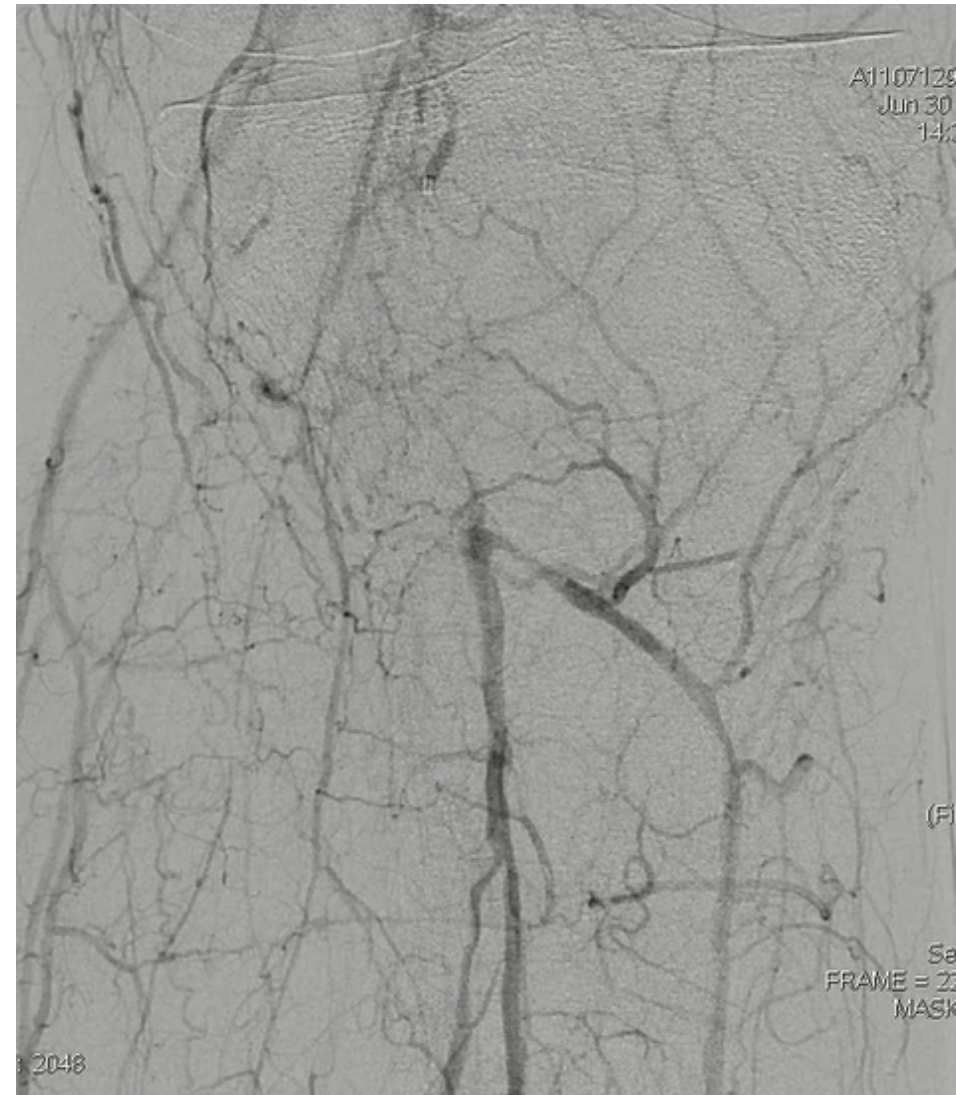
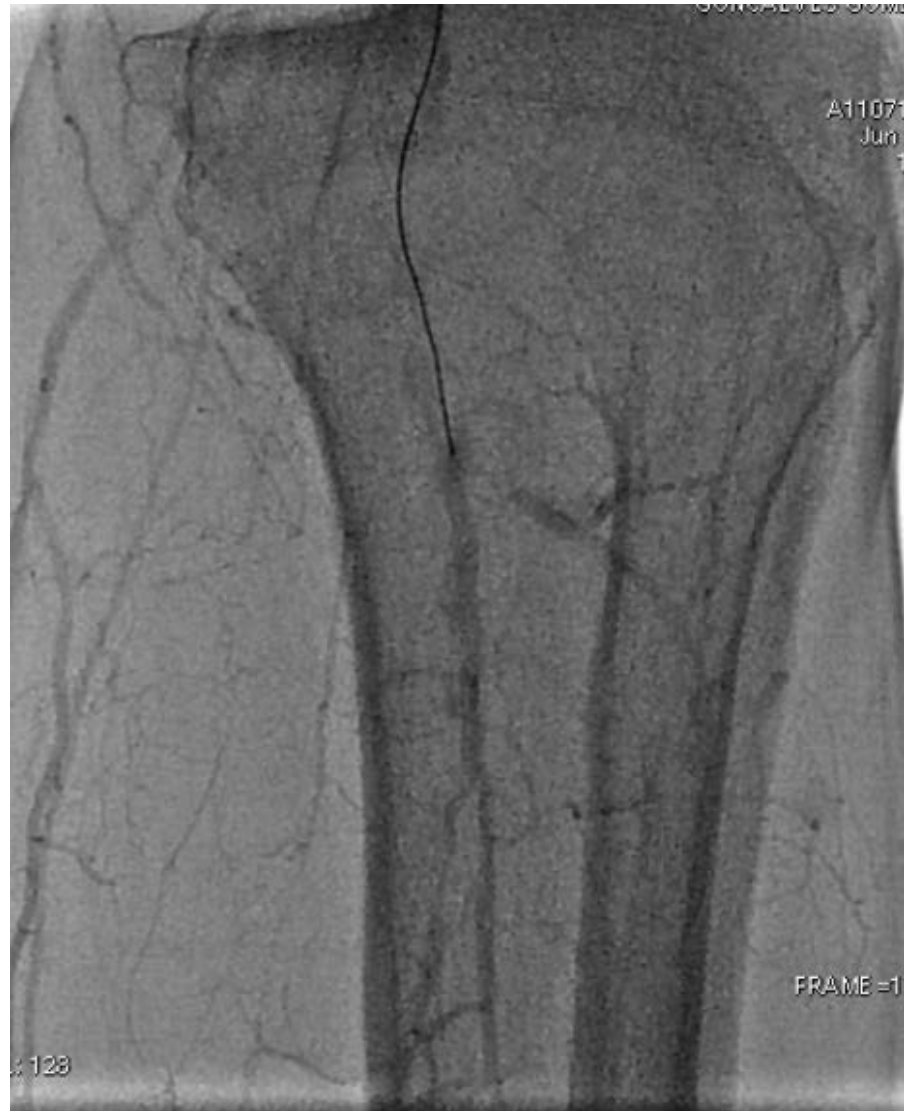





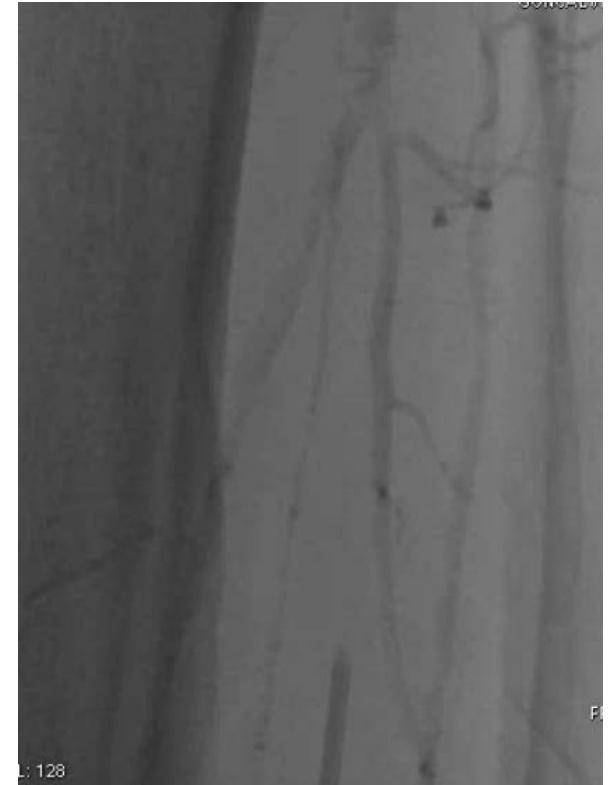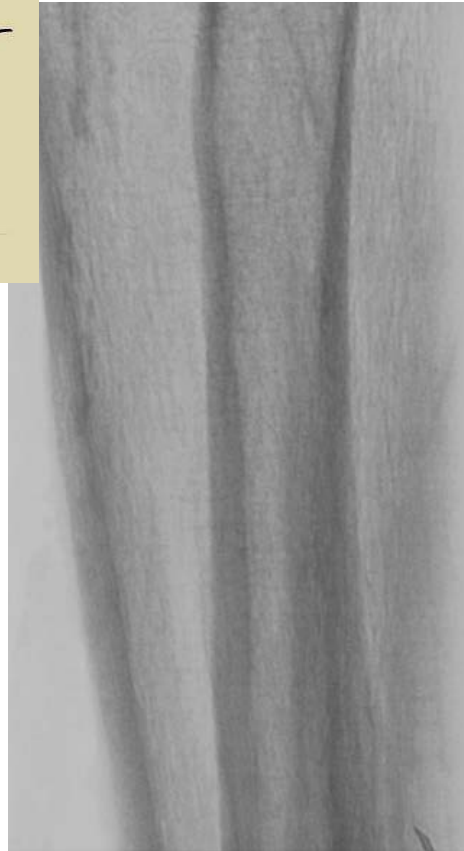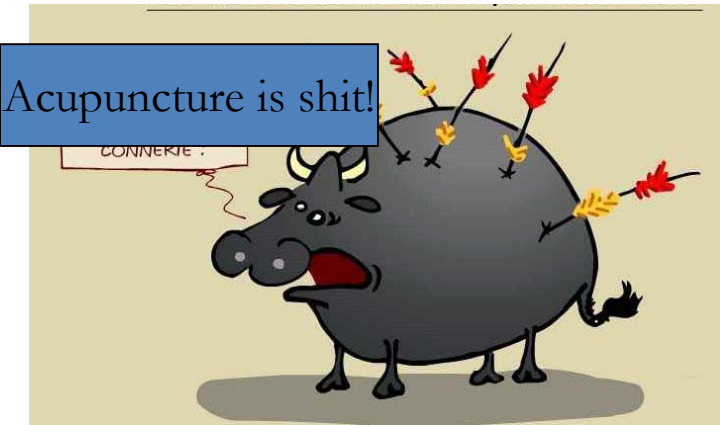


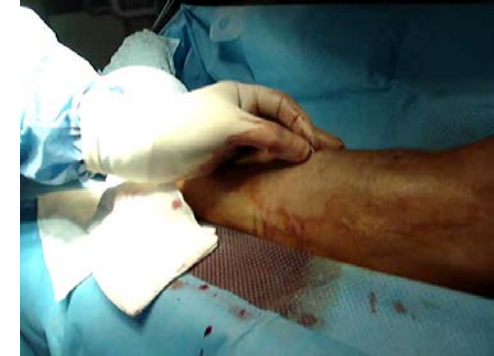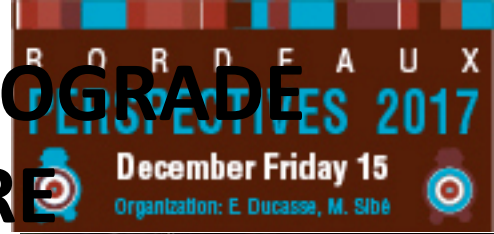STOP:1 HOUR

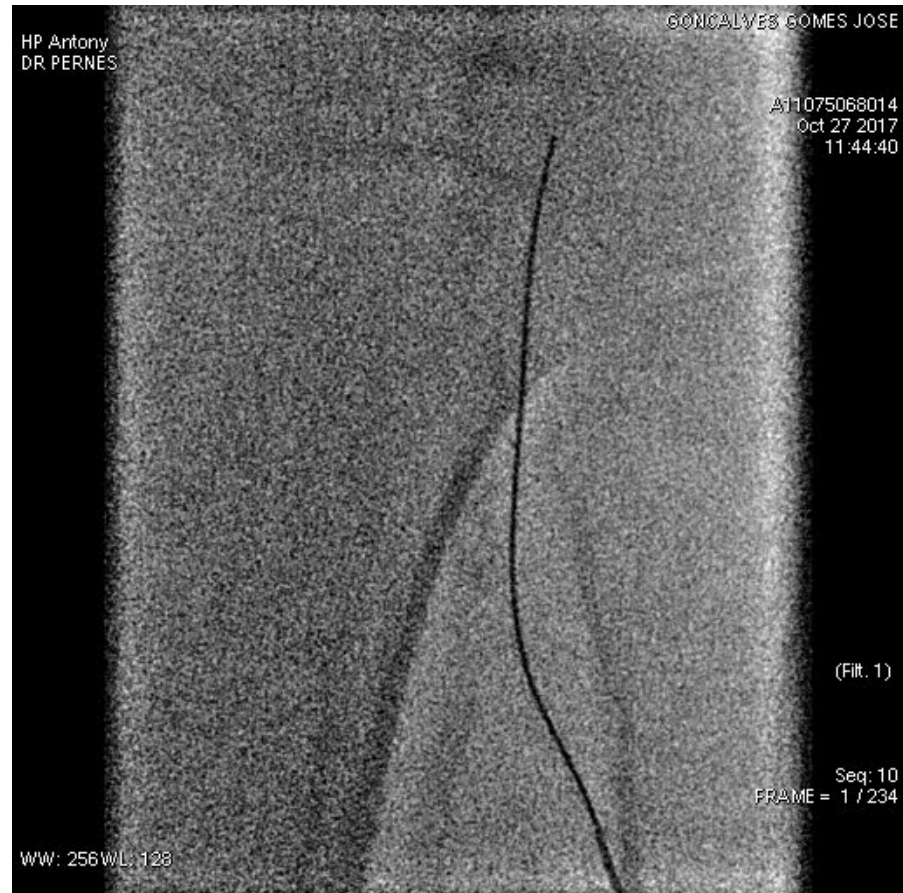


5 MONTHS LATER: ANTEGRADE + RETROGRADE ACCESS BY PERONEAL PUNCTURE

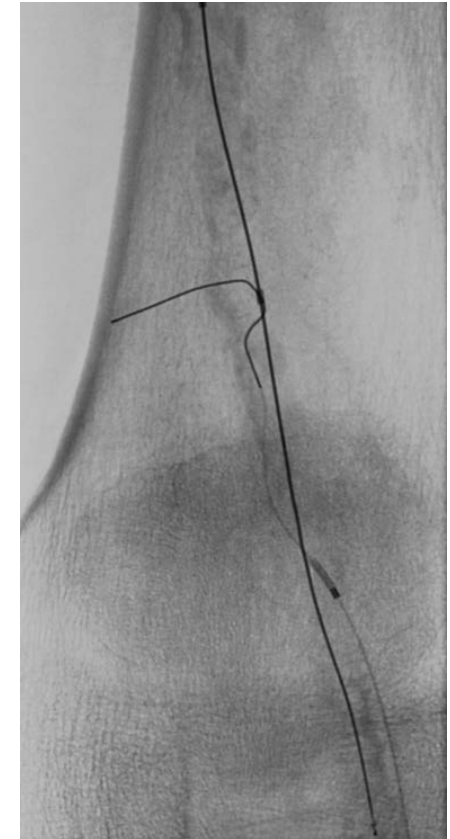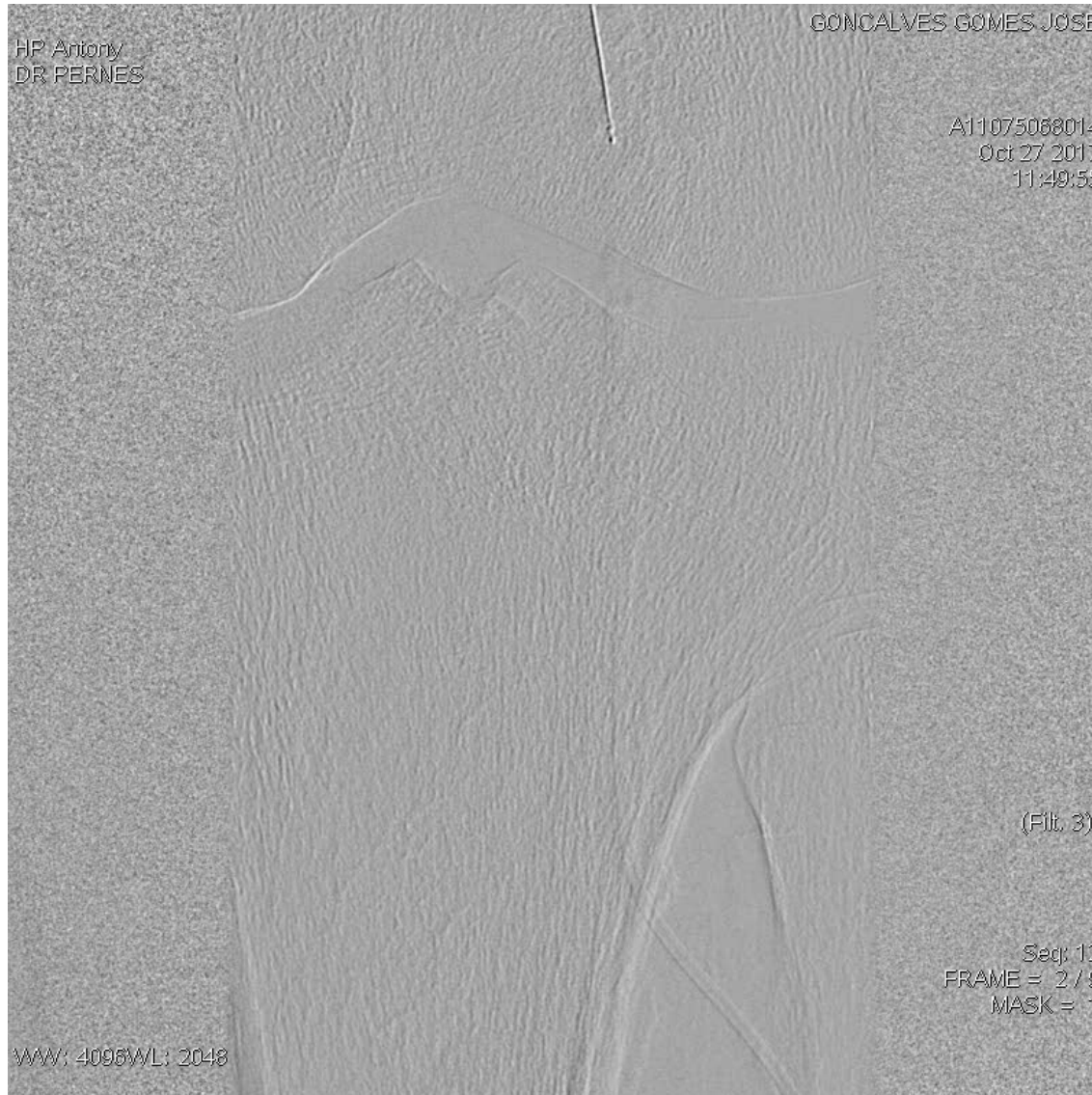
LE GROS NUL....



FINALLY: ANT TIB ARTERY ACCESS:OK(after catheterism of the vein...)



BUT QUICK STOP.....



HP Antony
DR PERNES

GONCALVES GOMES JOSÉ

A11075068014
Oct 27 2017
12:03:30

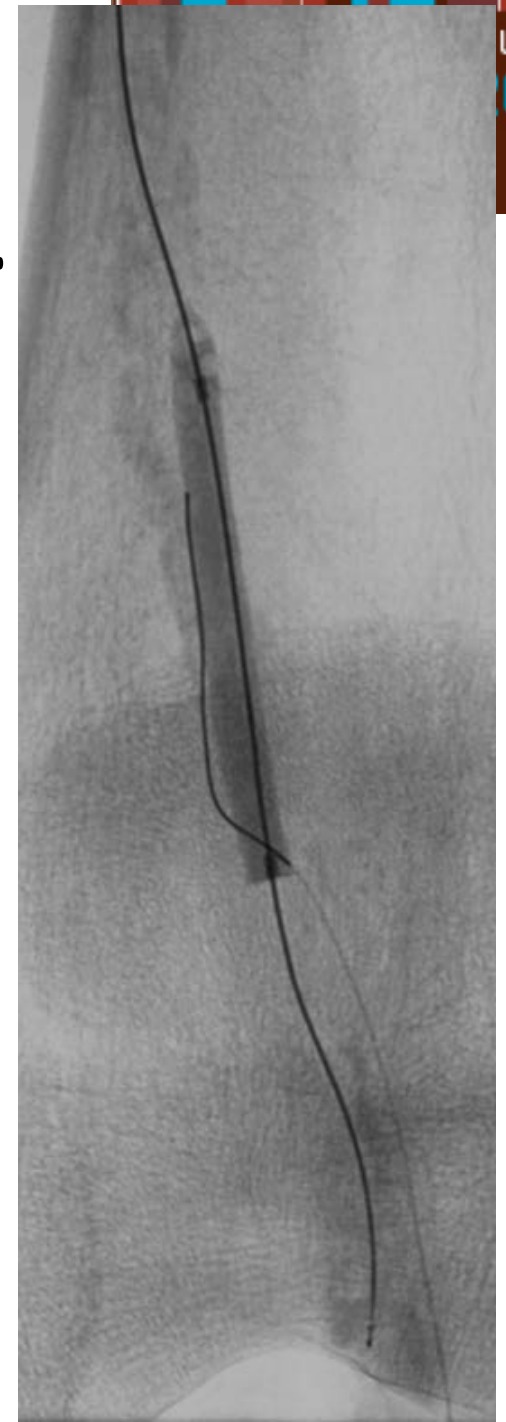
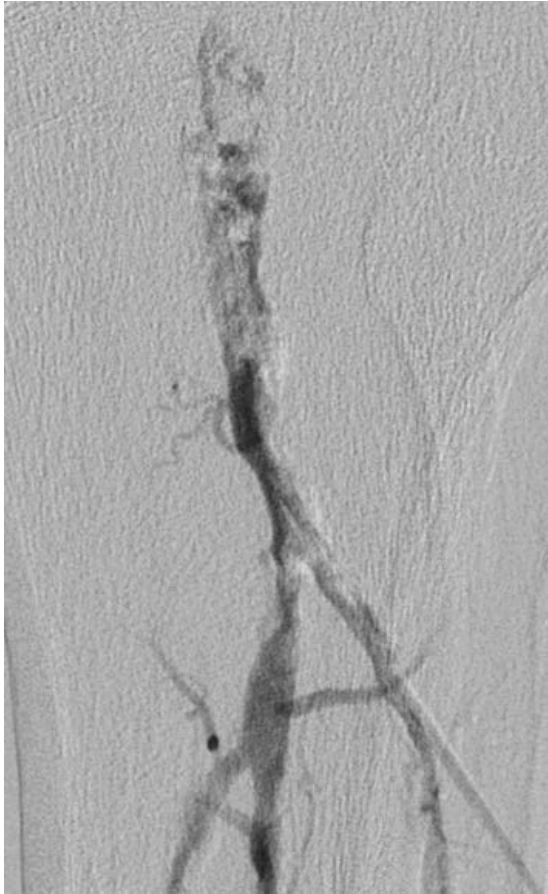

(Filt. 3)

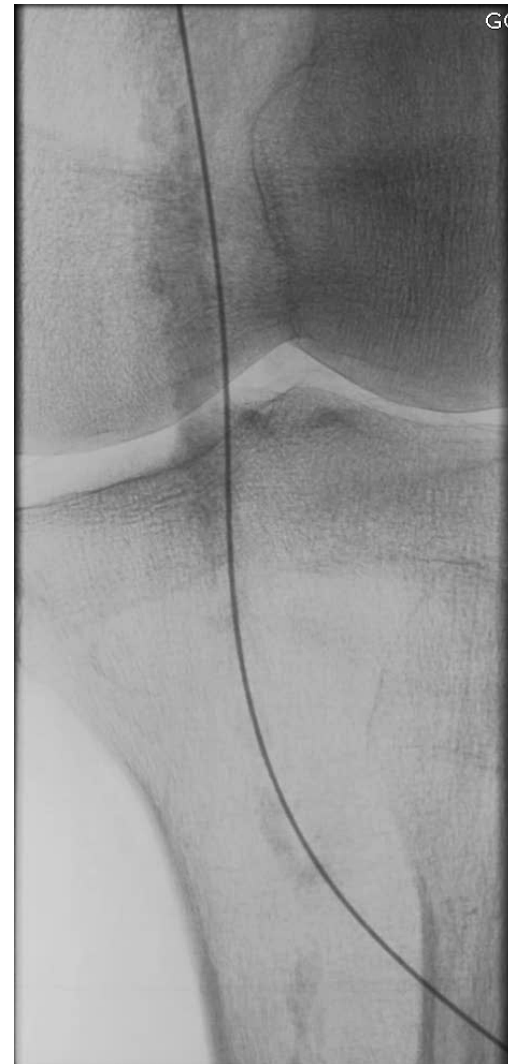Seq: 14
FRAME = 2 / 24
MASK = 1

WWW: 4096WL: 2048

CART PROCEDURE: FAILURE TO RE ENTER....



OLD SCHOOL: BOLIA RETROGRADE 0.035



HP Antony
DR PERNES

GONCALVES GOMES JOSE

A11075088014
Oct 27 2017
12:11:12

P O R D E A U X
PERSPECTIVES 2017
December Friday 15
Organization: E. Ducasse, M. Sibé



(Filt. 3)

Seq: 15
FRAME = 2 / 5
MASK = 1

WAW: 4098 WL: 2048

HP Antony
DR PERNES

GONCALVES GOMES JOSE

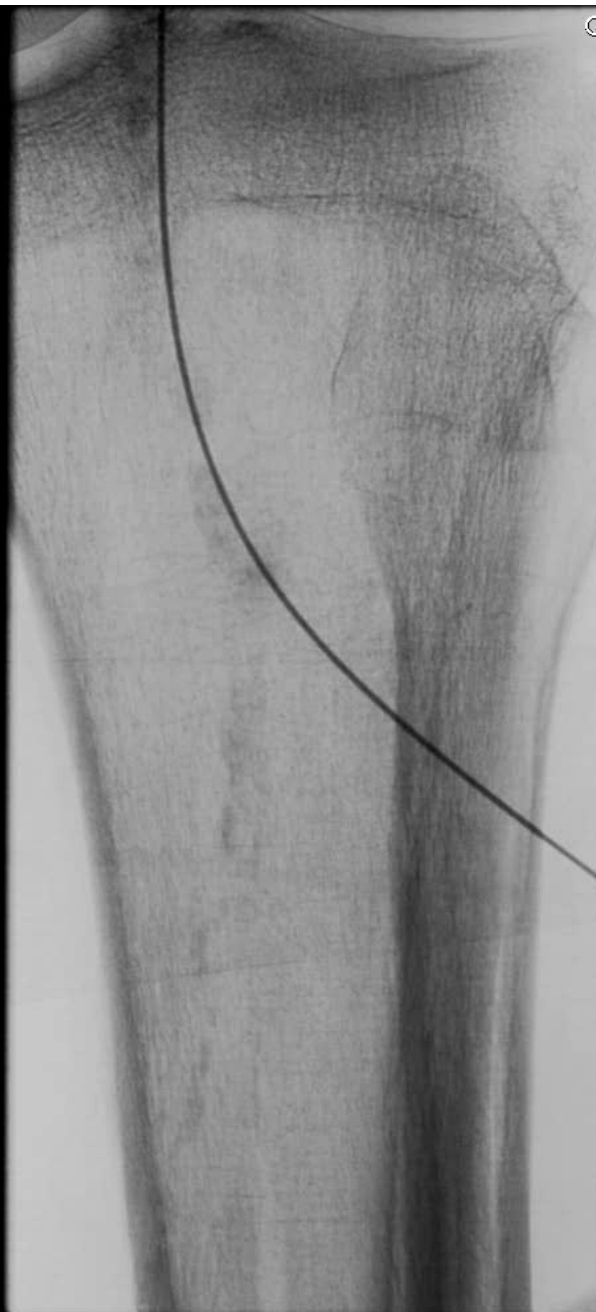R D E A U X
SPECTIVES 2017

December Friday 15

Organization: E. Ducasse, M. Sibé



A11075068014
Oct 27 2017
12:17:56



(Filt. 3)

Seq: 16
FRAME = 2 / 20

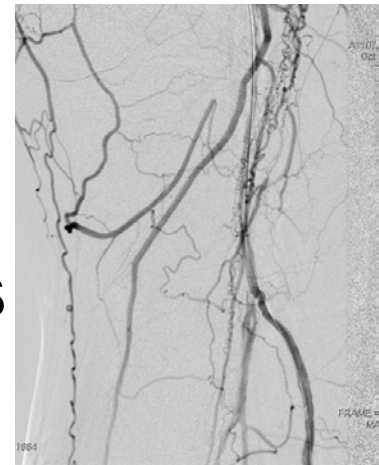
WW: 3282WL: 2294

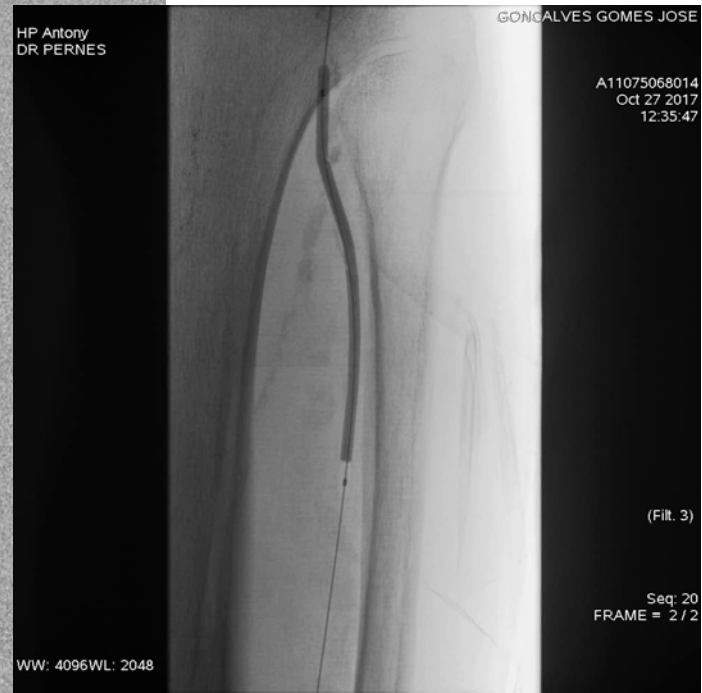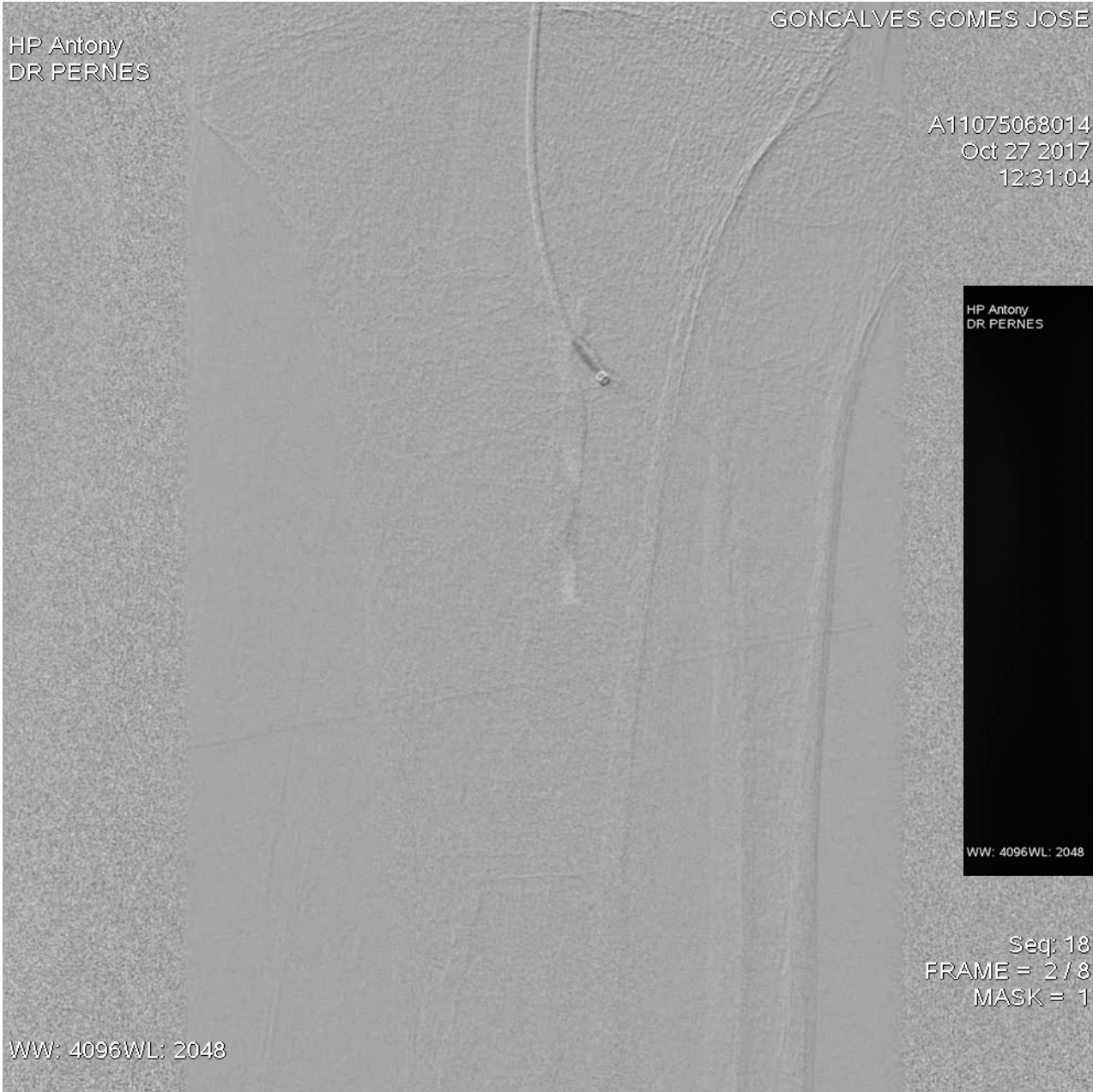
O.035 BOLIA WIRE (Terumo)

SUCCESS !!

- re-entry in the SFA and capture with a Lasso system
- Exchange for a long 0.018 Steel core wire (Abbott) on a 4F Quickcross catheter(Spectranetics)
- Inflation of a 3mm balloon,

**START OF THE TROUBLES:
extensive dissection to the distal arteries**





HP Antony
DR PERNES

GONCALVES GOMES JOSE

A11075068014
Oct 27 2017
12:41:27



(Filt. 3)

Seq: 22
FRAME = 2 / 17
MASK = 8

WW: 4096WL: 2048

HP Antony
DR PERNES

GONCALVES GOMES JOSE

D E A U X
CTIVES 2017
ber Friday 15
on: E. Ducasse, M. Sibé

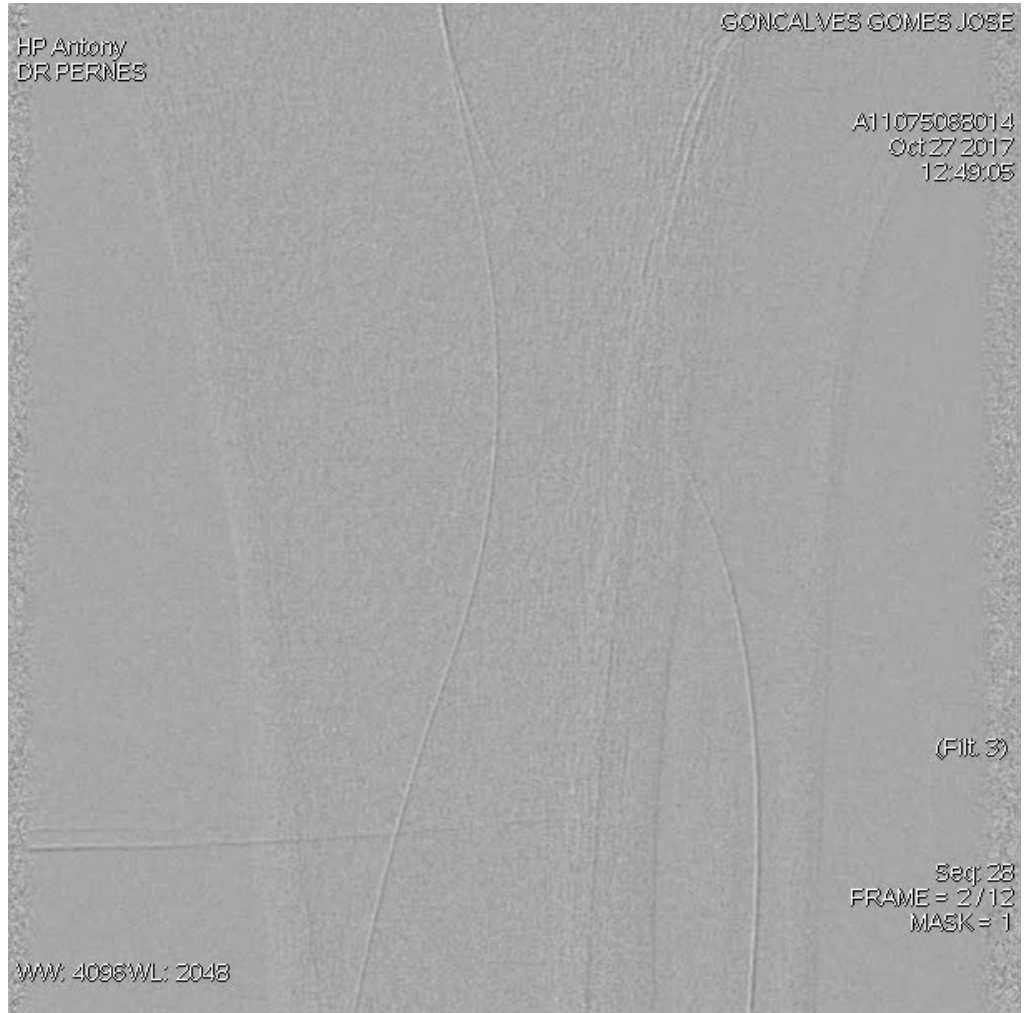A11075068014
Oct 27 2017
12:41:58

(Filt. 3)

Seq: 23
FRAME = 2 / 19
MASK = 8

WW: 3282WL: 2335

2^{ème} 0.014 WIRE IN THE DISSECTED TPT...BUT STIL SOME PROBLEMS



HP Antony
DR PERNES

GONCALVES GOMES JOSE

A11075088014
Oct 27 2017
12:58:35

(Fit. 3)

Seq: 29
FRAME = 2 / 14
MASK = 4

WWW: 4098/WL: 2048

HP Antony
DR PERNES

GONCALVES GOMES JOSE

A11075068014
Oct 27 2017
13:03:27

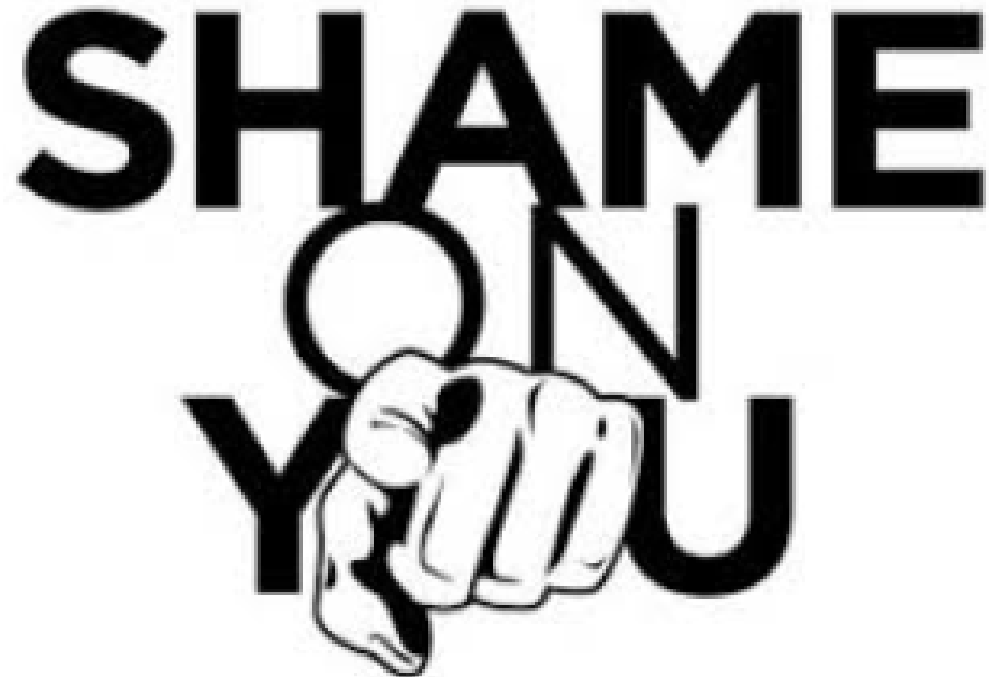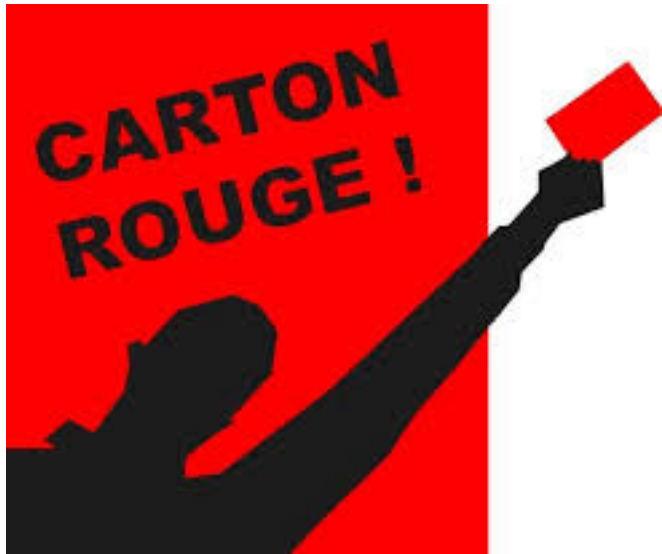(Filt 3)

Seq: 32
FRAME = 2 / 16
MASK = 1

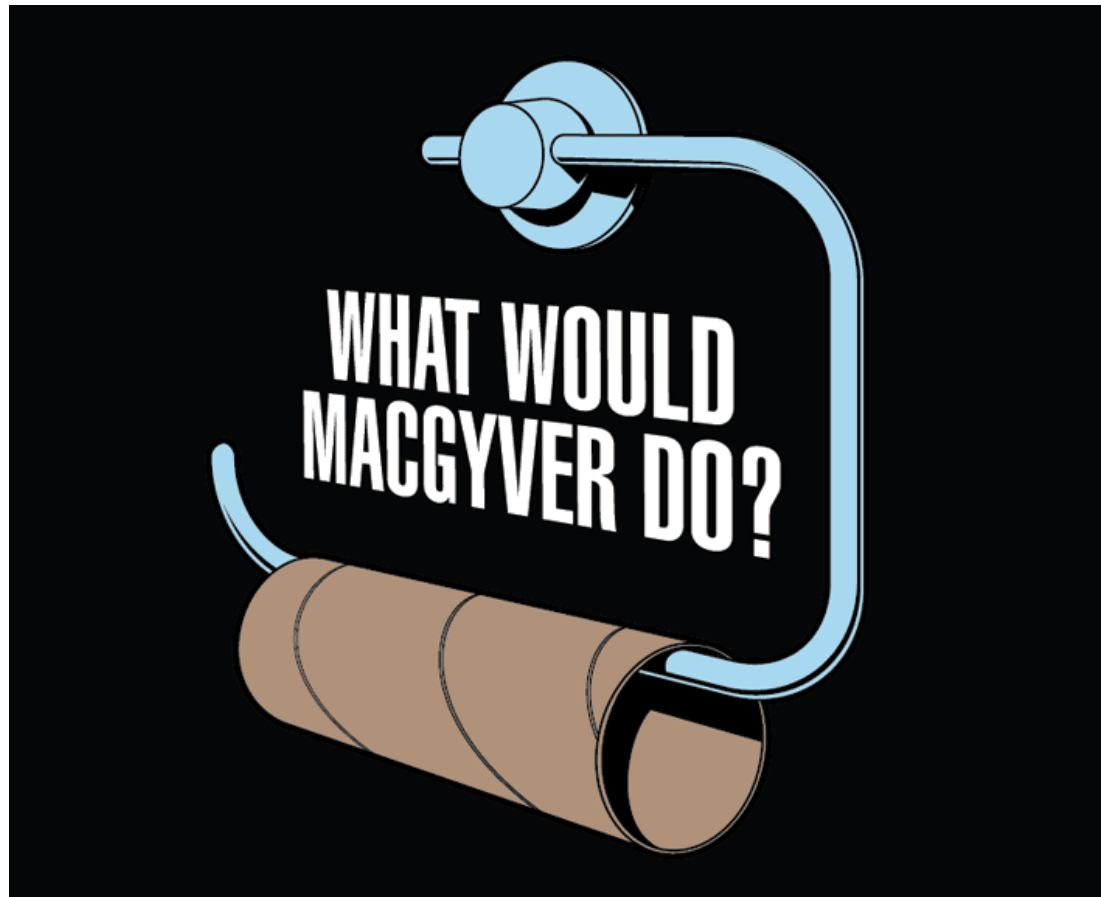WWW: 4096 WL: 2048

Explanations:

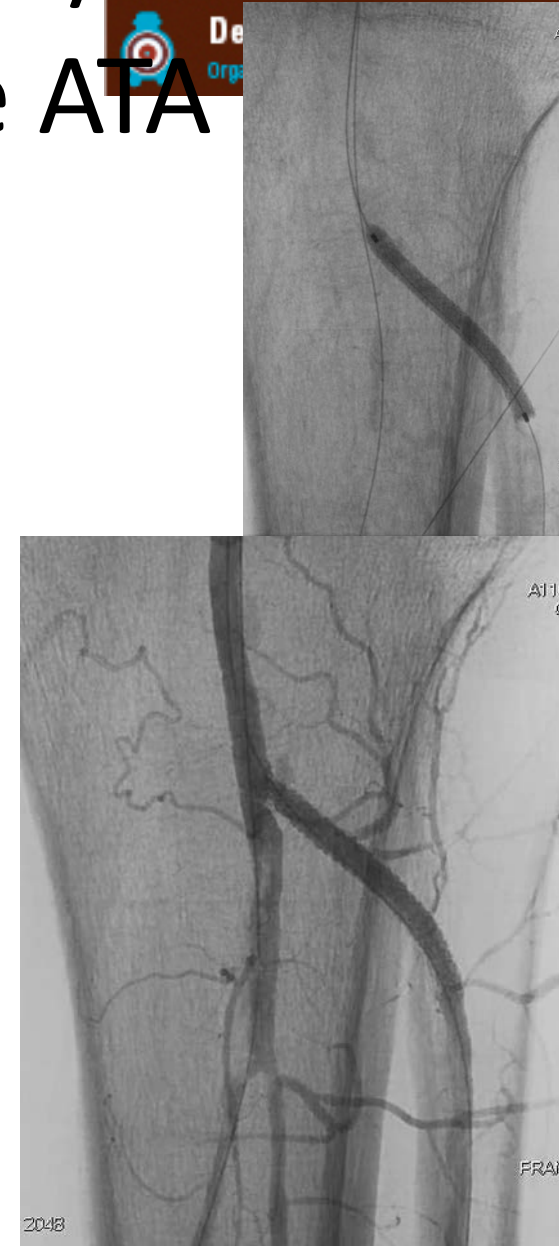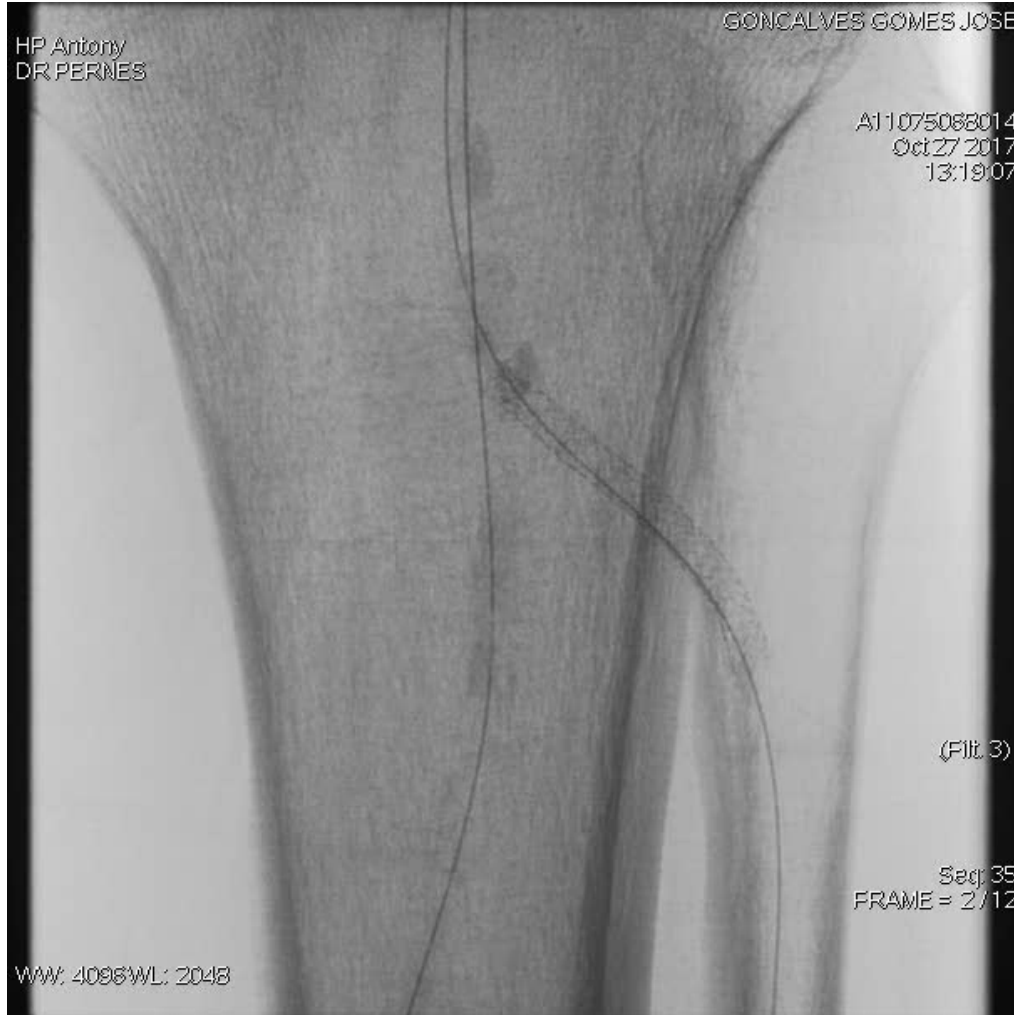High probability of catheterism of the false channel created by the attempts of extraluminal recanalization from the antegrade approach



**When you are in TROUBLE...
try to manage by yourself...**



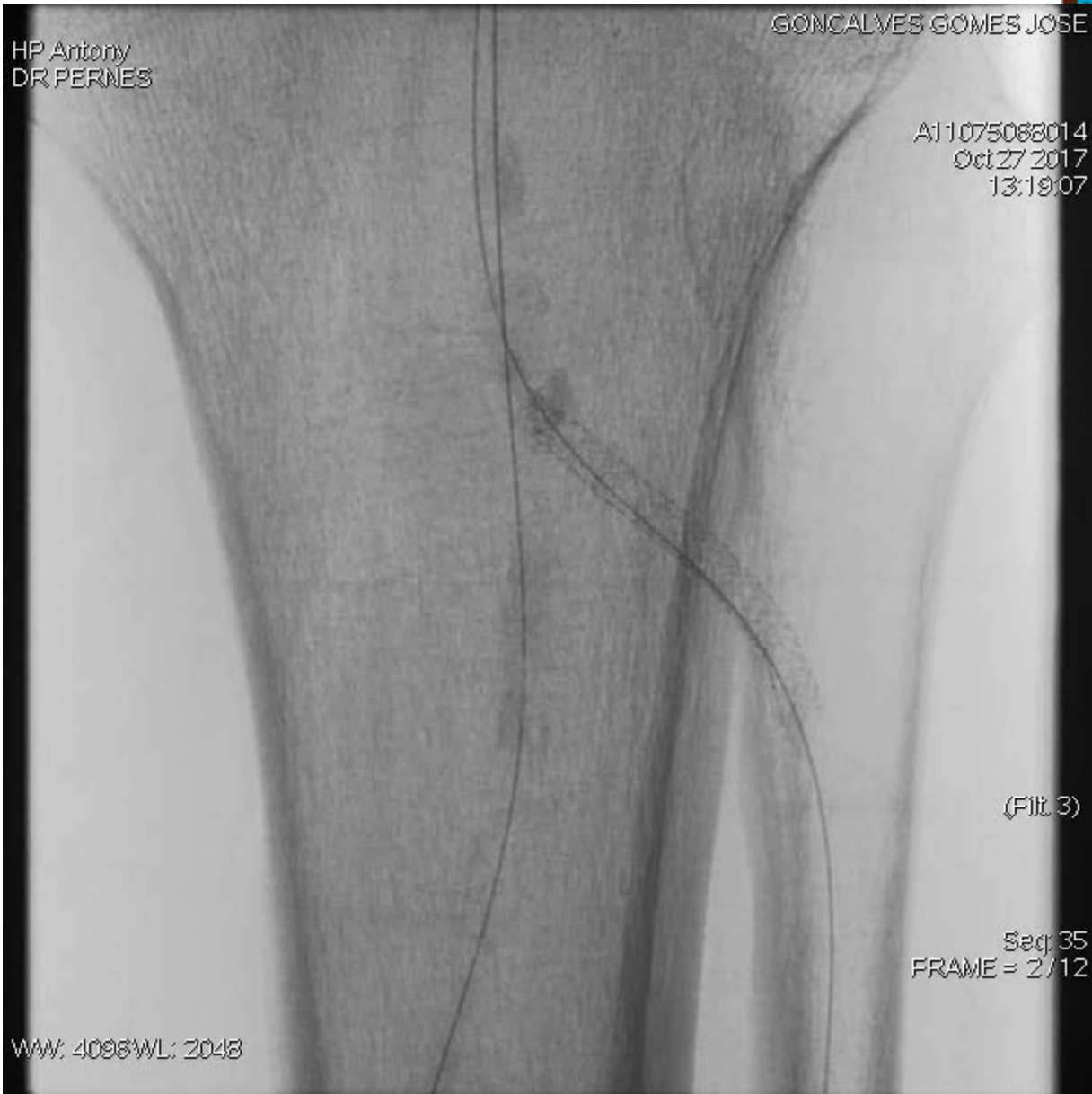After X balloon inflations , 3.5/38 mm DES (X-science) in the ATA



GONCALVES GOMES JOSE

HP Antony
DR PERNES

A11075088014
Oct 27 2017
13:19:07



(Filt 3)

Seq: 35
FRAME = 2 / 12

WWW: 4096\WL: 2048

then insertion of a SUPERA STENT(5.5/120)



HP Antony
DR PERNES

GONCALVES GOMES JOSE

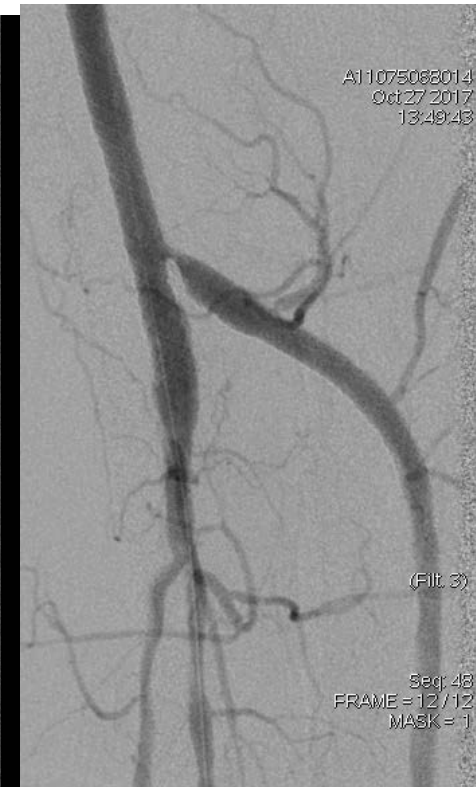
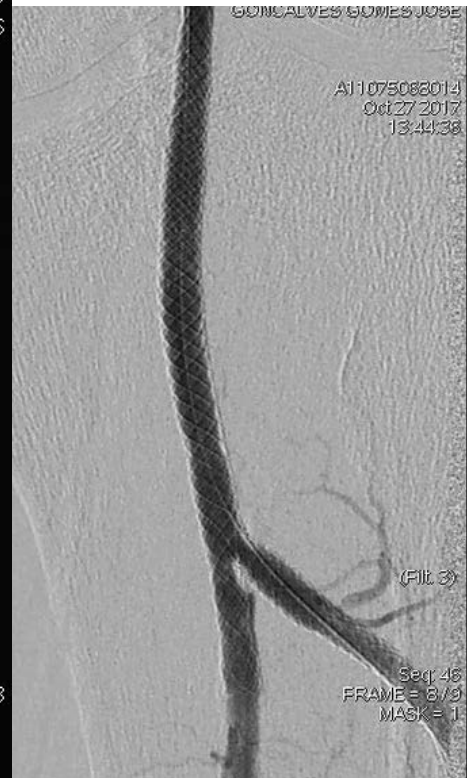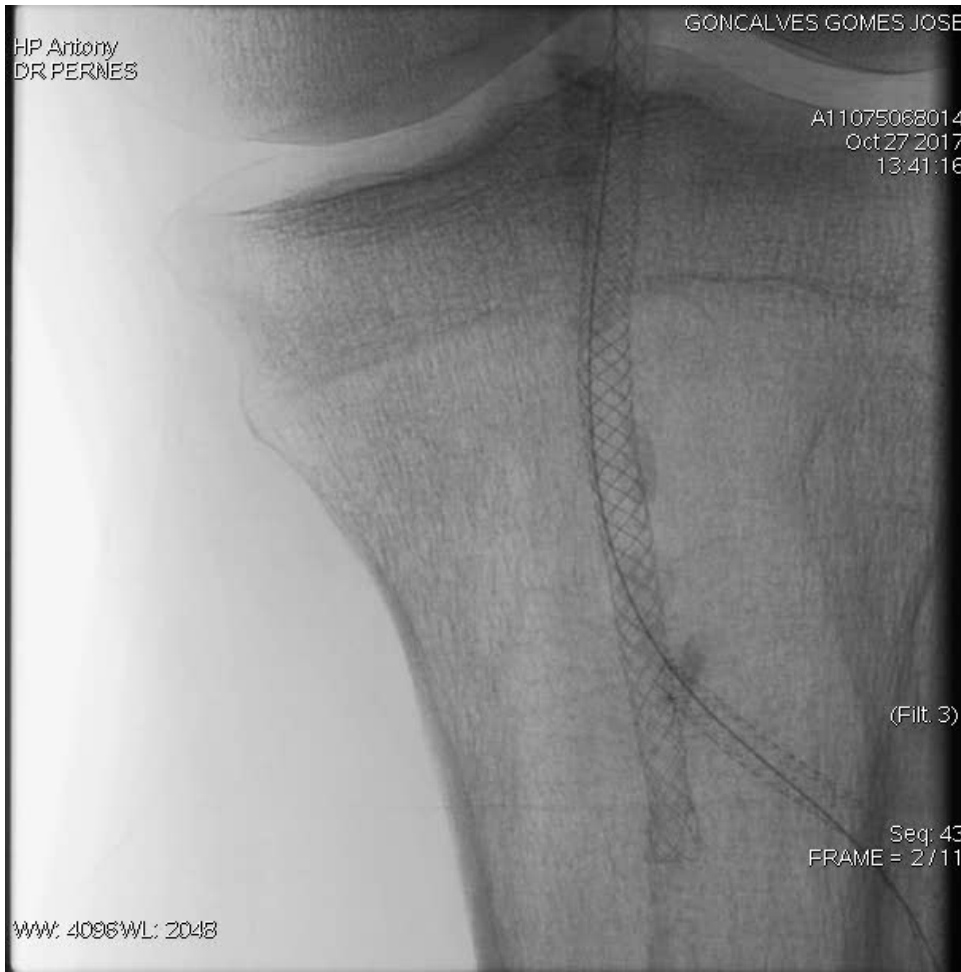A11075088014
Oct 27 2017
13:33:33

(Filt 3)

Seq: 38
FRAME = 2 / 13
MASK = 1

WWW: 4096WL: 2048

SHIFTING of the plaque in the TPT Alternative inflations of BTK balloons



HP Antony
DR PERNES

GONCALVES GOMES JOSE

A11075088014
Oct 27 2017
13:35:13

(Filt 3)

Seq: 41
FRAME = 2 / 11
MASK = 4

WAW: 4096WL: 2048

B O R D E A U X
PERSPECTIVES 2017
December Friday 15
Organization: E. Ducasse, M. Sibé



HP Antony
DR PERNES

GONCALVES GOMES JOSE

A11075088014
Oct 27 2017
13:44:38

(Filt 3)

Seq: 48
FRAME = 2 / 9
MASK = 1

WWW: 4086WL: 2048

HP Antony
DR PERNES

GONCALVES GOMES JOSE

A11075068014
Oct 27 2017
13:48:19

O R D E A U X
PERSPECTIVES 2017
December Friday 15
Organization: E. Ducasse, M. Sibé

(FIT. 1)

Seq: 47
FRAME = 1 / 33

WW: 256 WL: 128

HP Antony
DR PERNES

GONCALVES GOMES JOSE

O R D E A U X
PERSPECTIVES 2017

December Friday 15

Organization: E. Ducasse, M. Sibé



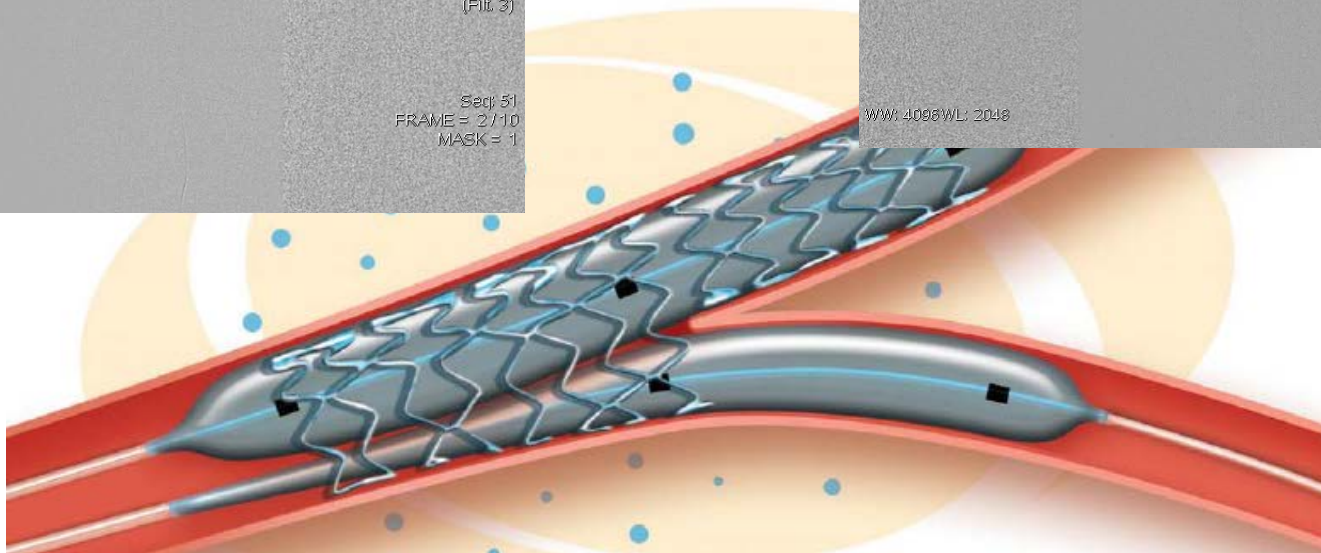
A11075068014
Oct 27 2017
13:57:37

(Filt. 3)

Seq: 50
FRAME = 2 / 3

www: 4096WL: 2048

KISSING WITH MONORAIL CORONARY 3 MM BALLONS. FINAL RESULT



HP Antony
DR PERNES

GONCALVES GOMES JOSE D R D E A U X

PERSPECTIVES 2017

December Friday 15

Organization: E. Ducasse, M. Sibé



A11075088014
Oct 27 2017
13:59:42

(Flt. 3)

Seq: 51
FRAME = 2 / 10
MASK = 1

WWW: 4096WL: 2048

HP Antony
DR PERNES


GONCALVES GOMES JOSE

A11075088014
Oct 27 2017
14:00:03

(Filt 3)

Seq: 52
FRAME = 2 / 14
MASK = 1

WWW: 4098 WL: 2048



HP Antony
DR PERNES

GONCALVES GOMES JOSE R D E A U X

PERSPECTIVES 2017

September Friday 15

Organization: E. Ducasse, M. Sibé

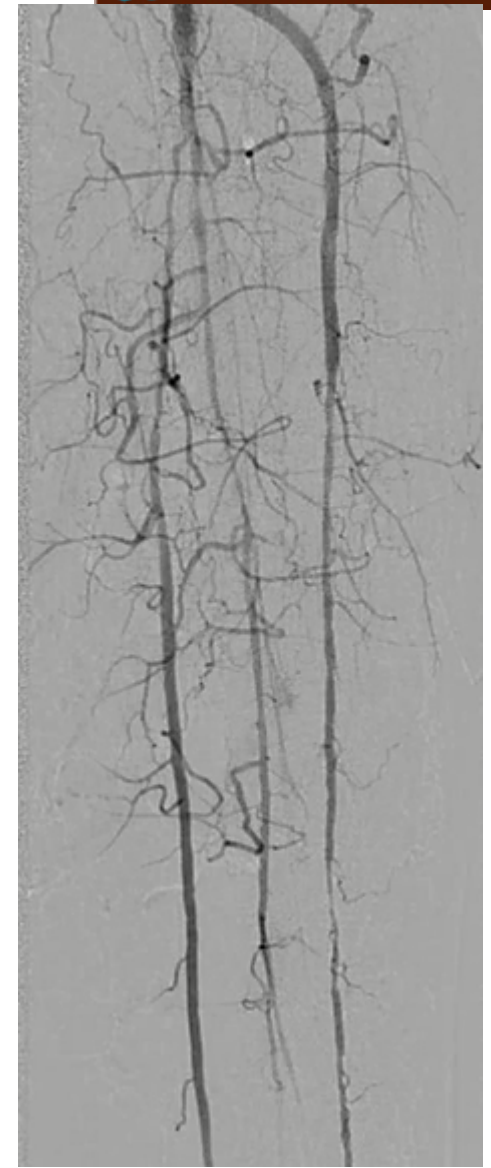
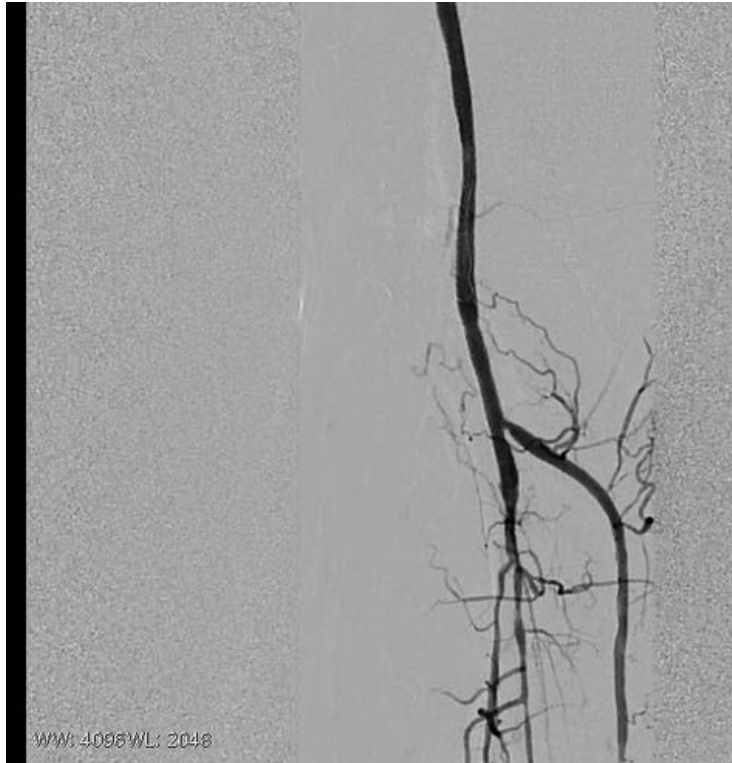
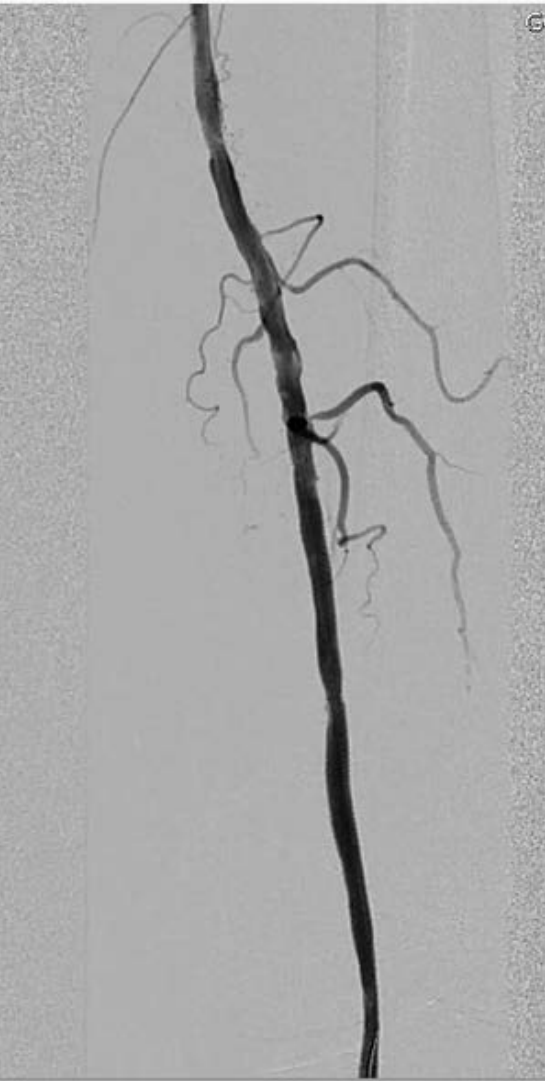
A11075068014
Oct 27 2017
14:00:24

(Filt. 3)

Seq: 53
FRAME = 2 / 16
MASK = 1

WV: 4096 WL: 2048



LESSONS

- Heavy calcified long occlusion involving the bifurcation: **ALWAYS an issue**
- The good timing for retrograde approach not easy: not to much insistance when antegrade acces fails, **caution with PIER** (but eternal thanks to A. Bolia!!!)
- Ponction of the fibular artery **often tricky**
- **Retrograde PIER technique with 0.035 hydrophilic dedicated wire possible**
- **Value of T Stenting and Kissing technique** with coronary devices (0.014 Wires, Monorail ballons and Stent)



.... Think to these CONFUCIUS and BOUDDHA proverbs:

« Experience is like a lantern hanging
on your back that lights only the path
you have already done »...



« If the problem has a solution , its
not necessary to worry but if there is
no solution, to worry will not change
anything... »



MY PROVERB!!!!

IF YOU ARE IN THE SHIT, UP TO THE NECK....



DO NOT PUT YOUR HEAD DOWN...

FINAL TIPS AND TRICKS.. FOR MAXIME ET ERIC

