

Bordeaux Perspectives 2017

« Merci Docteur ! »

Five years in the life of Mister T.

by Jean-Baptiste Bocquel

Vascular Surgery - Clinique HGO LORIENT

in August 2011

a 73 years old man

good health

background of abdominal surgery

AAA

in August 2011

a 73 years old man

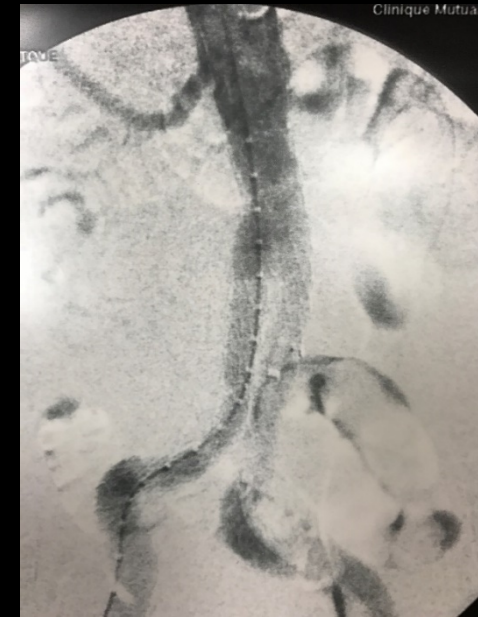
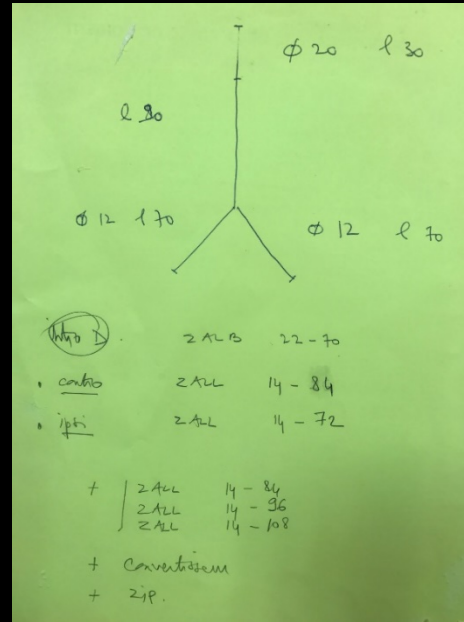
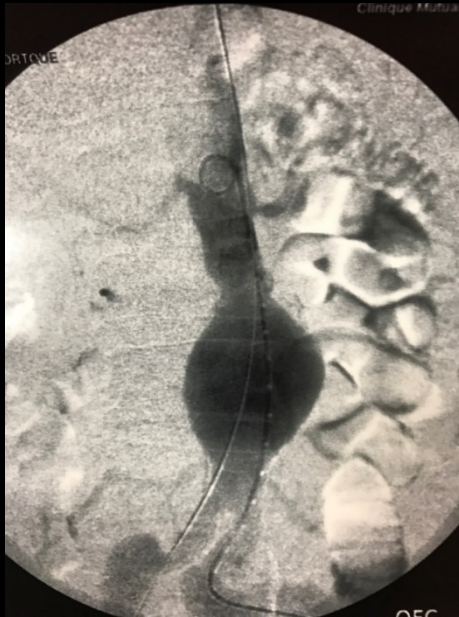
good health

background of abdominal surgery

AAA

→ EVAR

in August 2011



EVAR

in September 2013

in September 2013

right leg claudication...

in September 2013

« *LA TOTALE LOUSE* » *(french phrase)*

in September 2013

« LA TOTALE LOUSE » (french phrase)

verb « to lose »

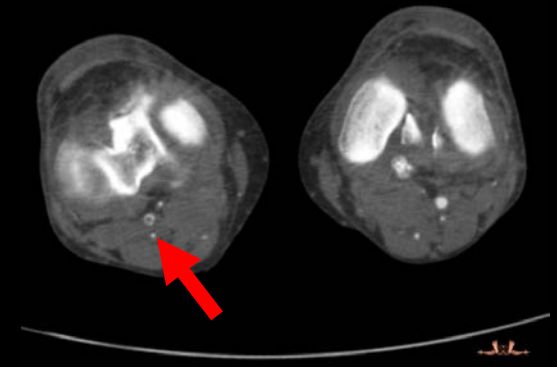
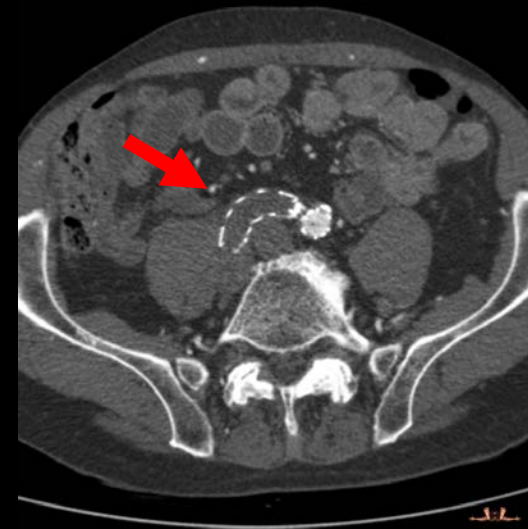
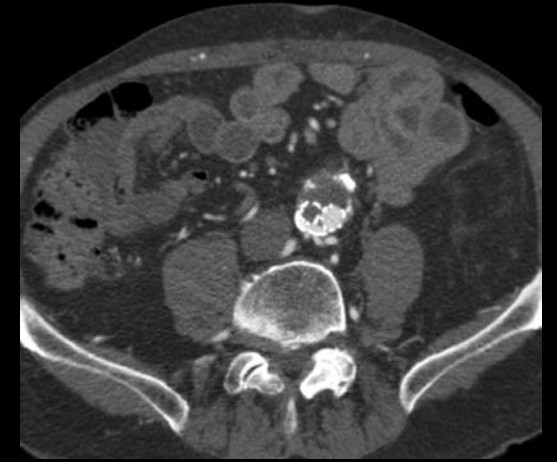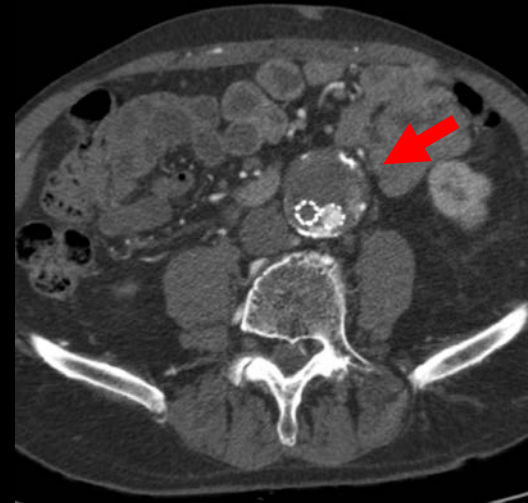
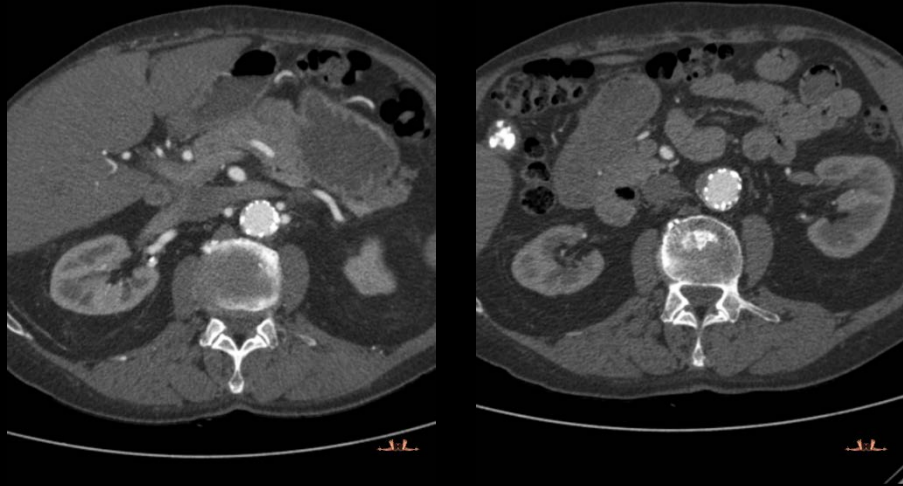
loss, defeat, failure, ruin

absolute bad luck

big shame

profound humiliation

in September 2013



*Right popliteal embolism
Right iliac leg thrombosis
Type II endoleak*

in September 2013

bearable limb ischemia

type II endoleak with enlargement

 *priority to the leak*

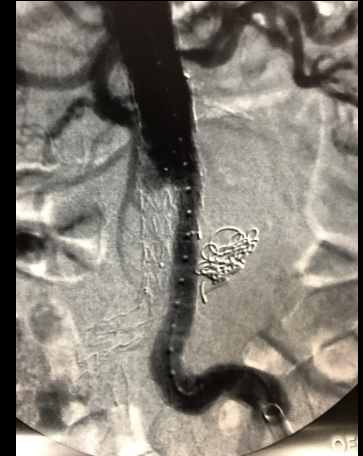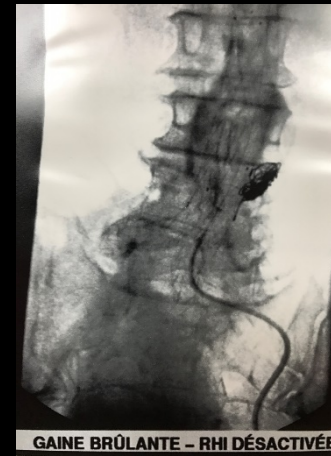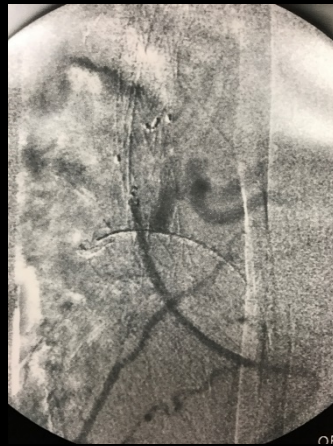
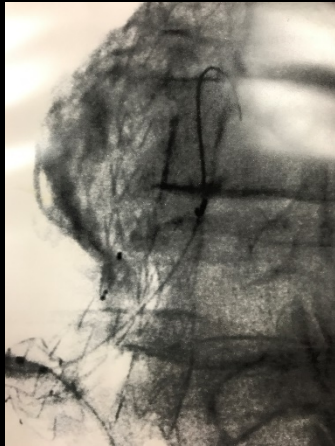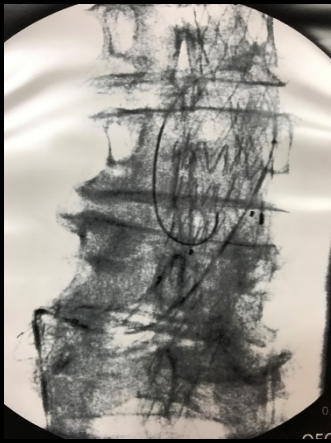in September 2013

Embolization

 *priority to the leak*

in September 2013

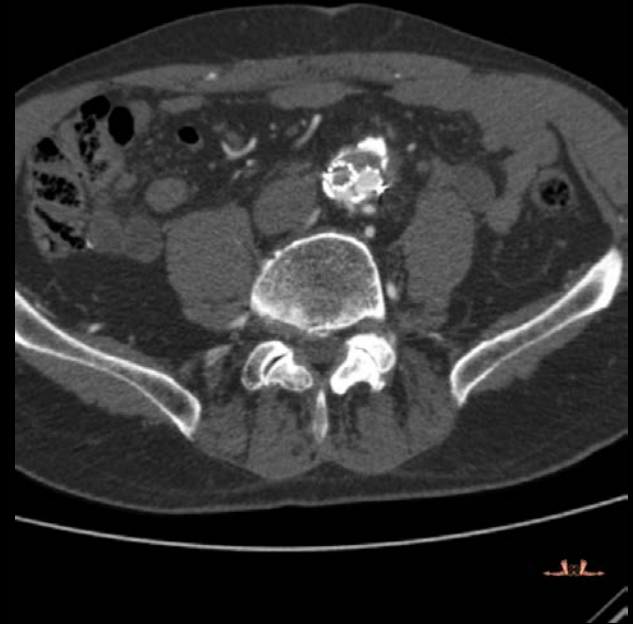
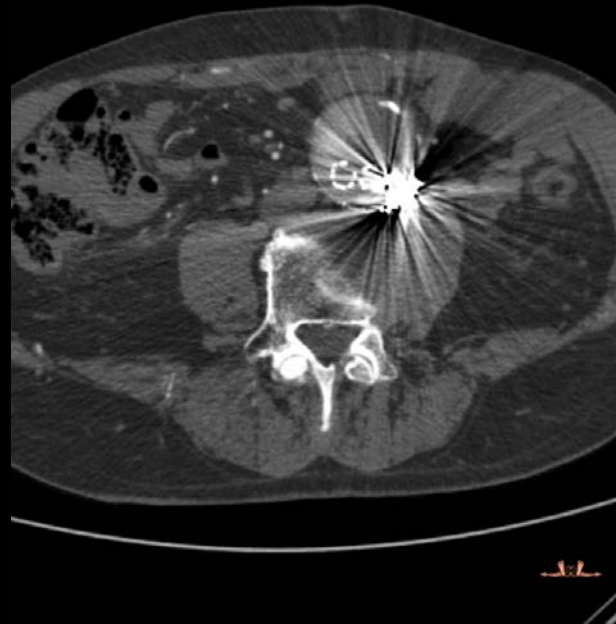Embolization



→ *not so easy...*

in September 2013

Embolization



→ failure

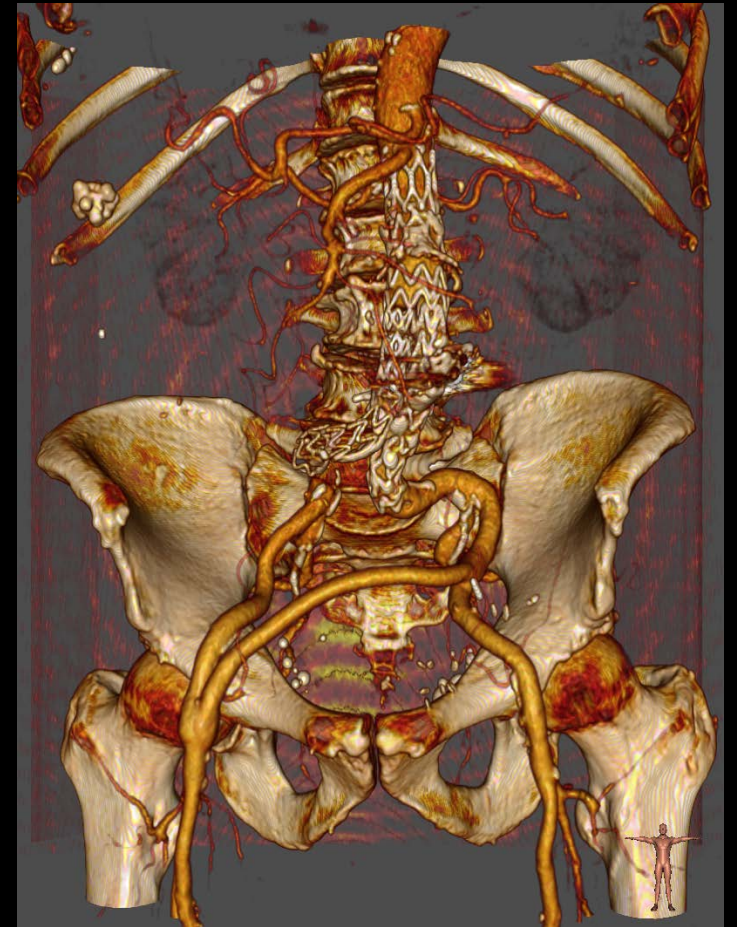
in December 2013

THE definitive solution

in December 2013

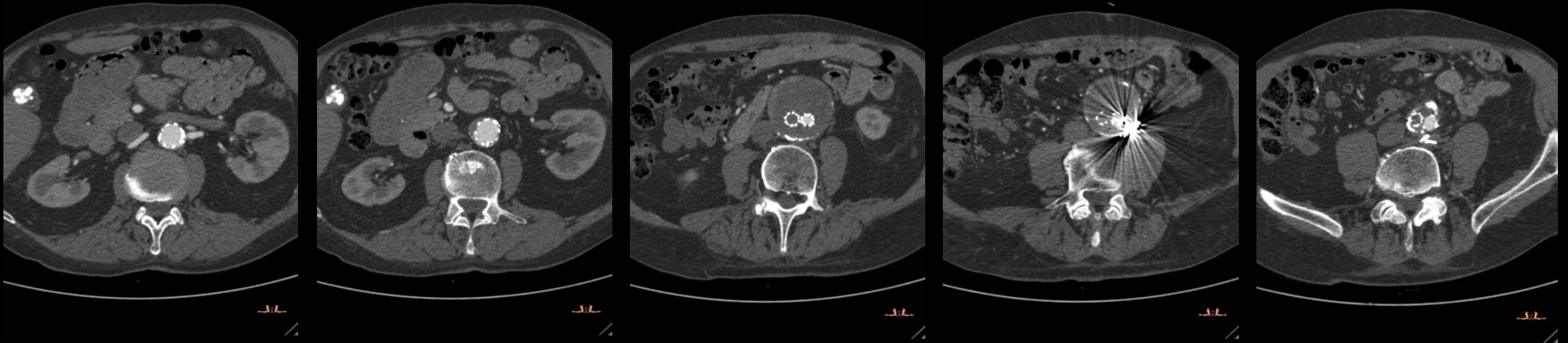THE definitive solution

*Extra anatomic iliofemoral bypass and
direct ligation of the lumbar arteries*



in December 2013

THE definitive solution



in February 2016

THE definitive solution ?

in February 2016

THE definitive solution ?

Invalidating claudication / popliteal thrombosis

in February 2016

THE definitive solution ?

Invalidating claudication / popliteal thrombosis

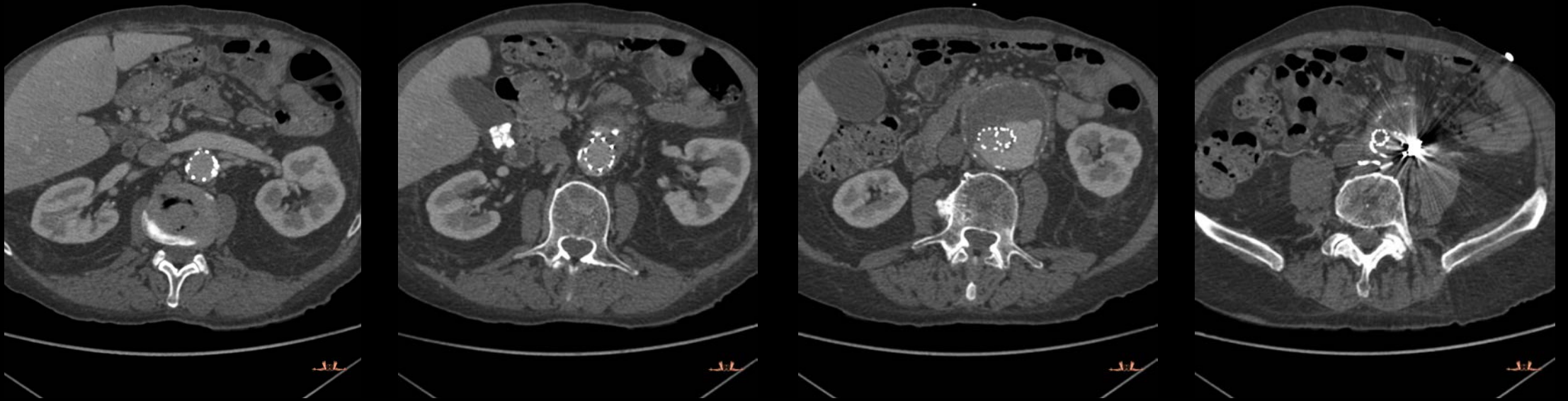
 *Popliteal recanalization*

in July 2016

Abdominal pains

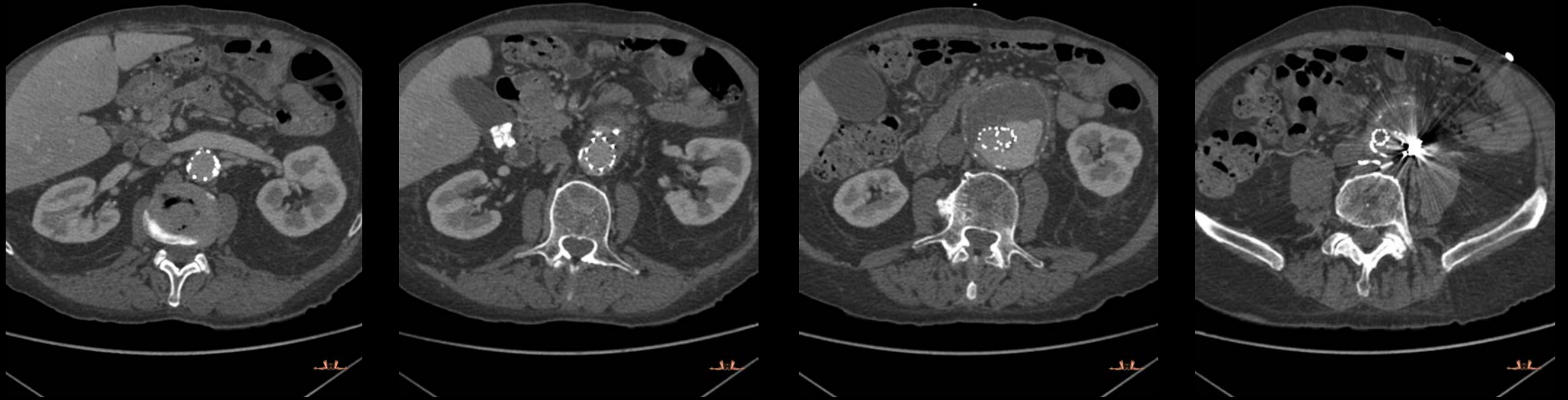
in July 2016

Abdominal pains / type I endoleak !



In July 2016

Abdominal pains / type I endoleak !



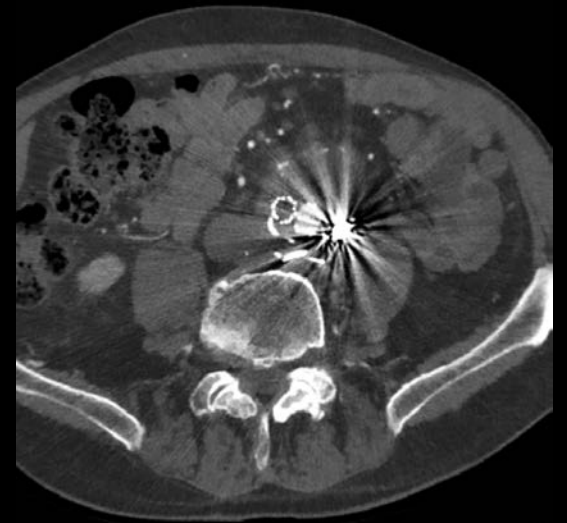
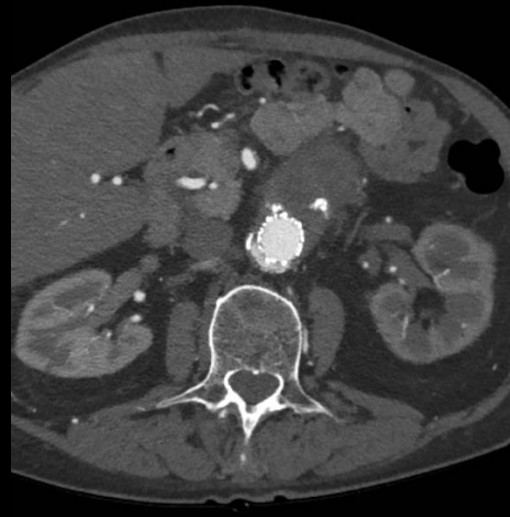
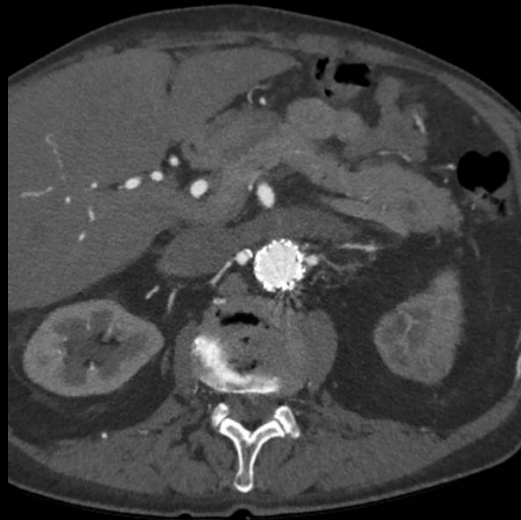→ *aortic cuff in emergency*

In September 2016

No more pain

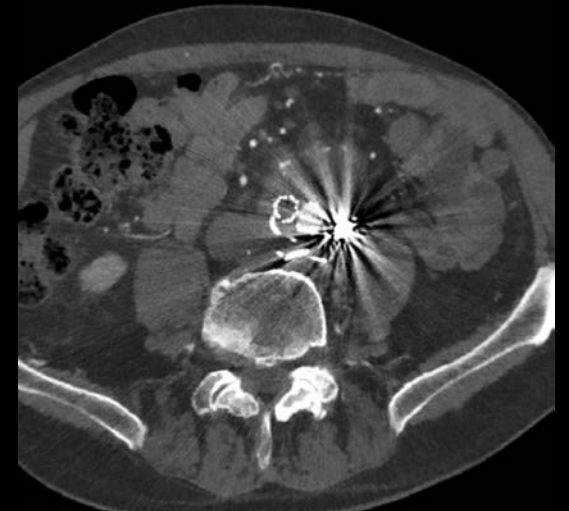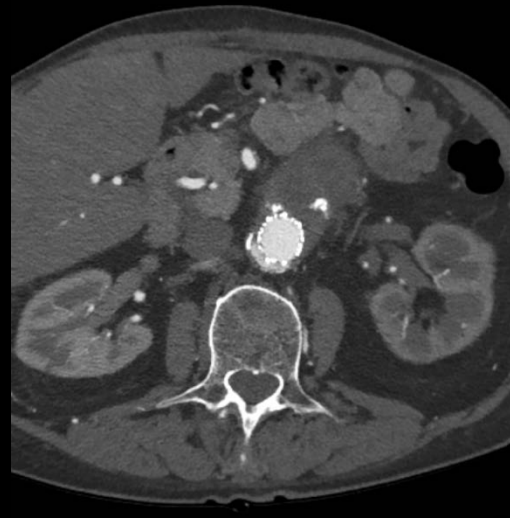
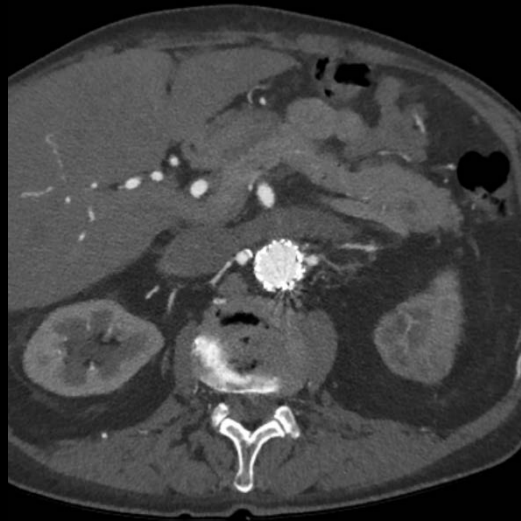In September 2016

No more pain, but persistent type I endoleak !!!



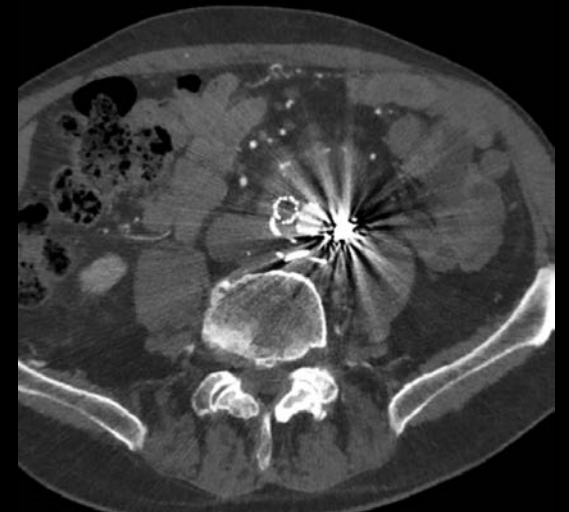
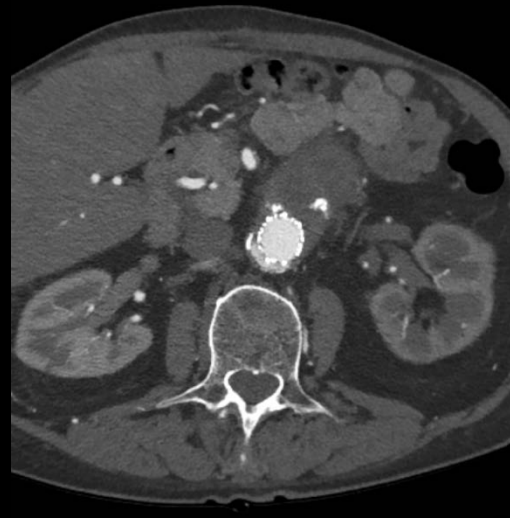
In September 2016

No more pain, but persistent type I endoleak !!!



In September 2016

No more pain, but persistent type I endoleak !!!



Stress echocardiography

In September 2016



*Supraceliac clamping
EVAR system explantation
Aortic tube graft*

To summarize

In August 2011

EVAR

In September 2013

Embolization attempt for type II endoleak

In December 2013

*Extra anatomic iliofemoral bypass
and lumbar ligatures*

In February 2016

Popliteal recanalization

In July 2016

Aortic cuff in emergency

In september 2016

*Supraceliac clamping
EVAR system explantation
Aortic tube graft*

To summarize

« Merci Docteur ! »

In August 2011

EVAR

In September 2013

Embolization attempt for type II endoleak

In December 2013

*Extra anatomic iliofemoral bypass
and lumbar ligatures*

In February 2016

Popliteal recanalization

In July 2016

Aortic cuff in emergency

In september 2016

*Supraceliac clamping
EVAR system explantation
Aortic tube graft*

Today *and for few years*

Today and for few years

AAA

high risk or obesity

EVAR for protection with close survey

but...

Today and for few years

AAA

good health

OPEN for recovery


Our duality Open/Endo

(Take home message)

Our duality Open/Endo

*« The interventional radiologist inside you
sometimes needs
the surgeon you are »*

(Take home message)



*The interventional radiologist inside you
sometimes needs
the surgeon you are*