

PERSPECTIVES 2017

December Friday 15 - BORDEAUX

Organization: E. Ducasse, M. Sibé



www.congresperspectives.com

Case discussion ... around the iliacs

L Maene



Disclosure of Interest

Speaker name: ...Lieven Maene.....

I have the following potential conflicts of interest to report:

- Consulting
 - Employment in industry
 - Shareholder in a healthcare company
 - Owner of a healthcare company
 - Other(s)
- ✓ I do not have any potential conflict of interest

PERSPECTIVES 2017

December Friday 15 - BORDEAUX

Organization: E. Ducasse, M. Sibé



www.congresperspectives.com

Case discussion ... around the iliacs





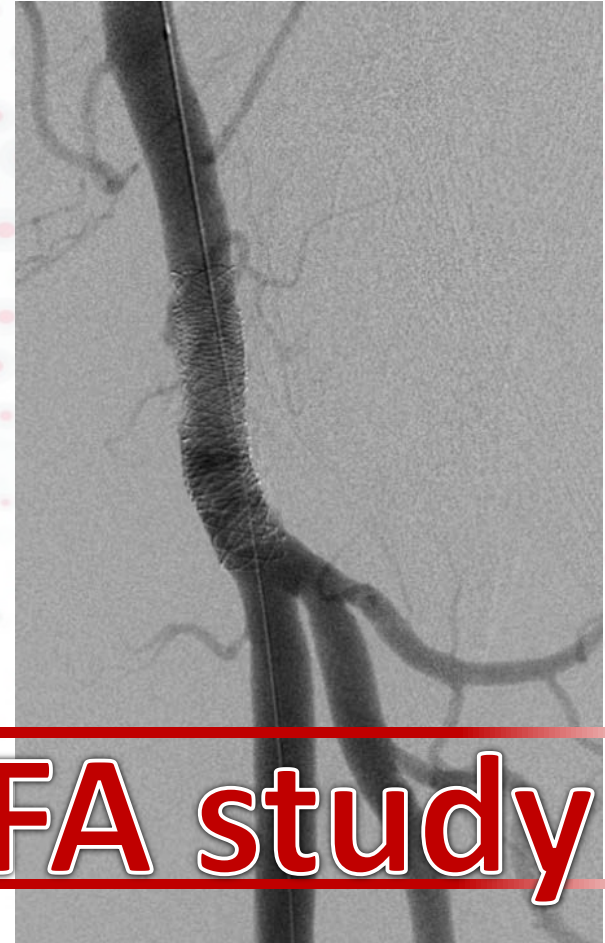
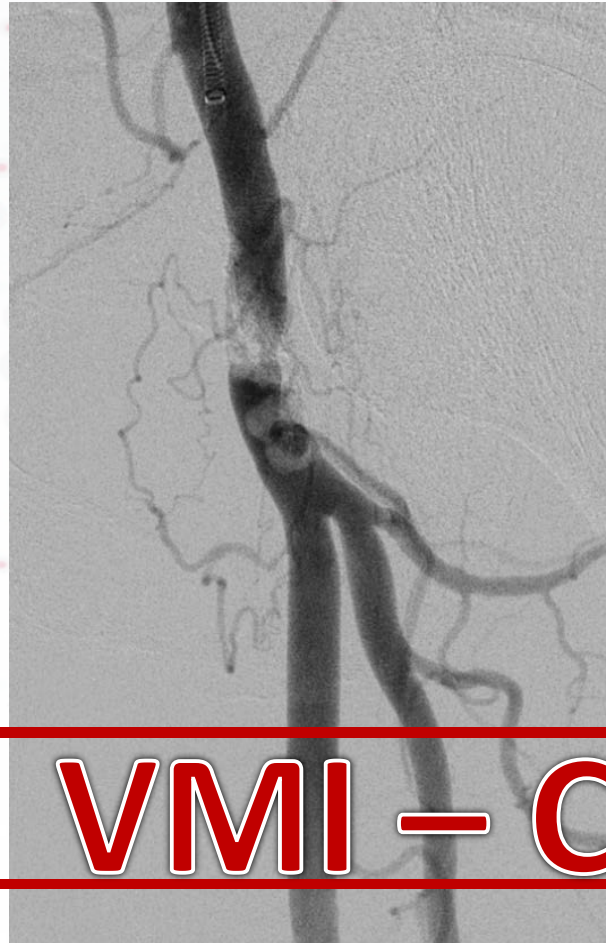







Case 0



VMI – CFA study



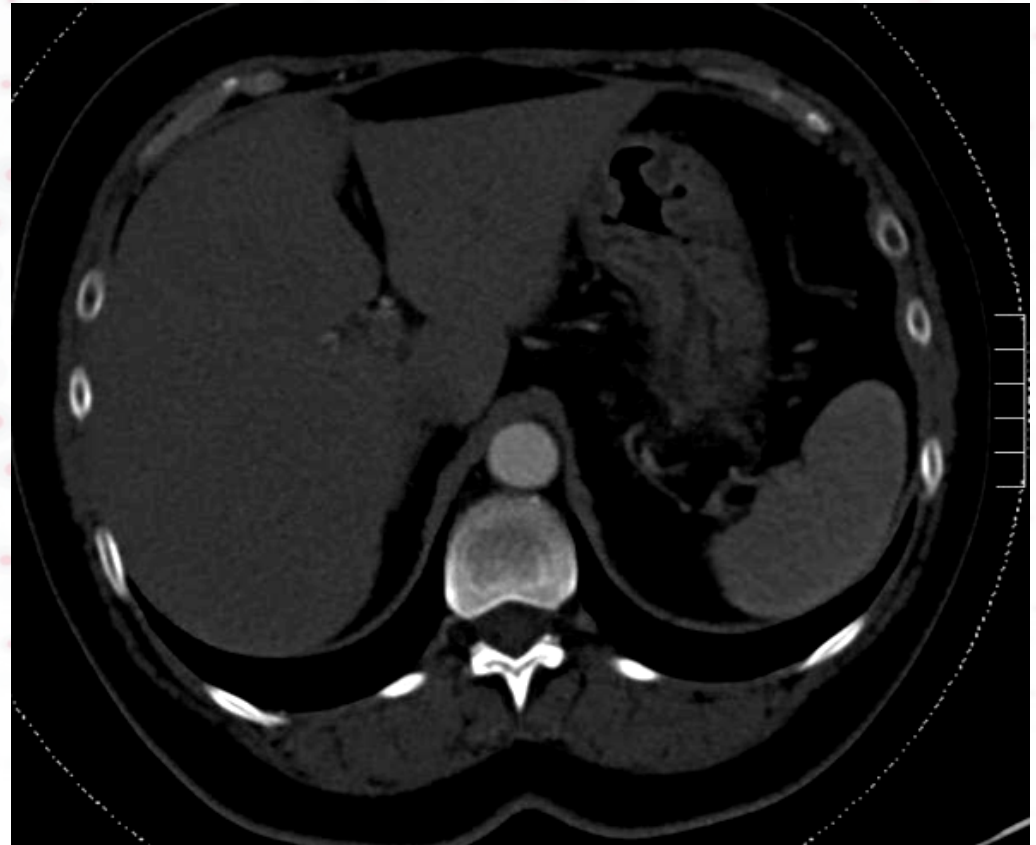
Case 1

- Female patient 59 Y
- 1 year in follow up “Chronic backpain”
“Walking impairment”
- 3 weeks ago ... “acute crisis” ...
- Today ... she said her physiotherapist goodbye and came to the ER



Case 1

- Subacute ischemia of both legs
 - Aortic thrombosis
 - Renal infarction
 - Slow recuperation of sens / motor loss



Éh Eric(a) ...


Aorto-Bifém... d'accord ?!!





Case 1

- Bilat CFA 5Fr
- Intraluminal recan
 - Ber Cath
 - 0035 guidewire





Case 1

- Bilat CFA 5Fr
- Intraluminal recan
- Two Unifuse cath
- Urokinase
- Heparine
- 24 h





Case 1

- Aortic ulcer ...
- CT scan
- Aortic stenting :
 - Begraft Bentley Inn.
 - Dogbone and catch

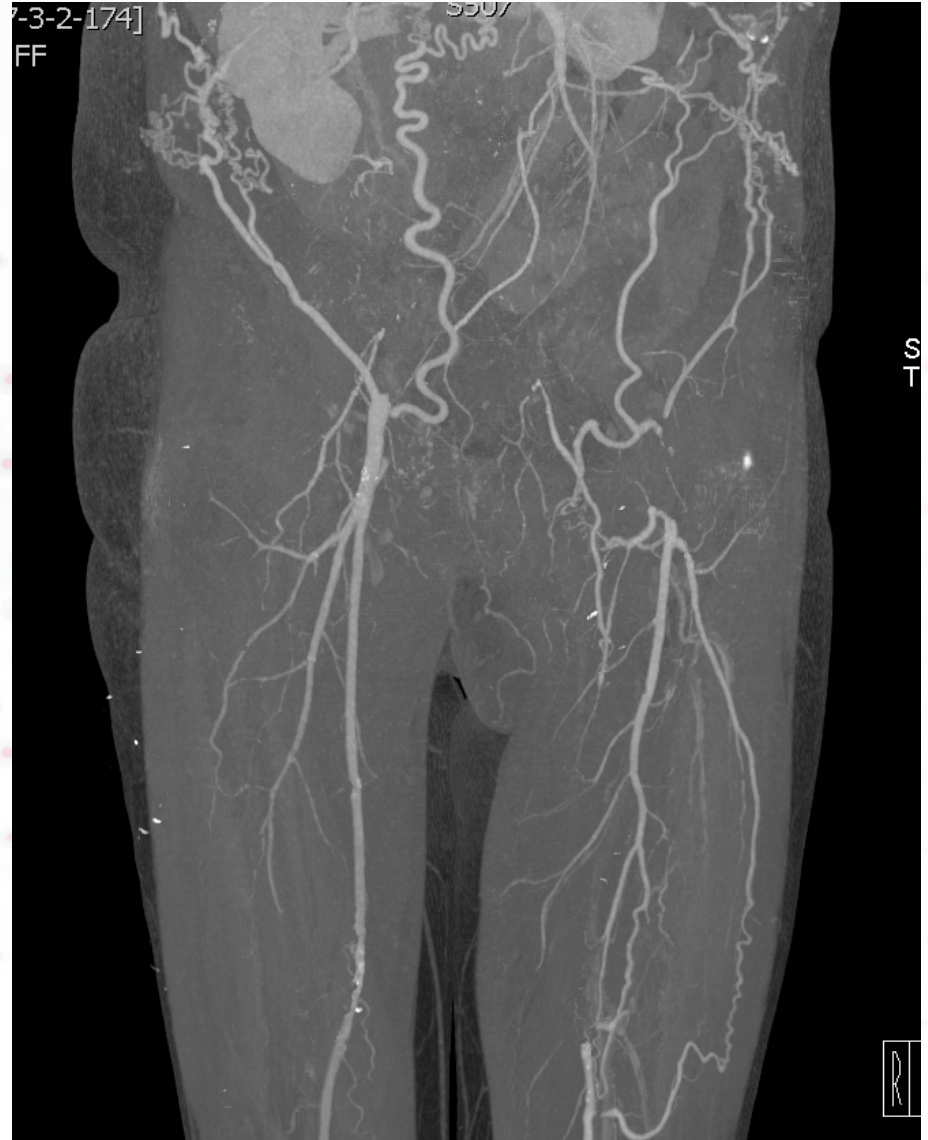

- Thrombolysis : < 4 weeks onset (?)
- Bilateral CFA access
 - Easier to perform intraluminal recanalisations
 - 2 multi-hole catheters
 - Bleeding complications under control



Case 2

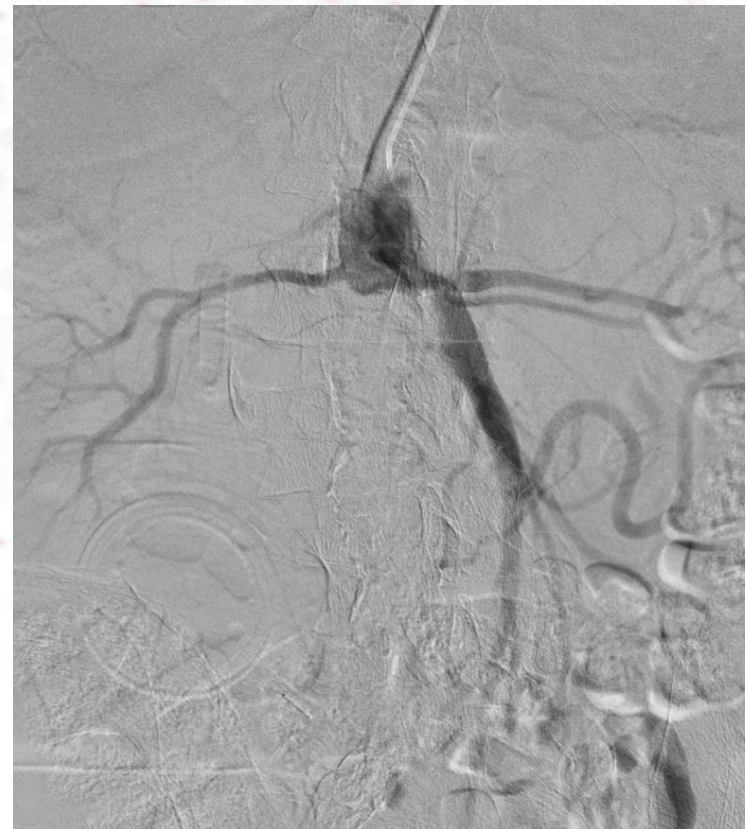- Male 74
- “Unfit” for open surgery
- Axillo-bifem bypass
- Ulcer right foot





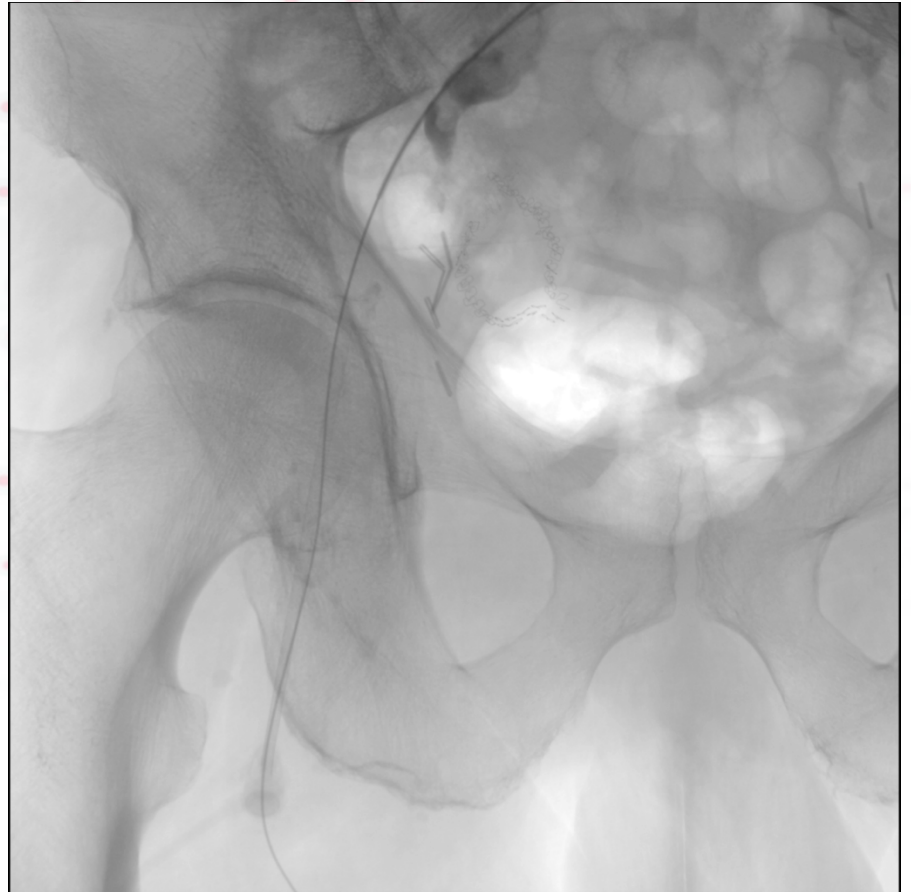
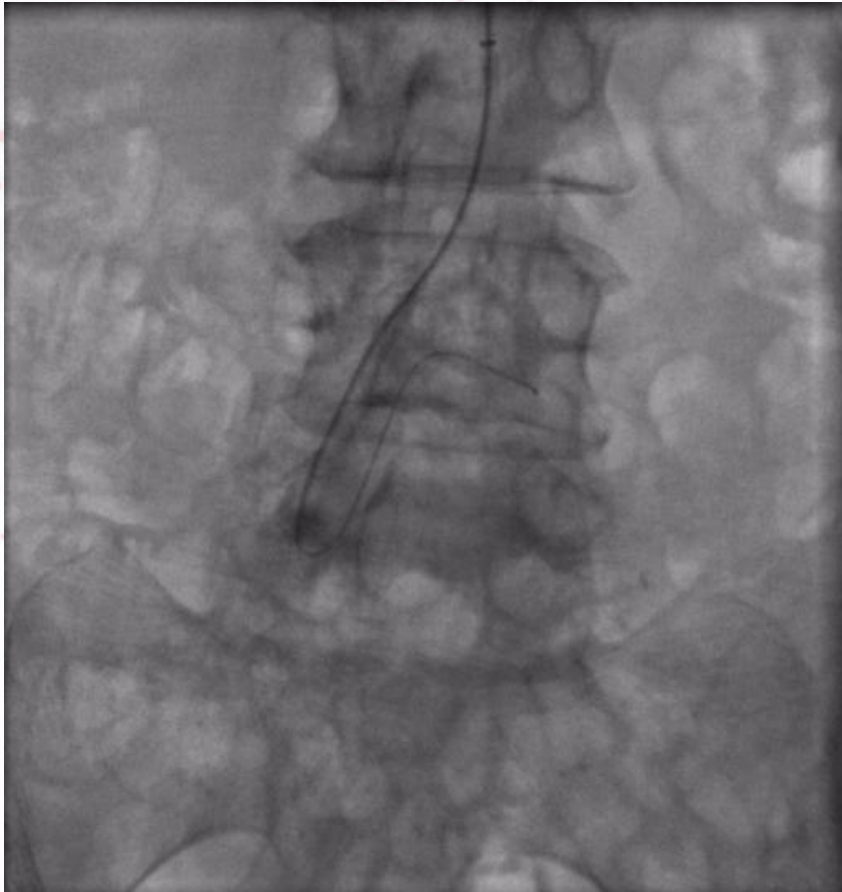Case 2

- L Brachial access
 - 90 cm 5Fr sheath
 - Clean infrarenal start
 - Extensive iliac disease
- Treat the symptomatic leg
- Hybrid reentry is always an option





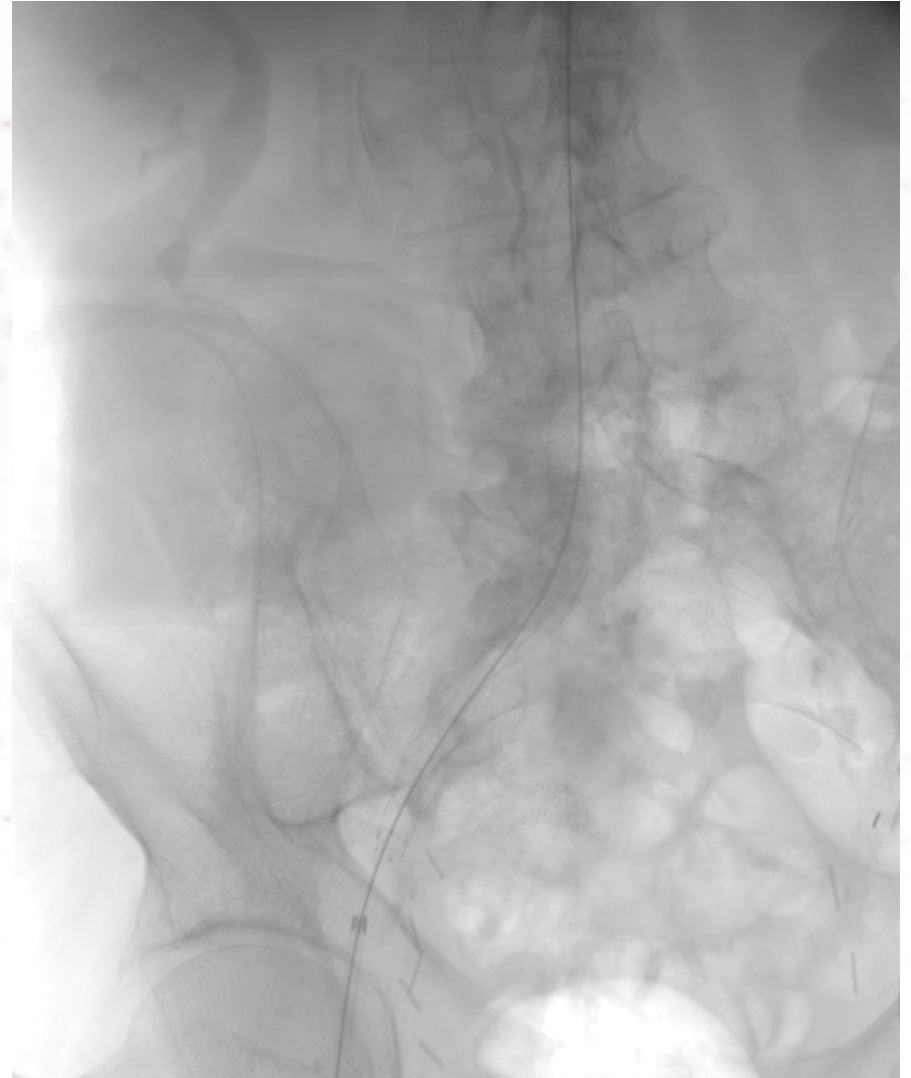Case 2





Case 2

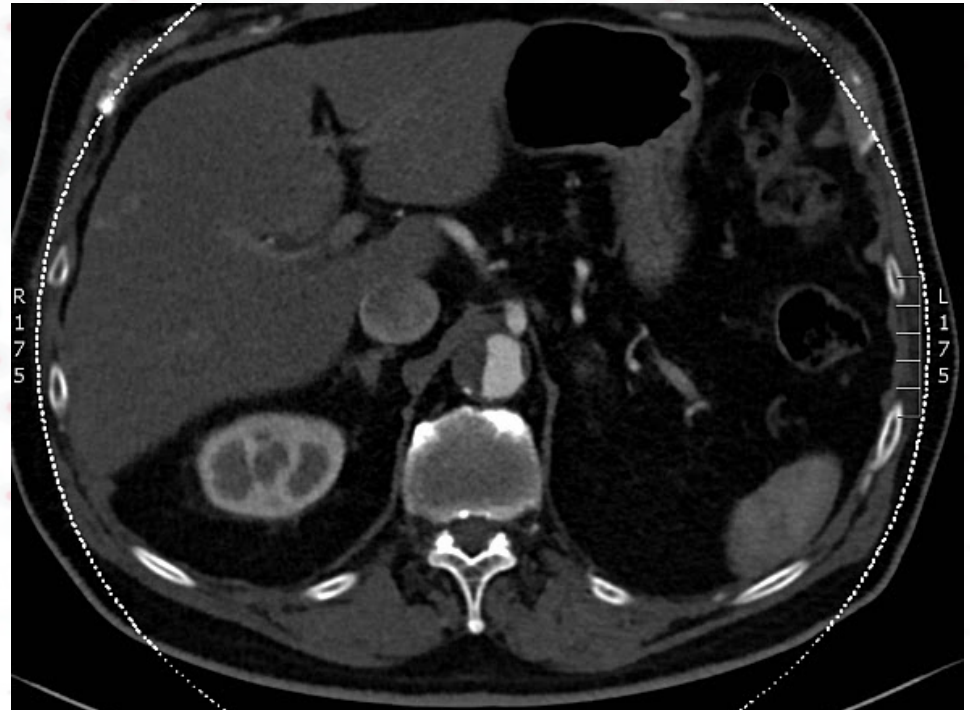
- R CFA Access
- Direct stenting
 - Viabahn 10mm (aortic)
 - Absolute Pro (Iliac)
- Postdilation





Case 3 ... the black cow ...

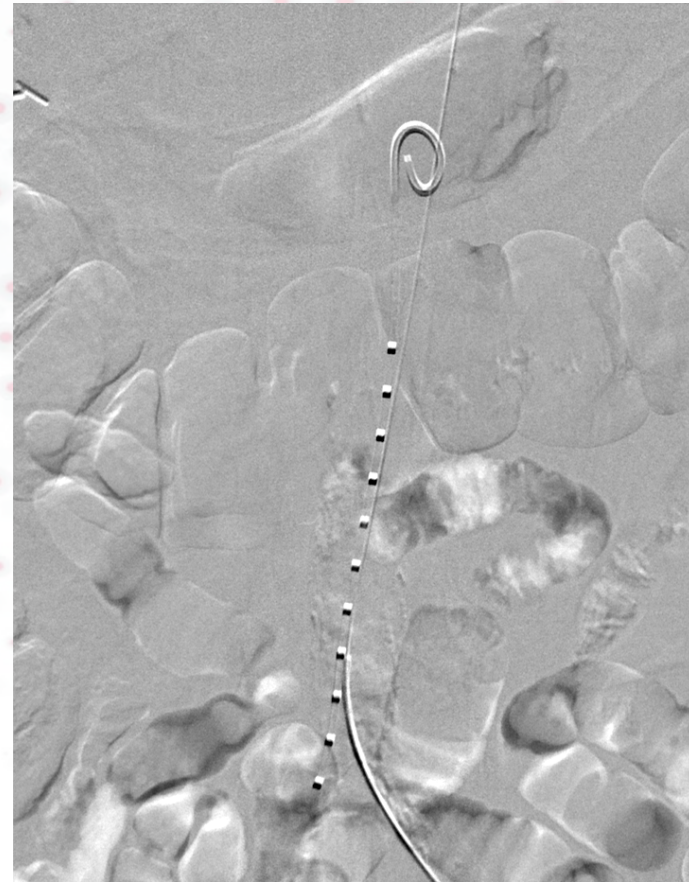- Male 68
- Refused open surgery





Case 3 ... the black cow ...

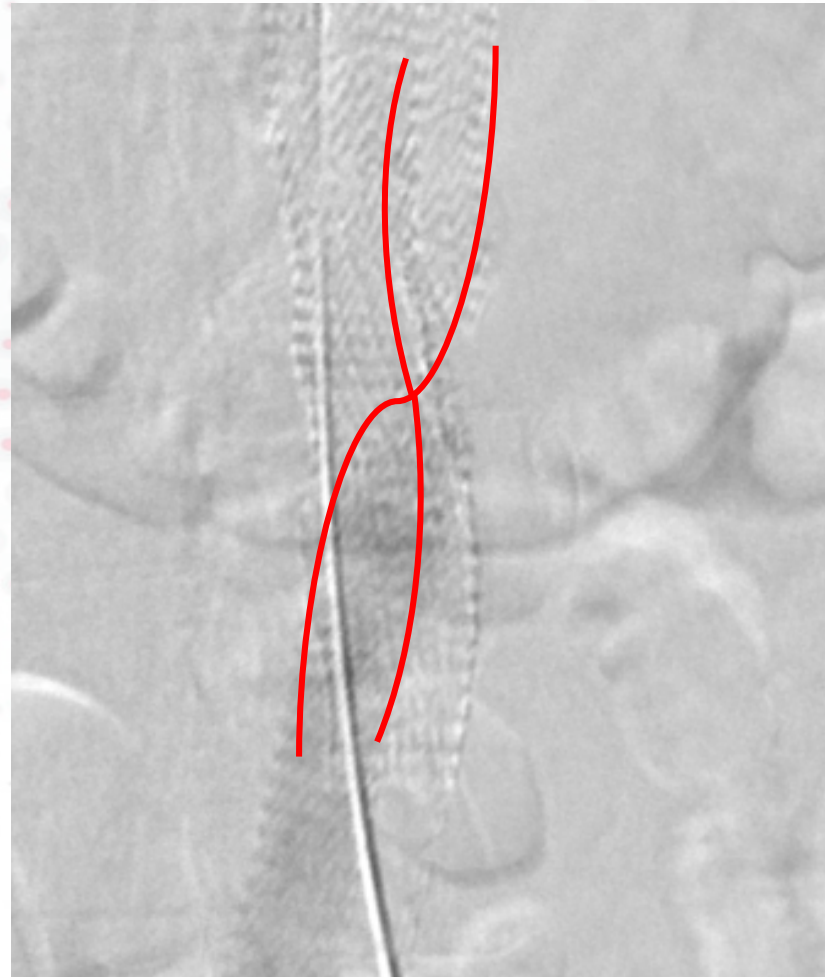
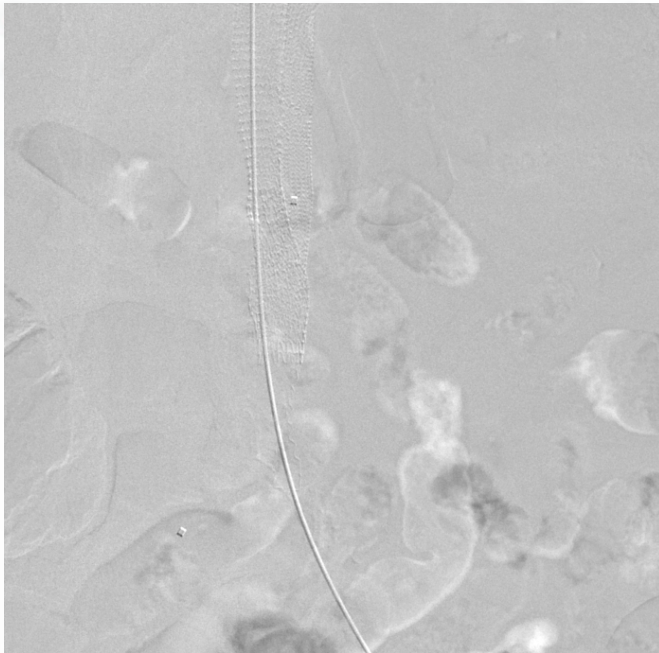
- Bilat CFA Access
 - Patent ext iliac arteries
 - Mild com iliac disease
- Direct stenting
 - Bilateral Viabahn 10mm (aortic)





Case 3 ... the black cow ...

- Postdilation



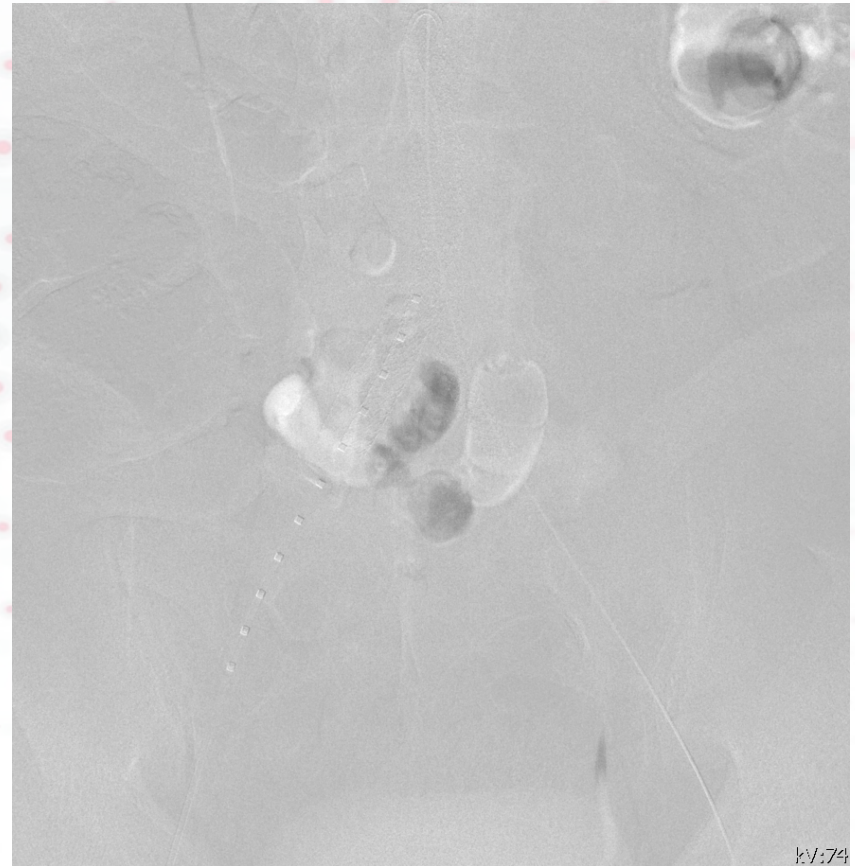

Case 3 ... the black cow ...

- Introduction of the left Viabahn twisted the implanted right stent
- Conversion : 1 inflow



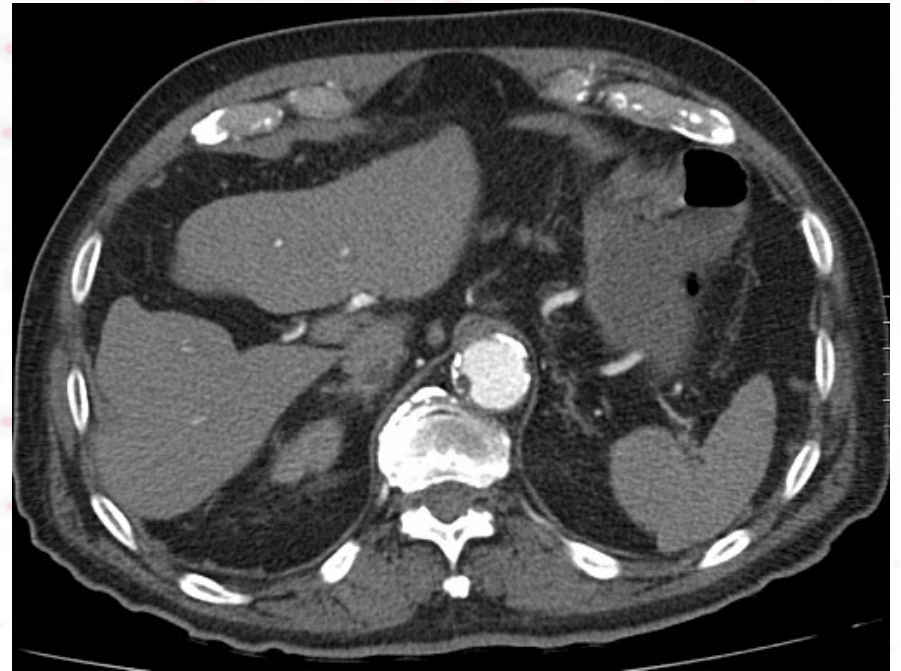
2 outflow





Case 4 ... Hybrid

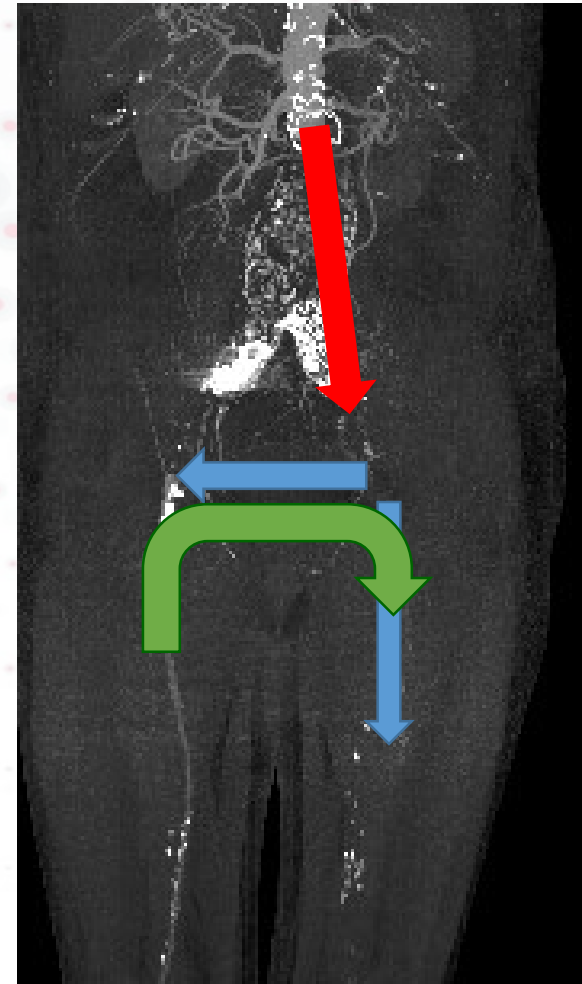
- Male 75
- Previous AUI stentgraft & fem-fem crossover
- Acute severe ischemia of left leg
- Mild sens loss right leg





Case 4 ... Hybrid

- Open thrombectomy :
 - Fem-fem bypass
 - Left SFA
- Relining of AUI with Viabahn
- Closed groin incision
- 12h thrombolysis : 4Fr sheath in Right SFA → Fem-Fem → Left BTK






Conclusions

- Use the right tools
- Patient-tailored,
- Lesion-tailored

- We need to build evidence and not throw the kid with the bathwater...



Pff ... Still loves big cuts !!

PERSPECTIVES 2017

December Friday 15 - BORDEAUX

Organization: E. Ducasse, M. Sibé



www.congresperspectives.com

Case discussion ... around the iliacs

L Maene

