

# The Mystery Of Tricuspid Valve Surgical Techniques and Outcomes


## Novel Technique for Tricuspid Valve Annuloplasty – “P” Repair

### Prakash P Punjabi

FRCS(Eng),MS,MCh,FCCP, Diplomate NBE  
National Heart and Lung Institute,  
Imperial College, London UK

Training Programme Director: Cardiothoracic Surgery  
Surgical Tutor: Royal College of Surgeons of England  
Editor in Chief: PERFUSION

UK Licensed Ham Radio Operator: Callsign - 2EOPMP

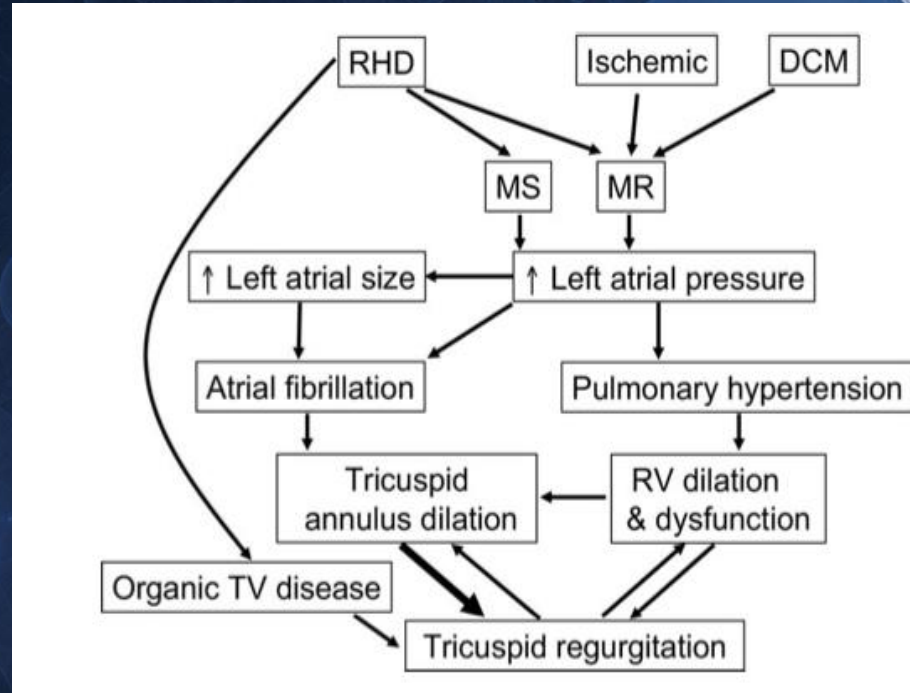


# Etiology OF TR

- PRIMARY causes - 25%
  - Rheumatic
  - Ebstein anomaly
  - Endocarditis
  - Carcinoid disease
  - Myxomatus
  - abnormality of the valve apparatus
- SECONDARY causes -75% OR FUNCTIONAL / Annular dilatation
  - RV dysfunction
    - RV Ischemia/infarction
  - Pulmonary hypertension
    - Left heart disease
    - PE
    - Chronic lung disease
    - Left to right shunt

# Pathophysiology

- primary structural abnormalities of the leaflets and chordae
- secondary to myocardial dysfunction and dilatation.



# Types of TR

## Primary TR

congenital  
abnormalities

bacterial  
endocarditis

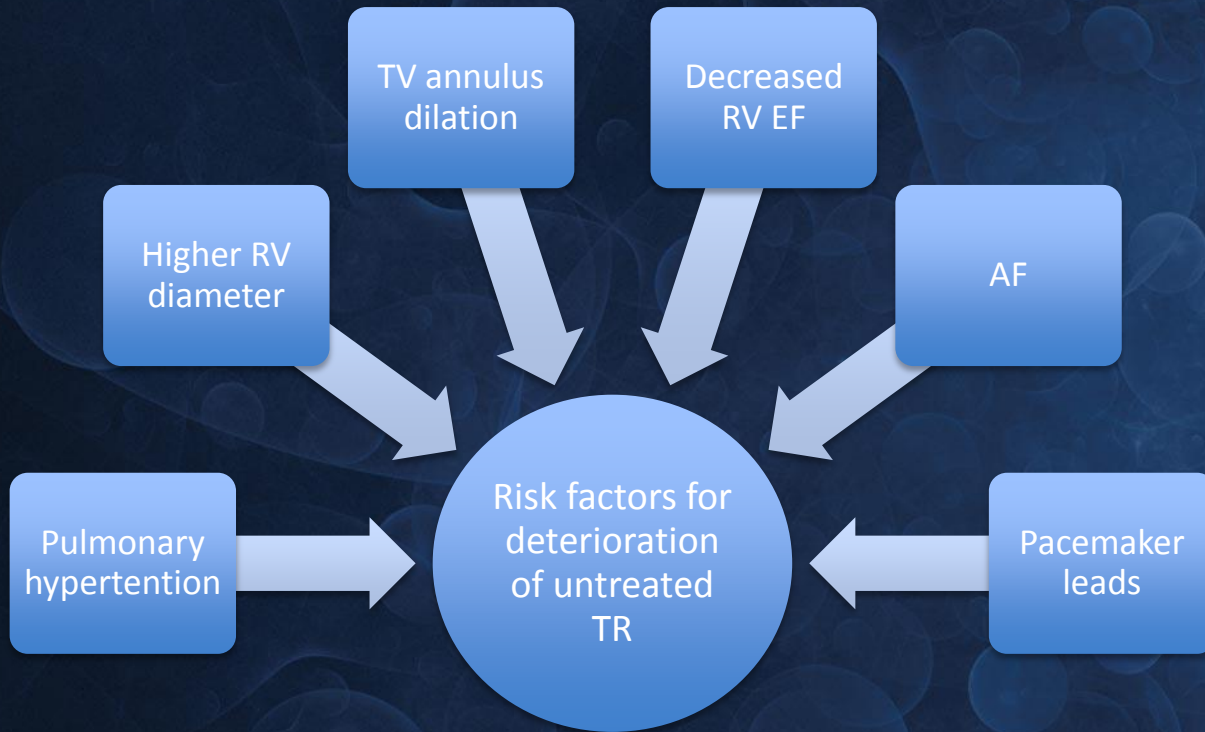
## Secondary TR

volume  
overloading

pressure  
overloading

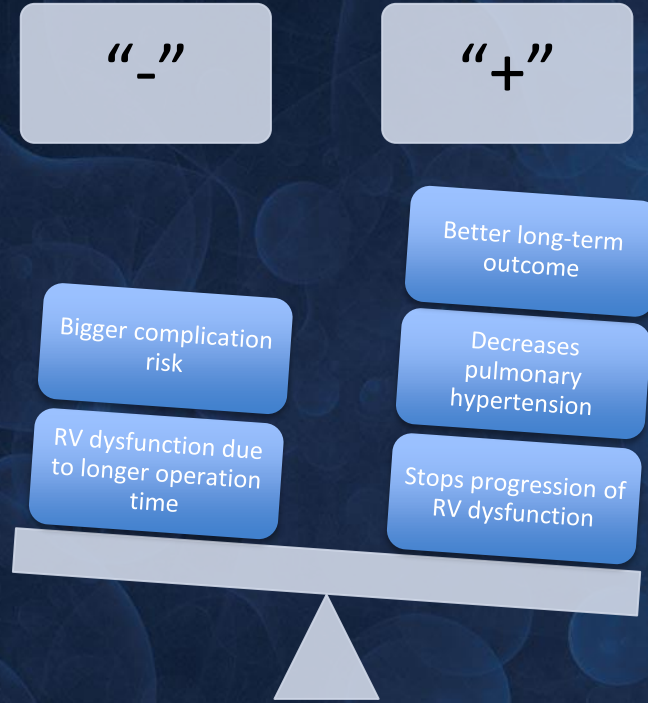


- Functional TR may decrease or totally disappear after resolution of the left heart lesion responsible for the overloading of the right ventricle
- However, TR may persist even after successful correction of left-sided lesions.
- Predicting the evolution of functional TR after surgical treatment of mitral valve disease remains difficult.



- When a separate tricuspid valve repair, due to significant TR, follows mitral valve surgery, mortality rates up to 32% are seen- and 5-year survivability is less than 50%.
- The reason is the poorer preoperative condition of the patients due to increased age, complications related to the previous mitral valve operation, and the possibility that irreversible right ventricular dysfunction had developed by the time of the second surgery.

# Advantages and disadvantages of TV repair





**PRACTICE GUIDELINE**

# **2014 AHA/ACC Guideline for the Management of Patients With Valvular Heart Disease**

A Report of the American College of Cardiology/American Heart Association Task Force on Practice Guidelines

*Developed in Collaboration With the American Association for Thoracic Surgery, American Society of Echocardiography, Society for Cardiovascular Angiography and Interventions, Society of Cardiovascular Anesthesiologists, and Society of Thoracic Surgeons*



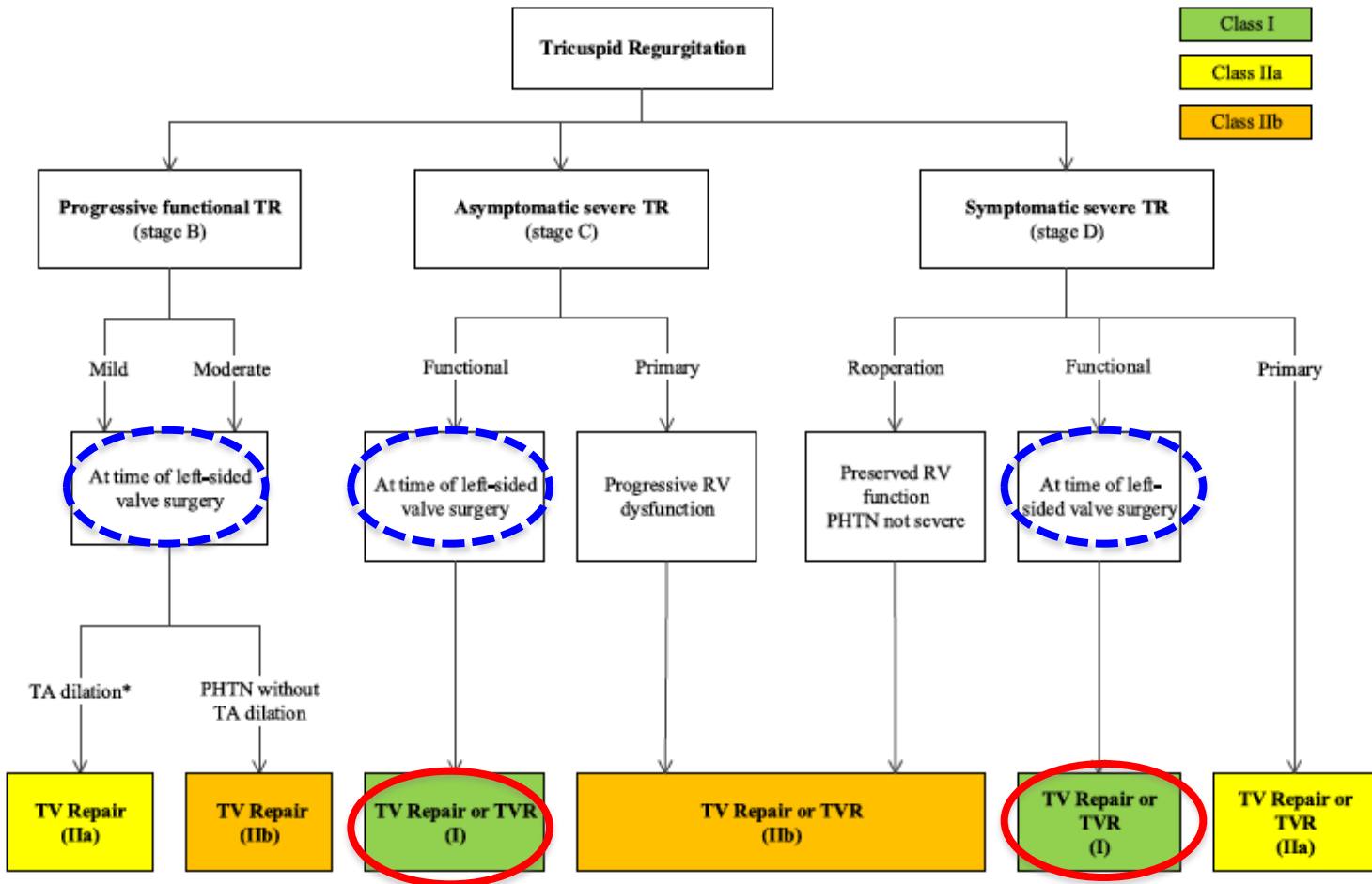


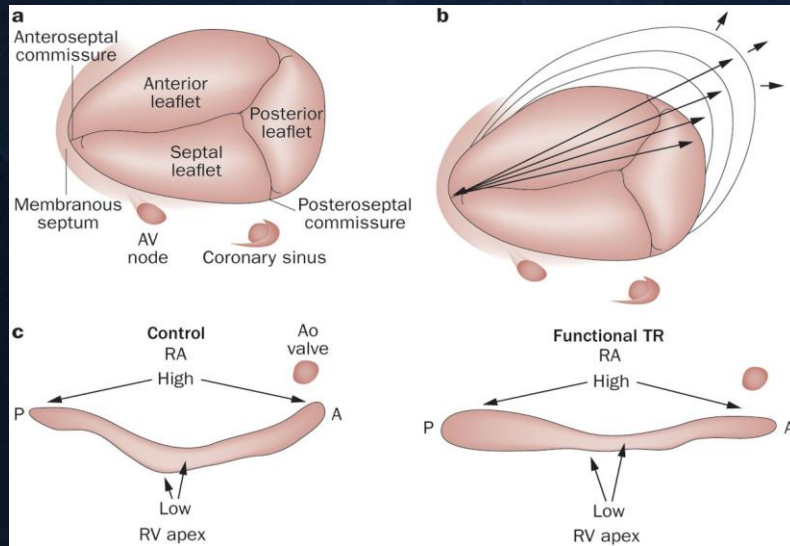
Figure 5. Indications for Surgery

**tricuspid valve annuloplasty of the tricuspid annulus dilated >40mm, together with trace to moderate tricuspid regurgitation, performed concurrently with a mitral valve operation can prevent subsequent progression of tricuspid regurgitation and right ventricular dilatation and systolic dysfunction in the relatively near-term postoperative period.**

- Because late TR in MV disease is usually due to TA dilation (although rheumatic patients might have organic leaflet disease as well) and carries significant morbidity and mortality, and because the results of repeat surgery for isolated late TR are poor, *concomitant TV repair with an annuloplasty ring should be performed at the time of the initial MV surgery.*



# Process of tricuspid annular dilatation



**a** A healthy tricuspid valve.

**b** Tricuspid annular dilatation secondary to left-sided heart valve disease occurs predominantly in the septal–lateral direction.

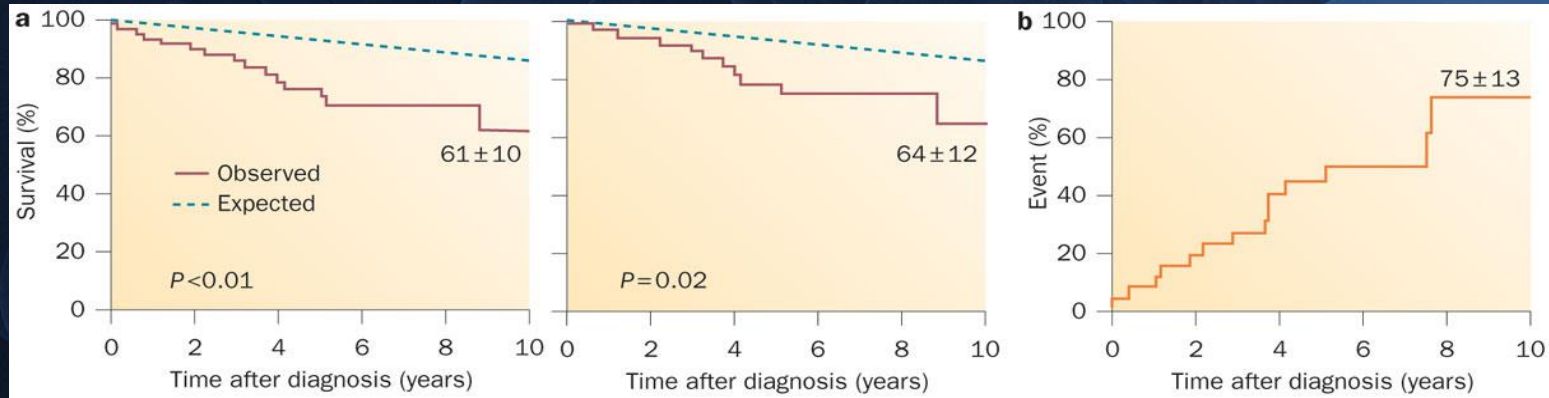
*Reprinted from The Annals of Thoracic Surgery, 79, Dreyfus, G. D. et al. Secondary tricuspid regurgitation or dilatation: which should be the criteria for surgical repair? 127–132, © 2013, with permission from Elsevier.*

**c** Tricuspid annulus viewed from profile displaying anteroposterior view in a control patient with a healthy tricuspid valve (left panel) with two high points located anteroposteriorly, and in a patient with functional TR (right panel), in whom the annulus becomes flatter with no distinct high point.

# GRADING

- Regurgitation jet area / RA area
  - I – mild  $< 0.2$
  - II – moderate  $0.2 - 0.34$
  - III – severe  $> 0.34$
- Presence of negative wave form in pulse wave Doppler tracing of hepatic venous flow – severe TR

# Clinical outcome of patients with tricuspid regurgitation caused by flail leaflets

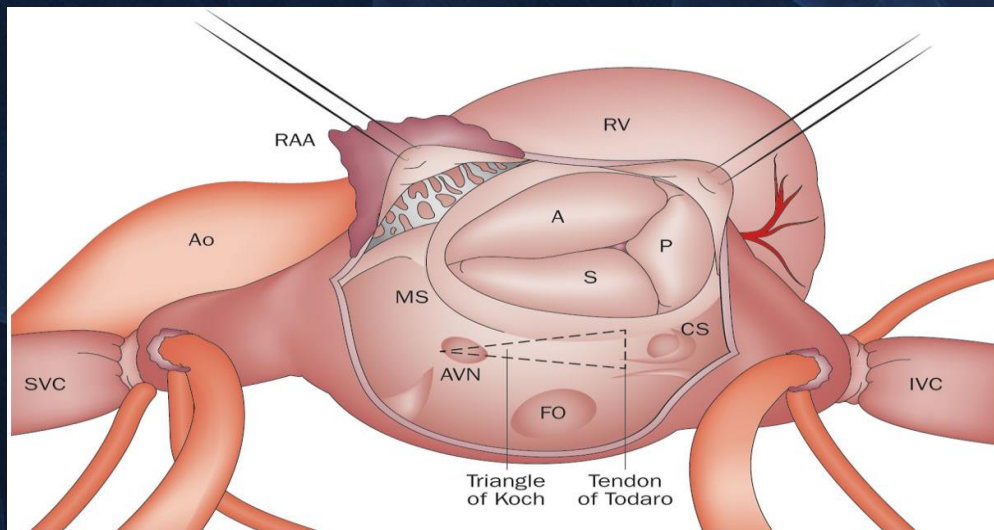


**a** Long-term survival compared with expected survival in the matched US population. Excess mortality was 4.5% yearly ( $P < 0.01$ ) in the overall population ( $n = 60$ ) with tricuspid flail leaflets (left panel), and 3.8% yearly ( $P = 0.02$ ) after exclusion of patients with associated diseases contributing to symptoms (right panel).

**b** Event rate in asymptomatic patients caused by flail leaflets. The Kaplan–Meier curve depicts the incidence of the combined end point of symptoms of heart failure, new atrial fibrillation, cardiac surgery, or death. Reprinted from *The Journal of Thoracic and Cardiovascular Surgery*,



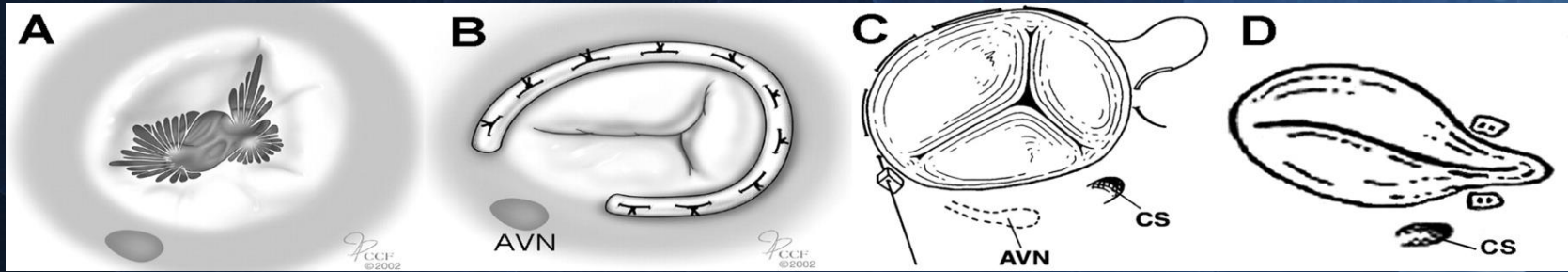
# Surgical view of the tricuspid valve



- The AVN is located near the anterior half of the base of the septal leaflet. Abbreviations: A, anterior; Ao, aorta; AVN, atrioventricular node; CS, coronary sinus; FO, foramen ovale; IVC, inferior vena cava; MS, membranous septum; P, posterior; RAA, right atrial appendage; RV, right ventricle; S, septal; SVC, superior vena cava.



# Surgical repair techniques

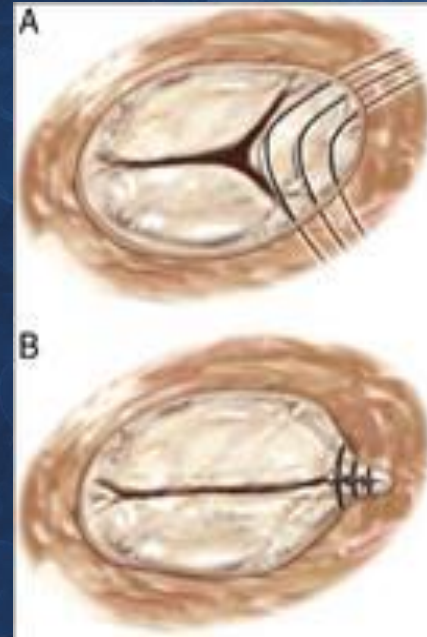


- A- Dilated tricuspid Annulus
- B- Rigid or flexible rings
- C- De-Vega annuloplasty
- D – Suture Bicuspidalisation

# Tricuspid valve bicuspidization

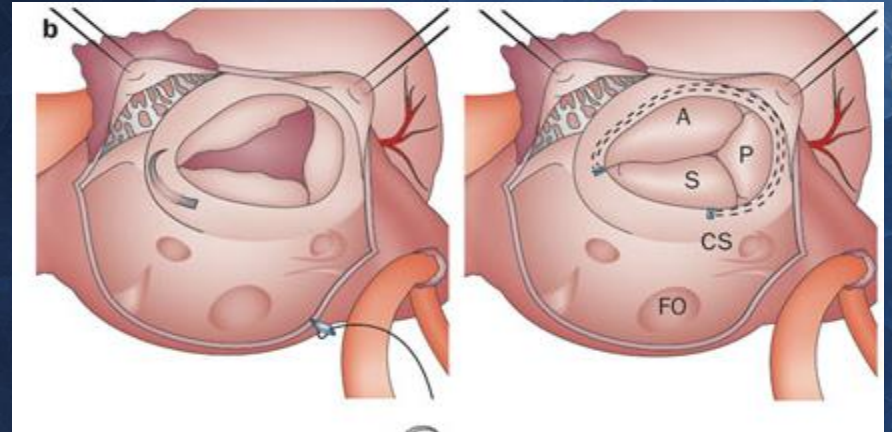
*Introduced by Kay et al 1965*

- **(A)** Is accomplished by plicating the annulus along the posterior leaflet.
  - mattress suture from the anteroposterior to the posteroseptal commissures along the posterior annulus
- **(B)** The sutures are tied, obliterating the posterior leaflet, creating a bicuspid valve.



# De Vega annuloplasty

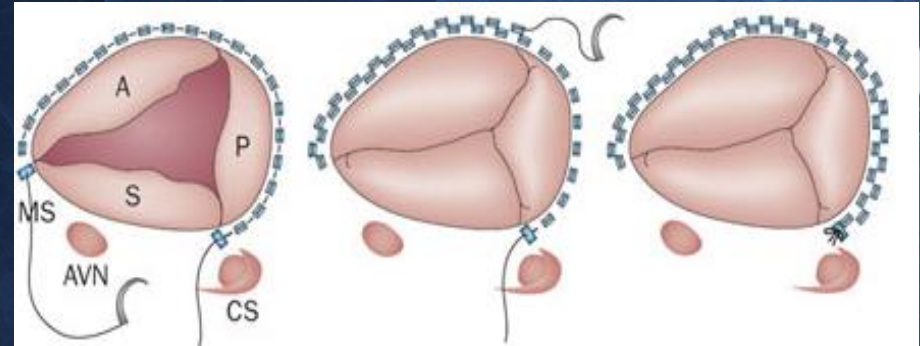
- suture commence from the anteroseptal commissure and ends beyond the origin of the coronary sinus.
- After the first suture line is completed, a another line is started close to the first one and ends at the same level as the coronary sinus.
- Both needles of the same suture are passed into a pledget and tied to reduce the orifice diameter.





# Modified De Vega annuloplasty

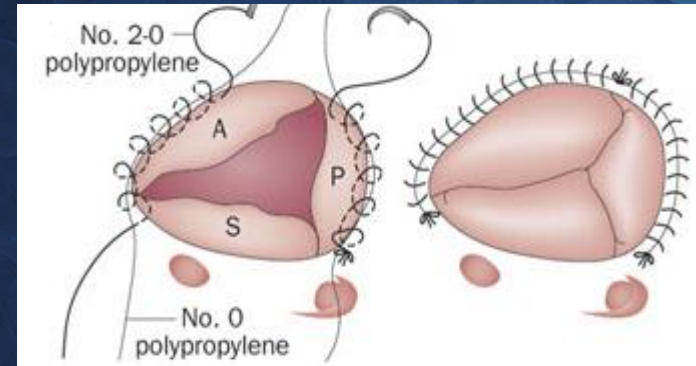
- concept remains the same as the De Vega procedure
  - This process involved interpositioning Teflon pledgets in each bite of the suture
  - Orifice diameter is reduced by a partial purse string suture and prevents suture slippage.





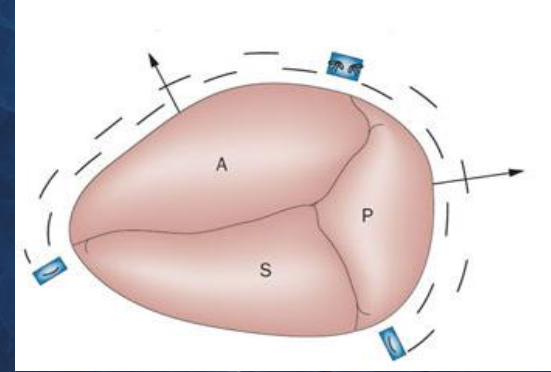
# Modified semicircular constricting annuloplasty

- Performed using 0 and 2-0 polypropylene sutures.
- At first, 0 and 2-0 polypropylene sutures are fixed and at anteroseptal and posteroseptal commissure.
- 2-0 Polypropylene sutures which come from anchoring points in clockwise and counterclockwise direction are used to encircle the free wall annulus as well as 0 polypropylene sutures in *spiral fashion (Spiral Annulry Suture Technique)*. When both sutures get to the anteroposterior commissural region (*tying point*), they are passed through plastic snares.
- In this annuloplasty, 0 polypropylene sutures are used for reduction and constriction, 2-0 polypropylene sutures are used for the fixation of 0 polypropylene sutures in annular level. When 0 polypropylene sutures is tied, it is very important to pull the free ends of 0 polypropylene sutures downwards to the *traction direction* to make the dilated annulus constrict and symmetrical.



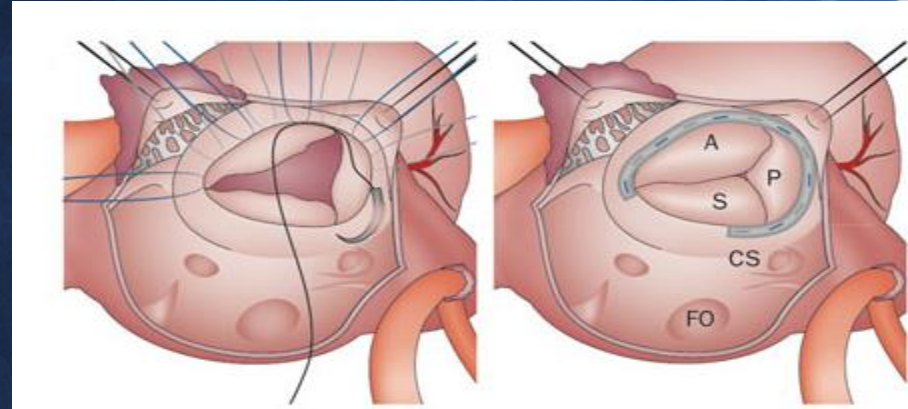
# Adjustable segmental tricuspid annuloplasty

- Two 2-0 Ethibond sutures with a Teflon pledget were used for double suture lines. The two separate sutures met in the middle, close to the anteroposterior commissure, and were held together using a wider Teflon pledget pointing towards the 12 o'clock position. Each suture was cinched until coaptation of three leaflets were achieved, and were then tied in sequence.



# Ring or band tricuspid annuloplasty

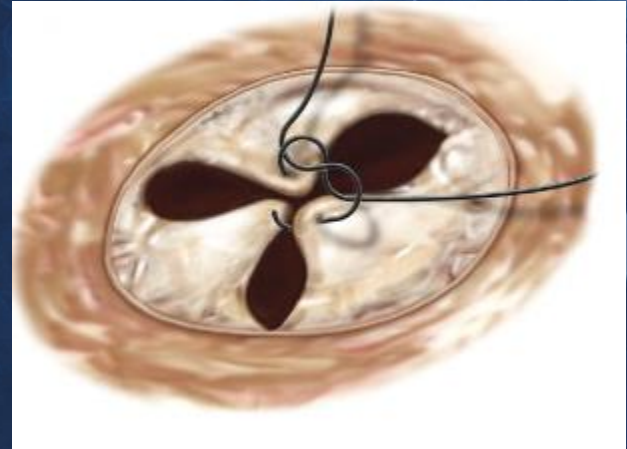
- The interrupted suture (2-0 Ticron or Ethibond) starts at the same points as in part **b**. The sutures end in front of the origin of the coronary sinus and, finally, the band or ring is positioned





# Edge to Edge repair- Clover Shaped

- The middle parts of the free edges of the tricuspid leaflets are sutured together
  - Resulting in clover-shaped valve
- Effective for patients with severe residual TR or complex lesions





# Evidence-based surgical management

**Table 1** | Studies of semicircular tricuspid suture annuloplasties

Study	Year	Type of annuloplasty	Number of patients	Follow-up duration (months)	Failure rate of annuloplasty (%)
Grondin, P. <i>et al.</i> <sup>73</sup>	1975	De Vega	17	11.5	23
Rábago, G. <i>et al.</i> <sup>74</sup>	1980	De Vega	150	6–30	5.9
Brugger, J. J. <i>et al.</i> <sup>75</sup>	1982	De Vega	76	30	4.2
Rivera, R. <i>et al.</i> <sup>76</sup>	1985	De Vega	83	64	34
Pasaoglu, I. <i>et al.</i> <sup>77</sup>	1990	De Vega	195	42	2
Holper, K. <i>et al.</i> <sup>78</sup>	1990	De Vega	97	56	33.8
Hashimoto, K. <i>et al.</i> <sup>79</sup>	1993	Arai	43	60	7
Peltora, T. <i>et al.</i> <sup>80</sup>	1996	De Vega	30	10–71	43.7
Tager, R. <i>et al.</i> <sup>81</sup>	1998	De Vega	43	57	11.5
Bernal, J. M. <i>et al.</i> <sup>82</sup>	2004	Revuelta	139	81	4.5
McCarthy, P. M. <i>et al.</i> <sup>83</sup>	2004	All types	790	48–168	14
Goksin, I. <i>et al.</i> <sup>71</sup>	2006	Sagban	25	17.8	4.2
Antunes, M. J. & Barlow, J. B. <sup>15</sup>	2007	Antunes	442	24–192	0.007

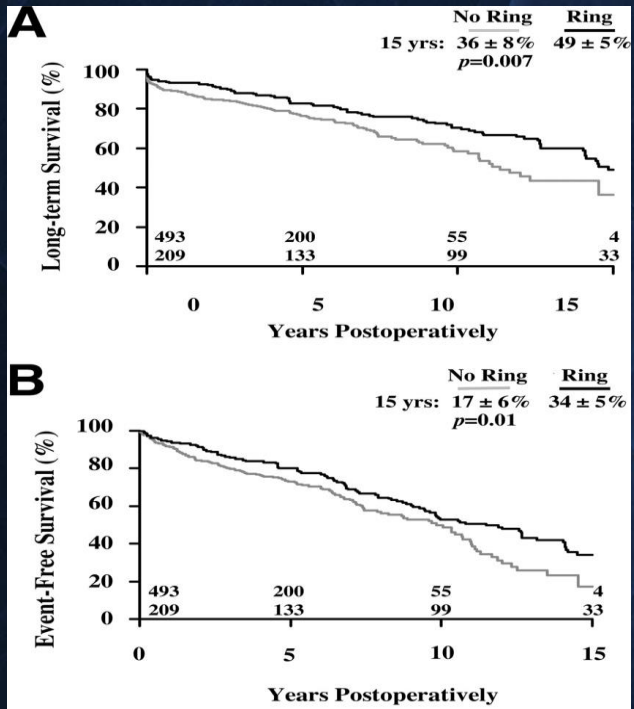
Shinn, S. H. & Schaff, H. V. (2013) Evidence-based surgical management of acquired tricuspid valve disease  
*Nat. Rev. Cardiol.* doi:10.1038/nrcardio.2013.5

# Currently available rings

Brand	Manufacturer	Type (rigid or flexible)	Size and shape (closed or open)	Use in surgery
Carpentier–Edwards®	Edward Lifesciences	Rigid ring	26–36 mm open planar	Dedicated for use in TV surgery
Cosgrove–Edwards®	Edward Lifesciences	Flexible band	26–38 mm open	MV or TV surgery
MC3®	Edward Lifesciences	Rigid titanium ring	26–36 mm open with 3D confirmation	Dedicated for use in TV surgery
Duran AnCore®	Medtronic	Flexible ring or band	25–35 mm closed or open	MV or TV surgery
Tailor®	St Jude Medical	Flexible ring or band	Closed or open	MV or TV surgery
Annuloflex®	Carbomedics	Flexible ring or band	26–36 mm convertible closed or open	MV or TV surgery
Simulus®	ATS Medical	Flexible ring or band	23–35 mm closed or open	MV or TV surgery

Abbreviations: MV, mitral valve; TV, tricuspid valve.

**Figure 2. Kaplan-Meier curves comparing long-term outcomes in patients who received a tricuspid annuloplasty ring vs those who did not receive a ring during tricuspid valve repair surgery.**



De Vega- N=493  
Ring N=209

Ring patients had significantly better long-term survival and event-free survival

Tang G H L et al. *Circulation*. 2006;114:I-577-I-581



# Novel Technique for Tricuspid Valve Annuloplasty

**P P Punjabi, A Macys, M Moscarelli, M Elshiekh,  
Z Zhou, A Momin, J Chan**

**Imperial College Healthcare NHS Trust  
Hammersmith Hospital  
National Heart and Lung Institute  
Imperial College, London UK**

**AATS Mitral Conclave 2013**



# Novel Technique for Tricuspid Valve Annuloplasty

- We describe a simple technique for Tricuspid Valve Annuloplasty.
- We have successfully performed Tricuspid Valve Annuloplasty using this technique in 38 cases and achieved tricuspid valve competency with no more than trace to mild regurgitation at discharge from hospital.
- The technique is easy to perform and reproducible.

# Novel Technique for Tricuspid Valve Annuloplasty

- We have performed tricuspid valve annuloplasty in patients undergoing concomitant mitral valve surgery with either severe tricuspid annular dilatation or moderate to severe tricuspid regurgitation.
- Tricuspid valve annuloplasty can be performed by various techniques.
- Kay and De Vega's suture annuloplasty as well as other techniques including implantation of prosthetic annuloplasty rings have greatly simplified tricuspid valve annuloplasty increasing its reproducibility and durability.

# Novel Technique for Tricuspid Valve Annuloplasty

- Each technique has its advantages and disadvantages.
- Challenges include accurate sizing of the prosthetic ring, avoidance of conduction bundle, as well as preventing suture dehiscence as most of the prosthetic annuloplasty rings are rigid.
- There have been some attempts to use flexible annuloplasty rings for tricuspid annuloplasty.



# Novel Technique for Tricuspid Valve Annuloplasty

- We describe a simple technique which is easy to perform, reproducible, and graduated to achieve optimum reduction in the tricuspid annular dimension to achieve competency and adequate co-aptation.
- Preoperative determination of the tricuspid annular dimension and assessment of tricuspid regurgitation confirms the need to perform tricuspid annuloplasty in patients undergoing concomitant mitral valve intervention +/- AF ablation.



# Novel Technique for Tricuspid Valve Annuloplasty

## **Technique:**

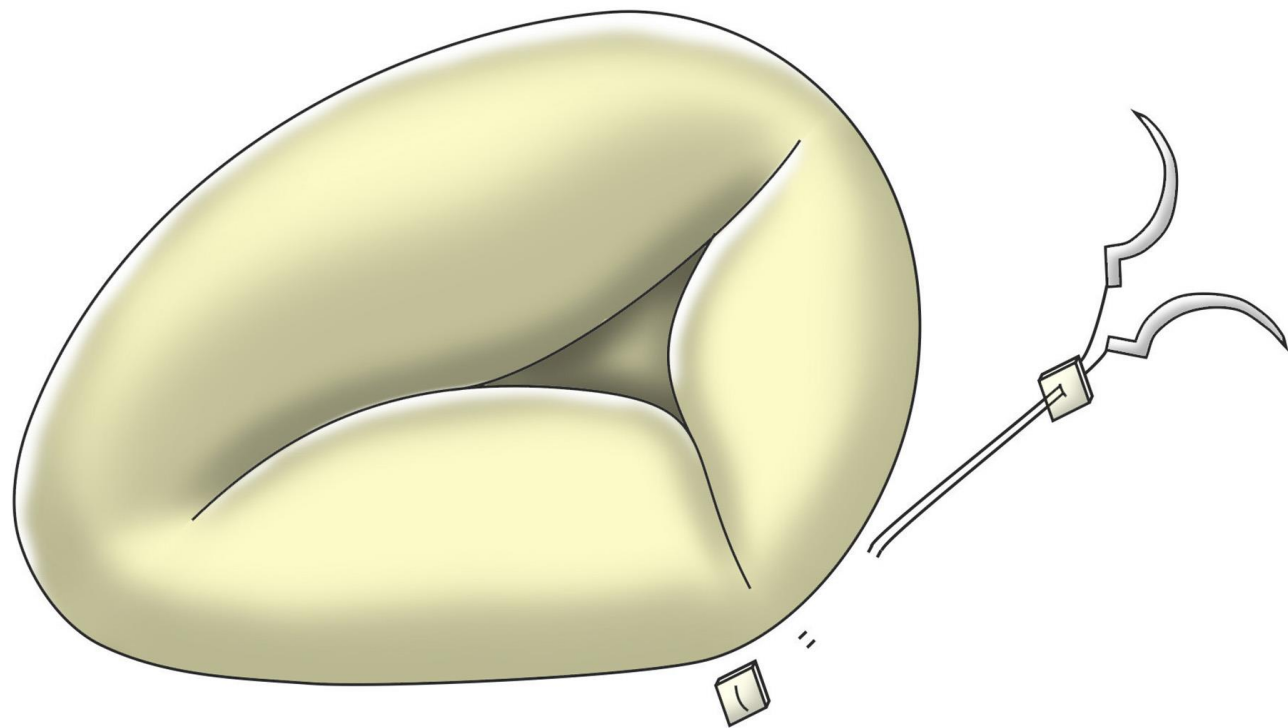
- This can be performed either on a beating heart or with cardioplegic arrest.
- 2.0 Ethibond sutures with pledgets are used.
- The annuloplasty can be achieved using between 8 and 12 sutures.
- Each suture is double pledgeted (pledgets on both sides) before tying to achieve reduction in annular size.

# Novel Technique for Tricuspid Valve Annuloplasty


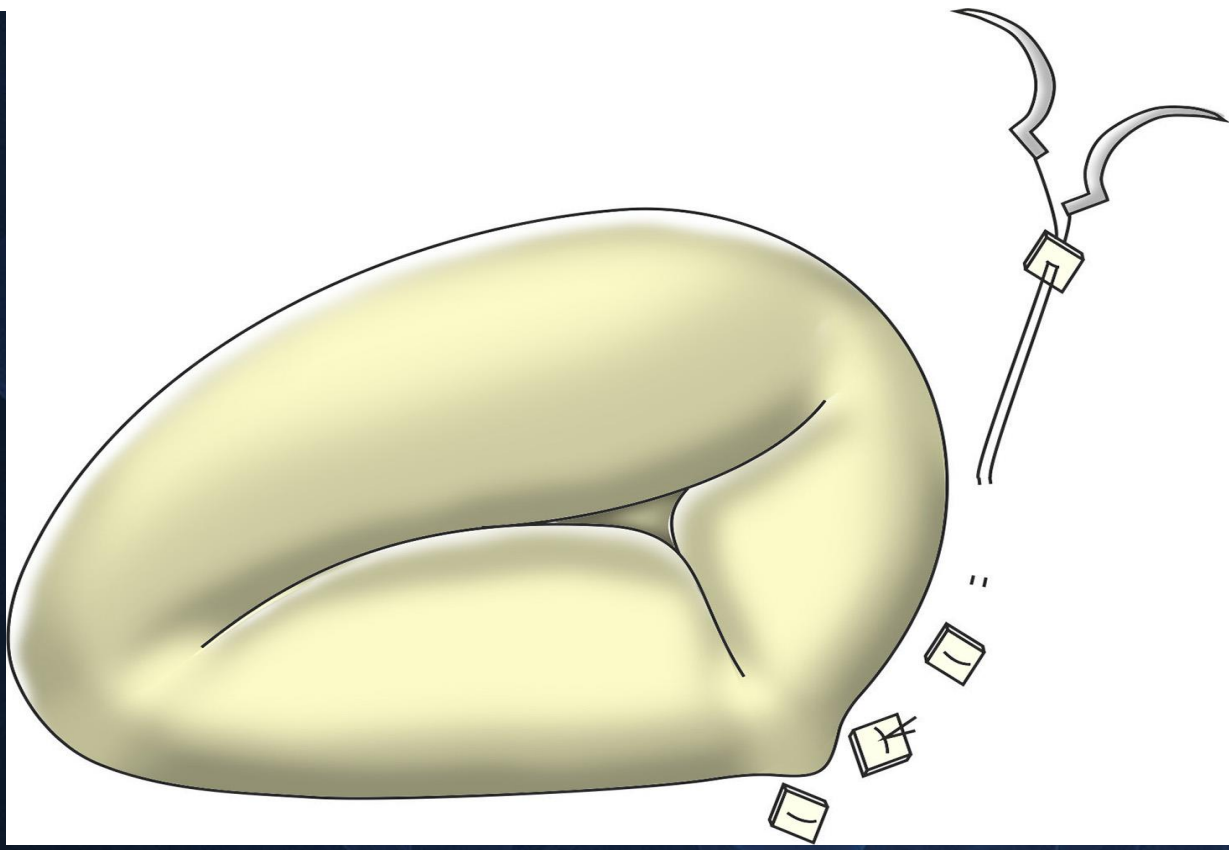
- The sutures extend from just above the anteroseptal commissure and circumferentially along the anterior leaflet, crossing the anteroposterior commissure, along the posterior leaflet and may extend just beyond the posteroseptal commissure.
- Both suture needles with the pledget are passed along the fibrous annulus travelling a distance between 6 to 8 millimetres, and then another pledget is passed through.


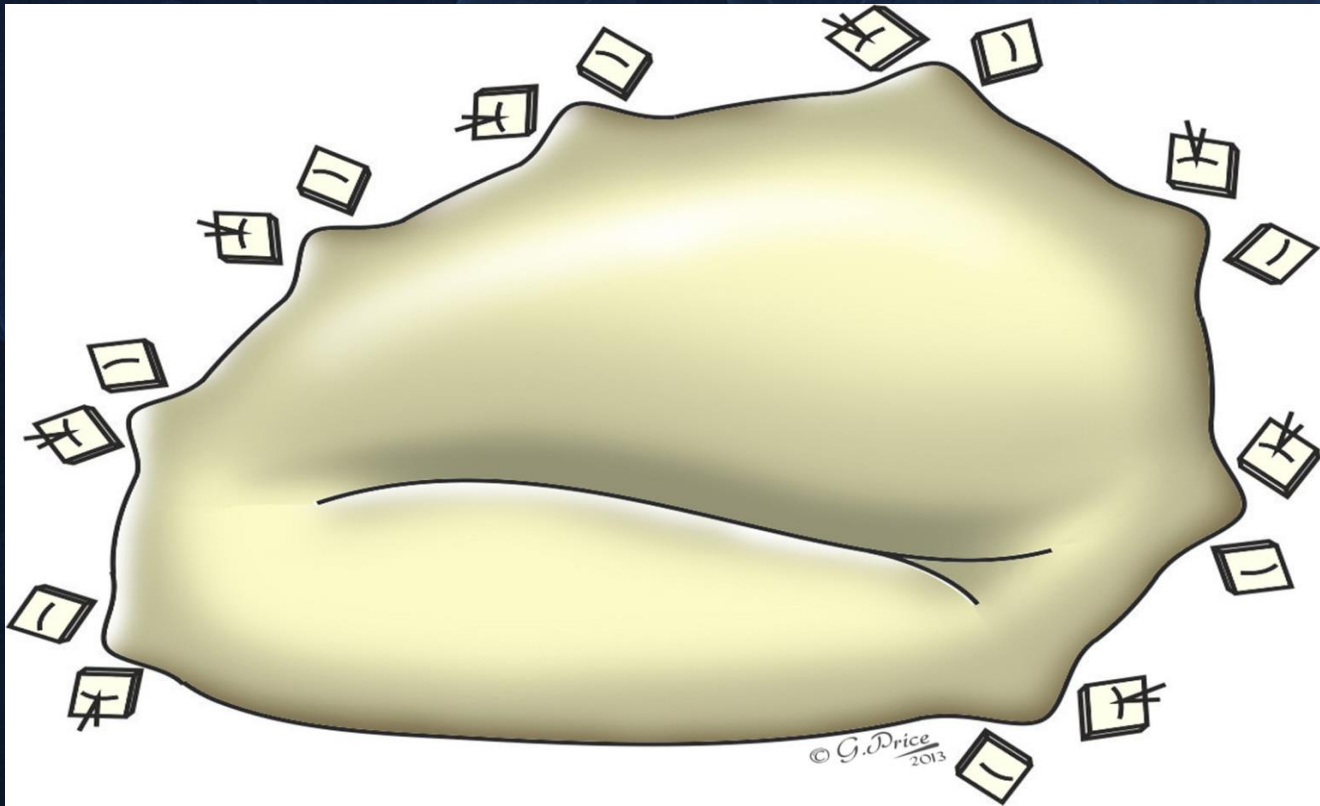
# Novel Technique for Tricuspid Valve Annuloplasty

- Initially only 8 sutures are passed along the circumference between the anteroseptal commissure and the midpoint of the posterior leaflet.
- These double pledgeted sutures are then tied to achieve reduction of the annulus and a water test is performed to test competency.
- Extra sutures may be implanted along the circumference crossing the posteroseptal commissure just into the septal leaflet if needed to achieve better competency and co-aptation.

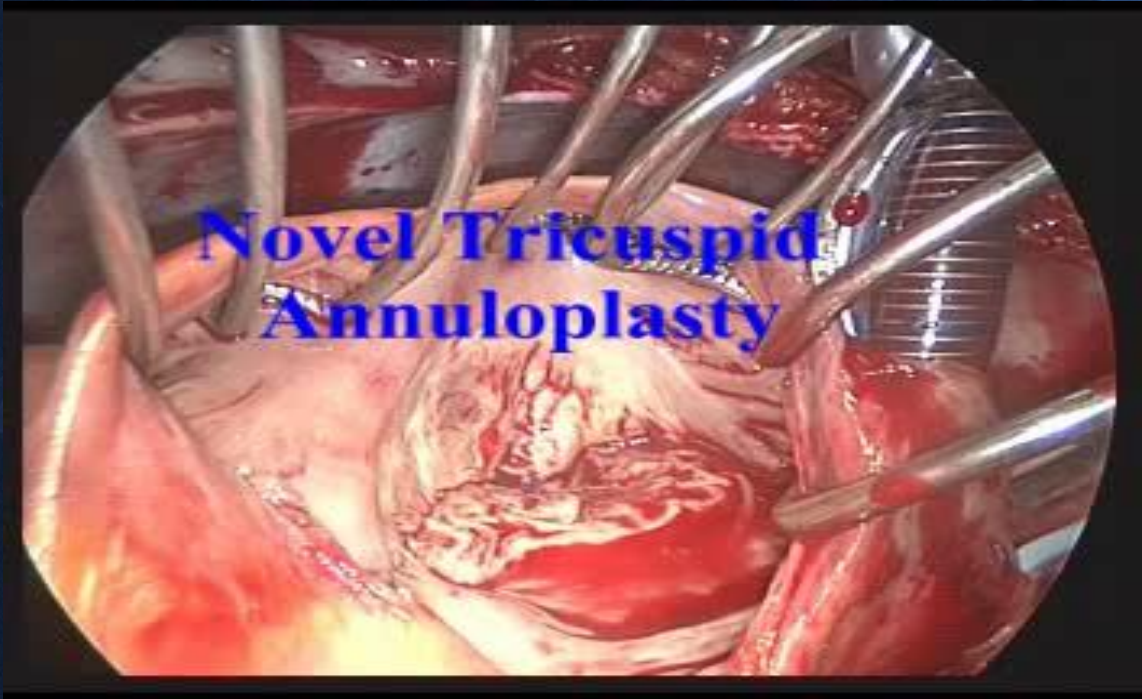







# Novel Technique for Tricuspid Valve Annuloplasty



# Novel Technique for Tricuspid Valve Annuloplasty

## Conclusion

- We have successfully used this technique to perform tricuspid valve annuloplasty with excellent results.
- Between January 2007 and December 2011, 38 cases of functional tricuspid regurgitation were repaired using this technique with concomitant mitral intervention +/- AF ablation.
- All patients had trace to mild tricuspid regurgitation at hospital discharge.
- Early/Intermediate follow-up: No re-intervention.
- Longer term follow up is currently in progress.



**Thank you**

