

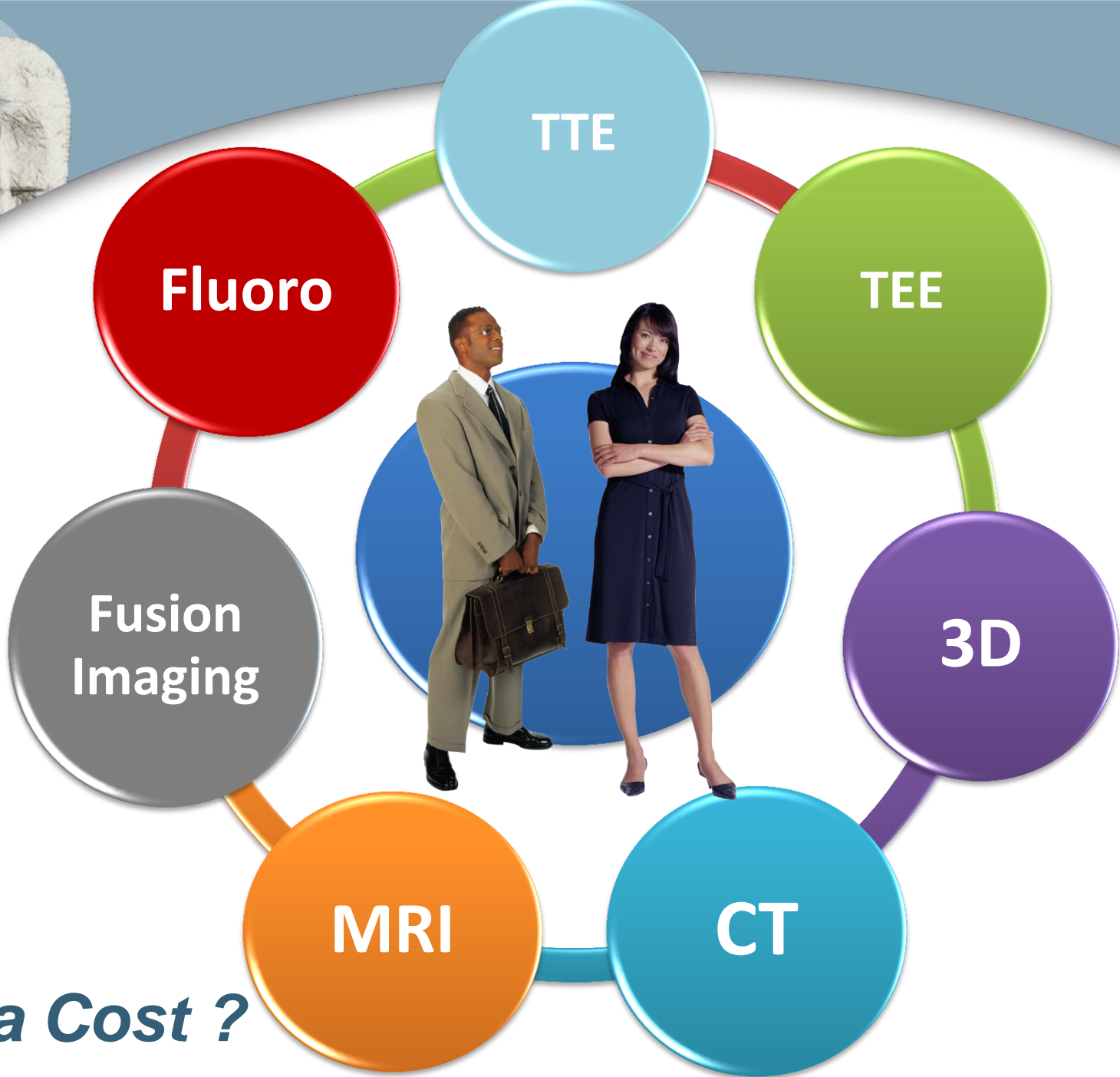


# The main dilemma

- **New catheter-based approaches to patients with cardiac disease.**
  1. Aortic valve implantation
  2. Closure of prosthetic paravalvular leaks
  3. Mitral repair

*How can we help ?  
What to do ?*





***Extra Cost ?***



# Fluoroscopy

## Advantages

- Images interventionalists work with
- Good definition
  - Catheters and wires
  - Devices
  - Calcified and metallic structures

## Limitations

- Poor anatomical definition
- Single plane
- Radiation exposure
- Contrast use



# 3D Echo

## Advantages

- Good definition of anatomy
- Visualize the same structure in different planes
- 3D images
- Minimizes radiation exposure
- Increases safety

## Limitations


- Interventionalists are not used to echo perspectives.
- Look back and forth
- Worse definition of intracardiac catheters

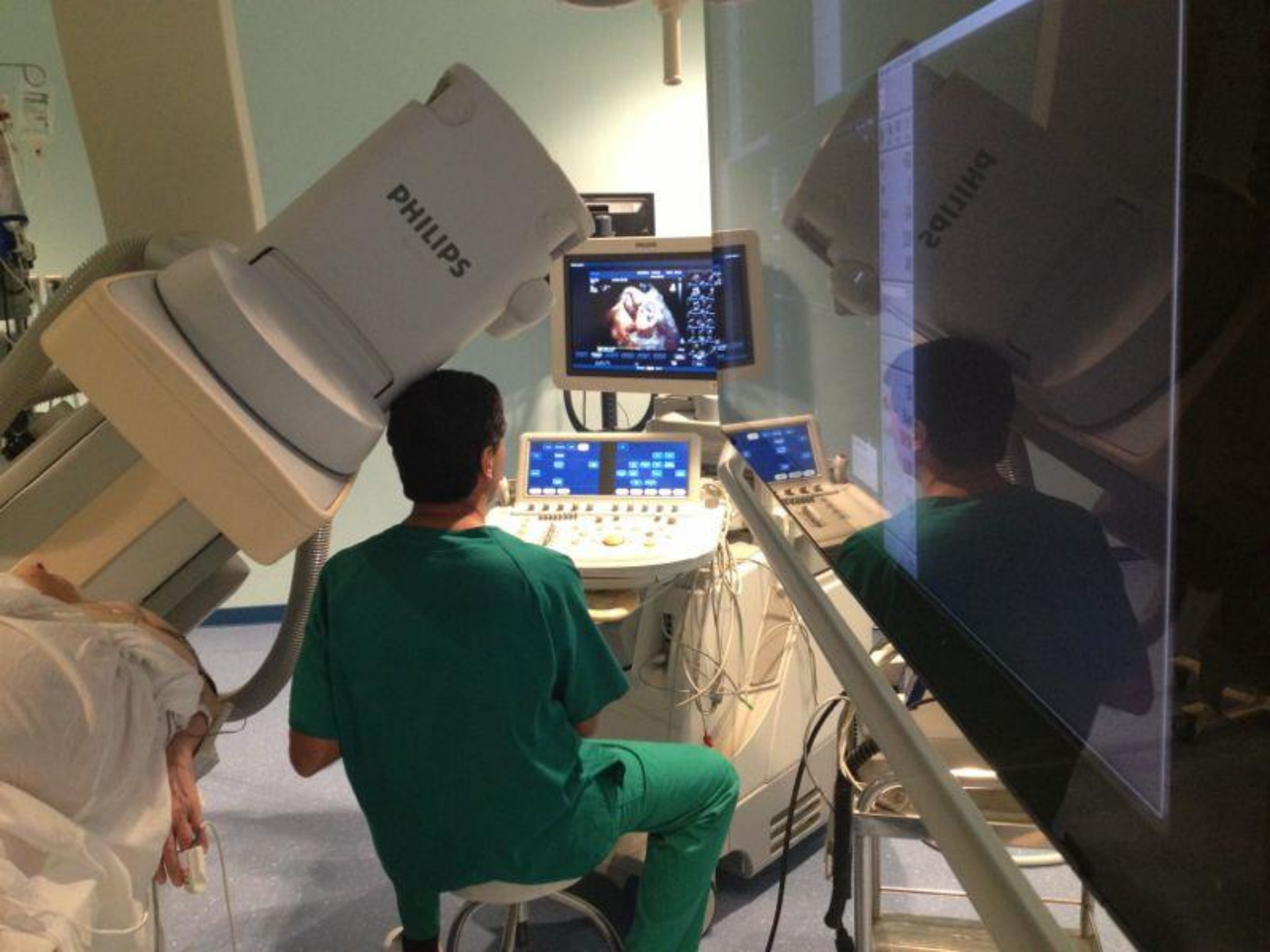

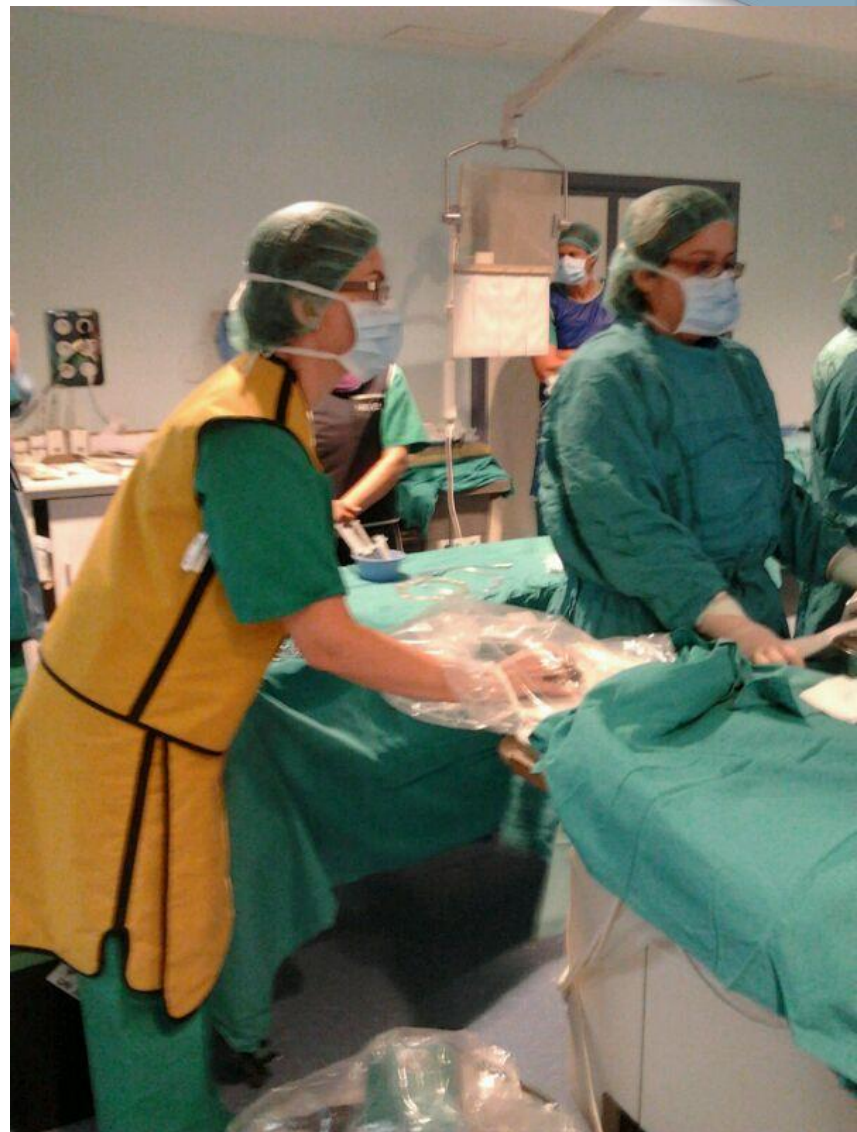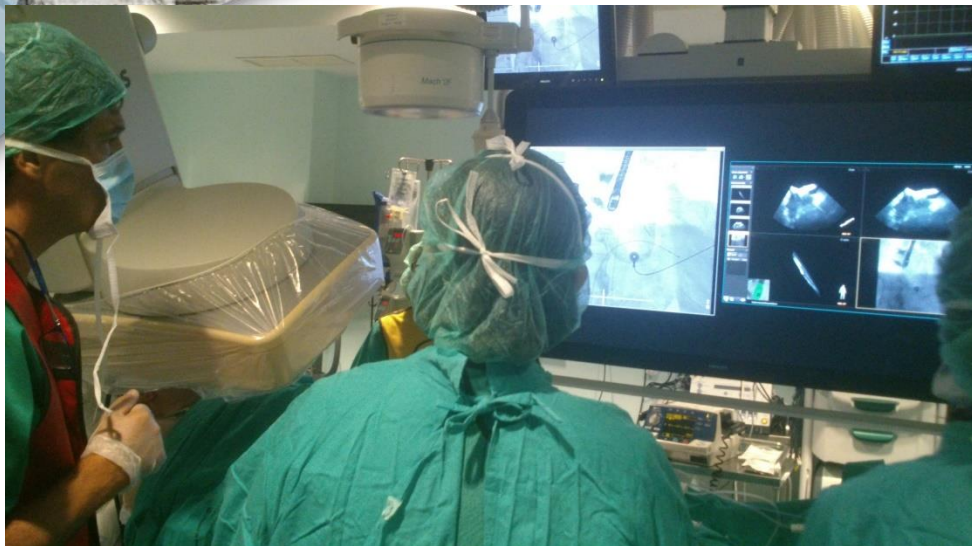# EchoNavigator

## A New Concept: UNITING IMAGES

- Combines live X-ray and live Echo images for structural heart disease repair.
- EchoNavigator recognizes TEE transducer and will detect and track its position.







Selec. disposición ?

Seleccionar vista ?

C-arm

Free


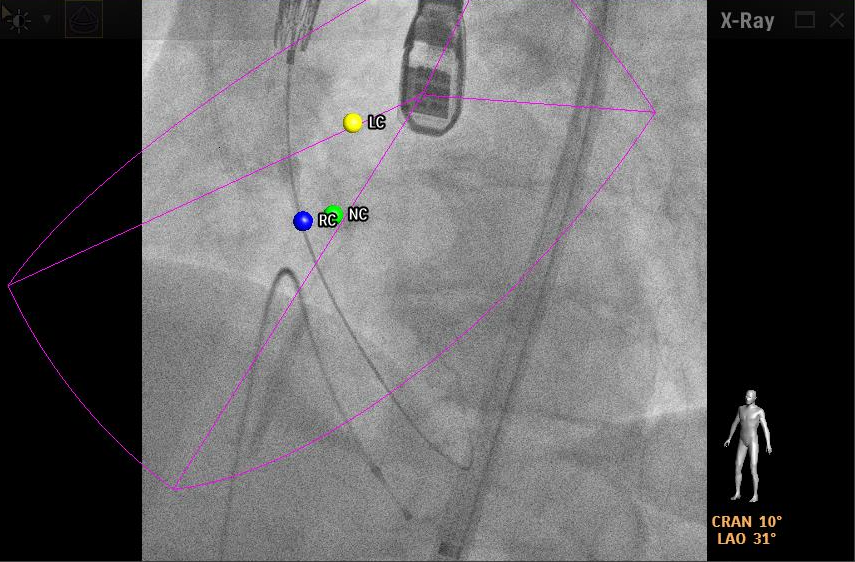
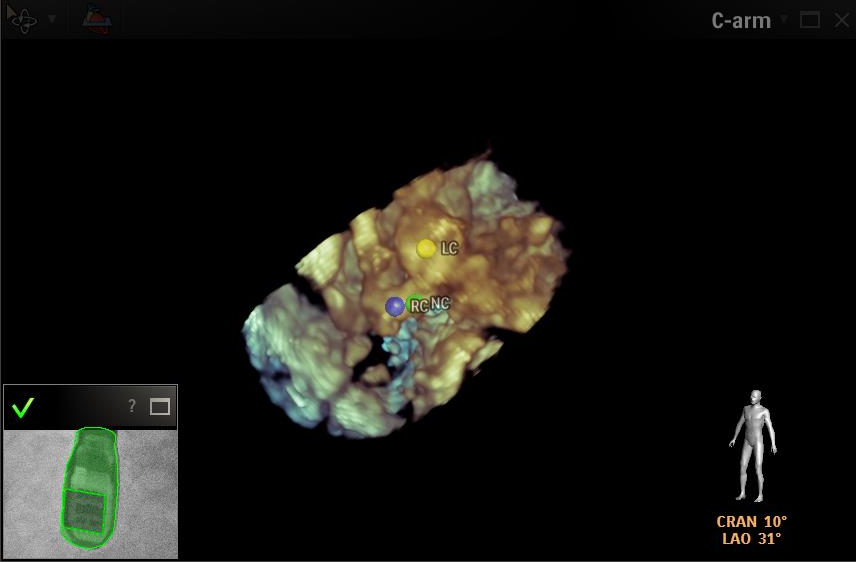
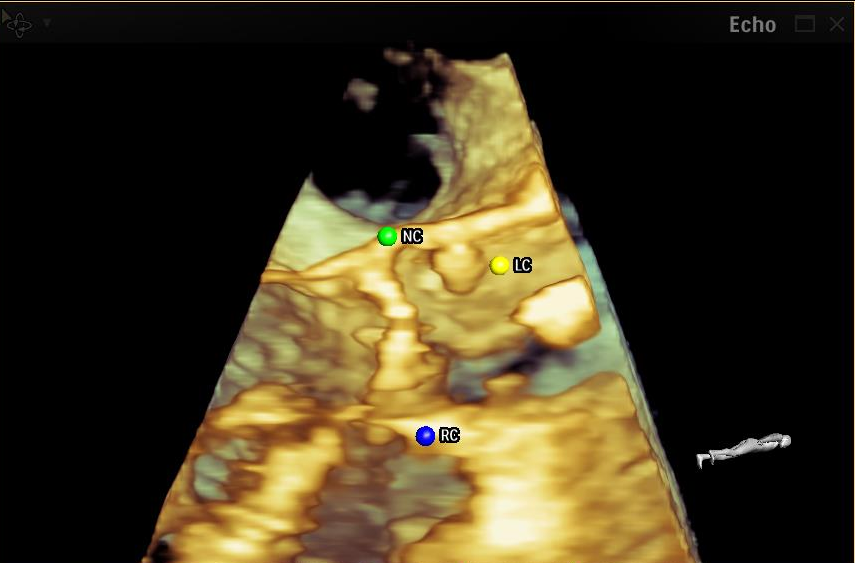
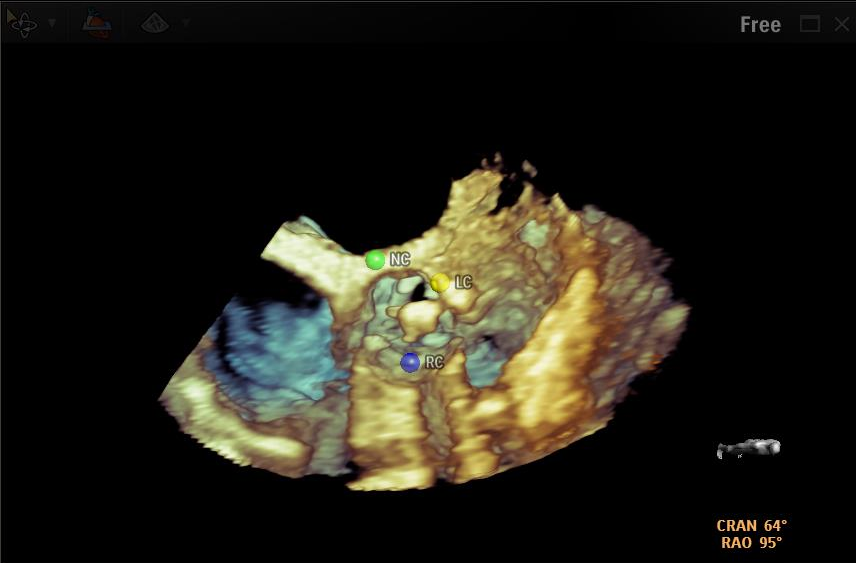
Echo

X-Ray

Marcado ?

Agregar Borrar

| Nombre                                 | Color                                 |
|--|---------------------------------------|
| <input checked="" type="checkbox"/> NC | <span style="color: green;">●</span>  |
| <input checked="" type="checkbox"/> RC | <span style="color: blue;">●</span>   |
| <input checked="" type="checkbox"/> LC | <span style="color: yellow;">●</span> |

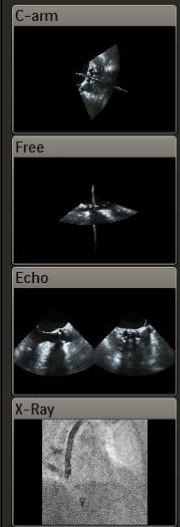



Selecc. disposición ?



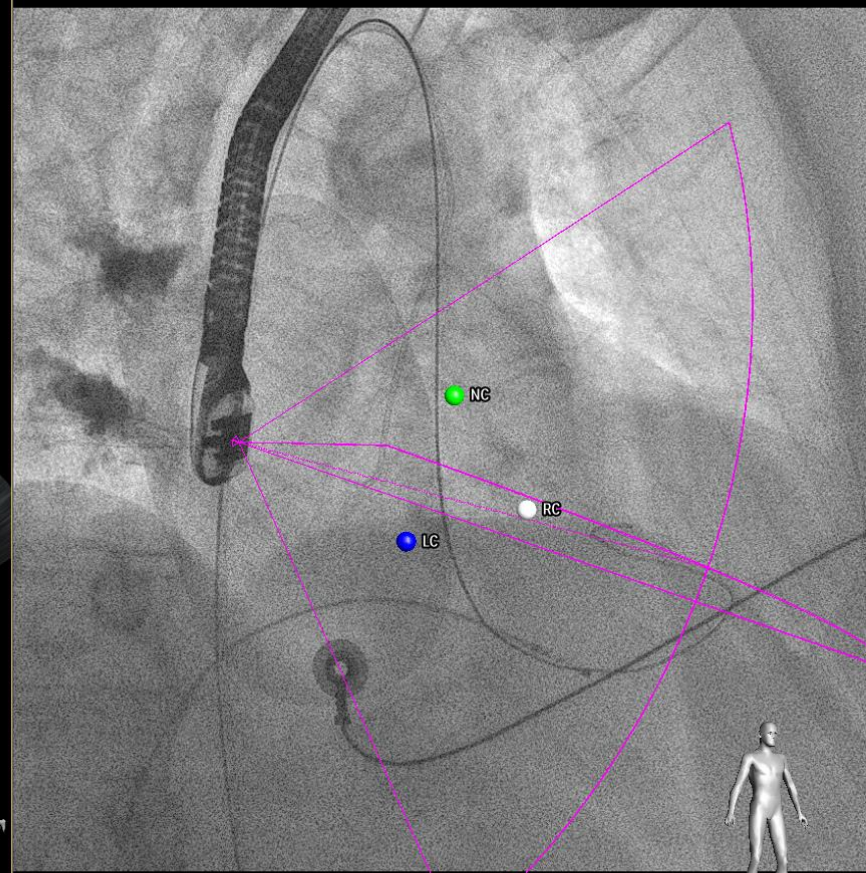
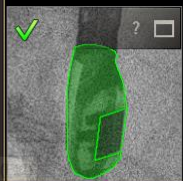
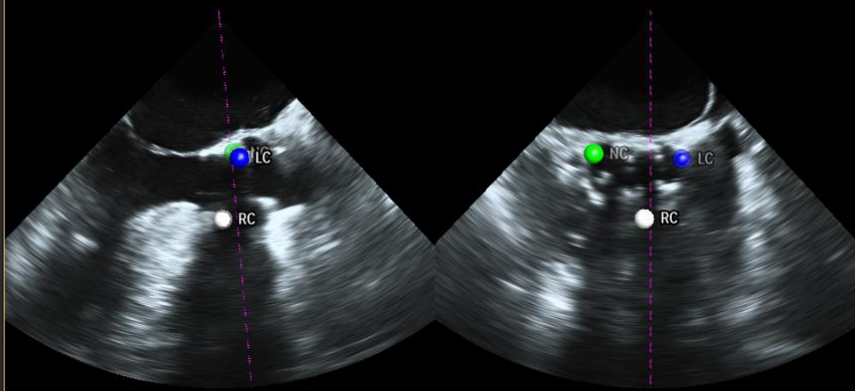
Seleccionar vista ?



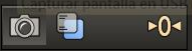
Marcado ?



| <input checked="" type="checkbox"/> | Nombre | Color                                |
|-------------------------------------|--------|--------------------------------------|
| <input checked="" type="checkbox"/> | RC     | <span style="color: white;">●</span> |
| <input checked="" type="checkbox"/> | NC     | <span style="color: green;">●</span> |
| <input checked="" type="checkbox"/> | LC     | <span style="color: blue;">●</span>  |



RAO 29°





# Conclusión





## Advantages

- **Better understanding** of anatomy, placement, and post-release evaluation.
- Facilitates catheter **guidance** and sizing.
- Useful **for difficult locations** and multiple holes.
- **Minimizes** fluoroscopy time.
- Increases **safety** for patient and interventionalist.
- More **efficient** procedure.



## Advantages

- **Avoids confusion** of different perspectives of two different imaging modalities. Integrating Echo and X-Ray images
- **Improves communication** between echocardiographer and interventionalist
- **One-screen view** for interventionalist